

A Case of Sudden Onset Septicemia in Recurred Gastric Cancer Following S1 Plus Docetaxel Treatment

Sumiya Ishigami, Takaaki Arigami, Yoshikazu Uenosono, Yasuto Uchikado, Yoshiaki Kita, Ken Sasaki, Hiroshi Okumura, Hiroshi Kurahara, Yuko Kijima, Akihiro Nakajo, Kosei Maemura, and Shoji Natsugoe

Department of Digestive Surgery, Breast and Thyroid Surgery, Kagoshima University School of Medicine, Kagoshima, Japan

Pyogenic liver abscess in patients with malignant disease is a fatal state and is easily diagnosed. We presented a rare case of sudden fatal septicemia following anticancer treatment for recurred gastric cancer due to multiple liver abscesses which could not be diagnosed. A 72-year-old male with recurred gastric cancer received anticancer agents. He had a history of distal gastrectomy with right hepatic lobectomy for hepatic metastasis. He received anticancer treatment in the outpatient's service center periodically, and his performance status was preserved with nothing in particular. After administrating docetaxel, he suddenly developed septicemia and multiple organ failure and died 5 days after strong medical supports. Pathological autopsy revealed that multiple minute abscesses of the liver which could not be detected macroscopically were the causes of fatal septicemia. The etiology, therapies and prognosis of rare entity are being discussed.

Key Words: Liver abscess, pyogenic; Sepsis; Stomach neoplasms; Anticancer drug; Immunodeficiency; Hepatectomy

Introduction

The clinical outcome of pyogenic liver abscesses with malignant disease is reportedly dismal.¹ Since liver abscesses can be easily detected by abdominal computed tomography (CT) or clinical symptoms, we have an opportunity to treat such diseases successfully; however, we rarely experience fetal septicemia from the occult liver abscesses which cannot be detected in advance. We hereby reported a rare case of acute septicemia unknown etiology following anti-cancer drug treatment, autopsy identified that *Escherichia coli* due to occult multiple liver abscesses was a trigger of these sepsis and organ failure.

Correspondence to: Sumiya Ishigami
Department of Digestive Surgery, Breast and Thyroid Surgery,
Kagoshima University School of Medicine, 8-35-1 Sakuragaoka,
Kagoshima 890-8520, Japan
Tel: +81-99-275-5361, Fax: +81-99-265-7426
E-mail: ishiga@m.kufm.kagoshima-u.ac.jp
Received May 9, 2013
Revised June 6, 2013
Accepted June 6, 2013

Case Report

A 72-year-old man having recurrent lymph node metastases from gastric cancer was admitted to Saiseikai Sendai Hospital to receive chemotherapy for gastric cancer. He had a history of dis-




Fig. 1. Resected specimen of the stomach and liver. Primary type 3 gastric cancer was found in the lesser curvature of the lower part of the stomach. Metastases to the liver was also resected curatively.

tal gastrectomy plus right hepatic lobectomy for advanced gastric cancer with liver metastases (Fig. 1). As paraaortic lymph node metastases had re-grown despite 17 courses of combination chemotherapy of paclitaxel (Bristol-Myers Squibb, NY, US) and S-1 (Taiho Pharmaceutical CO., LTD, Tokyo, Japan), the chemotherapy regime was changed to drip infusion of docetaxel (Sanofi-aventis, Paris, France). He showed no definite adverse effects at the first administration of docetaxel in short term hospitalization. This was the second treatment of docetaxel. On admission, he looked well-being and blood chemistry data showed no inflammatory disease. Before chemotherapy, abdominal CT showed neither metastasis nor abscesses in the liver. A total of 95 mg of docetaxel was infused intravenously. Before docetaxel administration, 8 mg of methylpredonine was routinely pretreated. One day after chemotherapy, the patient presented with a high-grade fever up to 39°C and low blood pressure (80/55 mmHg). At that time, laboratory findings revealed a white blood cell count of 13,550/L, a red blood cell count of 2,420,000/L, a blood platelet count of 109,000/L, aspartate aminotransferase of 1,112 IU/L, alanine aminotransferase of 774 IU/L, and CRP of 4.6 mg/dl. Since he was diagnosed with septicemia unknown etiology, continuous dopamine infusion and broad-band antibiotics were started. The next day, blood chemistry examination revealed serious liver and renal dysfunction. Although sepsis was strongly suspected from leucocytosis and the high value of C-reactive protein, the origin of sepsis could not be identified. Despite intensive care including hemodialysis and respiratory support, the patient died 5 days against strong medical care after docetaxel administration. Blood bacterial culture revealed strongly positive *E. coli*. An autopsy was performed to check the cause of rapid mul-

tle organ failure. There was no evidence of myelo-suppression by sequential chemotherapy from the result of bone marrow histology. Residual lymph node metastases from gastric cancer were histologically confirmed. Multiple occult liver abscesses which could not identified macroscopically were diagnosed by the histological examine (Fig. 2). They consisted of gram-negative rods and fungi (Fig. 3). Therefore, we concluded that fatal *E. coli* septicemia had been induced from multiple occult liver abscesses as a result of immuno compromised host induced by anticancer drug treatment.

Discussion

Pyogenic liver abscesses are found in 0.3~1.4% and their mortality rate is reportedly 11~13%.^{2,3} The majority of pyogenic liver abscesses are caused by infection originating from the biliary or intestinal tracts. *E. coli* infection may be introduced from the biliary tract. Patients with diabetes mellitus, immune deficiency and malignancy are at high risk for liver abscesses.⁴

The patient had recurrent gastric cancer and repeated anti-cancer drug administration. It seems that his occult immunosuppressive condition has a strong association with high risk for pyogenic liver abscess.

His white blood count was preserved during chemotherapy and normal bone marrow histology was confirmed by autopsy. This fatal septic state did not directly connected with myelo-suppression by redundant treatment of anti-cancer agents. When pyogenic liver abscess is diagnosed, the patients underwent radiologically guided percutaneous drainage of the liver abscess and they received empiric antimicrobial therapy.⁵ In the current case, regrettably, we

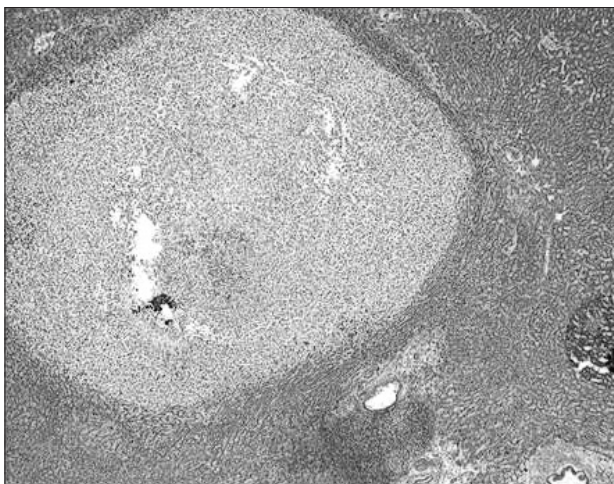


Fig. 2. Pyogenic micro-liver abscesses (H&E stain, ×100). Micro-liver abscesses were found in the entire liver, abscesses were consisted with bacteria and fungi.

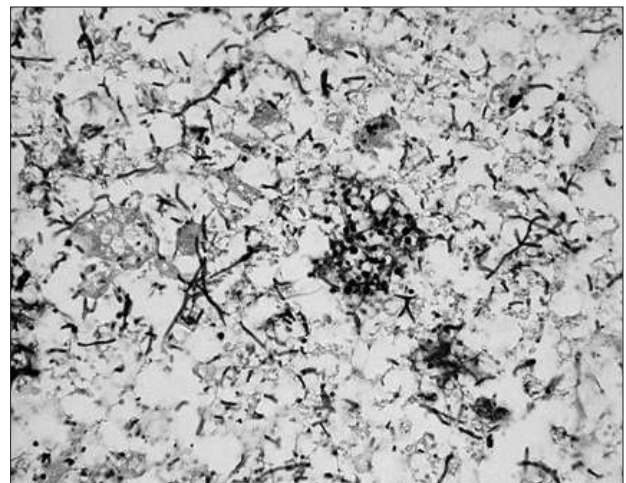


Fig. 3. Pyogenic micro-liver abscesses (H&E stain, ×200). Abscesses were consisted with bacteria and fungi.

could neither detect nor treat these liver abscesses before he developed fatal state. In this series, we did not perform CT examination. Considering the finding of the autopsy, we could not detect pyogenic liver abscess during the treatment.

In conclusion, we presented a rare case of fatal sepsis from multiple occult liver abscesses following redundant anti-cancer treatment. We should keep in mind the high risk of fatal sepsis from the pyogenic liver abscesses in cancer patients who had recurred tumor and history of redundant chemotherapy.

References

1. Bahloul M, Chaari A, Bouaziz-Khlaf N, Kallel H, Herguefi L, Chelly H, et al. Multiple pyogenic liver abscess. *World J Gastroenterol* 2006;12:2962-2963.
2. Greenstein AJ, Lowenthal D, Hammer GS, Schaffner F, Aufses AH Jr. Continuing changing patterns of disease in pyogenic liver abscess: a study of 38 patients. *Am J Gastroenterol* 1984;79:217-226.
3. Schiff E, Pick N, Oliven A, Odeh M. Multiple liver abscesses after dental treatment. *J Clin Gastroenterol* 2003;36:369-371.
4. Rahimian J, Wilson T, Oram V, Holzman RS. Pyogenic liver abscess: recent trends in etiology and mortality. *Clin Infect Dis* 2004;39:1654-1659.
5. Yeh TS, Jan YY, Jeng LB, Hwang TL, Chao TC, Chien RN, et al. Pyogenic liver abscesses in patients with malignant disease: a report of 52 cases treated at a single institution. *Arch Surg* 1998;133:242-245.