



Research paper

The spectrum of acute vestibular neuropathy through modern vestibular testing: A descriptive analysis

Dario Andrés Yacovino^{a,b,*}, Estefanía Zanutti^{a,1}, Marcello Cherchi^{c,d,2}^a Department of Neurology, Dr. Cesar Milstein Hospital, Buenos Aires, Argentina^b Memory and Balance Clinic, Buenos Aires, Argentina^c Department of Neurology, Feinberg School of Medicine, Northwestern University, Chicago, IL, USA^d Chicago Dizziness and Hearing, Chicago, IL, USA

ARTICLE INFO

Article history:

Received 16 October 2020

Received in revised form 2 February 2021

Accepted 24 February 2021

Available online 14 April 2021

Keywords:

Vestibular function

Vestibular neuritis

Video head impulse test

Saccule

Utricle

Vestibular nerve

ABSTRACT

Objective: Acute vestibular neuropathy (AVN), often referred to as vestibular neuritis, is a cranial neuropathy responsible for a significant proportion of cases of acute vertigo. This study describes the spectrum of lesion patterns in AVN as identified by video head impulse testing (vHIT) which assesses the high frequency vestibulo-ocular reflex function of the semicircular canals, and cervical and ocular vestibular evoked myogenic potentials (VEMPs) which assess otolith function.

Methods: We used vHIT and VEMPs to assess 35 patients with vestibular neuropathy in the acute stage.

Results: Unilateral superior division vestibular nerve involvement was the most common variant (57.1%), followed by unilateral superior and inferior division (28.5%), bilateral superior division (8.5%) and unilateral inferior division (5.7%). We observed a partial inverse correlation between the proportion of afferent fibers from an organelle, and the likelihood that the test of that organelle's function will be abnormal.

Conclusion: vHIT and VEMPs provide more detailed characterization of lesion pattern in AVN than caloric testing.

Significance: Comparison of lesion patterns from neuro-physiological testing with what is known about the proportional distribution of afferent fibers from the vestibular end-organelles suggests a new, neuro-anatomically based insight regarding susceptibility of these pathways to AVN.

© 2021 International Federation of Clinical Neurophysiology. Published by Elsevier B.V. This is an open access article under the CC BY-NC-ND license (<http://creativecommons.org/licenses/by-nc-nd/4.0/>).

1. Introduction:

The vestibular nerve is one of the 12 cranial nerves that form the cluster of direct sensory inputs to the brain. Anatomically related to the cochlear nerve, its “Y”-like configuration comprises two branches that combine into a single structure. Those branches are named according to their position in the internal auditory canal, as superior and inferior divisions. The superior division of the nerve carries the cupular input from the superior and horizontal semicircular canals (SCCs) and from the utricle, while the inferior division carries input from the posterior SCC and saccule. Similar to other cranial neuropathies, the vestibular nerve can be

independently affected by a variety of conditions including tumors, traumatic injuries, infections and inflammation (neuritis). The mechanism of the vestibular injury (immune, viral or vascular) in vestibular neuritis has remained elusive, so the term “vestibular neuritis” and the non-committal term “acute peripheral vestibulopathy” are currently used interchangeably.

Acute vestibular neuropathy (AVN), also called vestibular neuritis, is one of the archetypal conditions in vestibular medicine. It manifests as an acute vestibular syndrome (AVS) with vertigo, nystagmus, gait disturbance and autonomic symptoms (nausea and vomiting), all of which must by convention last more than 24 h (Hotson and Baloh, 1998; Kattah et al., 2009). The first clinical descriptions dated from 1924 (Nylen, 1924) and 1949 (Hallpike, 1949), and histological support was provided by Schuknecht and Kitamura in 1981 and others (Richard and Linthicum, 2012); Schuknecht and Kitamura, 1981. From this early evidence of VN two relevant aspects were observed; first, the histological changes are similar to other viral related neuropathies (e.g., Herpes zoster) such as the absence of evidence of micro-vascular occlusion; and second, the superior branch of the vestibular nerve is more often

* Corresponding author at: Memory and Balance Clinic, 177 Riglos Street Suite 2, Ciudad Autónoma de Buenos Aires, Argentina.

E-mail addresses: yac@intramed.net (D.A. Yacovino), m-cherchi2@northwestern.edu (M. Cherchi).

¹ Dr. Cesar Milstein Hospital, Buenos Aires, 951 La Rioja, Ciudad Autónoma de Buenos Aires 1221, Argentina.

² Department of Neurology, Feinberg School of Medicine, Northwestern University, Abbott Hall 11th Floor, 710 N. Lake Shore Dr., Chicago, IL 60611-3078, USA.

affected. Analysis of the nystagmus vector in the acute stage of VN provided additional support for the conjecture that the superior division is the affected part of the nerve in most of the cases (Yagi et al., 2010). Caloric testing, which is perhaps the most widely available method for assessing peripheral vestibular function, only measures function of one of the five vestibular organelles on each side (the horizontal semicircular canal, whose afferents travel through the superior division of the vestibular nerve), and thus cannot recognize other patterns of disease involvement by VN – though it bears mentioning that caloric testing assesses the low end of the frequency range of the horizontal SCC's function, whereas vHIT assesses the higher end thereof.

A contemporary vestibular laboratory includes both video head impulse testing (vHIT) and vestibular evoked myogenic potentials (VEMPs), which afford more comprehensive assessment of the 5 vestibular organelles on each side. The increased application of vHIT and data acquisition are facilitating more accurate characterization of the lesion profile of AVN. Therefore, applying these tests on a larger sample of AVN patients should permit a reassessment of whether this disease predominantly involves the superior division of the vestibular nerve, or is actually a spectrum of nerve lesions.

Our study has two aims. The first aim is to describe the variants of AVN observed through vHIT and VEMPs in patients with vestibular neuritis in the acute stage, and to illustrate for the clinician the spectrum of AVN observed in daily practice. The second aim is to provide new insights into vestibular lesion pattern by comparing our results with the micro-anatomic literature of the human vestibular nerve.

2. Methods

A retrospective cohort study was conducted. Patients with all variants of AVN that were evaluated between 2014 and 2018 at our tertiary clinic and its associated vestibular disorders centers networks were considered for this study. The patients were selected from the database according to established criteria. The inclusion criteria based on the HINTS protocol (Kattah et al., 2009) were patients without prior history of recurrent vestibular symptoms who (1) experienced new onset spontaneous and sustained acute vestibular syndrome (lasting more than 24 h) within the preceding 15 days; (2) had physical examination (nystagmus) consistent with peripheral vestibular involvement (horizontal-torsional, unidirectional, suppression with fixation) and without other cranial nerve or additional neurological abnormalities; (3) had both multi-axial vHIT and air conducted cervical and ocular VEMPs performed within the first 15 days from the onset of symptoms; (4) had no discernable lesion in the posterior fossa or vestibular nerve on a 1.5 or 3 Tesla brain MRI with contrast (and diffusion sequence) after 72 h of symptom onset; (4) had no subjective hearing complaints, and had an audiogram showing no synchronous ipsilateral hearing loss (to exclude labyrinthitis and Ménière's disease); (5) had no evidence of a more convincing alternative diagnosis (e.g., vestibular migraine) during the subsequent clinical evaluation from at least 1 year of follow up. Since there could be variants of AVN affecting canals other than the horizontal, a normal bedside horizontal Head impulse test (HIT) was *not* regarded as an exclusionary criterion. However, this subgroup of patients needed at least 2 or more 1.5 or 3 Tesla brain MRIs (with diffusion) without evidence of any lesion in the posterior fossa, performed within a 4-week interval to be included in the study.

In order to include individuals with sequential forms of AVN, patients with a well-documented history compatible with AVN supported by clinical examination, caloric testing, vHIT and MRI negative for any central lesion were not excluded from the study.

This research received prior approval from our institutional review board.

All vestibular tests and the physical examination were performed by the same operator (DAY) using the same video goggles and VEMP procedures. In all patients the VOR gain was assessed with vHIT (Eye See Cam®, Interacoustics, Denmark). The vestibular evoked myogenic potentials (VEMPs) were measured from the cervical muscles (cVEMP, cervical VEMP) and extraocular muscles (oVEMP, ocular VEMP) using 500 Hz air-conducted tone bursts at 100 dB (Epx Eclipse®, Interacoustics, Denmark). Two VEMP trials were performed; if the amplitude of both results were within the 40% difference between them, then the study was considered reliable and the higher amplitude was used.

The multi-axial vHIT was reviewed with specific attention to the vestibulo-ocular reflex (VOR) gain of all 6 canals and corrective catch up saccades. The software calculated VOR gains during in vHIT by two methods: the instantaneous velocity gain (eye velocity/head velocity) at a 60 ms window (VOR60), and the regression slope between head and eye velocity (VORrs). The normal vHIT range in our lab was obtained from a control group of 25 normal subjects (mean \pm 2 SD for VORrs gains). The side-to-side quotient was defined as the asymmetry index (gain regression asymmetry) between sides. Abnormal horizontal VOR gain was defined as below 0.8 for VORrs (range 0.9–1.12), asymmetry >6% and (\pm 2 SD). The range of normal values for the vertical canals VORrs gain was between 0.82 and 1.26 and asymmetry <8% (Yacovino et al., 2018).

The single variable used to measure the canal function was the VOR gain regression slope (VORrs), since it is more reliable than the occurrence of catch-up saccades or instantaneous VOR gain, in tracings contaminated by spontaneous nystagmus as observed in the acute stage of VN.

Evoked responses of VEMP include two peaks of vestibular origin, which appear at approximately 13 and 23 ms in cVEMP (p13–n23), and at approximately 10 and 16 ms (n10–p16) in oVEMP. Normal values of VEMPs were based on data from 34 control subjects (age range 25–80 years) and compared with the results in the patients. The VEMP responses were considered abnormal when they were absent (no definable and replicable VEMP response) or had amplitudes less than the fifth percentile according to the non-parametric data from the control group. The lower limits of inter-peak amplitude were 22 μ V (range 22–180 μ V) and 0.9 μ V (range 0.9–8.5 μ V) for cVEMP and oVEMP, respectively. Interaural asymmetry above 34% for cVEMP and 37% for oVEMP (percentile 95%) were considered abnormal. Abnormal results on the latency of p/n potentials, or more than 40% of difference variability in the amplitude of potential p/n on 3 successive VEMP trials were regarded as indeterminate results.

The results of vHIT and VEMPs were analyzed as a binary outcome, normal or abnormal according to the normative data.

2.1. Topographic grouping procedure

Based on the nerve's anatomy vestibular neuritis can be divided into four variants. (1) If the anterior SCC, horizontal SCC and utricle were all involved then it was considered a complete superior division VN. However, if one of the organelle afferents was unaffected then the case was defined as partial superior division VN. (2) If the posterior canal and the saccule were both affected, then it was considered a complete inferior division VN. (3) Involvement of both divisions was defined as any combination lesion of the superior and inferior divisions was obtained in the vHIT and VEMP measurements. (4) In accordance with previous studies, bilateral forms of VN (bilateral sequential and bilateral simultaneous VN) were included to cover the full spectrum of this condition (Huppert et al., 2006; Schuknecht and Witt, 1985; Yacovino et al., 2018).

Table 1

Topographic spectrum of vestibular nerve involvement based on the results of 35 patients who underwent complete video head impulse testing (vHIT) and vestibular evoked myogenic potentials (VEMPs). The results are presented as binary outcomes (normal or abnormal). In 6 patients VEMPs (cVEMP n:4 and/or oVEMP n:2) were indeterminate since they presented with abnormally prolonged p1/n1 latency, and/or more than 40% of the variability in the peak-to-peak potential amplitude, recorded on three measurement trials. Consequently, the lesion profile was grouped based on the vHIT results alone. Superior and inferior division means at least one vestibular end-organ innervated by the superior and inferior division, respectively. Bilateral vestibular neuritis forms refer to bilateral involvement of vestibular neuritis (either sequential or simultaneous), topographically corresponding to vestibular nerve involvement. ASCC: anterior semicircular canal; HSCC: horizontal semicircular canal; PSCC posterior semicircular canal.

n: 35	HSCC	ASCC	PSCC	Utricle	Sacculle	CLASSIFICATION
Both branches (n: 10, 28.5%)						
3	affected	affected	affected	affected	normal	All canals + utricle
1	affected	normal	affected	affected	affected	PSC + HSC + utricle + sacculle
1	affected	affected	affected	normal	normal	Only canals
4	affected	affected	normal	affected	affected	Superior division + sacculle
1	normal	normal	normal	affected	affected	Utricle + sacculle
Superior branch alone (n: 20, 57.1%)						
3	affected	normal	normal	normal	normal	HSC
6	affected	affected	normal	undetermined	undetermined	Unclassifiable
1	affected	affected	normal	normal	normal	Only canals
7	affected	affected	normal	affected	normal	Complete superior division
3	affected	normal	normal	affected	normal	HSC + utricle
Inferior branch alone (n: 2, 5.7%)						
Bilateral forms (n: 3, 8.5%)						
Total (percent)						
	32 (91.4%)	25 (71.4%)	7 (20%)	22 (62.9%)	8 (22.9%)	Bilateral superior division

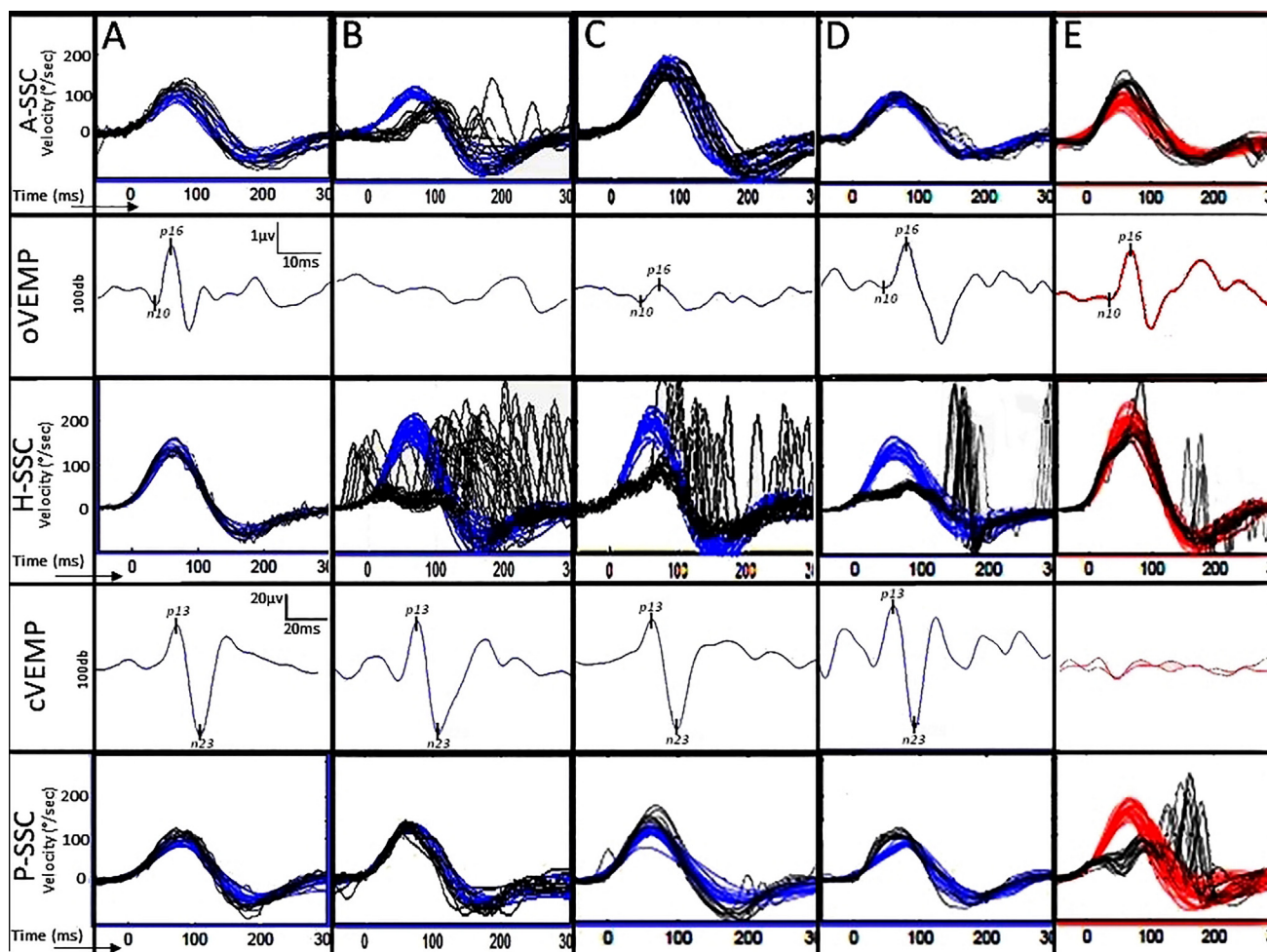


Fig. 1. Vestibular testing battery (vHIT and VEMPs) in the left labyrinth of normal subjects (column A), in cases with acute superior branch vestibular neuritis (columns B, C, D) and in a case of inferior branch vestibular involvement of the right ear (column E). Red and blue tracings represent responses originating from the right and left ears, respectively. For vHIT testing, the VOR eye velocity responses (in black) are superimposed on the head velocity tracings (in red or blue), inverted. The vertical axis represents the velocity scale from -100 to $300^\circ/\text{s}$, and the horizontal axis represents the time from -50 to 300 ms. The data in column B show a reduction on the VOR gain on the horizontal and anterior canals with evident catch-up saccades, and absent responses in the ipsilateral oVEMP, consistent with complete superior branch vestibular neuritis. The spontaneous nystagmus contaminated all the vHIT tracings. The data in column C are from a case with horizontal canal involvement and reduced oVEMP responses, but normal anterior and posterior canal function, consistent with partial superior division vestibular lesion. The data in column D are from a case with a more restricted superior vestibular nerve lesion, since only the horizontal canal gain is reduced, while the function of the remaining organelles has remained intact. The data in column E show reduced gain in the posterior canal, and absent cVEMP, consistent with a complete inferior division lesion. In this case there was oblique (predominantly down beat) nystagmus. (For interpretation of the references to colour in this figure legend, the reader is referred to the web version of this article.)

3. Results

Thirty-five patients (mean age: 51.6 years) with new AVN from our database met all inclusion criteria and none of the exclusion criteria. The restrictive temporal window of ≤ 15 days (in order to limit the analysis to cases in the acute stage), the lack of diffusion sequence in the MRI, and the presence of conductive hearing loss were the most frequent reasons for exclusion. The mean time from symptom onset to clinical examination and instrumented evaluation was 7.8 days (SD 4.7). The follow up of the patient (first to last visit interval) ranged between 12 and 50 months (mean: 36 months).

The AVN patients were classified according to the results of the vHIT and VEMPs into four main groups (Table 1).

Selected examples of data from a control subject and from each category of AVN are displayed in Fig. 1.

In our case series the frequency of involvement by organelle afferents, in descending order, was horizontal SCC (91%), anterior SCC (71%), utricle (63%), saccule (23%) and posterior SCC (20%). This order is similar, though not identical, to the studies by Taylor et al (Taylor et al., 2016) and Navari et al (Navari and Casani, 2020), in which posterior canal involvement was more common than saccular involvement.

Superior branch involvement represented the most frequent variant, accounting for 57.1% (20/35) of cases. Of those cases of superior division involvement, a complete superior division vestibular lesion was the most common form observed. Complete inferior division involvement was observed in only 5.7% (2/35) of cases. Involvement of both divisions was found in 28.5% (10/35) of cases, representing the second most common pattern overall in frequency. Bilateral involvement was found in 8.6% (3/35) of cases, of which 2 were bilateral sequential AVN (Fig. 2) and one was bilateral simultaneous AVN (Fig. 3). Isolated otolith impairment in combination with normal canal function was documented in a single case (Fig. 4). (To contrast those abnormal vestibular profiles with a vestibular testing in normal subjects see Supplementary Fig. 1).

For this study we have chosen to remain neutral with respect to etiology; nevertheless, of the 10 patients with complete (superior and inferior division) involvement, we checked 5 of them for Herpes zoster antibodies and found all 5 to be positive for IgG but negative for IgM; moreover, none of these 5 patients developed the herpetic skin lesions in the external auditory canal suggestive of Herpes zoster oticus; consequently we speculated that the IgG positivity was more likely due to recent varicella vaccination.

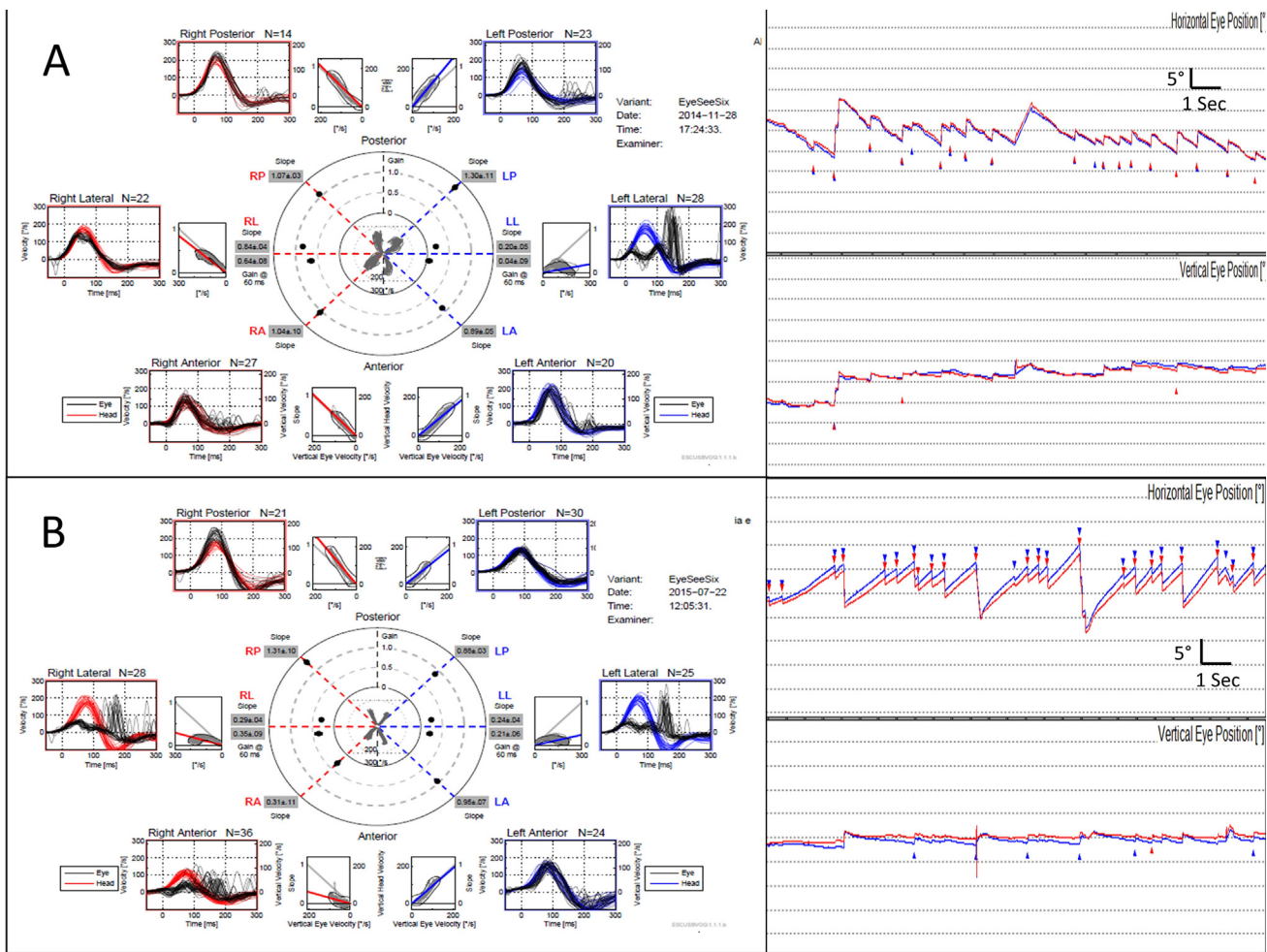


Fig. 2. Video head-impulse test and nystagmographic tracings in one of the patients with bilateral sequential vestibular neuritis. This patient with left sided vestibular neuritis in the acute stage exhibited spontaneous right beat nystagmus (right side, top panel). The vHIT performed at 7 weeks from symptom onset showed hypofunction of the left horizontal canal associated with well-organized covert and overt saccades (left side, panel A). Eight months later the patient reported a second attack of dizziness with severe imbalance. This second attack was likely superior branch vestibular neuritis on the right side, based on the fact that repeat vestibular testing showed spontaneous left and mild up beat nystagmus (right side, second panel from the bottom), and reduced VOR in the horizontal and anterior canals (left side, panel B). After 2 weeks the spontaneous nystagmus was no longer present, whereas the reduced VOR remained (data not shown).

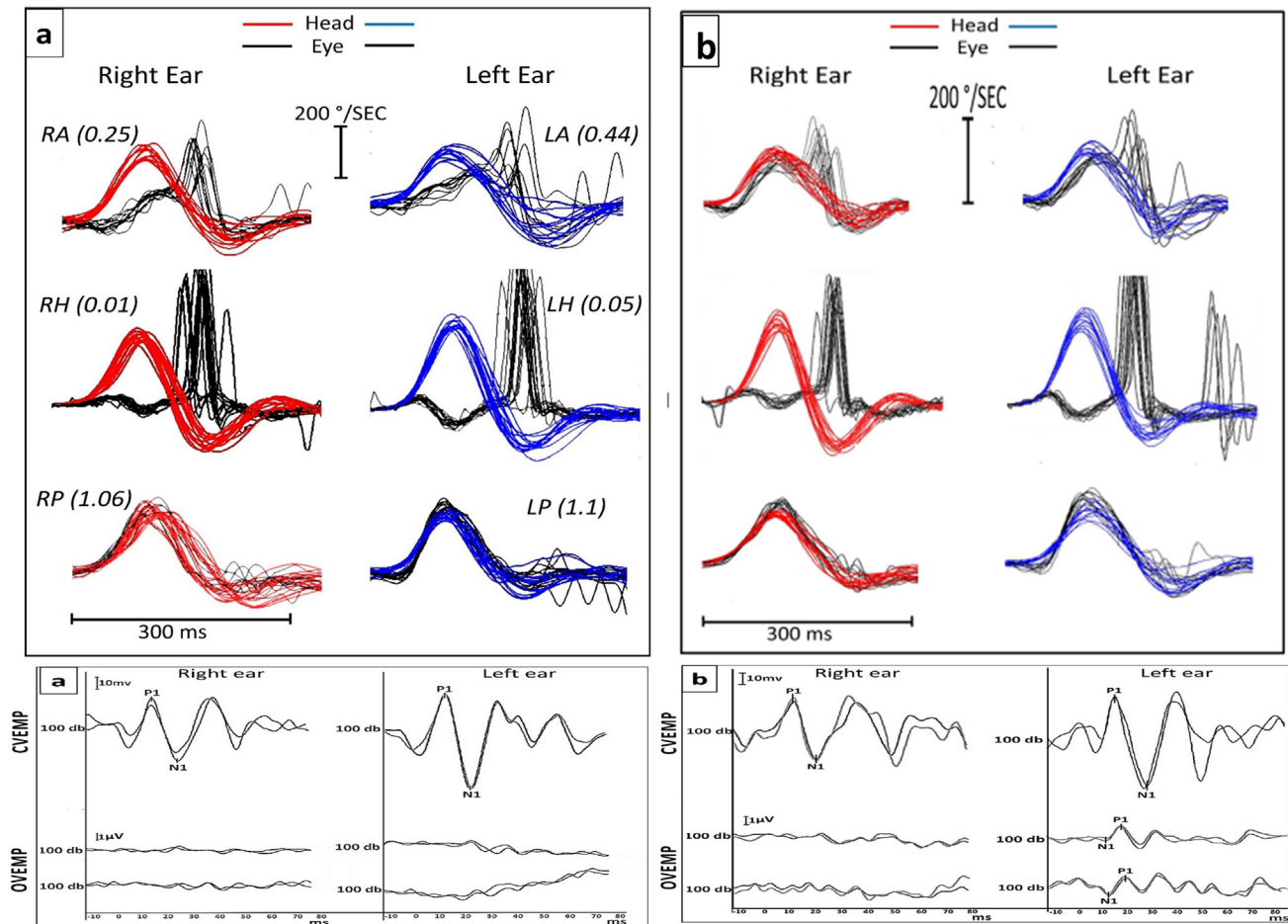


Fig. 3. Video head impulse test (vHIT), cVEMP and oVEMP, in a patient with bilateral simultaneous superior division vestibular neuritis. Panels on the left (a) show results of testing in the acute phase; panels on the right (b) show results of testing from follow-up two years later. AC (anterior SCC), HC (horizontal SCC) and oVEMP (utricle) are bilaterally affected. Both posterior SCCs and cVEMPs are normal. At the 2-year follow up, mild recovery was observed in terms of gain on both anterior canals and in the amplitude of the oVEMP only on the left ear. In the cVEMP tracing P1 represents the p13 peak and N1 represents the n23. In oVEMP tracing N1 represents the n10 peak and P1 represents the p16 peak; as reported elsewhere (Yacovino DA, et al., *Front Neurol* 2018; 9: 353) in this case the patient exhibited spontaneous up beat nystagmus at the initial symptomatic stage.

4. Discussion

Although most physicians feel reasonably comfortable with the clinical diagnosis of AVN, several questions remain regarding the exact pathogenesis, the treatment, the frequency of sub-variants (e.g., pure otolithic involvement) and why some organelles' afferent pathways are more vulnerable than others. One aim of this study is to characterize the frequency of different variants of AVN encountered in vestibular clinics. Understanding these lesion profiles may improve their recognition in the real-world setting.

This study relied heavily on vHIT. When acute vestibular hypofunction is suspected, it is recommended to start with vHIT due to its low burden for the test subject (Starkov et al., 2020). Loss of caloric function by itself is insufficient to diagnose VN given that it identifies a deficit in only 1 out of 5 vestibular organelles. In addition, caloric testing is uncomfortable for an acutely ill patient, it poses several technical challenges, and the underlying spontaneous nystagmus may result in miscalculation of vestibular hypofunction.

Exclusively superior division AVN was the most common presentation in our series, similar to the recent study by Navari and Casani (Navari and Casani, 2020). Although supportive histological data are scarce, superior division involvement was considered for years to be a characteristic finding of VN (Fetter and Dichgans,

1996; Himmelein et al., 2017). This was supported by what was at that time the most widely available tool, the caloric test. Several explanations for this pattern were proposed, including (a) direct viral invasion via the facio-vestibular anastomosis selectively involving the superior division; (b) the longer and narrower aspect of the bony channel of the superior division than the inferior division of the vestibular nerve, making the former more vulnerable to compression inside the channel due to edema (Goebel et al., 2001); and (c) a double innervation of the posterior SCC which confers greater resistance to injury of the inferior portion of the labyrinth (Arbusow et al., 1999).

In mild to moderate cases, a more distal involvement of the nerve could lead to incomplete and selective distal branch lesions (Goebel et al., 2001).

In contrast to our study, other authors using similar vestibular testing batteries have reported that involvement of both superior and inferior divisions is the most prevalent profile in VN (Guan et al., 2017; Taylor et al., 2016). This discrepancy may be attributable to a selection bias or to dissimilar inclusion/exclusion criteria.

Like other cranial neuropathies, AVN is a dynamic process, and some spontaneous recovery (restoration of function through central compensation) is expected (Büki et al., 2017; Fu et al., 2019; Palla and Straumann, 2004). Vestibular testing performed at a significant delay after symptom onset may not be representative of

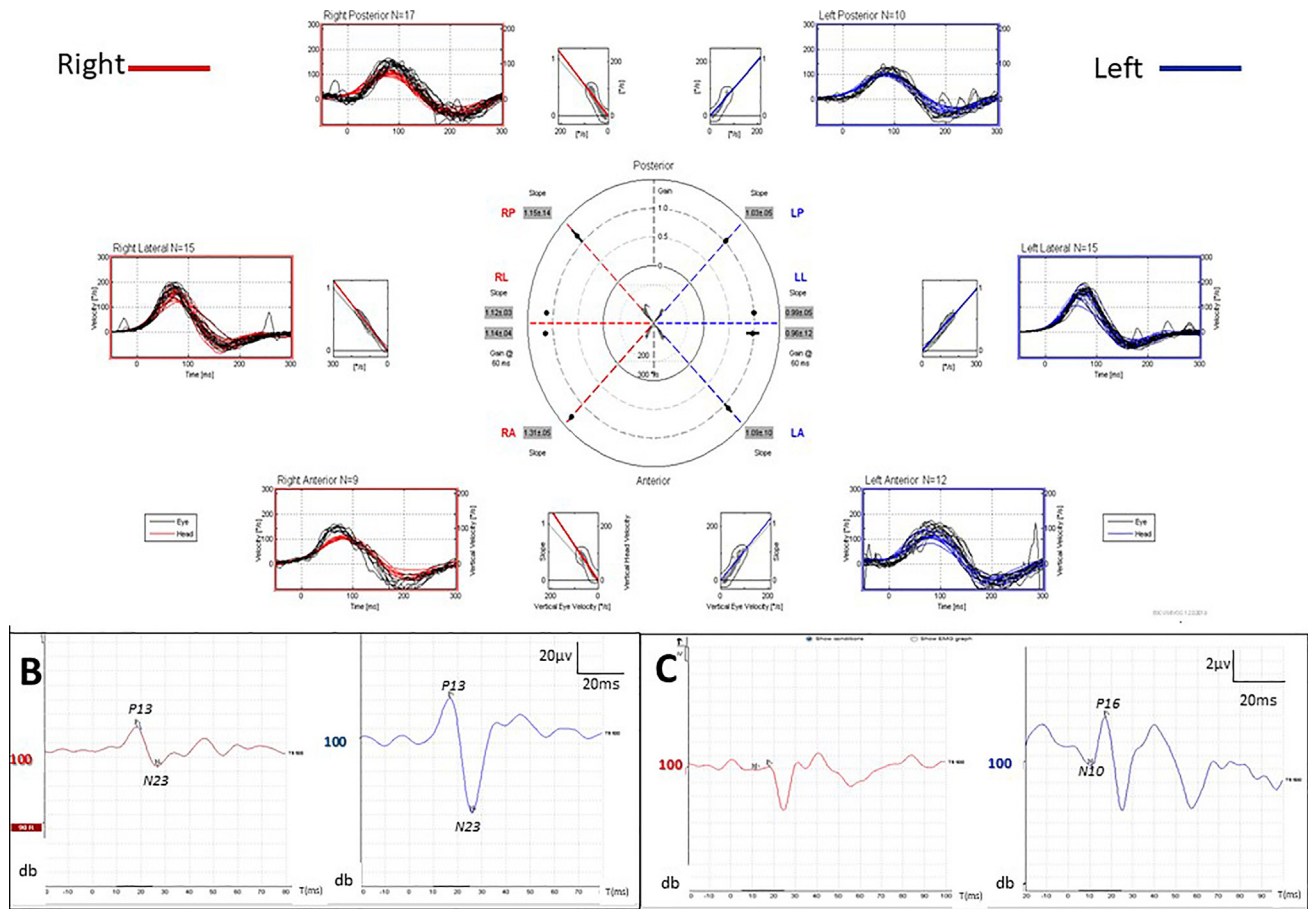


Fig. 4. Pure otolithic involvement in VN. This unusual case, a young woman presented to the emergency room with acute vertigo and sustained positional nystagmus with mixed torsional and mild horizontal components, with fixation and gait disturbance. She subsequently developed frequently recurring typical BPPV in the right ear, eventually involving all three canals. In the right ear the oVEMP was absent and the cVEMP was weak. At 3 months she was better but was still unbalanced. Note that on vHIT, the VOR gain was normal in all three canals, and there were no catch-up saccades.

the initial injury and the original topography. In contrast, testing performed too early (<24–48 h) may provide a similarly incomplete picture of the final extent of vestibular damage (Taylor et al., 2016). Therefore, the timing between symptom onset and vestibular assessment is critical for correct localization of the lesion within the vestibular nerve.

Isolated involvement of nearly each individual vestibular end-organ has been reported as an independent variant of AVN. For example, pure ampullary nerve involvement of the horizontal or posterior canals, and isolated utricular lesions have been described (Blodow et al., 2013; Guan et al., 2017; Halmagyi et al., 2002; Kim and Kim, 2012; Magliulo et al., 2012; Manzari et al., 2014). Despite this variability, an isolated lesion of the anterior SCC afferents has never been reported, nor did any such cases appear among our data.

Interestingly, one patient displayed an absent response on the utricle (oVEMP) and moderate impairment on the saccule (cVEMP) with normal multiaxial vHIT (Fig. 4). This AVN profile would be attributed to a selective lesion of fibers in the superior vestibular nerve. Since there are neural anastomoses within the vestibular nerve – such as Voit’s nerve (Curthoys et al., 2014; Gacek and Rasmussen, 1961; Voit, 1907), which carries about 10% of saccular fibers into the superior division of the vestibular nerve – it is conceivable that the combination of oVEMP absence and cVEMP weakness partly reflects input from crossed labyrinthine afferents. Similarly, due to the double innervation of the saccule, it could be misclassified as a lesion of both divisions in cases with superior

nerve lesion plus saccular involvement. In any case, there is still insufficient evidence to clarify the group to which such cases would belong. Since the oVEMP response is mediated by an ascending pathway, and the cVEMP by a descending pathway, we would not expect a single central lesion to account for this pattern; moreover, the function of the canal afferents was normal, and MRI failed to demonstrate any lesion in the vestibular nuclei.

AVN is typically unilateral, and while rare, a separate lesion involving the contralateral nerve has been described in 1–4% of patients (Huppert et al., 2006; Mandala et al., 2010). Such cases usually occur in a sequential pattern, after a long period (months to years) following the initial nerve damage (Huppert et al., 2006; Schuknecht and Witt, 1985). Our data include two cases of a bilateral sequential vestibular lesion (Fig. 2) and one case of an acute bilateral simultaneous AVN (Fig. 3) as we reported elsewhere (Yacovino et al., 2018). Three patients in our series were classified within this group, all of them involving the superior division. The underlying mechanisms of contralateral lesions are unknown, but may be related to a sympathetic immune response (Young et al., 2016). In support of this conjecture were an early study that failed to demonstrate the efficacy of antiviral therapy (valacyclovir) in acute VN (Strupp et al., 2004), the finding of elevated pro-inflammatory components in the peripheral blood in the acute stage of VN (Fattori et al., 2003; Kassner et al., 2011), and some evidence of positive effect of corticosteroids (Solis et al., 2019). Taking these into account, some authors postulate an immune mediated injury as the main mechanism of AVN (Wu et al., 2019).

Table 2

Comparison of the relative percentage of fibers of each organelle in the vestibular nerve from temporal bone histological studies (two columns on left) with the relative percentage of organelle involvement from clinical studies (three columns on right). ASCC: anterior semicircular canal; HSCC: horizontal semicircular canal; PSCC posterior semicircular canal.

Histologic studies of human temporal bones, with organelle afferents and their percentage of total fibers of the vestibular nerve, in ascending order		Clinical studies of the percentage of cases of vestibular neuritis in which an organelle is involved, in descending order		
Lee et al. (1990)	Bergström (1973)	Taylor et al. (2016)	Navari and Casani (2020)	Our series
HSCC (12%)		HSCC (97.7%)	HSCC (97%)	HSCC (91.4%)
ASCC (12.8%)		ASCC (93%)	ASCC (83%)	ASCC (71.4%)
PSCC (14.5%)	PSCC (13.35%)	Utricle (72.1%)	Utricle (73%)	Utricle (62.9%)
Sacculle (26.5%)	Sacculle (22.05%)	PSCC (39.5%)	PSCC (46%)	Sacculle (22.9%)
Utricle (34.2%)	Utricle (32.44%)	Sacculle (39%)	Sacculle (44%)	PSCC (20%)

The vHIT and VEMP provide more comprehensive tools than the caloric test to identify these variants of VN. Although the most frequent cause of bilateral vestibular weakness is ototoxicity, that is not a plausible etiology in our patients; there would need to be a history of ototoxic exposure, and the onset of vestibular symptoms would need to be gradual; our cases did not have these features. Rationally, patients with bilateral vestibular hypofunction who were previously considered idiopathic might be reclassified within a bilateral AVN group according to the results from a modern test battery.

Although other authors have reported on the distribution of the vestibular nerve lesions in AVN (Magliulo et al., 2014; Navari and Casani, 2020; Taylor et al., 2016), our study aimed to survey all potential variants, including the sequential or “patchy” forms. In any case, our observations and those of others do show that it is quite characteristic for AVN to manifest as a sub-total lesion of the vestibular nerve.

The question of why vestibular neuritis involves specific afferent pathways in the observed patterns remains unanswered, though comparing our data (and that of others) with what is known of the microanatomy of the vestibular nerve may suggest some clues. The microstructural anatomy of the vestibular nerve is difficult to analyze due to a variety of factors, such as neuronal anastomoses with adjacent structures (Ozdogmus et al., 2004), the gradual rotation in the disposition of the fibers along the course of the nerve (Silverstein et al., 1986), the variable orientation between individuals (Rasmussen, 1940), variability between genders (Moriyama et al., 2007), the attrition of nerve fibers with age (Bergström, 1973, (NAGAI et al., 1999), and variability between different methods of histological preparation (Lopez et al., 2005). Nevertheless, a few painstaking studies on human specimens have been conducted, each with its merits and limitations. For example, the study by Lee et al. (Lee et al., 1990) has the merit of tracing fibers from each of the five vestibular organelles, but the limitation of analyzing only three specimens; the study by Bergstrom (Bergström, 1973) has the merit of analyzing forty specimens, but the limitation of conflating the afferents from the anterior and horizontal canals; the study by Lopez, Ishiyama et al (Lopez et al., 2005) has the merit of analyzing thirteen specimens, but the limitation of completely omitting saccular afferents. Some of those histologic data are juxtaposed with data from clinical studies in Table 2.

Interestingly, there is a partial inverse correlation between the proportion of afferent fibers from an organelle, and the likelihood that the test of that organelle’s function will be abnormal (with the utricle being a notable exception to this generalization). This relationship appears counterintuitive at first, as one might expect that the greater the cross-sectional area of the vestibular nerve occupied by an organelle’s of fibers, the more likely that it would be involved by a lesion (and thus the more likely that its dysfunction would be detected by a vestibular test). However, another way of conceptualizing this is that the larger the number of fibers from a given organelle, the less likely it would be for a lesion to interrupt

them all, effectively rendering that organelle’s function more resilient against a lesion. In other words, assuming a random distribution of damage from AVN involving a given number of fibers, a pathway containing a smaller total number of fibers will be proportionally more affected (and thus its dysfunction will be more readily detectable on vestibular testing), whereas a pathway containing a larger total number of fibers will be proportionally less affected (and thus its dysfunction will be less readily detectable on vestibular testing). This may be why, for example, the test of lateral canal afferents is abnormal in 91.4–97.7% of cases of AVN, even though those afferent fibers account for only 12% of the total fibers in the vestibular nerve.

5. Limitations of the study

This study was designed to demonstrate primarily the value of vHIT in classifying the sub-variants of an acute peripheral vestibular syndrome, and consequently does not consider caloric testing as the gold standard since that test does not assess function of the vertical canals. Therefore, patients with caloric hypofunction yet normal H-SCC gain in vHIT could be missed; it is known that results from these tests can be discrepant (Blodow et al., 2013; Burston et al., 2018; Fukushima et al., 2019; Jung et al., 2017; Mahringer and Rambold, 2014; McGarvie et al., 2015; Park et al., 2005; Rambold, 2015; Rubin et al., 2018; Wegmann-Vicuña et al., 2018; Yoo et al., 2016), and such discrepancies are believed to be attributable to the fact that the tests assess different frequencies of the vestibulo-ocular reflex (McCaslin et al., 2014, Redondo-Martínez et al., 2016, Zellhuber et al., 2014).

The question of whether a very small (lacunar) acute stroke undetected by MRI could provoke the symptoms in some patients is a limitation. However, even in the typical clinical forms (diagnosed by HINTS) the MRI has the last word, simply because the MRI is still regarded as the gold standard for detecting a central lesion. The probability of a stroke with two normal MRIs is believed to be extremely low (Choi et al., 2018), and we did check this in the atypical forms of AVN in the present study.

The optimal time frame after symptom onset for conducting these vestibular tests has not been established. In the interest of studying a relatively uniform clinical group of acute AVN patients, we used the inclusion criterion of <15 days from symptom onset. In a similarly arbitrary fashion, other studies have elected to use different time frames. It is certainly possible that a different time inclusion criterion could result in a different profile of lesion distribution patterns.

6. Conclusion

Examining each of the 10 vestibular end organs with vHIT and VEMPs is currently the most expeditious method for identifying

the lesion pattern in cases of acute vestibular syndrome presentation (from unilateral, to bilateral, to superior division, to inferior division, to single branch involvement). This more detailed characterization of the lesion pattern will facilitate more accurate diagnosis of AVN.

Future studies should analyze larger samples of AVN patients, including the less frequent forms (e.g., pure otolithic or bilateral), and consider investigating different time frames from symptom onset, since it is known that different tests may detect recovery (compensation) at different times.

7. Author disclosures

On behalf of all authors, the corresponding author states that there is no conflict of interest. This research did not receive any specific grant from funding agencies in the public, commercial, or not-for-profit sectors.

Acknowledgements

The authors express a debt of gratitude to Dr. Timothy Hain for his teaching, support and mentorship over many years.

Appendix A. Supplementary data

Supplementary data to this article can be found online at <https://doi.org/10.1016/j.cnp.2021.02.008>.

References

Arbusow, V., Schulz, P., Strupp, M., Dieterich, M., Von Reinhardtstoettner, A., Rauch, E., Brandt, T., 1999. Distribution of herpes simplex virus type 1 in human geniculate and vestibular ganglia: implications for vestibular neuritis. *Ann. Neurol.* 46 (3), 416–419.

Bergström, B., 1973. Morphological Studies of the Vestibular Nerve. *Otolaryngology. University of Uppsala, Uppsala*, p. 39.

Blodow, A., Helbig, R., Bloching, M., Walther, L.E., 2013. Isolated functional loss of the lateral semicircular canal in vestibular neuritis. *HNO* 61 (1), 46–51.

Blodow, A., Helbig, R., Wichmann, N., Wenzel, A., Walther, L.E., Bloching, M.B., 2013. Video head impulse test or caloric irrigation? Contemporary diagnostic tests for vestibular schwannoma. *HNO* 61 (9), 781–785.

Büki, B., Hanschek, M., Jünger, H., 2017. Vestibular neuritis: Involvement and long-term recovery of individual semicircular canals. *Auris Nasus Larynx* 44 (3), 288–293.

Burston, A., Mossman, S., Mossman, B., Weatherall, M., 2018. Comparison of the video head impulse test with the caloric test in patients with sub-acute and chronic vestibular disorders. *J. Clin. Neurosci.* 47, 294–298.

Choi, J.-H., Oh, E.H., Park, M.-G., Baik, S.K., Cho, H.-J., Choi, S.Y., Lee, T.-H., Kim, J.S., Choi, K.-D., 2018. Early MRI-negative posterior circulation stroke presenting as acute dizziness. *J. Neurol.* 265 (12), 2993–3000.

Curthoys, I.S., Vulovic, V., Burgess, A.M., Manzari, L., Sokolic, L., Pogson, J., Robins, M., Mezey, L.E., Goonetilleke, S., Cornell, E.D., MacDougall, H.G., 2014. Neural basis of new clinical vestibular tests: otolithic neural responses to sound and vibration. *Clin. Exp. Pharmacol. Physiol.* 41 (5), 371–380.

Fattori, B., Ursino, F., Cristofani, R., Galetta, F., Nacci, A., 2003. Relevance of plasma D-dimer measurement in patients with acute peripheral vertigo. *J. Laryngol. Otol.* 117 (6), 467–472.

Fetter, M., Dichgans, J., 1996. Vestibular neuritis spares the inferior division of the vestibular nerve. *Brain* 119 (3), 755–763.

Fu, W., He, F., Wei, D., Bai, Y., Shi, Y., Wang, X., et al., 2019. Recovery pattern of high-frequency acceleration vestibulo-ocular reflex in unilateral vestibular neuritis: A preliminary study. *Front. Neurol.* 10, 85.

Fukushima, M., Oya, R., Nozaki, K., Eguchi, H., Akahani, S., Inohara, H., Takeda, N., 2019. Vertical head impulse and caloric are complementary but react opposite to Meniere's disease hydrops. *Laryngoscope* 129 (7), 1660–1666.

Gacek, R.R., Rasmussen, G.L., 1961. Fiber analysis of the statoacoustic nerve of guinea pig, cat, and monkey. *Anat. Rec.* 139, 455–463.

Goebel, J.A., O'Mara, W., Gianoli, G., 2001. Anatomic considerations in vestibular neuritis. *Otol. Neurotol.* 22 (4), 512–518.

Guan, Q., Zhang, L., Hong, W., Yang, Y.I., Chen, Z., Lu, P., Zhang, D., Hu, X., 2017. Video head impulse test for early diagnosis of vestibular neuritis among acute vertigo. *Can. J. Neurol. Sci.* 44 (5), 556–561.

Hallpike, C., 1949. The pathology and differential diagnosis of aural vertigo. In: *Proceedings of 4th International Congress on Otolaryngology. British Medical Association*, p. 514.

Halmagyi, G.M., Arw, S.T., Karlberg, M., Curthoys, I.S., Todd, M.J., 2002. Inferior vestibular neuritis. *Ann N Y Acad Sci* 956, 306–313.

Himmelein, S., Lindemann, A., Sinicina, I., Horn, A.K.E., Brandt, T., Strupp, M., Hüfner, K., Longnecker, R.M., 2017. Differential involvement during latent herpes simplex virus 1 infection of the superior and inferior divisions of the vestibular ganglia: implications for vestibular neuritis. *J. Virol.* 91 (14).

Hotson, J.R., Baloh, R.W., 1998. Acute vestibular syndrome. *N. Engl. J. Med.* 339 (10), 680–685.

Huppert, D., Strupp, M., Theil, D., Glaser, M., Brandt, T., 2006. Low recurrence rate of vestibular neuritis: a long-term follow-up. *Neurology* 67 (10), 1870–1871.

Jung, J., Suh, M.J., Kim, S.H., 2017. Discrepancies between video head impulse and caloric tests in patients with enlarged vestibular aqueduct. *Laryngoscope* 127 (4), 921–926.

Kassner, S.S., Schöttler, S., Bonaterra, G.A., Stern-Straeter, J., Hormann, K., Kinscherf, R., Gössler, U.R., 2011. Proinflammatory activation of peripheral blood mononuclear cells in patients with vestibular neuritis. *Audiol. Neurootol.* 16 (4), 242–247.

Kattah, J.C., Talkad, A.V., Wang, D.Z., Hsieh, Y.-H., Newman-Toker, D.E., 2009. HINTS to diagnose stroke in the acute vestibular syndrome: three-step bedside oculomotor examination more sensitive than early MRI diffusion-weighted imaging. *Stroke* 40 (11), 3504–3510.

Kim, J.-S., Kim, H.J., 2012. Inferior vestibular neuritis. *J. Neurol.* 259 (8), 1553–1560.

Lee, W.S., Suarez, C., Honrubia, V., Gomez, J., 1990. Morphological aspects of the human vestibular nerve. *Laryngoscope* 100 (7), 756–764.

Lopez, I., Ishiyama, G., Tang, Y., Frank, M., Baloh, R.W., Ishiyama, A., 2005. Estimation of the number of nerve fibers in the human vestibular endorgans using unbiased stereology and immunohistochemistry. *J. Neurosci. Methods* 145 (1–2), 37–46.

Magliulo, G., Gagliardi, S., Appiani, M.C., Iannella, G., Gagliardi, M., 2012. Selective vestibular neurolabyrinthitis of the lateral and superior semicircular canal ampulla and ampullary nerves. *Ann. Otol. Rhinol. Laryngol.* 121 (10), 640–644.

Magliulo, G., Gagliardi, S., Appiani, M.C., Iannella, G., Re, M., 2014. Vestibular neurolabyrinthitis: a follow-up study with cervical and ocular vestibular evoked myogenic potentials and the video head impulse test. *Ann. Otol. Rhinol. Laryngol.* 123 (3), 162–173.

Mahringer, A., Rambold, H.A., 2014. Caloric test and video-head-impulse: a study of vertigo/dizziness patients in a community hospital. *Eur. Arch. Otorhinolaryngol.* 271 (3), 463–472.

Mandala, M., Santoro, G.P., Awrey, J., Nuti, D., 2010. Vestibular neuritis: recurrence and incidence of secondary benign paroxysmal positional vertigo. *Acta Otolaryngol.* 130 (5), 565–567.

Manzari, L., MacDougall, H.G., Burgess, A.M., Curthoys, I.S., 2014. Selective otolith dysfunctions objectively verified. *J. Vestib. Res.* 24 (5–6), 365–373.

McCaslin, D.L., Jacobson, G.P., Bennett, M.L., Gruenewald, J.M., Green, A.P., 2014. Predictive properties of the video head impulse test: measures of caloric symmetry and self-report dizziness handicap. *Ear Hear.* 35 (5), e185–e191.

McGarvie, L.A., Curthoys, I.S., MacDougall, H.G., Halmagyi, G.M., 2015. What does the dissociation between the results of video head impulse versus caloric testing reveal about the vestibular dysfunction in Meniere's disease? *Acta Otolaryngol.* 135 (9), 859–865.

Moriyama, H., Itoh, M., Shimada, K., Otsuka, N., 2007. Morphometric analysis of fibers of the human vestibular nerve: sex differences. *Eur. Arch. Otorhinolaryngol.* 264 (5), 471–475.

Nagai, Y., Goto, N., Goto, J., Kaneko, Y., Suzuki, H., 1999. Morphometric nerve fiber analysis and aging process of the human vestibular nerve. *Okajimas Folia Anat. Jpn.* 76 (2–3), 95–100.

Navari, E., Casani, A.P., 2020. Lesion patterns and possible implications for recovery in acute unilateral vestibulopathy. *Otol. Neurotol.* 41 (2), e250–e255.

Nylen, C.O., 1924. Some cases of ocular nystagmus due to certain positions of the head. *Acta Otolaryngol. (Stockh.)* 6 (1), 106–137.

Ozdogmus, O., Sezen, O., Kubilay, U., Saka, E., Duman, U., San, T., Cavdar, S., 2004. Connections between the facial, vestibular and cochlear nerve bundles within the internal auditory canal. *J. Anat.* 205 (1), 65–75.

Palla, A., Straumann, D., 2004. Recovery of the high-acceleration vestibulo-ocular reflex after vestibular neuritis. *J. Assoc. Res. Otolaryngol.* 5 (4), 427–435.

Park, H.J., Migliaccio, A.A., Della Santina, C.C., Minor, L.B., Carey, J.P., 2005. Search-coil head-thrust and caloric tests in Meniere's disease. *Acta Otolaryngol.* 125 (8), 852–857.

Rambold, H.A., 2015. Economic management of vertigo/dizziness disease in a county hospital: video-head-impulse test vs. caloric irrigation. *Eur. Arch. Otorhinolaryngol.* 272 (10), 2621–2628.

Rasmussen, A.T., 1940. Studies of the VIIIth cranial nerve of man. *Laryngoscope* 50 (1), 67–83.

Redondo-Martínez, J., Bécara-Martínez, C., Orts-Alborch, M., García-Calleja, F.J., Pérez-Carbonell, T., Marco-Algarra, J., 2016. Relationship between video head impulse test (vHIT) and caloric test in patients with vestibular neuritis. *Acta Otorrinolaringol. Esp.* 67 (3), 156–161.

Richard, C., Linthicum Jr., F.H., 2012. Vestibular neuritis: the vertigo disappears, the histological traces remain. *Otol. Neurotol.* 33 (7), e59–e60.

Rubin, F., Simon, F., Verillaud, B., Herman, P., Kania, R., Hautefort, C., 2018. Comparison of video head impulse test and caloric reflex test in advanced unilateral definite Meniere's disease. *Eur. Ann. Otorhinolaryngol. Head Neck Dis.* 135 (3), 167–169.

Schuknecht, H.F., Kitamura, K., 1981. Second Louis H. Clerf Lectur. Vestibular neuritis. *Ann. Otol. Rhinol. Laryngol. Suppl.* 90, 1–19.

- Schuknecht, H.F., Witt, R.L., 1985. Acute bilateral sequential vestibular neuritis. *Am. J. Otolaryngol.* 6 (4), 255–257.
- Silverstein, H., Norrell, H., Haberkamp, T., McDaniel, A.B., 1986. The unrecognized rotation of the vestibular and cochlear nerves from the labyrinth to the brain stem: its implications to surgery of the eighth cranial nerve. *Otolaryngol. Head Neck Surg.* 95 (5), 543–549.
- Solis, R.N., Sun, D.Q., Tatro, E., Hansen, M.R., 2019. Do steroids improve recovery in vestibular neuritis? *Laryngoscope* 129 (2), 288–290.
- Starkov, D., Strupp, M., Pleshkov, M., Kingma, H., van de Berg, R., 2020. Diagnosing vestibular hypofunction: an update. *J. Neurol.* 268 (1), 377–385.
- Strupp, M., Zingler, V.C., Arbusow, V., Niklas, D., Maag, K.P., Dieterich, M., Bense, S., Theil, D., Jahn, K., Brandt, T., 2004. Methylprednisolone, valacyclovir, or the combination for vestibular neuritis. *N. Engl. J. Med.* 351 (4), 354–361.
- Taylor, R.L., McGarvie, L.A., Reid, N., Young, A.S., Halmagyi, G.M., Welgampola, M.S., 2016. Vestibular neuritis affects both superior and inferior vestibular nerves. *Neurology* 87 (16), 1704–1712.
- Voit, M., 1907. Zur Frage der Verästelung des Nervus Acusticus bei den Säugetieren. *Anatomischer Anzeiger* 31, 635–640.
- Wegmann-Vicuña, R., Garaycochea, O., Domínguez-Echavarrí, P., Guajardo-Vergara, C., García-Eulate, R., Pérez-Fernández, N., 2018. Dissociated responses to caloric and head impulse stimulation in a case of isolated vestibule-lateral semicircular canal dysplasia. *Acta Oto-Laryngol. Case Rep.* 3 (1), 5–10.
- Wu, Y., Hu, Z., Cai, M., Fan, Z., Han, W., Guan, Q., et al., 2019. Decreased 25-hydroxyvitamin D levels in patients with vestibular neuritis. *Front. Neurol.* 10, 863.
- Yacovino, D.A., Akly, M.P., Luis, L., Zee, D.S., 2018. The floccular syndrome: dynamic changes in eye movements and vestibulo-ocular reflex in isolated infarction of the cerebellar flocculus. *Cerebellum* 17 (2), 122–131.
- Yacovino, D.A., Finlay, J.B., Urbina Jaimes, V.N., Verdecchia, D.H., Schubert, M.C., 2018. Acute bilateral superior branch vestibular neuropathy. *Front. Neurol.* 9, 353.
- Yagi, T., Koizumi, Y., Sugizaki, K., 2010. 3D analysis of spontaneous nystagmus in early stage of vestibular neuritis. *Auris Nasus Larynx* 37 (2), 167–172.
- Yoo, M.H., Kim, S.H., Lee, J.Y., Yang, C.J., Lee, H.S., Park, H.J., 2016. Results of video head impulse and caloric tests in 36 patients with vestibular migraine and 23 patients with vestibular neuritis: a preliminary report. *Clin. Otolaryngol.* 41 (6), 813–817.
- Young, A.S., Taylor, R.L., McGarvie, L.A., Halmagyi, G.M., Welgampola, M.S., 2016. Bilateral sequential peripheral vestibulopathy. *Neurology* 86 (15), 1454–1456.
- Zellhuber, S., Mahringer, A., Rambold, H.A., 2014. Relation of video-head-impulse test and caloric irrigation: a study on the recovery in unilateral vestibular neuritis. *Eur. Arch. Otorhinolaryngol.* 271 (9), 2375–2383.