

## To grow or not to grow, That is the question

Tamara Kliot, Yavuz Ince<sup>1</sup>, Tarik Tihan<sup>1</sup>, Michael Wilson<sup>2</sup>, Michel Kliot<sup>3</sup>

Teach for America, Chalmette High School, Chalmette, LA, <sup>1</sup>Departments of Pathology, <sup>2</sup>Neurology and <sup>3</sup>Neurological Surgery, University of California, San Francisco, CA, USA

E-mail: Tamara Kliot - [tamara.kliot@istandabove.org](mailto:tamara.kliot@istandabove.org); Yavuz Ince - [hince@ku.edu.tr](mailto:hince@ku.edu.tr); Tarik Tihan - [Tarik.Tihan@ucsf.edu](mailto:Tarik.Tihan@ucsf.edu);

Michael Wilson - [MichaelR.Wilson@ucsf.edu](mailto:MichaelR.Wilson@ucsf.edu); \*Michel Kliot - [KliotM@neurosurg.ucsf.edu](mailto:KliotM@neurosurg.ucsf.edu)

\*Corresponding author

Received: 29 August 13 Accepted: 02 October 13 Published: 31 October 13

### This article may be cited as:

Kliot T, Ince Y, Tihan T, Wilson M, Kliot M. To grow or not to grow, That is the question. *Surg Neurol Int* 2013;4:S407-10.

Available FREE in open access from: <http://www.surgicalneurologyint.com/text.asp?2013/4/2/407/120882>

Copyright: © 2013 Kliot T. This is an open-access article distributed under the terms of the Creative Commons Attribution License, which permits unrestricted use, distribution, and reproduction in any medium, provided the original author and source are credited.

**Key Words:** Grow, neurofibroma, neoplasm, static, tumor

## EDITORIAL COMMENTS

The following article is the first to appear in a new section of New Horizons in SNI called, “Thinking Outside the Box”. The goal of this new section is to take an interesting, but as of yet unexplained neurosurgically relevant observations with important clinical implications, and propose a plausible and testable mechanistic hypothesis. In this case, the interesting observation is that many if not most neurofibromas stop growing for long periods of time. The clinically important implication is that if we can understand the molecular mechanisms that retard or arrest neurofibroma growth, then we can: 1) convert growing tumors into non-growing or static tumors, and 2)

have the option of performing a biopsy to predict which ones will likely grow and need a surgical resection, and which ones will remain static and can be observed. The mechanistic and testable hypothesis presented here is that many neurofibromas activate senescence pathways that eventually slow and even stop their growth for long periods of time. It is our hope that this section will provide a platform for physicians to voice new ideas, some of which may one day culminate in novel approaches to treat and even cure currently vexing clinical problems.

Michel Kliot, MD

## INTERESTING CLINICAL OBSERVATIONS ON THE VARIABLE GROWTH OF TUMORS IN PATIENTS WITH NEUROFIBROMATOSIS-I

Neoplasms represent uncontrolled growth of cells, and usually come to clinical attention because of the symptoms and/or clinical signs they elicit. A growing number of studies examining the natural history of neoplasms show that particular types can exhibit highly variable growth patterns.<sup>[18]</sup> Some neoplasms continue to grow and become malignant, while others spontaneously stop growing or even regress. As imaging

and screening protocols have become more widespread and sophisticated, asymptomatic/incidental neoplasms are increasingly being found.<sup>[21]</sup> Recent evidence, including autopsy series or imaging studies, reveal the existence

### Access this article online

#### Quick Response Code:



Website:  
[www.surgicalneurologyint.com](http://www.surgicalneurologyint.com)

DOI:  
10.4103/2152-7806.120882

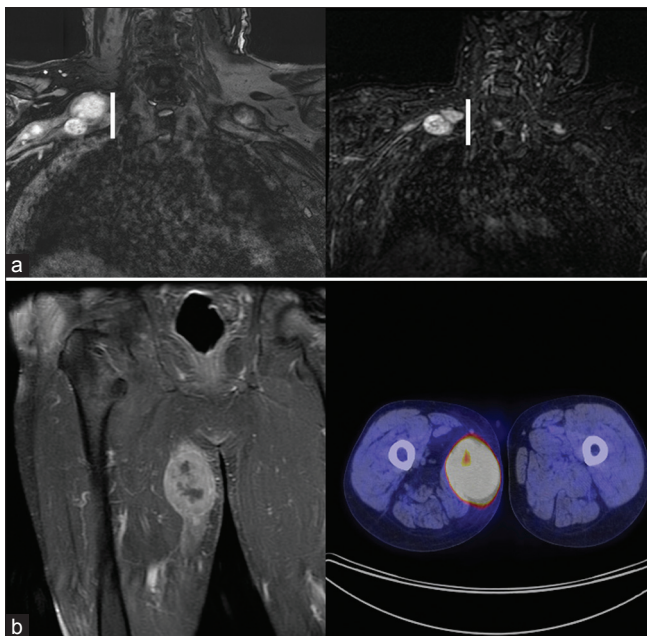
of much larger number of tumors than those that come to clinical attention.<sup>[10]</sup> As a consequence, screening studies for tumors are now grappling with the challenge of determining the risks and benefits of treating early detected asymptomatic masses surgically and/or medically. It is also becoming clear that the risks of treating a tumor ought to be weighed against its natural history, and such incidental neoplasms may behave more differently than symptomatic ones. This dilemma was shown by a recent clinical trial in which male patients with localized prostate cancer randomized to undergo either radical surgical resection or medical observation were shown to have no difference in all-cause mortality over a 12 year period.<sup>[26]</sup>

An excellent example of variable tumor growth is exhibited by patients with Neurofibromatosis-1 (NF1). NF1 is one of the more common familial tumor syndromes with a prevalence of approximately 1 in 3500.<sup>[9]</sup> NF1 is caused by a germline mutation of this gene on chromosome 17q11.2 that encodes for a large cytoplasmic protein called neurofibromin,<sup>[12]</sup> a GTPase activating protein. It has an autosomal dominant pattern of inheritance, and both alleles have to be mutated for tumorigenesis consistent with its tumor suppressor role. Thus although every cell has the same germline mutation in one of the NF1 genes, a second hit of the other NF1 gene occurs sporadically and leads to the development

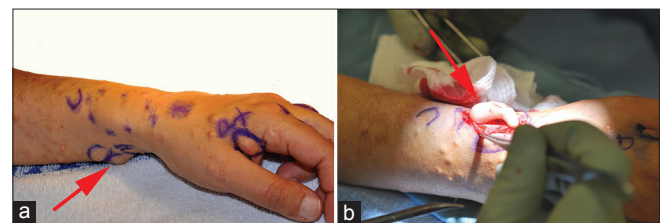
of a neurofibroma. This process is very different from metastatic tumors where the original tumor gives rise to satellite tumors. While the penetrance of NF1 approaches 100% by age 20, the severity of the disease is highly variable even among family members with the same germline mutation.<sup>[20]</sup> A hallmark of NF1 is the presence of multiple neurofibromas and/or at least one plexiform neurofibroma, in association with other neoplastic and non-neoplastic lesions such as optic gliomas,<sup>[13,14]</sup> skeletal dysplasias,<sup>[7]</sup> cardiovascular abnormalities,<sup>[8]</sup> and neurocognitive deficits.<sup>[19]</sup> Neurofibromas are neoplasms of cranial and peripheral nerves<sup>[6]</sup> consisting of a mixture of cell types including Schwann cells. Neurofibromas often exhibit variable growth patterns among patients and even in the same patient<sup>[18]</sup> Malignant transformation of neurofibromas has been reported to occur at a rate of approximately 2% in NF1 patients.<sup>[25]</sup>

Clinical experience may generate a bias in the surgeon's view of tumors since most patients who come to surgical clinics have masses that are growing and/or symptomatic. Over the past 5 years, one of the authors with a peripheral nerve clinical practice (MK) has operated on over 140 patients with peripheral nerve neoplasms that are either symptomatic and/or growing. He is also following an even greater number of patients with peripheral nerve neoplasms that are minimally symptomatic or not growing.

The mechanisms proposed in this manuscript were prompted by the observation of many examples of neurofibromas that have not grown over many years. One such patient had multiple right brachial plexus neurofibromas with highly variable growth patterns over a 3 year period, during which some tumors enlarged, some became smaller, and some stayed the same size while one neurofibroma in his thigh became malignant [Figure 1]. Another example of variable neurofibroma growth is that of a 37 year-old female with NF1 who had numerous growing and non-growing neurofibromas, She elected to have eleven of the non-growing as well three of the growing neurofibromas surgically resected in her forearms and hands on both sides to reduce her pain and improve her upper extremity function [Figure 2]. The



**Figure 1: (a)** Middle age man with multiple neurofibromas in his right and left brachial plexus showing variable patterns of growth over a 3 year period including enlargement, stasis, and reduction in size (right panel MRN done 3 years after left panel MRN). **(b)** A tumor in his right medial thigh developed at the later time point and is visualized on a MRN (left panel) as well as PET CT study (right panel) which showed high metabolic activity consistent with a malignant neurofibroma, a diagnosis confirmed by surgical pathology



**Figure 2: (a)** 37 year old woman with NF1 who underwent resection of fourteen neurofibromas with variable growth patterns, 11 were tender but had not grown for several years, and three progressively grew. **(b)** An intraoperative image showing one neurofibroma as it is being removed. Red Arrows point to neurofibroma being removed

histological appearance of these growing and non-growing neurofibromas was nearly identical.

## MOLECULAR MECHANISMS MEDIATING TUMORIGENESIS IN NF1

While it is important to recognize the neoplasms that have a propensity for progression, we believe it is equally important to understand why the overwhelming majority of neoplasms remain dormant in the setting of NF1. A few mechanistic possibilities can be proposed, and some of these are discussed briefly.

Neurofibromin down-regulates Ras, a key intracellular signaling protein for promoting cell growth and survival.<sup>[15,27]</sup> Loss of neurofibromin and unopposed Ras activity has been shown to lead to the activation of the mammalian target of rapamycin (mTOR),<sup>[24]</sup> mitogen-activated protein kinase (MAPK) pathways,<sup>[23]</sup> and increased cell growth.<sup>[28]</sup> However, loss of neurofibromin in Schwann cells is thought to be insufficient for neoplastic growth and likely requires additional genetic or epigenetic events.<sup>[29]</sup> This suggests that Schwann cells likely initiate but are insufficient to cause neoplastic transformation. Such observations suggest that the consequences of Ras activation depends on the cell type, context and development stage, and in certain circumstances an intact growth arrest and senescence response.<sup>[22]</sup> A more comprehensive review on this can be found in Zhu *et al.*<sup>[29]</sup>

## HYPOTHESIS: THE POSSIBLE ROLE OF SENESCENT PATHWAYS IN ARRESTING THE GROWTH OF NEUROFIBROMAS

The fundamental mechanisms of the disparate growth patterns of neurofibromas in NF1 are unclear, and recent studies have pointed to a number of possible explanations especially oncogene induced senescence which is a barrier to cellular proliferation.<sup>[16]</sup> In 1997, Serrano *et al.* reported that activated Ras induces the accumulation of p53, p16, and ARF and triggers cellular senescence in primary cultures.<sup>[22]</sup> Additionally, recent studies have further demonstrated that Ras, Raf, and PTEN mutations trigger oncogene induced senescence in human tumors and in mouse tumor models.<sup>[1,3,4,17]</sup> Courtois-Cox *et al.* found that mutations affecting NF1, Raf, and Ras induce a global negative feedback response that potently suppresses Ras and/or its effectors; moreover, these signals promote senescence by inhibiting the Ras/PI3K pathway, which can impact the senescence machinery through HDM2 and FOXO.<sup>[5]</sup> This negative feedback program is regulated in part by RasGEFs, Sprouty proteins, RasGAPs, and MKPs.<sup>[5]</sup> Holtkamp *et al.* showed that Sprouty gene is downregulated in malignancies associated with NF1 as compared to neurofibromas.<sup>[11]</sup>

and the Sprouty-related gene SPRED 1 has recently been reported to be genetically inactivated in a syndrome with features similar to NF1.<sup>[2]</sup> These and many other recent studies suggest that in addition to abrogation of the neurofibromin function, the tumors require disruption of the senescence pathways for growth and malignant transformation.

## CONCLUSION

Neurofibromas are both common and have extremely variable rates of growth ranging from growth arrest and even regression to slow growth or even malignant transformation with metastatic spread. All these tumor phenotypes can exist in a single patient. The important question of why most neurofibromas remain dormant for decades can lead us to the discovery of critical pathways that keep these tumors in check. Recognition of the critical importance of an intact system that favors senescence in Ras activated tumors allows us to consider a number of important points. First, such tumors are likely to escape senescence if other mutagenic events inactivate cell-cycle check points such as p16 or p53.<sup>[22]</sup> One cannot imagine a better mutagen than those given for adjuvant therapy in the clinic such as radiation and chemotherapy, which should lead us to question when it is most appropriate to use such modalities in slow growing or non-growing neurofibromas. Second, if it is possible to identify which tumors can undergo senescence and growth arrest, it may be possible to recognize which masses do not require surgical intervention, thereby avoiding potentially significant surgical morbidity. It is quite possible that a multitude of genetic or epigenetic aberrations can abrogate senescence, but it will be critical to understand what should remain intact to keep the Ras activation in the senescent, non-growing mode. We plan to study growing and non-growing neurofibromas in the same patient where the NF1 germline mutation is the same in all cells. The second NF1 mutation that occurs sporadically leads to neurofibroma formation with cellular proliferation that in the majority of cases is arrested. This model offers us the unique and powerful opportunity to test whether these specific molecular mechanisms mediating cellular senescence are responsible for the different phenotypic growth behaviors exhibited by neurofibromas. It is an important biological and clinical question that can be defined by a modified version of a famous William Shakespeare quote: To Grow Or Not To Grow, That Is The Question.

## REFERENCES

1. Braig M, Lee S, Loddenkemper C, Rudolph C, Peters AH, Schlegelberger B, *et al.* Oncogene-induced senescence as an initial barrier in lymphoma development. *Nature* 2005;436:660-5.
2. Brems H, Chmara M, Sahbatou M, Denayer E, Taniguchi K, Kato R, *et al.* Germline loss-of-function mutations in SPRED1 cause a neurofibromatosis 1-like phenotype. *Nat Genet* 2007;39:1120-6.

3. Chen Z, Trotman LC, Shaffer D, Lin HK, Dotan ZA, Niki M, et al. Crucial role of p53-dependent cellular senescence in suppression of Pten-deficient tumorigenesis. *Nature* 2005;436:725-30.
4. Collado M, Gil J, Efeyan A, Guerra C, Schuhmacher AJ, Barradas M, et al. Tumour biology: Senescence in premalignant tumours. *Nature* 2005;436:642.
5. Courtois-Cox S, Genter Williams SM, Reczek EE, Johnson BW, McGillicuddy LT, Johannessen CM, et al. A negative feedback signaling network underlies oncogene-induced senescence. *Cancer Cell* 2006;10:459-72.
6. Dolecek TA, Propp JM, Stroup NE, Kruchko C. CBTRUS statistical report: Primary brain and central nervous system tumors diagnosed in the United States in 2005-2009. *Neuro Oncol* 2012;14 Suppl 5:v1-49.
7. Friedman JM. Neurofibromatosis I: Clinical manifestations and diagnostic criteria. *J Child Neurol* 2002;17:548-54.
8. Friedman JM, Arbiser J, Epstein JA, Gutmann DH, Huot SJ, Lin AE, et al. Cardiovascular disease in neurofibromatosis I: Report of the NFI Cardiovascular Task Force. *Genet Med* 2002;4:105-11.
9. Gottfried ON, Viskochil DH, Fults DW, Couldwell WT. Molecular, genetic, and cellular pathogenesis of neurofibromas and surgical implications. *Neurosurgery* 2006;58:1-16.
10. Hegenscheid K, Seipel R, Schmidt CO, Volzke H, Kuhn JP, Biffar R, et al. Potentially relevant incidental findings on research whole-body MRI in the general adult population: Frequencies and management. *Eur Radiol* 2013;23:816-26.
11. Holtkamp N, Mautner VF, Friedrich RE, Harder A, Hartmann C, Theallier-Janko A, et al. Differentially expressed genes in neurofibromatosis I-associated neurofibromas and malignant peripheral nerve sheath tumors. *Acta Neuropathol* 2004;107:159-68.
12. Li Y, O'Connell P, Breidenbach HH, Cawthon R, Stevens J, Xu G, et al. Genomic organization of the neurofibromatosis I gene (NF1). *Genomics* 1995;25:9-18.
13. Listernick R, Charrow J, Greenwald M, Mets M. Natural history of optic pathway tumors in children with neurofibromatosis type I: A longitudinal study. *J Pediatr* 1994;125:63-6.
14. Listernick R, Charrow J, Greenwald MJ, Esterly NB. Optic gliomas in children with neurofibromatosis type I. *J Pediatr* 1989;114:788-92.
15. Martin GA, Viskochil D, Bollag G, McCabe PC, Crosier WJ, Haubruck H, et al. The GAP-related domain of the neurofibromatosis type I gene product interacts with ras p21. *Cell* 1990;63:843-9.
16. Mathon NF, Lloyd AC. Cell senescence and cancer. *Nat Rev Cancer* 2001;1:203-13.
17. Michaloglou C, Vredeveld LC, Soengas MS, Denoyelle C, Kuilman T, van der Horst CM, et al. BRAF600-associated senescence-like cell cycle arrest of human naevi. *Nature* 2005;436:720-4.
18. Nguyen R, Dombi E, Widemann BC, Solomon J, Fuensterer C, Kluwe L, et al. Growth dynamics of plexiform neurofibromas: A retrospective cohort study of 201 patients with neurofibromatosis I. *Orphanet J Rare Dis* 2012;7:75.
19. Ozonoff S. Cognitive impairment in neurofibromatosis type I. *Am J Med Genet* 1999;89:45-52.
20. Riccardi VM, Lewis RA. Penetrance of von Recklinghausen neurofibromatosis: A distinction between predecessors and descendants. *Am J Hum Genet* 1988;42:284-9.
21. Roth J, Keating RF, Myseros JS, Yaun AL, Magge SN, Constantini S. Pediatric incidental brain tumors: A growing treatment dilemma. *J Neurosurg Pediatr* 2012;10:168-74.
22. Serrano M, Lin AW, McCurrach ME, Beach D, Lowe SW. Oncogenic ras provokes premature cell senescence associated with accumulation of p53 and p16INK4a. *Cell* 1997;88:593-602.
23. Sharma R, Wu X, Rhodes SD, Chen S, He Y, Yuan J, et al. *Hum Mol Genet* 2013. [Epub ahead of print].
24. Shaw RJ, Cantley LC. Ras, PI (3) K and mTOR signalling controls tumour cell growth. *Nature* 2006;441:424-30.
25. Sørensen SA, Mulvihill JJ, Nielsen A. Long-term follow-up of von Recklinghausen neurofibromatosis. Survival and malignant neoplasms. *N Engl J Med* 1986;314:1010-5.
26. Wilt TJ, Brawer MK, Barry MJ, Jones KM, Kwon Y, Gingrich JR, et al. The Prostate Cancer Intervention Versus Observation Trial: VA/NCI/AHRQ Cooperative Studies Program #407 (PIVOT): Design and baseline results of a randomized controlled trial comparing radical prostatectomy to watchful waiting for men with clinically localized prostate cancer. *Contemp Clin Trials* 2009;30:81-7.
27. Xu GF, Lin B, Tanaka K, Dunn D, Wood D, Gesteland R, et al. The catalytic domain of the neurofibromatosis type I gene product stimulates ras GTPase and complements ira mutants of *S. cerevisiae*. *Cell* 1990;63:835-41.
28. Yunoue S, Tokuo H, Fukunaga K, Feng L, Ozawa T, Nishi T, et al. Neurofibromatosis type I tumor suppressor neurofibromin regulates neuronal differentiation via its GTPase-activating protein function toward Ras. *J Biol Chem* 2003;278:26958-69.
29. Zhu Y, Parada LF. Neurofibromin, a tumor suppressor in the nervous system. *Exp Cell Res* 2001;264:19-28.