

Research article

## Tetramethylpyrazine attenuates spinal cord ischemic injury due to aortic cross-clamping in rabbits

Shaoyang Chen\*, Lize Xiong, Qiang Wang, Hanfei Sang, Zhenhua Zhu, Hailong Dong and Zhihong Lu

Address: Department of Anesthesiology, Xijing Hospital, Fourth Military Medical University, Xi'an ShaanXi, 710032, China

E-mail: Shaoyang Chen\* - chensy@fmmu.edu.cn; Lize Xiong - lxiong@fmmu.edu.cn; Qiang Wang - wangqg@pub.xaonlne.com; Hanfei Sang - sanghf@fmmu.edu.cn; Zhenhua Zhu - zhuzh@fmmu.edu.cn; Hailong Dong - donghl@fmmu.edu.cn; Zhihong Lu - luzh@fmmu.edu.cn

\*Corresponding author

Published: 17 April 2002

BMC Neurology 2002, 2:1

Received: 8 December 2001

Accepted: 17 April 2002

This article is available from: <http://www.biomedcentral.com/1471-2377/2/1>

© 2002 Chen et al; licensee BioMed Central Ltd. Verbatim copying and redistribution of this article are permitted in any medium for any purpose, provided this notice is preserved along with the article's original URL.

### Abstract

**Background:** Lower limb paralysis occurs in 11% of patients after surgical procedure of thoracic or thoracoabdominal aneurysms and is an unpredictable and distressful complication. The aim of this study was to investigate the effects of tetramethylpyrazine (TMP), an intravenous drug made from traditional Chinese herbs, on the neurologic outcome and histopathology after transient spinal cord ischemia in rabbits.

**Methods:** Forty-five male New Zealand white rabbits were anesthetized with isoflurane and spinal cord ischemia was induced for 20 min by infrarenal aortic occlusion. Animals were randomly allocated to one of five groups (n = 8 each). Group C received no pharmacologic intervention. Group P received intravenous infusion of 30 mg·kg<sup>-1</sup> TMP within 30 min before aortic occlusion. Group T<sub>1</sub>, Group T<sub>2</sub> and Group T<sub>3</sub> received intravenous infusion of 15, 30 and 60 mg·kg<sup>-1</sup> TMP respectively within 30 min after reperfusion. In the sham group (n = 5), the animals underwent the same procedures as the control group except infrarenal aortic unocclusion. Neurologic status was scored by using the Tarlov criteria (in which 4 is normal and 0 is paraplegia) at 4 h, 8 h, 12 h, 24 h, and 48 h after reperfusion. All animals were sacrificed at 48 h after reperfusion and the spinal cords (L<sub>5</sub>) were removed immediately for histopathologic study.

**Results:** All animals in the control group became paraplegic. Neurologic status and histopathology (48 h) in the Groups P, T<sub>2</sub> and T<sub>3</sub> were significantly better than those in the control group (P < 0.05). There was a strong correlation between the final neurologic scores and the number of normal neurons in the anterior spinal cord (r = 0.776, P < 0.01).

**Conclusion:** Tetramethylpyrazine significantly reduces neurologic injury related to spinal cord ischemia and reperfusion after aortic occlusion within a certain range of dose.

### Background

Spinal cord ischemic injury remains a devastating and un-

predictable complication, which develops paralysis or paraplegia in proximately 11~40% of patients undergoing

descending thoracic or thoracoabdominal aneurysm repair [1,2]. Therefore, a great number of efforts have been focused on solving this problem, which include surgical techniques, pharmacologic intervention and mechanical methods, used such as hypothermia, cerebrospinal fluid drainage, and retrograde venous perfusion [3–6]. The cellular and molecular mechanisms of ischemic spinal cord injury are not fully understood. But multiple studies have suggested that calcium overload, free radical production, platelet aggregation, neutrophil accumulation and adhesion following ischemia may contribute to neuronal ischemic spinal cord injury [4,8]. Pharmacologic studies have demonstrated tetramethylpyrazine (TMP), an intravenous drug made from traditional Chinese herbs, was able to inhibit release of intracellular calcium and to scavenge oxygen free radicals [9,10]. The significant efficacy of TMP in cerebral ischemia and reperfusion injury was confirmed [11,12]. However, no study has been designed to examine its use in spinal cord ischemia. This study was designed to investigate the protective efficacy and the dose-response relationship of TMP against the neurologic and histopathologic outcomes of spinal cord ischemia and reperfusion injury relating to aortic occlusion in rabbits.

## Materials and Methods

### Experimental Groups

Forty-five male New Zealand White rabbits (provided by Experimental Animal Center of the Fourth Military Medical University), weighing 1.8 to 2.6 kg, were randomly assigned to one of six groups ( $n = 8$  each). In the control group, the animals underwent infrarenal aortic occlusion and intravenous infusion of 0.9% sodium chloride (volume was identical to those of TMP infusion). In protection group (Group P), the animals received  $30 \text{ mg} \cdot \text{kg}^{-1}$  TMP within 30 min before aortic occlusion. In treatment groups  $T_1$ ,  $T_2$  and  $T_3$ , the animals received 15, 30 and  $60 \text{ mg} \cdot \text{kg}^{-1}$  TMP respectively at the onset of reperfusion. In the sham group ( $n = 5$ ), the animals underwent the same procedures as control group except infrarenal aortic occlusion. The TMP (Changzhou Pharmacological Co., China, NO: 990129), diluted in 10 ml of 0.9% sodium chloride, was intravenously infused at a rate of  $20 \text{ ml} \cdot \text{h}^{-1}$  by using microinjector (3 M, Model 600, USA).

### Spinal Cord Ischemia

The spinal cord ischemia was induced based on the method previously described by Wakamatsu et al [5]. After an overnight fast with unrestricted access to water, the rabbits were induced in plastic box with 4% isoflurane in oxygen. Animals were allowed to breathe spontaneously. Anesthesia was maintained by inhalation of 2%~3% isoflurane in oxygen administered by face mask at a flow rate of  $4 \text{ l} \cdot \text{min}^{-1}$ . The left ear vein was cannulated with a 24-gauge catheter for the infusion of lactated Ringer's solution and

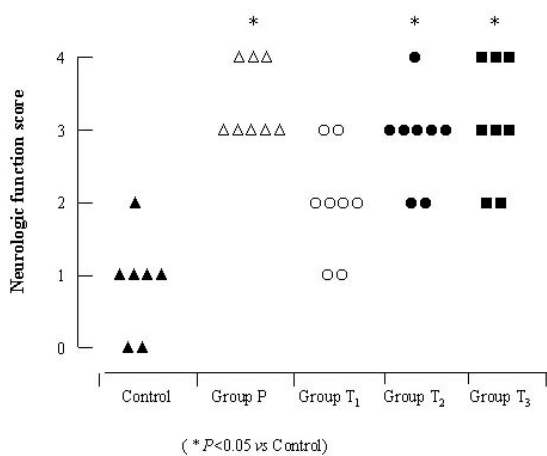
TMP, the right ear artery was cannulated with a 24-gauge catheter for the measurement of proximal arterial blood pressure and for drawing blood samples. The distal arterial blood pressure was measured via a 24-gauge catheter inserted into the right femoral artery. With the rabbits in the prone position, the abdomen was opened through a vertical midline incision to expose the abdominal aorta. The aorta and its branches were meticulously dissected from caudal to the left renal artery. Heparin ( $150 \text{ U} \cdot \text{kg}^{-1}$ ) was given and intravenously a circum-aortic occlusion device was placed across the aorta just distal to the left renal artery to occlude blood supply to the lumbar spinal cord. Spinal cord ischemia was induced by pulling the device. After a previously established ideal ischemic time of precisely 20 minutes, the device was removed, thus beginning reperfusion. After completion of surgery, the aorta was detected to be intact, and the abdominal wall was closed with 4-0 nylon suture in separate layers. The local infiltration around the wound with 0.25% bupivacaine hydrochloride was applied for postoperative analgesia. The animals were administered gentamicin ( $40,000 \text{ U}$ ) i.m., and allowed to recover with free access to food and water. During the procedure, lactated Ringer's solution was infused via ear vein. Proximal and distal arterial blood pressure and heart beat were continuously monitored (Spacelab, model 90206A, USA), body temperature was continuously monitored with a flexible probe (509 Monitor, USA) inserted 5 cm into the rectum and core temperature was maintained at  $38 \sim 39^\circ\text{C}$  by heating lamps. Arterial blood was sampled for determination of blood gases (AVL-2, Switzerland) and plasma glucose (One Touch II, USA) at 20 minutes before ischemia, 10 minutes after ischemia and 20 minutes after reperfusion respectively.

### Neurologic Assessment

At 4 h, 8 h, 12 h, 24 h, and 48 h after perfusion, the motor function scores (MFS) were scaled in all rabbits by an observer unaware of the treatment group using the modified Tarlov criteria [13] as follows: 0: paraplegic with no lower extremity function; 1: poor lower extremity function, weak antigravity movement only; 2: some lower extremity function with good antigravity strength but inability to draw legs under body; 3: ability to draw under body and hop, but not normally; 4: normal motor function.

### Histopathologic examination

After completion of the MFS at 48 h, the animals were re-anesthetized with 2% sodium pentobarbital, and transcardial perfusion and fixation were performed with 1000 mL of heparinized saline followed by 500 mL 10% phosphate-buffered formalin. The spinal cord was removed and refrigerated in 10% phosphate-buffered formalin for 48 h, then was embedded in paraffin. Coronal section of the spinal cord ( $L_5$  level) was cut at the thickness of  $6 \mu\text{m}$



**Figure 1**  
The neurologic outcomes 48 h after reperfusion

and stained with hematoxylin and eosin. Neuronal injury was evaluated at 200 × magnification by an observer unaware of the treatment group.

**Statistical Analysis**

Values are expressed as mean ± SD. The physiologic variables were analyzed with repeated measures analysis of variance (ANOVA). The hindlimb motor function and the number of normal neurons in the anterior spinal cord were analyzed using a nonparametric method (Kruskal-Wallis test) followed by the Mann-Whitney U-test with Bonferroni correction. The correlation of hindlimb motor function scores and the number of normal neurons in the anterior spinal cord were analyzed using Spearman's rank correlation. A P value < 0.05 was considered statistically significant.

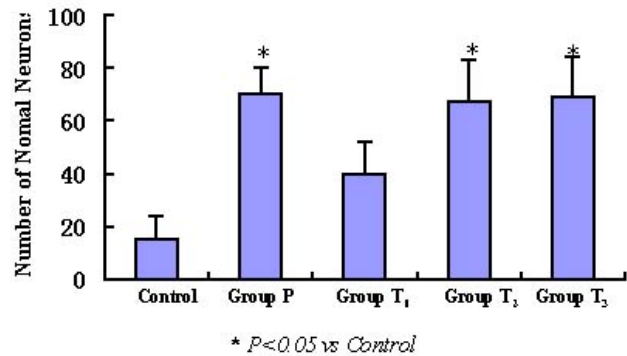
**Results**

**Physiologic and hemodynamic parameters**

Physiologic variables are shown in Table 1 (see additional file 1). Rectal temperature, heart rate, and mean arterial blood pressure were not affected by the slow infusion of TMP. There were no statistical differences in the physiologic parameters of the animals among the five groups. PaO<sub>2</sub>, PaCO<sub>2</sub> and arterial oxygen saturation were within normal range in all animals.

**Neurologic outcomes**

The animals in the sham group had normal motor function during study. The MFS at 4 h, 8 h, 12 h, 24 h, and 48 h in the groups P, T<sub>2</sub> and T<sub>3</sub> received intervention of TMP 30 mg · kg<sup>-1</sup>(P), 30 mg · kg<sup>-1</sup>(T<sub>2</sub>), and 60 mg · kg<sup>-1</sup> (T<sub>3</sub>) was significantly better than that in the control group (P < 0.05). There was no significant difference in the MFS



**Figure 2**  
The number of normal motor neurons in the anterior spinal cord 48 h after reperfusion

among groups P, T<sub>2</sub> and T<sub>3</sub>. At 48 h after reperfusion, all rabbits in the control group showed paralysis of the hind limbs with median Tarlov score of 0. Except for one rabbit in group T<sub>2</sub>, all animals improved to scores of 3 or 4 in groups P, T<sub>2</sub> and T<sub>3</sub> (Figure 1).

**Histopathologic examination**

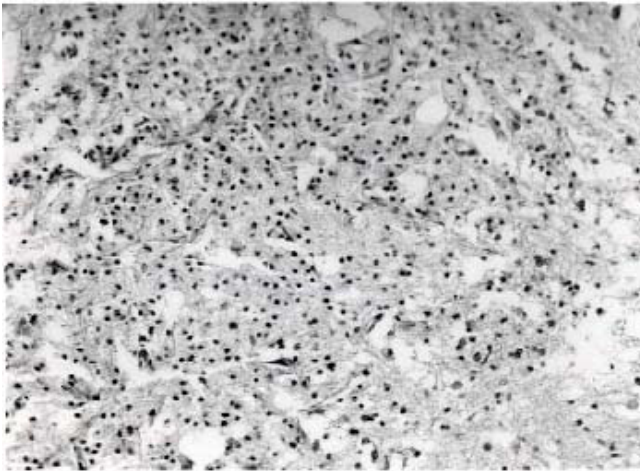
Histopathology of the lumbar spinal cord (L<sub>5</sub>) was examined in all animals. The numbers of normal neurons in the anterior spinal cord at 48 h after reperfusion of groups P, T<sub>2</sub>, and T<sub>3</sub> were significantly greater than that of control group (P < 0.05). No difference was found among groups P, T<sub>2</sub> and T<sub>3</sub> (Figure 2). The morphologic changes were observed in rabbits with different MFS. Figure 3 shows that light microphotographs of anterior horn of the spinal cord from the rabbit in control group with paraplegia (Tarlov grade 0), exhibited few normal neurons, and destruction of the motor neurons with karyolysis and vacuolization of anterior horn. No sign of neuronal damage was observed in the spinal cord of rabbit in group T<sub>3</sub> with normal motor function (Tarlov score 4). Well-preserved, normal-looking motor neurons were seen in figure 4. Figure 5 shows that cross-section of anterior horn of the spinal cord from the rabbit rated Tarlov score 2 in group T<sub>1</sub>, exhibited moderate motor neuronal degeneration with shrunken and triangular shaped perikaryon.

**Correlation between motor function scores and the numbers of normal neurons at anterior spinal cord**

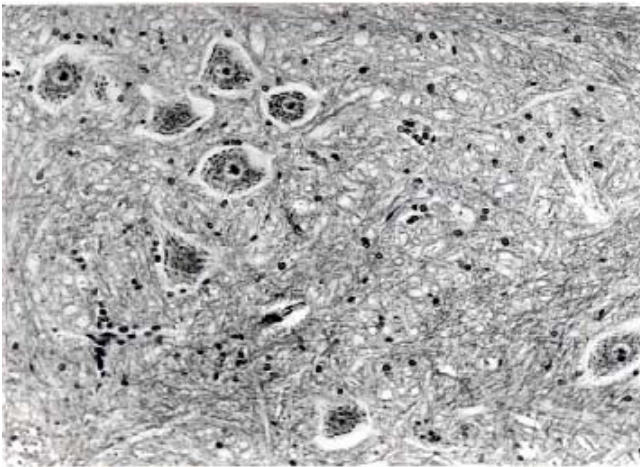
There was a strong correlation between the final neurologic outcome and the numbers of normal neurons in anterior spinal cord 48 h after reperfusion (r = 0.776, P < 0.01).

**Discussion**

The present study demonstrated that TMP by intravenous administration before or after aortic occlusion significantly ameliorates transient spinal cord ischemia (20 min)



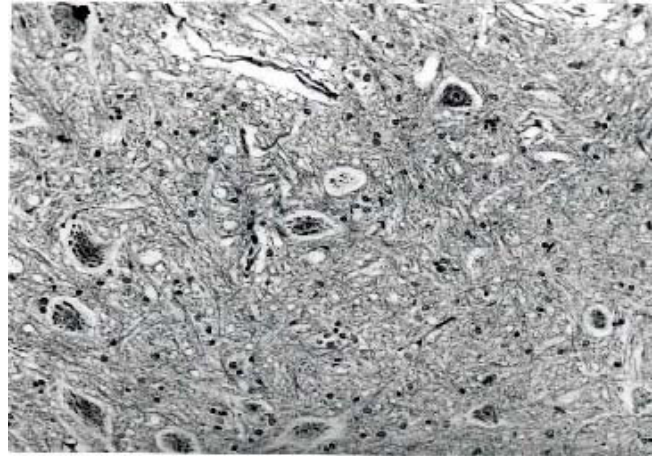
**Figure 3**  
Cross-section of anterior horn spinal cord taken from in control group with paraplegia at 48 h after reperfusion



**Figure 4**  
Cross-section of anterior horn spinal cord taken from in group T<sub>3</sub> with neurologically normal at 48 h after reperfusion

produced by occlusion of the infrarenal aorta in rabbits. No obvious dose-response effect was observed within the dose range studied in the present study.

Partial to complete paralysis during the early postoperative period is an unfortunate and unpredictable consequence of operation on the descending thoracic or thoracoabdominal aorta or direct spinal cord surgery for tumors. Neurologic deficits may be noted during the immediate postoperative period or may be manifested many hours after operation, which severely influences surgical outcome, and leads to massive psychological and financial burden. Multiple studies [3–6] have been done to ex-



**Figure 5**  
Cross-section of anterior horn spinal cord taken from in group T<sub>1</sub> rated Tarlov score 2 at 48 h after reperfusion

amine the effects of various pharmacologic agents on spinal cord ischemia, but no clinically effective treatments have yet been developed. TMP, one of the alkaloids in *Ligusticum Wallichii* Franch (*L. Wallichii*), an active ingredient in Chuanxiong, has been widely used, especially in the treatment of patients with cerebrovascular ischemic diseases in China and manifested its therapeutic actions in clinic [14,15]. TMP has been demonstrated to provide significant protective properties against acute brain ischemic injury induced by ligation of bilateral common carotid arteries (2VO) in gerbils and cerebral infarction produced by middle cerebral artery occlusion (MCAO) in rats in experimental studies [11,12], but limited data exist regarding the use of TMP in spinal cord injury. The rabbit model of spinal cord ischemia used in this study, which mimics aortic occlusion during operation on the thoracoabdominal aorta in clinic, is a reliable and reproducible model for producing neurologic deficit and testing drugs that might serve to protect the spinal cord from ischemic injury [16].

There was significant improvement in the neurologic outcomes of rabbits that received TMP comparing with the control group. Both protective group and treated group with the same dose of TMP had higher Tarlov scores than that in the control animals. Animals treated with TMP before aortic occlusion had 100% recovery at 48 h. These animals were able to stand without difficulty and hop normally. Except for one rabbit treated with TMP at the onset of reperfusion, other animals reached a median Tarlov score of 3 after 48 h with standing or hopping. In contrast, control animals showed paralysis of the hind limbs. It was confirmed in present study that the motor function scores at different time points and the number of normal neurons in the anterior spinal cord at 48 h in the two

groups received treatment of TMP 30 and 60 mg · kg<sup>-1</sup> after reperfusion were significantly better and greater respectively than those in the control group. Animals treated with 15 mg · kg<sup>-1</sup> TMP did not show any neurologic and histopathologic improvements, indicating a enough dose of TMP is needed to have therapeutic effect on spinal cord ischemic injury. These results are not consistent with a recent study [12] examining the protective effects of TMP on cerebral infarction produced by middle cerebral artery occlusion (MCAO) in rats. Cen et al [12] demonstrated that TMP 10, 20, 40 mg · kg<sup>-1</sup> given intravenously markedly improved the abnormal nervous symptoms in rats, significantly reduced the infarct volume at 24 h after MCAO, and presented a certain dose-response relation. This study showed that lower dosage of TMP produced inadequate protective effects against ischemic spinal cord injury. The differences may be result of different animal species and model.

Histologic examination confirmed the ability of TMP to limit neuronal degeneration and necrosis in the anterior horn motor neurons. Histologic examination of the spinal cords revealed either no evidence or very little evidence of injury in TMP-prevented rabbits, whereas spinal cords from control animals had evidence of extensive spinal cord injury with central gray matter necrosis, perikaryal swelling, vacuolization of anterior horn motor neurons, Nissl substance dissolution, and karyolysis. These morphologic changes developed after ischemia and caused the physiologic and clinic consequences observed after ischemic disturbance. The number of normal neurons at anterior spinal cord has direct relations with neurologic function, which was manifested by a strong correlation between the final neurologic outcomes and the number of normal neurons at anterior spinal cord.

The mechanism of motor neuronal cell death after spinal cord ischemia and reperfusion has been explored through molecular, cellular and genic aspects, but it has not been yet identified. Evidence is gathering that a various of factors induced over-accumulation of intracellular calcium triggers proteases, lipase, protein kinase C, nitric oxide synthase, endonucleases, altered gene transcription, and release of free radicals, eventually producing neuronal injury and death. The present study did not explore the protective mechanism of TMP on motor neurons after spinal cord ischemia. According to pharmacology of TMP and studies for effects of TMP on cerebral ischemic injury, antiplatelet activation and aggregation, dilating arterioles to improve microcirculation [17,18], scavenging free radicals, increasing the activity of SOD and decreasing lipid peroxidation [10], inhibiting calcium overload [9], reducing the production of nitric oxide and dynorphin A1-13 in ischemic tissue [19,20], decreasing the protein expression of c-fos and increasing the protein expression of bcl-2 and

heat shock protein 70(HSP 70) [21,22] may be mechanisms for protection of TMP against spinal cord ischemia /reperfusion injury. The injection of TMP is a pure extract from Chinese herbs, and has the properties of abundant resources, cheapness, wide range of dose in clinic and few side effects. Thus we anticipate that TMP might have important clinical application as a treatment in the prevention of spinal cord injury during thoracoabdominal aortic operations.

### Conclusion

It can be concluded from these experiments that tetramethylpyrazine (TMP), an intravenous drug made from traditional Chinese herbs, significantly improves the neurologic injury secondary to spinal cord ischemia and reperfusion after aortic occlusion for 20 minutes in the rabbit.

### Competing Interests

None declared.

### Authors' Contributions

Author 1 initials participated in the design of the study, participated in the sequence alignment and drafted the manuscript.

Author 2 conceived of the study, and participated in its design and coordination.

Author 3 initials participated in the design of the study, carried out the histopathologic examination, and drafted the manuscript.

Author 4 initials performed neurologic assessment participated in the sequence alignment.

Author 5 initials participated in the sequence alignment.

Author 6 initials participated in the sequence alignment

Author 7 initials participated in the sequence alignment

All authors read and approved the final manuscript.

Table 1. Physiologic Variables. See Additional file 1: [Table 1].



## Additional material

### Additional file 1

Click here for file

[<http://www.biomedcentral.com/content/supplementary/1471-2377-2-1-S1.doc>]

## Acknowledgements

This study was supported by a grant-in-aid for "tenth five-year plan" scientific research on medicine from PLA of China (NO. 01M118).

## References

- Crawford ES, Crawford JL, Safi HJ, Coselli JS, Hess KR, Brooks B, Norton HJ, Glaeser DH: **Thoracoabdominal aortic aneurysms: preoperative and intraoperative factors determining immediate and long-term results of operations in 605 patients.** *J Vasc Surg* 1986, **3**:389-404
- Kouchoukos NL, Rokkas CK: **Descending thoracic and thoracoabdominal aortic surgery for aneurysm or dissection: how to we minimize the risk of spinal cord injury?** *Semin Thorac Cardiovasc Surg* 1993, **5**:47-54
- Lang-Lazdunski L, Heurteaux C, Vaillant N, Widmann C, Lazdunski M: **Riluzole prevents ischemic spinal cord injury caused by aortic crossclamping.** *J Thorac Cardiovasc Surg* 1999, **117**:881-889
- Danielisova V, Chavko M: **Comparative effects of the N-Methyl-D-aspartate antagonist MK-801 and the calcium channel blocker KB-2796 on neurologic and metabolic recovery after spinal cord ischemia.** *Exp Neurol* 1998, **149**:203-208
- Matsumoto M, Iida Y, Wakamatsu H, Ohtake K, Nakakimura K, Xiong LZ, Sakabe T: **The effects of NG-nitro-L-Arginine-Methyl ester on neurologic and histopathologic outcome after transient spinal cord ischemia in rabbits.** *Anesth Analg* 1999, **89**:696-702
- Wakamatsu H, Matsumoto M, Nakakimura K, Sakabe T: **The effects of moderate hypothermia and intrathecal tetracaine on glutamate concentrations of intrathecal dialysate and neurologic and histopathologic outcome in transient spinal cord ischemia in rabbits.** *Anesth Analg* 1999, **88**:56-62
- Hall ED, Wolf DL: **A pharmacological analysis of the pathophysiological mechanisms of posttraumatic spinal cord ischemia.** *J Neurosurg* 1986, **64**:951-961
- Agee JM, Flanagan T, Blackburne LH, et al: **Reducing postischemic paraplegia using conjugated superoxide dismutase.** *Ann Thorac Surg* 1991, **51**:911-915
- Kwan CY, Daniel CE, Chen MC: **Inhibition of vasoconstriction by tetramethylpyrazine :does it act by blocking the voltage-dependent Ca<sup>2+</sup> channel?** *J Cardiovasc Pharmacol* 1990, **15**:157-162
- Zhang ZH, Yu SZ, Wang ZT, Zhao BL, Hou JW, Yang FJ, Xin WJ: **Scavenging effects of tetramethylpyrazine on active oxygen free radicals.** *Acta Pharmacol Sin* 1994, **5**:229-231
- Xiao SH, Ge JW: **Protection of tetramethylpyrazine on cerebral ischemia and reperfusion injury in rats.** *J Trad Chin Med* 1993, **18**:35-436
- Cen DY, Chen ZW, Song BW, Wang Y, Fang M, Jiang Q, Ma CG: **The protective effect of ligustrazine on cerebral infarction in rats.** *Chin Pharmacol Bul* 1999, **15**:464-466
- Tarlov IM: **Acute spinal cord compression paralysis.** *J Neurosurg* 1972, **36**:10-20
- Zhang JL, Shi ZX, Mao JS, Zhang TL, Huang L, Li HC, Shi YT, HY' Zhang, Zi BH: **Clinical study of Naoxin Sutong in treating patients with acute cerebral infarction.** *Chin J Integ Trad & West Med* 1994, **14**:478-481
- Men QN: **Treatment of 38 cases of acute cerebral infarction with tetramethylpyrazine and Buyin Huanwu Tang.** *Integ Trad Chin & West Med Prac Crit Care Med* 1999, **6**:12
- Moore WM, Hollier LH: **The influence of severity of spinal cord ischemia in the etiology of delayed-onset of paraplegia.** *Ann Surg* 1991, **213**:427-431
- Liu SY, Sylvester DM: **Antiplatelet structure-activity relationship of tetramethylpyrazine.** *Life Sci* 1994, **55**:1317-1326
- Liu SY, Sylvester DM: **Antiplatelet activity of tetramethylpyrazine.** *Thromb Res* 1994, **75**:51-62
- Gan BX, Chen CF, Chen JW, Li XY, Wang Y: **Effects of the therapy of Reinforcing Qi and activating circulation on acute cerebral ischemia and its mechanism.** *J Guangzhou Univ Trad Chin Med* 1999, **16**:41-44
- Liu Z, Shi Y: **Effects of ligusticum wallichii on the plasma and CSF levels of dynorphin A1-13 in rabbits under acute experimental cerebral ischemia.** *Chin J Integ Trad & West Med* 1990, **10**:160-161
- Wang CX, Bao SY, Liu CF, Zhang ZL: **Effects of nimodipine and ligustrazini on the protein expression of c-fos and bcl-2 after focal cerebral ischemia followed by reperfusion.** *Chin Crit Care Med* 1999, **11**:609-611
- Li Y, Chen ZX, Xie A, Zhang SH, Gong WQ, Ciu ZX, Zang YM: **Effect of tetramethylpyrazine on the HSP70 expression in rats with cerebral ischemic reperfusion injury.** *Chin J Intern Med* 1998, **37**:333-335

## Pre-publication history

The pre-publication history for this paper can be accessed here:

<http://www.biomedcentral.com/1471-2377/2/1/prepub>

Publish with **BioMed Central** and every scientist can read your work free of charge

"BioMedCentral will be the most significant development for disseminating the results of biomedical research in our lifetime."

Paul Nurse, Director-General, Imperial Cancer Research Fund

Publish with **BMC** and your research papers will be:

- available free of charge to the entire biomedical community
- peer reviewed and published immediately upon acceptance
- cited in PubMed and archived on PubMed Central
- yours - you keep the copyright



Submit your manuscript here:

<http://www.biomedcentral.com/manuscript/>

[editorial@biomedcentral.com](mailto:editorial@biomedcentral.com)