






ORIGINAL ARTICLE

Effectiveness of calcaneal osteotomy in surgical treatment of foot conditions: A Prisma statement guidelines compliant systematic review

Daniel López-López¹  | Ricardo Larrainzar-Garijo²  |
Ricardo Becerro-de-Bengoa-Vallejo³  | Marta Elena Losa-Iglesias⁴  |
Javier Bayod-López⁵ 

¹Research, Health and Podiatry Group, Department of Health Sciences, Faculty of Nursing and Podiatry, Universidade da Coruña, Ferrol, Spain

²Orthopaedics and Trauma Department, Medicine School, Universidad Complutense – Hospital Universitario Infanta Leonor, Madrid, Spain

³Faculty of Nursing, Physiotherapy and Podiatry, Complutense University of Madrid, Madrid, Spain

⁴Faculty of Health Sciences, Universidad Rey Juan Carlos, Alcorcón, Spain

⁵Biomedical Research Networking center in Bioengineering, Biomaterials and Nanomedicine (CIBER-BBN), Group of Applied Mechanics and Bioengineering (AMB), Aragon Institute of Engineering Research (I3A), Universidad de Zaragoza, Zaragoza, Spain

Correspondence

Daniel López-López, Grupo de Investigación Saúde e Podoloxía, Departamento de Ciencias da Saúde, Universidade da Coruña, Campus Universitario de Esteiro s/n, 15403 Ferrol, Spain.

Email: daniellopez@udc.es

Funding information

Ministerio de Ciencia e Innovación, Grant/Award Number: PID2019-108009RB-I00

Abstract

Calcaneal osteotomy is a commonly established method used to correct various foot malalignment surgery problems that produce varus and valgus hindfoot abnormality as well as Haglund's deformity, cavovarus foot reconstruction, flatfoot deformity, plantar fasciitis, posterior tibial tendon insufficiency and planovalgus foot. After decades, several procedures in orthopaedic foot surgery have been suggested for reducing the risk of wound and neurovascular complications. The goal of this Prisma statement guidelines compliant systematic review was to establish the effectiveness and safety of calcaneal osteotomy in foot surgery. We have performed a novel systematic review of the current published literature in order to evaluate the scientific evidence now available on this association, assigning predefined exclusion and inclusion criteria. Eight investigations were selected which had 191 cases. The adult flatfoot, tibialis posterior reconstruction and cavovarus foot deformity were treated with different procedures of calcaneal osteotomy techniques. The adequate level of effectiveness of calcaneal osteotomy is associated with the kind and location of the incision, with or without screw application, in each specific foot condition. There is a limited number of scientific investigations of the effectiveness and safety of the different kinds of calcaneal osteotomy in foot surgery, and there is the need to enhance outcome knowledge on this foot surgery technique.

KEYWORDS

calcaneus, foot, foot disease, heel

Key Messages

- we have estimated the effectiveness of calcaneal osteotomy in surgical treatment of foot conditions
- a limited number of scientific investigations of the effectiveness and safety of the different kinds of calcaneal osteotomy in foot surgery
- there is the need to enhance outcome knowledge on this foot surgery technique

This is an open access article under the terms of the [Creative Commons Attribution-NonCommercial](https://creativecommons.org/licenses/by-nc/4.0/) License, which permits use, distribution and reproduction in any medium, provided the original work is properly cited and is not used for commercial purposes.

© 2021 The Authors. *International Wound Journal* published by Medicalhelplines.com Inc (3M) and John Wiley & Sons Ltd.

1 | INTRODUCTION

Calcaneal osteotomy is a commonly established method used to correct various foot malalignment surgery problems that produce varus and valgus hindfoot abnormality as well as Haglund's deformity, cavovarus foot reconstruction, flatfoot deformity, plantar fasciitis, posterior tibial tendon insufficiency and planovalgus foot.¹⁻⁵ Furthermore, this surgical technique improves the biomechanical characteristics of the calcaneal alignment, produces deformity correction in multi-plane motion and can have a positive impact on walking dynamics in people that suffer this condition.⁶

In the last decades, these kind of deformities and alterations of the foot are identified as an indispensable public health problem, linked with the augment of the high prevalence and discomfort of most of the foot malalignment symptoms is related with: (a) joint pain, (b) difficulties for putting on shoes, (c) variation in plantar pressures, (d) muscle weakness, (e) gait abnormalities and (f) risk of falls.^{7,8} This has been confirmed by the physicians and health policymakers as a significant threat to overall public health owing to its negative influence on individual and global health.^{9,10}

Thus, many methods of fixation in the foot surgery specialty have been developed over the years, to increase safety and effectiveness, according to the orthopaedic surgeons' preferences, to reduce several complications such as: (a) infection, (b) undercorrection or overcorrection, (c) limited fixation, (d) greater postoperative oedema, (e) vascular embarrassment, (f) sural nerve loss or entrapment, (g) graft absorption, (h) subtalar or calcaneocuboid arthritis and (i) fracture in the calcaneus and so improve the outcomes of these procedures.¹¹

Based on these antecedents, studies have not been found focussing on correcting various foot malalignments related to how best to secure the calcaneal osteotomy. In this way, in our hypothesis, there is a small number of the clinical studies and trials regarding the effectiveness of calcaneal osteotomy in surgical treatment of foot conditions. Thus, our goal in this novel Prisma statement guidelines compliant systematic review was to establish the effectiveness and safety of calcaneal osteotomy in foot surgery.

2 | MATERIALS AND METHODS

2.1 | Study design

This Prisma statement guidelines compliant systematic review was conducted to improve the global overview of this important foot malalignment in order to better

understand available evidence. The investigation was registered with the record number CRD42021271306 in the International Prospective Register of Systematic Reviews [PROSPERO]; this database is linked to health sciences report related outcomes.¹²

2.2 | Search strategy

An electronic systematic search was performed in the following online databases: Web of Science and MEDLINE applying relevant keywords and checked vocabulary words (ie, medical sub-heading [MeSH] terms). The keywords incorporated global search terms such as Calcaneus, Foot, Foot diseases, and Heel and treatment-related terms Calcaneal osteotomy, Calcaneal surgery, Calcaneal treatment, and Minimally invasive, Foot Surgery. Our completed search protocol strategy can be reviewed in Appendix.

In addition, this systematic review interval included the last 10 years. All investigations available in these two online databases until August 2021 were incorporated. We selected articles reporting finished randomised or non-controlled clinical trials published in international peer-reviewed journals. All references list incorporated in these articles issued in English or Spanish were evaluated and subjected to revision in both languages.

Further, special caution was used on the online search in Web of Science and MEDLINE, to make sure to include all relevant investigations, even though that ran the risk of detecting irrelevant data that would subsequently have to be erased.

2.3 | Exclusion and inclusion criteria

We assigned these exclusion and inclusion criteria to analyse which studies were included in this novel systematic review related to original investigations in foot surgery conducted in experimental laboratories, podiatry clinic or orthopaedic medical centres applying any calcaneal osteotomy procedure. Only research in human and cadaveric fresh frozen specimens was included. The criteria for assignment of variables were: (a) randomised or non-controlled clinical trials published in the previous 10 years, (b) cases of patients or cadaveric samples, (c) various foot malalignment surgery problems, (d) type of calcaneal osteotomy, (e) outcomes measurements, (f) time of follow-up, (g) efficacy of the calcaneal osteotomy and (h) investigations written in English and Spanish.

The exclusion criteria were: (a) studies evaluating the finite element method or sawbones anatomical models, (b) commentaries or letters to the editor and (c) investigations published in languages other than English and Spanish.¹²

TABLE 1 Main characteristics of the included investigations

Foot malalignment		Intervention	Type of the System	System insertion place	Outcomes measures	Follow Up	Level of the Fixation
Schmid et al ¹³	10	Cavovarus foot deformity	Two 2.0 mm Kirschner wires were driven from the first and third metatarsal into the talar head. The proximal 30 mm of the tibia and fibula were fixed in a polymethylmethacrylate (PMMA) block (Beracryl, Suter Kunststoff AG, Jegenstorf, Switzerland)	Supramalleolar valgus osteotomies and lateralising calcaneal osteotomies	<ul style="list-style-type: none"> High-resolution pressure and force measurement sensors (TekScan Inc, South Boston, Massachusetts). Custom air pressure sensor calibration machine (AO Foundation, Switzerland). 	None	<ul style="list-style-type: none"> Both osteotomies showed good results.
Charwat-Pessler et al ¹⁴	21	Adult acquired flat foot deformity	<ul style="list-style-type: none"> A cannulated 6.5 Synthes cortical screw (Synthes Inc., West Chester, Pennsylvania) 	<ul style="list-style-type: none"> Medial displacement calcaneal osteotomy Tenotomy of the flexor digitorum longus and junction with the tendon of the flexor hallucis longus. 	<ul style="list-style-type: none"> Visual Analogue Scale American Orthopaedic Foot and Ankle Society Radiographic parameters (talo-first metatarsal angle, talonavicular coverage angle and the hindfoot alignment) 	20 months	<ul style="list-style-type: none"> Good results
Martinkewich et al ¹⁵	10	Pes planovalgus	<ul style="list-style-type: none"> Hydroxyapatite tricalcium phosphate graft (Sheffield, England). Tricortical iliac crest autograft 	<ul style="list-style-type: none"> Osteotomy proximal and parallel to the calcaneocuboid joint was distracted by 10 mm to 12 mm until the deformity was corrected. 	<ul style="list-style-type: none"> Radiostereometric analysis (Arco-Ceil/Medira; Santax Medico, Aarhus, Denmark) with x-ray tubes angled towards each other at 40° and a focus-grid uniplanar carbon calibration box (Box 24, Medis Special, Leiden, the Netherlands) 	6 months	<ul style="list-style-type: none"> Poor results (Hydroxyapatite tricalcium phosphate graft). Good results (Tricortical iliac crest autograft)
Chong et al ¹⁶	24	Planovalgus deformity	Vilex titanium implants (McMinnville, Tennessee)	<ul style="list-style-type: none"> A lateral incision was made over the distal calcaneus for an opening wedge osteotomy, inserting a wedge of cadaveric bone. A 1 cm lateral incision in sinus tarsi to implant the conical screw. 	<ul style="list-style-type: none"> Fluoroscopy. 10-camera motion capture system (Vicon, Centennial, Colorado). Force plates (AMTI, Watertown, Massachusetts). Pedobarograph mat (RSScan, Paal, Belgium). Oxford Ankle-Foot Questionnaire for Children. 	12 months	<ul style="list-style-type: none"> Optimal (lateral column lengthening) Optimal (subtalar arthroereisis)

TABLE 1 (Continued)

Cases	Foot malalignment	Intervention	Type of the System	System insertion place	Outcomes measures	Follow Up	Level of the Fixation
Uselli et al ¹⁷ 42	Adult flatfoot	Medial displacement of the calcaneal osteotomy and flexor digitorum longus transfer to navicular bone	<ul style="list-style-type: none"> 2.5-mm Kirschner wire for fixation of the calcaneal osteotomy. Bioabsorbable interference screw for fixation of the FDL tendon in navicular bone. 	<ul style="list-style-type: none"> A 4 cm lateral incision of the calcaneal tuberosity. The tuberosity was cut from lateral to medial and displaced medially and fixed with a cannulated 7.3-mm cancellous lag screw. 	<ul style="list-style-type: none"> Radiographs Magnetic resonance imaging Sports Athlete Foot and Ankle Score 	24 months	<ul style="list-style-type: none"> Good results
Chan et al ¹⁸ 30 cases	Adult acquired flatfoot deformity	Medialising calcaneal osteotomy	<ul style="list-style-type: none"> 6.5- or 7.3-mm cannulated screw fixation Iliac crest autograft Two fully threaded with cortical screws 	<ul style="list-style-type: none"> Lateral incision with cut of the calcaneus was translated medially, fixed with 6.5- or 7.3-mm cannulated screws. The lateral column lengthening was performed through the anterior part of the calcaneus, filled with iliac crest autograft and two fully threaded, cortical screws. 	<ul style="list-style-type: none"> Radiographs 	24 weeks	<ul style="list-style-type: none"> Good results
Kheir et al ¹⁹ 29 cases	Tibialis posterior reconstruction	Medial displacement of at least 10 mm	6.5 mm cannulated screw	<ul style="list-style-type: none"> Minimally invasive calcaneal osteotomy surgery 	<ul style="list-style-type: none"> Fluoroscopy 	20 weeks	<ul style="list-style-type: none"> Good results
Niki et al ²⁰ 25 cases	Adult acquired flatfoot	Medial displacement of the calcaneal osteotomy with flexor digitorum longus tendon transfer	<ul style="list-style-type: none"> Not applicable 	<ul style="list-style-type: none"> Not applicable 	<ul style="list-style-type: none"> Radiographs Magnetic resonance imaging Preoperative and postoperative Japanese Society for Surgery of the Foot Foot Function Index SF-36 	12 months	<ul style="list-style-type: none"> Poor results

2.4 | Synthesis of data and management of search results

Two senior expert reviewers evaluated the search findings related with calcaneal osteotomy procedures in foot surgery (D.L.-L. and J.B.-L.), and if there were queries on any investigation regarding the exclusion or inclusion criteria, this was agreed with all co-authors. All references of scientific investigations to be incorporated were manually analysed, and those original articles that might be added were also evaluated and obtained.

We retrieved identical information associated with all the original articles according to the Prisma statement guidelines, applying a standardised format that is shown in Table 1 with individual fields for each original paper. We recorded all the information from every investigation in an evidence level table with qualitative data, and an overall conclusion was drawn. The level of risk of bias evaluation in the systematic review was assessed using the Review Manager software of The Cochrane Library, version 5.3. It was not possible to conduct a meta-analysis because of the heterogeneity of the incorporated investigations.

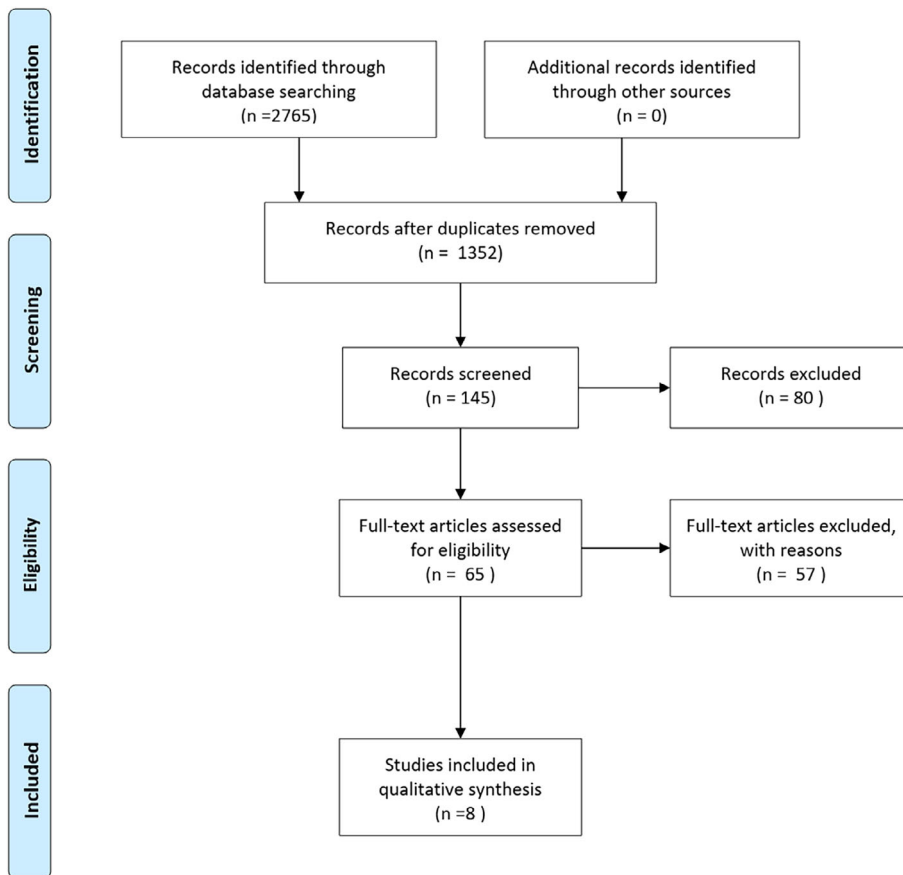


FIGURE 1 Flowchart of the included studies describing calcaneal osteotomy in foot surgery

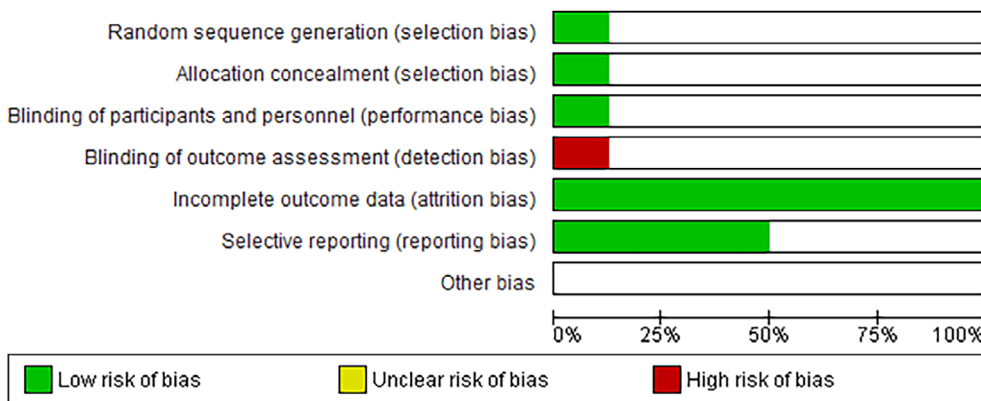


FIGURE 2 Risk of bias graph in the studies included. (1) Green (low risk), (2) white (unclear risk) and (3) red (high risk)

FIGURE 3 Risk of bias summary in the studies. (1) green (low risk), (2) white (unclear risk) and (3) red (high risk)

	Usueili 2016	Schmid 2013	Niki 2012	Martinkovich 2016	Kheit 2015	Chong 2015	Charwat-Pessler 2015	Chan 2013	
Random sequence generation (selection bias)				+					
Allocation concealment (selection bias)				+					
Blinding of participants and personnel (performance bias)		+							
Blinding of outcome assessment (detection bias)		●							
Incomplete outcome data (attrition bias)	+	+	+	+	+	+	+	+	
Selective reporting (reporting bias)				+	+	+	+		
Other bias									

3 | RESULTS

3.1 | Summary of the studies included

Figure 1 presents the flowchart of the data published in the original articles associated with calcaneal osteotomy in foot surgery retrieved.

Eight studies recorded all the inclusion criteria. Most of the studies analysed were original articles on randomised or non-controlled clinical trials. Eight of the original papers corresponded to outcomes of cases of patients, and one study in fresh frozen human cadavers, all information appears in Table 1.

Lastly, the risk of bias was evaluated in these eight studies. Only one investigation showed a low risk in random sequence generation, in blinding of outcome assessment and in allocation concealment. All the studies recorded displayed a low risk in incomplete outcome data, and four included a selective reporting bias. Also, the majority of the investigations appeared unclear of bias in terms of other bias. All data are shown in Figures 2 and 3.

4 | DISCUSSION

To our scientific knowledge, this is the first Prisma statement guidelines compliant systematic review. This innovative investigation focussed on suitable published original literature that exclusively determines the overall knowledge available on the effectiveness and safety of calcaneal osteotomy in foot surgery.

We have discovered that calcaneal osteotomy is a standard method of choice to enhance various foot malalignment surgery problems that produce varus and

valgus hindfoot abnormality. This is a main technique for reparation of functional or structural alterations such as supinatory or pronatory syndromes. This surgical method can modify the calcaneal axis, the orthopaedic correction in aligning biomechanical problems in any planes of motion.²¹

Due to the large number of studies in the current literature describing foot malalignment surgery problems and evaluating various techniques with theoretical instructions for performing various types of calcaneal osteotomies, the reports recognise heterogeneity in the site of the calcaneal osteotomy that suggests the choice is based on the orthopaedic surgeon's preference, simplicity or other local factors in the case of more complicated reconstructions.^{5,22}

In fact, it was identified that most of these foot problems were managed through a lateral approach, applying screws, a lateral plate or transfer of muscles, which are safe techniques with good radiographic and clinical results which are satisfactory in most of the patients.^{13,14,16-20}

The majority of these scientific studies displayed adequately performed calcaneal osteotomy in foot surgery through a lateral approach as an excellent technique for the reparation of various foot malalignments.

For deciding on calcaneal osteotomy, it is necessary to establish clinical and surgery recommendations related with to consider availability, the higher cost and the structural quality of the bone to determine the fixation model. Thus, there must be an evaluation and analysis of the joints that allow adequate biomechanical movement, using screws, different size plate systems and/or the transfer muscles for the patient to obtain the optimal outcome in the foot surgery treatment and the best fixation system in every case.

This Prisma statement guidelines compliant systematic review highlights some limitations because of the

scant available scientific evidence, foot malalignment was very different in the provided studies and due to the heterogeneous methods associated with these original studies, which did not provide the opportunity to perform a meta-analysis. Furthermore, some scientific investigations were of patients and others of cadaveric samples with variations in the types of measurements of the main features in the included reports.

Last, innovative systematic review offers helpful data to treat various related foot malalignment surgery problems for investigators and orthopaedic surgeon clinicians regarding the safety and effectiveness of calcaneal osteotomy techniques. Additionally, it manifests the value of continuous scientific investigation of this technique to get better surgical findings, overall health and quality of life for the patients with these foot problems.

5 | CONCLUSIONS

There is a limited number of scientific investigations about the effectiveness and safety of the different kinds of calcaneal osteotomy in foot surgery, and there is a need to enhance outcome knowledge on this foot surgery technique.

ACKNOWLEDGEMENTS

This research was funded by Spanish Ministry of Science and Innovation through the project PID2019-108009RB-I00.

CONFLICT OF INTEREST

All authors declare there is no conflict of interest with the article publication and agree with this journal copyright.

AUTHOR CONTRIBUTIONS

Conceptualisation, Daniel López-López, Ricardo Larrainzar-Garijo, Ricardo Becerro de Bengoa Vallejo, Marta Elena Losa-Iglesias and Javier Bayod López, data curation, Daniel López-López and Javier Bayod López, formal analysis, Daniel López-López and Javier Bayod López, investigation, Daniel López-López, Ricardo Larrainzar-Garijo, Ricardo Becerro de Bengoa Vallejo, Marta Elena Losa-Iglesias and Javier Bayod López, methodology, Daniel López-López, Ricardo Larrainzar-Garijo, Ricardo Becerro de Bengoa Vallejo, Marta Elena Losa-Iglesias and Javier Bayod López, supervision, Daniel López-López, Ricardo Larrainzar-Garijo, Ricardo Becerro de Bengoa Vallejo, Marta Elena Losa-Iglesias and Javier Bayod López, writing – original draft, Daniel López-López, Ricardo Larrainzar-Garijo, Ricardo Becerro de Bengoa Vallejo, Marta Elena Losa-Iglesias and Javier Bayod López, writing – review and editing, Daniel López-López, Ricardo Larrainzar-Garijo, Ricardo Becerro de Bengoa Vallejo, Marta Elena Losa-Iglesias and Javier Bayod López.


DATA AVAILABILITY STATEMENT

The dataset supporting the conclusions of this article is available in the daniellopez@udc.es in the Research, Health and Podiatry Group. Department of Health Sciences. Faculty of Nursing and Podiatry. Universidade da Coruña, Ferrol, Spain.

ORCID

Daniel López-López  <https://orcid.org/0000-0002-9818-6290>

Ricardo Larrainzar-Garijo  <https://orcid.org/0000-0002-0501-2006>

Ricardo Becerro-de-Bengoa-Vallejo  <https://orcid.org/0000-0003-1568-7602>

Marta Elena Losa-Iglesias  <https://orcid.org/0000-0001-7588-2069>

Javier Bayod-López  <https://orcid.org/0000-0001-5505-6974>

REFERENCES

- Green A, Hass M, Tubridy S, Goldberg M, Perry J. Calcaneal osteotomy for retrocalcaneal exostosis. *Clin Podiatr Med Surg.* 1991;8(3):659-665.
- Jacobs A, Geistler P. Posterior calcaneal osteotomy. Effect, technique, and indications. *Clin Podiatr Med Surg.* 1991;8(3):647-657.
- Miyamoto W, Takao M, Uchio Y. Calcaneal osteotomy for the treatment of plantar fasciitis. *Arch Orthop Trauma Surg.* 2010;130(2):151-154. doi:10.1007/s00402-009-0879-8.
- Hockenbury RT, Sammarco GJ. Medial sliding calcaneal osteotomy with flexor hallucis longus transfer for the treatment of posterior tibial tendon insufficiency. *Foot Ankle Clin.* 2001;6(3):569-581.
- Bariteau JT, Blankenhorn BD, Tofte JN, DiGiovanni CW. What is the role and limit of calcaneal osteotomy in the Cavovarus foot? *Foot Ankle Clin.* 2013;18(4):697-714.
- Malerba F, De Marchi F. Calcaneal osteotomies. *Foot Ankle Clin.* 2005;10(3):523-540.
- Margolis S. Foot problems. *Aust Fam Physician.* 2015;44(3):85-85.
- Prat D, Lee W, Farber DC. Calcaneal osteotomies. *Ann Jt.* 2020;5(0):29-29.
- López-López D, Becerro-de-Bengoa-Vallejo R, Losa-Iglesias ME, et al. Evaluation of foot health related quality of life in individuals with foot problems by gender: a cross-sectional comparative analysis study. *BMJ Open.* 2018;8(10):e023980.
- López-López D, Pérez-Ríos M, Ruano-Ravina A, et al. Impact of quality of life related to foot problems: a case-control study. *Sci Rep.* 2021;11(1):1-6. <https://www.nature.com/articles/s41598-021-93902-5>
- Frankel J, Turf R, Nichols D. Complications of calcaneal osteotomies. *Clin Podiatr Med Surg.* 1991;8(2):409-423.
- Page MJ, McKenzie JE, Bossuyt PM, et al. The PRISMA 2020 Statement: an Updated Guideline for Reporting Systematic Reviews. *BMJ.* 2021;372(71). <https://doi.org/10.1136/bmj.n71>
- Schmid T, Zurbruggen S, Zderic I, Gueorguiev B, Weber M, Krause FG. Ankle joint pressure changes in a Pes Cavovarus

- model: supramalleolar valgus osteotomy versus lateralizing calcaneal osteotomy. *Foot Ankle Int.* 2013;34(9):1190-1197. doi:[10.1177/1071100713500473](https://doi.org/10.1177/1071100713500473)
14. Charwat-Pessler CG, Hofstaetter SG, Jakubek DE, Trieb K. Interference screw for fixation of FDL transfer in the treatment of adult acquired flat foot deformity stage II. *Arch Orthop Trauma Surg.* 2015;135(10):1369-1378. doi:[10.1007/s00402-015-2295-6](https://doi.org/10.1007/s00402-015-2295-6), 135, 1369, 1378.
 15. Martinkevich P, Rahbek O, Stilling M, Pedersen LK, Gottliebsen M, Søballe K, Møller-Madsen B. Is structural hydroxyapatite tricalcium-phosphate graft or tricortical iliac crest autograft better for calcaneal lengthening osteotomy in childhood? interim results from a randomised, controlled non-inferiority study. *Bone Joint J.* 2016;98-B(11):1554-1562. doi:[10.1302/0301-620X.98B11](https://doi.org/10.1302/0301-620X.98B11)
 16. Chong DY, Macwilliams BA, Hennessey TA, Teske N, Stevens PM. Prospective comparison of subtalar arthroereisis with lateral column lengthening for painful flatfeet. *J Pediatr Orthop B.* 2015;24(4):345-353.
 17. Usuelli FG, Di Silvestri CA, D'Ambrosi R, Maccario C, Tan EW. Return to sport activities after medial displacement calcaneal osteotomy and flexor digitorum longus transfer. *Knee Surg Sports Traumatol Arthrosc.* 2018;26(3):892-896. doi:[10.1007/s00167-016-4360-2](https://doi.org/10.1007/s00167-016-4360-2)
 18. Chan JY, Williams BR, Nair P, et al. The contribution of medializing calcaneal osteotomy on Hindfoot alignment in the reconstruction of the stage II adult acquired flatfoot deformity. *Foot Ankle Int.* 2013;34(2):159-166. doi:[10.1177/1071100712460225](https://doi.org/10.1177/1071100712460225)
 19. Kheir E, Borse V, Sharpe J, Lavalette D, Farndon M. Medial displacement calcaneal osteotomy using minimally invasive technique. *Foot Ankle Int.* 2015;36(3):248-252. doi:[10.1177/1071100714557154](https://doi.org/10.1177/1071100714557154)
 20. Niki H, Hirano T, Okada H, Beppu M. Outcome of medial displacement calcaneal osteotomy for correction of adult-acquired flatfoot. *Foot Ankle Int.* 2012;33(11):940-946. doi:[10.3113/FAI.2012.0940](https://doi.org/10.3113/FAI.2012.0940)
 21. Greenfield S, Cohen B. Calcaneal osteotomies: pearls and pitfalls. *Foot Ankle Clin.* 2017;22(3):563-571.
 22. Haggerty EK, Chen S, Thordarson DB. Review of calcaneal osteotomies fixed with a calcaneal slide plate. *Foot Ankle Int.* 2020;41(2):183-186. <https://pubmed.ncbi.nlm.nih.gov/31535578/>

SUPPORTING INFORMATION

Additional supporting information may be found in the online version of the article at the publisher's website.

How to cite this article: López-López D, Larrainzar-Garijo R, Becerro-de-Bengoa-Vallejo R, Losa-Iglesias ME, Bayod-López J. Effectiveness of calcaneal osteotomy in surgical treatment of foot conditions: A Prisma statement guidelines compliant systematic review. *Int Wound J.* 2022; 19(6):1494-1501. doi:[10.1111/iwj.13745](https://doi.org/10.1111/iwj.13745)