

## RESEARCH

# Pituitary haemorrhage and infarction: the spectrum of disease

Fizzah Iqbal<sup>1</sup>, William Adams<sup>2</sup>, Ioannis Dimitropoulos<sup>1</sup>, Samiul Muquit<sup>3</sup> and Daniel Flanagan<sup>1</sup><sup>1</sup>Department of Endocrinology, University Hospital Plymouth, Plymouth, UK<sup>2</sup>Department of Radiology, University Hospital Plymouth, Plymouth, UK<sup>3</sup>Department of Neurosurgery, University Hospital Plymouth, Plymouth, UKCorrespondence should be addressed to D Flanagan: [danielflanagan@nhs.net](mailto:danielflanagan@nhs.net)

## Abstract

**Background:** Pituitary apoplexy is an acute syndrome of haemorrhage or infarction into the pituitary. The condition is relatively well-described. Less well-described is sub-acute presentation of the same condition.

**Objective:** To compare the clinical presentation and natural history of subacute pituitary haemorrhage/infarction with pituitary apoplexy (acute).

**Method:** Retrospective analysis of a consecutive cohort of 55 patients (33 with pituitary apoplexy, 22 with subacute disease) presenting to University Hospital Plymouth between 1994 and 2019. Comparison of the clinical, endocrinological and radiological features at presentation. Comparison of clinical treatment and subsequent outcomes for the two groups.

**Results:** There were no significant differences in predisposing factors for the two groups. Acute headache was more frequent in the acute group. Chronic headache was common in both groups prior to presentation. Low sodium was more common at presentation in the acute group (11/26 vs 2/19  $P = 0.02$ ) otherwise there were no differences in endocrine deficit at presentation. A significant proportion showed an improvement in endocrine function at follow up (acute 8/31, subacute 5/21  $P = 1.0$ ). MRI characteristics were variable at presentation and follow up in both groups. Ring enhancement with contrast was more frequent in acute (14/20 vs 3/11  $P = 0.03$ ). This appearance resolved at follow up in the majority.

**Conclusions:** Pituitary apoplexy has a characteristic and dramatic presentation. Subacute pituitary haemorrhage/infarction shows similar natural history and outcome. These conditions would appear to represent a spectrum of the same condition.

## Key Words

- ▶ pituitary
- ▶ haemorrhage
- ▶ infarction
- ▶ apoplexy

*Endocrine Connections*  
(2021) **10**, 171–179

## Introduction

The word apoplexy is derived from the ancient Greek word apoplexia meaning ‘a striking away’. The definition implies a sudden or severe attack of some form. The term is now mostly used to describe a sudden haemorrhage or infarction in a specific tissue such as the pituitary. Classically patients present with sudden onset severe headache. There may be accompanying meningism, vomiting, confusion and visual dysfunction. In addition, neuro-ophthalmologic

signs may involve the second, third, fourth, fifth and sixth cranial nerves.

There is a wide differential diagnosis for presentation with sudden onset headache. Severe headache is common. Pituitary apoplexy represents a rare condition in a common presentation (1, 2, 3, 4, 5, 6). Diagnosis may be delayed and only made when appropriate imaging of the pituitary is performed. The diagnosis is usually made by MRI. Therefore the diagnosis is dependent on an MRI

report commenting on possible pituitary haemorrhage or infarction within the appropriate clinical presentation. If the appropriate test is not performed then the diagnosis is not made (7). It would seem likely that a significant proportion of patients are discharged from acute care without the correct diagnosis being made. Equally as the clinical presentation is variable it is likely that a number of people with the same condition do not present acutely.

MRI technology has significantly improved in the past two decades (8). Possible haemorrhage or infarction is now reported in an increasing proportion of pituitary scans (9). Some of these patients will have had entirely asymptomatic presentations. Some will have had classical presentations with severe headache but the diagnosis may not be made at the time. There would also appear to be a group that retrospectively are found to have had sudden less severe symptoms that probably represent the initial event but they did not present for medical help at that time. Pituitary apoplexy by definition is not an appropriate term to describe the second and third groups although it seems likely that all three represent the spectrum of a single condition.

There are a number of aspects of management that remain unclear such as the role of surgery (10, 11). The published literature would suggest that there is a potential for clinical improvement in a proportion of patients with an acute presentation although there is less evidence for those with subacute disease. A multidisciplinary approach including endocrinology, neurosurgery, radiology and oncology is recommended (12).

The UK guidelines for the management of pituitary apoplexy describe the group with asymptomatic presentation as 'sub clinical pituitary apoplexy'. Although it was felt that this was a common finding, this group were excluded from the guidelines (1).

As this is a rare condition there are few cohorts published in the modern era where MRI is used to guide management. We report our experience with a cohort of patients presenting acutely with what would be described as apoplexy. We have compared this group with a cohort presenting less acutely where pituitary haemorrhage or infarction was suspected at presentation and confirmed by the passage of time. The hypothesis being tested was that these two groups represent a spectrum of the same disease.

## Methods

We conducted a retrospective analysis of the medical and radiological records of patients diagnosed with

pituitary haemorrhage or infarction between 2004 and 2019 managed at University Hospital Plymouth, UK. We identified cases using the regional pituitary audit, records of multidisciplinary team meetings and from clinic correspondence. Plymouth is the regional centre for pituitary surgery. Patients were included from a number of referring hospitals within the region.

Both acute and subacute haemorrhage/infarction patients were included based on clinical and radiological criteria and where follow up had excluded the possible differential diagnoses. An acute syndrome (that would be described as apoplexy) was diagnosed in subjects presenting with a sudden syndrome requiring hospital admission or assessment. This syndrome included sudden severe headache or meningism with other associated symptoms that are recognised as part of this condition. These included a new visual field defect or ophthalmoplegia. Although the initial imaging in some cases was CT, MRI was performed in all cases during the acute presentation. Subjects were included if the initial MRI report supported the diagnosis of haemorrhage and/or infarction. As the imaging was performed in a number of different hospitals, the scanning protocols differ between centres.

The sub-acute syndrome was diagnosed primarily on the basis of a dedicated pituitary MRI scan showing features suggestive of haemorrhage or infarction. Although a number of these patients had been referred urgently to the pituitary service, they had not been admitted to hospital or sent to inpatient assessment or ambulatory care units. Pituitary apoplexy had not been considered in this group as the initial working diagnosis. Pituitary haemorrhage or infarction had not been considered until the results of the initial MRI were available although, on direct questioning, symptoms that would be consistent with the diagnosis (such as headache) were present in a high proportion. The MRI imaging features of pituitary haemorrhage/infarction are not specific to this condition. Other diagnoses were initially considered (such as Rathke's cleft cyst). Patients were only included in this group if the short term follow up scan then showed further changes consistent with resolving haemorrhage/infarction. These changes would include shrinkage of the initial lesion or rapid changes in signal consistent with the previously published features of resolving haemorrhage or infarction. We have avoided the term apoplexy for this group as this implies a more acute change.

We analysed age at presentation, gender, risk factors that may predispose to pituitary apoplexy, history of adenoma as well as symptoms at presentation and

the presence or absence of neuro-ophthalmic signs. Imaging at diagnosis and follow up was also reviewed as well as immediate management that is conservative vs neurosurgical. Endocrine deficiencies at diagnosis and subsequent hormone replacement requirement at follow up were also reviewed. Although the full clinical correspondence was available for each patient, endocrine deficits were only included if the actual laboratory results were available for review.

Continuous variables were compared using Mann-Whitney or unpaired *t*-test depending upon the distribution of the data. Categorical variables were compared using Fisher's exact test. The study was registered with the audit department at Plymouth Hospitals NHS Trust Ca\_2015-16-221. Ethical review and consent were not required for this study.

## Results

Fifty-five individuals with radiological evidence of pituitary haemorrhage or infarction that presented between 1994 and 2019 were identified and included in this study. Thirty-three people presented with a clinical syndrome that would be described as pituitary apoplexy, 22 presented with a sub-clinical syndrome. The full clinical history at the time of presentation and at follow up was available for all patients.

### Predisposing factors

Table 1 details the predisposing factors for the two groups of acute and subacute patients. Established predisposing factors for this syndrome were compared across the acute

and subacute groups. Genders were equally represented in both groups. The mean age at presentation was 50 years for both groups. Hypertension was the commonest predisposing factor in both groups although there was no difference between the two groups. Prolactinoma was more common in both groups than would be expected based on the population prevalence. Dopamine agonist therapy had been used in two of six patients in the acute group and two of four in the subacute group. Two of fourteen women in the acute group presented during pregnancy, one of fifteen women in the subacute presented during pregnancy. There were no significant differences in the frequency of any predisposing factors between the two groups although there was a trend towards more anticoagulation in the acute group (four people compared with 0 in the subacute group).

### Clinical presentation

Table 2 defines the presenting symptoms of the two groups. Acute headache was an almost universal finding in those presenting with acute haemorrhage/infarction (97% of cases). This was not present in the subacute group although a preceding history of a headache was elicited in a large proportion of both groups prior to presentation (ten people in each group). Photophobia, vomiting, meningism and fever were common presentations in the acute group. Meningitis and subarachnoid haemorrhage were considered as part of the differential diagnosis in most of the acute group. Some degree of confusion was documented in 9/33 of the acute group but was also present in 2/22 of the subacute group prior to presentation. Visual field defects were present in a high proportion of both groups. Visual field defect was seen in a slightly higher

**Table 1** Demographics and predisposing factors.

	Acute	Subacute	Odds ratio	P-value	Confidence interval
<i>n</i>	33	22	—	—	—
Gender (male/female)	19/14	7/15	2.91	0.10	0.94–9.01
Age years mean	50.3	50.8	—	—	—
Age median (IQR)	49 (36)	53 (35)	—	0.74	—
Study period	1994–2019	2005–2019	—	—	—
Follow up years mean (s.d.)	5.2 (3.8)	5.0 (5.1)	—	0.21	—
Previous hypertension	12/33	9/22	0.69	0.58	0.23–2.06
Recent pregnancy	2/33	1/22	1.40	0.66	0.12–15.91
Anticoagulation	4/33	0	—	0.07	—
Antiplatelet	5/33	4/22	0.80	1.00	0.19–3.40
Previous stroke	1/33	0	—	1.00	—
Previous dopamine agonist therapy	2/33	2/22	0.65	1.00	0.08–4.96
Previous radiotherapy	1/33	0	—	1.00	—
Acromegaly	0	1/22	—	1.00	—
Prolactinoma	6/33	4/22	2.72	0.18	0.67–11.1

**Table 2** Symptoms and signs at time of diagnosis.

	Acute, n = 33	Subacute, n = 22	Odds ratio	P-value	CI
Acute headache	31/33	0/22	—	<0.01	—
Chronic headache	10/33	10/22	0.44	0.17	0.14–1.33
Fever	5/33	0/22	—	0.08	—
Meningism	9/33	0/22	—	<0.01	—
Confusion	9/33	2/22	2.34	0.33	0.56–10.01
Vomiting	13/33	0/22	—	<0.01	—
Photophobia	12/33	0/22	—	<0.01	—
Visual field deficit	9/33	7/22	0.80	0.77	0.25–2.61
Cranial nerve palsy	8/33	1/22	6.72	0.07	0.78–58.17
Fatigue	15/33	5/22	2.83	0.16	0.85–9.50
Asymptomatic	0/33	5/22	—	<0.01	—

proportion of the subacute group although this trend was not significant. Other cranial nerve palsies were also commonly present in both groups with a trend towards more frequent presentation in the acute group. Fatigue as a symptom at presentation was relatively common with no difference between groups. None of the acute group were asymptomatic at the time of presentation but only 5/22 of the subacute group had no symptoms at that time.

### Endocrine deficits at presentation

Table 3 details the endocrine results for those patients where the actual laboratory values were available at the time of presentation. Hyponatraemia has previously been documented as common presenting feature of pituitary apoplexy. This was present in 11/26 of the acute group in this study but also present in 2/19 of the subacute group (*P* for difference 0.02). Cortisol deficiency was diagnosed either with a 9.00 cortisol < 100 nmol/L during the acute stress or an insulin stress test or synacthen test performed at an appropriate interval. 17/26 of the acute group were cortisol deficient at the time of diagnosis compared with 8/19 of the subacute patients. Dysfunction of the pituitary/gonadal and growth hormone axes were the

most common (although this is only indicative as growth hormone deficiency was only confirmed in a small proportion of each group). Diabetes insipidus was present in a small proportion of each group although this is more frequent than the expected incidence of this condition in a population with pituitary macroadenoma. Apart from hyponatraemia at presentation, there were no significant differences in endocrine dysfunction at presentation between the groups.

### Pituitary function at follow up

Table 4 documents the endocrine function for the two groups at 5 years follow up. There had been a further deterioration in pituitary function in 3/31 of the acute group and 2/21 of the subacute group compared with the admission assessment. However, there had been an improvement in pituitary function for a larger number (acute 8/31, subacute 5/21). In two patients (one in each group), there had been an initial improvement but subsequent deterioration. One further patient in the acute group developed diabetes insipidus at follow. There were no significant differences in changes in pituitary function with time or the requirements for

**Table 3** Endocrine deficits at diagnosis.

Characteristics and outcome	Acute	Subacute	Odds ratio	P-value	CI
Proportion with low sodium	11/26	2/19	6.23	0.02	1.19–32.75
Proportion with decreased pituitary/adrenal function	17/26	8/19	2.73	0.14	0.78–9.53
Proportion with decreased pituitary/thyroid function	11/27	6/19	1.06	1.0	0.30–3.77
Proportion with decreased pituitary/gonadal function	17/24	12/18	0.71	0.74	0.18–2.73
Proportion with growth hormone < 1 ug/L	13/17	9/10	2.34	0.63	0.22–25.25
Proportion with diabetes insipidus	2/29	1/18	1.24	1.0	0.11–14.70
Proportion with low prolactin (<85 miu/L)	9/26	1/19	7.00	0.10	0.76–64.61
Proportion with a raised prolactin	3/26	7/19	0.41	0.31	0.11–1.57
Proportion requiring surgery from initial presentation	9/33	5/22	1.28	0.76	0.36–4.48

Full data were not available for each subject. Results give the total number of results as a proportion of the available results and percentage of the available results.

**Table 4** Pituitary function at follow up.

Characteristics and outcome	Acute	Subacute	Odds ratio	P-value	CI
Proportion with deterioration in anterior pituitary function	3/31	2/21	1.02	1.0	0.16–6.68
Proportion with improvement in anterior pituitary function	8/31	5/21	1.11	1.0	0.31–4.03
Proportion requiring glucocorticoid replacement	16/32	8/21	1.63	0.42	0.53–4.98
Proportion requiring thyroid replacement	15/33	9/21	1.18	0.79	0.39–3.57
Proportion requiring testosterone replacement	15/19	5/7	1.5	1.0	0.21–10.82
Proportion requiring oestrogen replacement	4/15	3/14	0.75	1	0.14–4.17
Proportion requiring desmopressin	3/31	1/19	2.04	1.0	0.20–21.07
Proportion taking dopamine agonist	3/33	4/22	0.29	0.20	0.05–1.75

pituitary hormone replacement between the acute and subacute groups.

### Pituitary imaging

Tables 5 and 6 document the MRI characteristics of the pituitary lesions at presentation and then at a mean of 5 years follow up. Although the initial imaging in some patients was CT, an MRI was performed at or shortly after presentation in all subjects. As patients have presented to a number of different hospitals at different times, the imaging protocols are not directly comparable (e.g., not all scans were given contrast or had full T2 sequences performed). The MRI characteristics of the pituitary will change quite rapidly in the days or weeks following the acute episode. There is quite marked variation in both the T1 and T2 appearances of both groups depending on the time of presentation. Mixed or high signal on T1 would appear to be a common presentation in the acute group. The T1 appearances of the subacute group are more variable at presentation. Heterogeneity in both T1 and T2 sequences is a common theme in both groups. A high proportion of the acute group show ring enhancement with contrast at presentation (14/20). This is less common in the subacute group (3/11)  $P=0.03$ . Apart from the differences in ring

enhancement, there were no significant differences in the imaging features at presentation between the two groups.

At 5 years follow up both groups show a reduction in coronal height of the pituitary lesions. This was more marked in the acute group with a reduction of 12.8 mm compared with 7.8 for the subacute group  $P=0.05$ . A higher proportion of both groups show lower T1 signal at follow up but there was no difference between the groups. Ring enhancement is a less common finding at follow up. Apart from the difference in reduction in tumour size, there were no significant differences between the two groups at follow up.

### Outcomes comparing surgical versus conservative management

The clinical decision to offer surgery to a patient presenting with pituitary haemorrhage or infarction can be difficult. The decision needs to be taken on an individual basis but visual loss is an important criterion when making the decision. The primary reason for offering surgery was a visual field defect relating to compression of the optic apparatus by the pituitary. Table 7 compares the outcomes for patients who underwent surgery compared with those that followed a conservative approach. The period of follow up was

**Table 5** MRI characteristics at presentation.

Characteristics	Acute	Sub-acute	Odds ratio	P-value	CI
Maximum coronal height, mean (s.e.)	18 (2)	17 (1)	—	0.70	—
Maximum coronal width, mean (s.e.)	20 (1)	18 (1)	—	0.20	—
T1 signal					
High	8/26	7/22	0.95	1.00	0.28–3.24
Low	0/26	4/22	2.44	0.04	1.71–3.49
Isointense	12/26	4/22	3.86	0.07	1.02–14.58
Mixed	8/26	7/22	0.95	1.00	0.28–3.24
T2 signal					
High	4/25	5/20	0.57	0.48	0.31–2.49
Low	7/25	4/20	1.56	0.73	0.38–6.31
Isointense	3/25	1/20	2.59	0.62	0.25–27.03
Mixed	11/25	10/20	0.79	0.77	0.24–2.56
T1 heterogeneous contrast enhancement	14/20	5/11	2.8	0.26	0.61–12.86
Ring enhancement	14/20	3/11	6.23	0.03	1.21–31.94



**Table 6** MRI characteristics at follow up.

Characteristics	Acute	Sub-acute	Odds ratio	P-value	CI
Years follow up, mean (s.d.)	5.2 (3.8)	5.0 (5.1)	—	0.21	—
Reduction in coronal height, mean (s.e.)	12.8 (1.0)	7.8 (1.2)	—	0.05	—
Reduction in coronal width, mean (s.e.)	10.6 (1.5)	6.9 (1.6)	—	0.23	—
T1 signal					
High	5/25	6/21	0.63	0.73	0.16–2.44
Low	5/25	4/21	1.06	0.62	0.25–4.60
Isointense	15/25	7/21	3.00	0.09	0.90–10.06
Mixed	2/25	4/21	0.37	0.39	0.06–2.26
T2 signal					
High	7/24	4/18	1.44	0.73	0.35–5.95
Low	8/24	6/18	1.07	0.59	0.29–3.92
Isointense	4/24	2/18	1.68	0.68	0.27–10.43
Mixed	4/24	6/18	0.42	0.23	0.10–1.81
T1 heterogenous contrast enhancement	6/17	1/10	4.91	0.20	0.50–48.62
Ring enhancement	5/17	0/10	1.88	0.12	1.25–6.25

significantly longer for those that underwent surgery. The acute and subacute groups were equally represented in the surgical and conservative categories. As would be expected, the surgical group had larger lesions at presentation. The surgical group showed an immediate reduction in tumour size after surgery but showed less reduction in size at further follow up compared with the group that did not have surgery. Thus a high proportion of the conservative group showed further reduction in size of the lesion with time at final follow up (29/35). A high proportion of the conservative group showed an improvement in pituitary function at follow up (12/39). This was less obvious in the surgical group although the difference did not reach statistical significance. Outcomes would appear to be generally good for the conservative group.

Comparing clinical features, endocrine deficits at presentation and follow up and imaging features at presentation and follow up, there would appear to be few differences between those presenting with an acute syndrome and those with subacute disease. The main differences being those symptoms that make patients seek urgent help. It would appear that perhaps these two groups represent the ends of a clinical symptom spectrum with considerable overlap in their presenting features and

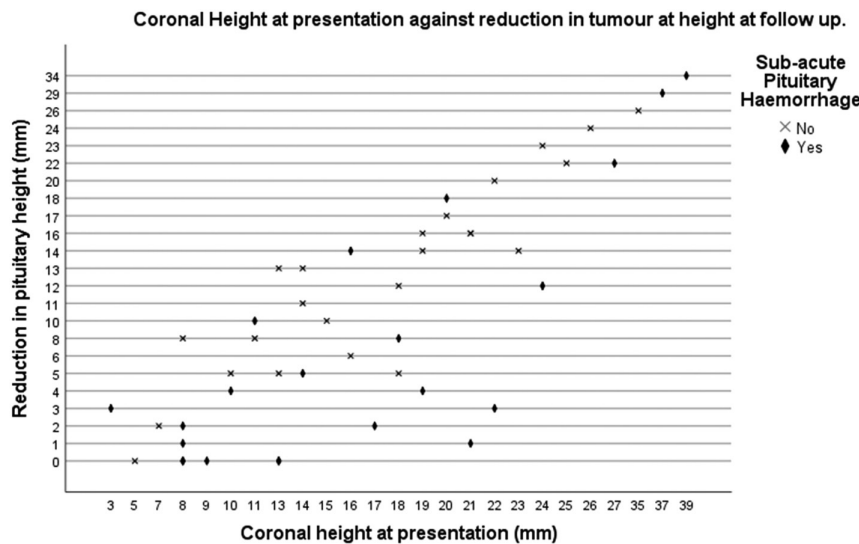
clinical course. **Figure 1** shows the initial coronal height of the two groups against the reduction in coronal height at follow up. More of the acute group were present with larger tumours but the largest tumours at presentation were actually within the subacute group demonstrating considerable overlap between the two groups.

### Discussion

Pituitary haemorrhage and infarction are rare conditions. There are relatively few descriptions of large series to guide clinical management in the modern era (1, 13, 14, 15). Large case series since the development of routine MRI of the pituitary are also limited (8). The majority of publications have focussed on those presenting with an acute clinical syndrome and have often specifically excluded those with a more subclinical presentation. We have compared a cohort of 33 patients presenting acutely (with a diagnosis of pituitary apoplexy) with 22 patients who were diagnosed with pituitary haemorrhage or infarction primarily on serial MRI images. Although there are clearly differences in the presenting symptoms, there are few differences in the demographics or risk

**Table 7** Outcomes for patients following conservative or surgical management.

Characteristics	Conservative	Surgery	Odds ratio	P-value	CI
Years follow up mean (s.d.)	5.2 (6.2)	8.9 (3.7)	—	0.05	—
Acute	24	9	1.00	0.63	0.30–3.34
Subacute	16	6			
Coronal height at presentation mm (s.d.)	14 (6)	25 (7)	—	<0.01	—
Proportion with further reduction in tumour size	29/35	4/13	10.88	0.01	2.50–47.28
Proportion with increasing tumour size	3/35	1/13	1.33	0.65	0.12–14.14
Proportion with deterioration in anterior pit function	2/39	3/13	5.55	0.09	0.81–37.88
Proportion with improvement in anterior pituitary function	12/39	1/13	0.19	0.14	0.02–1.61



**Figure 1**  
MRI coronal height at presentation against reduction in tumour height at follow up.

factors of the two groups. The endocrine and radiological features at presentation are similar. The subsequent course and radiological features at follow up are similar. It would seem reasonable to conclude that although some patients present with more acute symptoms, this is the same condition with a similar clinical course.

The median age at presentation for both groups in this study was around 50 years but with a broad spread of ages at presentation. This is similar to previous studies (15, 16). There were a higher number of men with the acute presentation and a higher number of women with subacute presentation although there was no statistical difference between groups. Although previous publications show variations in gender mix, there is a suggestion that this presentation is more common in men (2). All of the patients included in this series had presented with a pituitary macroadenoma. This is the case in most previous case series (17). The established risk factors for this condition were analysed. Prolactinoma is clearly a risk factor for this condition and the use of dopamine agonists enhances this risk. It is prudent to warn patients commencing dopamine agonists for treatment of macroprolactinoma that there is a risk of pituitary haemorrhage and that this can present either with a severe headache or milder symptoms. In previous studies looking at just acute presentations, this link has not been as clear (18). Hypertension was more common in both cohorts and was above the prevalence expected for a population of this age. Again previous studies have come to differing conclusions about the link between blood pressure and pituitary haemorrhage/ infarction (2, 19).

As would be expected there were significant differences in the presenting symptoms of the acute and

subacute groups. Severe headache is widely reported as the most common symptom of pituitary apoplexy and this was the case here (20, 21, 22). Interestingly there was a preceding headache in a significant number of patients prior to presentation in the acute group and chronic headache was also commonly present in the subacute group. Symptoms of meningeal irritation were common in the acute group and absent in the subacute group. Visual field defect was equally present in both groups and was the main indication for subsequent pituitary surgery. As visual field defect was relatively uncommon, only a small proportion in each group underwent surgery. Other cranial nerve palsies are relatively uncommon at presentation of pituitary macroadenoma without haemorrhage. This is thought to be because relatively rapid change in size is required to produce compression of structures in the wall of the cavernous sinus. This is sometimes seen with rapidly growing pituitary tumours but is also regularly reported as a consequence of pituitary apoplexy (1). Diplopia was seen in 25% of those patients in the acute group but only 5% of the subacute group. This supports the view that speed of change in tumour size may be a factor in cranial nerve palsies in the cavernous sinus or could simply mean the acute group are exerting more lateral pressure.

Low serum sodium was commonly seen in the acute group. This is likely to be a mixture of SIADH and glucocorticoid deficiency as some of those with hyponatraemia were subsequently found to have normal pituitary adrenal axis function. This was less common in the subacute group and was the only endocrine deficit that was significantly different between the two groups. Diabetes insipidus was present in two of the acute group

at presentation and three at follow up. This was present in one patient within the subacute group. There was no improvement in diabetes insipidus with time. The group with diabetes insipidus at presentation showed no improvement in endocrine function with time suggesting a worse prognosis at presentation. Most publications would suggest that endocrine outcome is generally poor in patients presenting with this condition (2, 12, 20). The data presented here would suggest that there is clinical improvement in pituitary function in about a quarter of patients in both groups. This improvement was almost entirely in those patients managed conservatively perhaps strengthening the argument for a conservative approach.

There are a number of publications describing the MRI appearances (8, 9, 17, 23, 24). It is clear from the literature that there are significant changes in the appearance of the pituitary over a very short time period in the acute setting. In the hyperacute phase (<6 h), T1 weighted imaging may be isointense but then becomes hypo and then hyperintense over the following days. In the chronic phase (>1 month), the appearances are once more variable but are often isointense. T2 weighted imaging may be iso or hyperintense in the hyperacute phase but will then often become hypointense over the next few days. Over the following weeks T2 weighted imaging will often become hyperintense. It is perhaps not surprising that the appearances of the pituitary on first imaging are varied in both groups as the imaging will have been performed at different stages in the natural history of the disease. There appear to be two general conclusions that may be helpful at presentation. The pituitary shows a heterogeneous appearance with contrast and a significant proportion will show ring enhancement. As more time may have passed before first imaging in the subacute group, these signs are less obvious. With time these features appear to resolve and were less commonly seen with follow up at 5 years. There was no difference in tumour size at presentation although the acute group showed a greater reduction in size with time (having shown a trend towards greater size at presentation).

Whether to use a conservative or surgical approach for the management of this condition is controversial. A pragmatic approach suggested by the UK guidelines for the management of pituitary apoplexy suggests that the decision should be individualised but primarily based on the presence of optic nerve compression (1). This was the approach used for this cohort. We have compared surgical and conservative treatment across the two cohorts. There was no significant difference in the proportions of the acute and subacute groups that underwent surgery. The surgical group showed greater reduction in tumour size overall

(although there was also a clinically significant reduction in the conservative group). The surgical group had shown larger tumours before surgery. There was a trend towards more improvement in pituitary function in the conservative group however, it would seem that this group have less severe disease and it is difficult to draw firm conclusions.

A significant weakness of the paper is the size of the cohort. A larger study may be able to show more subtle differences between the two groups studied although this may not be clinically relevant. This is a problem with most of the published evidence for this condition. There is likely to be reporting bias in this paper as less severe disease is likely to be missed. It is possible that there is a further cohort of patients with smaller pituitary lesions at presentation who are entirely asymptomatic and may possibly have a more benign cohort. A further weakness of the paper is including patients with other conditions that may mimic pituitary haemorrhage or infarction. We have tried to reduce this by only including patients that had objective change in the pituitary imaging appearances over a short period of time. This increases the confidence that patients included have the correct condition but we have potentially excluded a cohort that had this disease but did not show a change in pituitary appearance with time. The gold standard would be to have histopathological proof of haemorrhage/ infarction but this would not be possible for a condition that often does not require surgery. We have not been able to answer any of the continuing controversies in the management of this condition as this would require a randomised trial. This is difficult to perform with this rare condition.

In conclusion not all patients that are subsequently diagnosed as having undergone pituitary haemorrhage or infarction present acutely. Those that present less acutely seem to show a similar clinical course. Optimistically a significant proportion of both groups studied showed an improvement in pituitary appearance and function with time.

---

#### Declaration of interest

The authors declare that there is no conflict of interest that could be perceived as prejudicing the impartiality of the research reported.

---

#### Funding

This research did not receive any specific grant from any funding agency in the public, commercial or not-for-profit sector.

---

#### Data availability statement

The data that support the findings of this study are available on request from the corresponding author. The data are not publicly available due to privacy or ethical restrictions.



## References

- Rajasekaran S, Vanderpump M, Baldeweg S, Drake W, Reddy N, Lanyon M, Markey A, Plant G, Powell M, Sinha S, *et al.* UK guidelines for the management of pituitary apoplexy. *Clinical Endocrinology* 2011 **74** 9–20. (<https://doi.org/10.1111/j.1365-2265.2010.03913.x>)
- Abbara A, Clarke S, Eng PC, Milburn J, Joshi D, Comminos AN, Ramli R, Mehta A, Jones B, Wernig F, *et al.* Clinical and biochemical characteristics of patients presenting with pituitary apoplexy. *Endocrine Connections* 2018 **23** 1058–1066. (<https://doi.org/10.1530/EC-18-0255>)
- Brougham M, Heusner AP & Adams RD. Acute degenerative changes in adenomas of the pituitary body--with special reference to pituitary apoplexy. *Journal of Neurosurgery* 1950 **7** 421–439. (<https://doi.org/10.3171/jns.1950.7.5.0421>)
- Bills DC, Meyer FB, Laws ER Jr, Davis DH, Ebersold MJ, Scheithauer BW, Ilstrup DM & Abboud CF. A retrospective analysis of pituitary apoplexy. *Neurosurgery* 1993 **33** 602–608; discussion 8–9. (<https://doi.org/10.1227/00006123-199310000-00007>)
- Sibal L, Ball SG, Connolly V, James RA, Kane P, Kelly WF, Kendall-Taylor P, Mathias D, Perros P, Quinton R, *et al.* Pituitary apoplexy: a review of clinical presentation, management and outcome in 45 cases. *Pituitary* 2004 **7** 157–163. (<https://doi.org/10.1007/s11102-005-1050-3>).
- Baldeweg SE, Vanderpump M, Drake W, Reddy N, Markey A, Plant GT, Powell M, Sinha S, Wass J & Society for Endocrinology Clinical Committee. Society for Endocrinology: endocrine Emergency Guidance: emergency management of pituitary apoplexy in adult patients. *Endocrine Connections* 2016 **5** G12–G15. (<https://doi.org/10.1530/EC-16-0057>)
- Yang CW & Fuh JL. Thunderclap headache: an update. *Expert Review of Neurotherapeutics* 2018 **18** 915–924. (<https://doi.org/10.1080/14737175.2018.1537782>)
- Bashari WA, Senanayake R, Fernández-Pombo A, Gillett D, Koulouri O, Powlson AS, Matys T, Scoffings D, Cheow H, Mendichovszky I, *et al.* Modern imaging of pituitary adenomas. *Best Practice & Research. Clinical Endocrinology & Metabolism* 2019 **33** 101278. (<https://doi.org/10.1016/j.beem.2019.05.002>)
- Piotin M, Tampieri D, Rüfenacht DA, Mohr G, Garant M, Del Carpio R, Robert F, Delavelle J & Melanson D. The various MRI patterns of pituitary apoplexy. *European Radiology* 1999 **9** 918–923. (<https://doi.org/10.1007/s003300050767>)
- Ayuk J, McGregor EJ, Mitchell RD & Gittoes NJ. Acute management of pituitary apoplexy--surgery or conservative management? *Clinical Endocrinology* 2004 **61** 747–752. (<https://doi.org/10.1111/j.1365-2265.2004.02162.x>)
- Gruber A, Clayton J, Kumar S, Robertson I, Howlett TA & Mansell P. Pituitary apoplexy: retrospective review of 30 patients--is surgical intervention always necessary? *British Journal of Neurosurgery* 2006 **20** 379–385. (<https://doi.org/10.1080/02688690601046678>)
- Goshtasbi K, Abiri A, Sahyouni R, Mahboubi H, Raefsky S, Kuan EC, Hsu FPK & Cadena G. Visual and endocrine recovery following conservative and surgical treatment of pituitary apoplexy: a meta-analysis. *World Neurosurgery* 2019 **132** 33–40. (<https://doi.org/10.1016/j.wneu.2019.08.115>)
- Randeva HS, Schoebel J, Byrne J, Esiri M, Adams CB & Wass JA. Classical pituitary apoplexy: clinical features, management and outcome. *Clinical Endocrinology* 1999 **51** 181–188. (<https://doi.org/10.1046/j.1365-2265.1999.00754.x>)
- Leyer C, Castinetti F, Morange I, Gueydan M, Oliver C, Conte-Devolx B, Dufour H & Brue T. A conservative management is preferable in milder forms of pituitary tumor apoplexy. *Journal of Endocrinological Investigation* 2011 **34** 502–509. (<https://doi.org/10.3275/7241>)
- Semple PL, Jane JA, Lopes MB & Laws ER. Pituitary apoplexy: correlation between magnetic resonance imaging and histopathological results. *Journal of Neurosurgery* 2008 **108** 909–915. (<https://doi.org/10.3171/JNS/2008/108/5/0909>)
- Bonicki W, Kasperlik-Zaluska A, Koszewski W, Zgliczyński W & Wislawski J. Pituitary apoplexy: endocrine, surgical and oncological emergency. Incidence, clinical course and treatment with reference to 799 cases of pituitary adenomas. *Acta neurochirurgica* 1993 **120** 118–122. (<https://doi.org/10.1007/BF02112028>)
- Goyal P, Utz M, Gupta N, Kumar Y, Mangla M, Gupta S & Mangla R. Clinical and imaging features of pituitary apoplexy and role of imaging in differentiation of clinical mimics. *Quantitative Imaging in Medicine and Surgery* 2018 **8** 219–231. (<https://doi.org/10.21037/qims.2018.03.08>)
- Ghadirian H, Shirani M, Ghazi-Mirsaeed S, Mohebi S & Alimohamadi M. Pituitary apoplexy during treatment of prolactinoma with cabergoline. *Asian Journal of Neurosurgery* 2018 **13** 93–95. (<https://doi.org/10.4103/1793-5482.181130>)
- Möller-Goede DL, Brändle M, Landau K, Bernays RL & Schmid C. Pituitary apoplexy: re-evaluation of risk factors for bleeding into pituitary adenomas and impact on outcome. *European Journal of Endocrinology* 2011 **164** 37–43. (<https://doi.org/10.1530/EJE-10-0651>)
- Bujawansa S, Thondam SK, Steele C, Cuthbertson DJ, Gilkes CE, Noonan C, Bleaney CW, Macfarlane IA, Javadpour M & Daousi C. Presentation, management and outcomes in acute pituitary apoplexy: a large single-centre experience from the United Kingdom. *Clinical Endocrinology* 2014 **80** 419–424. (<https://doi.org/10.1111/cen.12307>)
- Liu ZH, Chang CN, Pai PC, Wei KC, Jung SM, Chen NY & Chuang CC. Clinical features and surgical outcome of clinical and subclinical pituitary apoplexy. *Journal of Clinical Neuroscience* 2010 **17** 694–699. (<https://doi.org/10.1016/j.jocn.2009.11.012>)
- Li JL & Yu CJ. The diagnosis and therapy of subclinical pituitary adenoma apoplexy. *Zhonghua Wai Ke Za Zhi* 2005 **43** 879–881.
- Glick RP & Tiesi JA. Subacute pituitary apoplexy: clinical and magnetic resonance imaging characteristics. *Neurosurgery* 1990 **27** 214–218; discussion 8–9.
- Vaphiades MS. Pituitary ring sign plus sphenoid sinus mucosal thickening: neuroimaging signs of pituitary apoplexy. *Neuro-Ophthalmology* 2017 **41** 306–309. (<https://doi.org/10.1080/01658107.2017.1349807>)

Received in final form 16 December 2020

Accepted 6 January 2021

Accepted Manuscript published online 8 January 2021