



Contents lists available at ScienceDirect

International Journal of Surgery Case Reports

journal homepage: www.casereports.com

A rare etiology of acute abdominal syndrome in adults: Gastric volvulus – Cases series



Fatih Altintoprak^{a,*}, Omer Yalkin^b, Enis Dikicier^b, Taner Kivilcim^b, Yusuf Arslan^b, Yasemin Gunduz^c, Orhan Veli Ozkan^a

^a Sakarya University, Faculty of Medicine, Department of General Surgery, Turkey

^b Sakarya University, Research and Educational Hospital, Department of General Surgery, Turkey

^c Sakarya University, Faculty of Medicine, Department of Radiology, Turkey

ARTICLE INFO

Article history:

Received 16 December 2013

Received in revised form 13 August 2014

Accepted 22 August 2014

Available online 30 August 2014

Keywords:

Acute abdomen syndrome

Volvulus

Gastric volvulus

ABSTRACT

INTRODUCTION: Gastric volvulus is a rare surgical emergency with a high mortality rate that requires urgent surgical management.

PRESENTATION OF CASE: A 19-year-old male and 51-year-old female patient underwent emergency surgery with a prediagnosis of acute abdomen syndrome, and a 60-year-old female patient underwent elective surgery due to diaphragmatic hernia. Abdominal exploration revealed gastric volvulus together with perforation in received emergency surgery patients, and a mesenteroaxial gastric volvulus due to diaphragmatic defect in third patient.

DISCUSSION: Gastric volvulus is classified into four subgroups depending on the mechanism of development, and organoaxial form is the most common type of gastric volvulus. The most challenging step in diagnosing gastric volvulus is the consideration of this diagnosis.

CONCLUSION: Preoperative diagnosis is often difficult, and its management involves surgical correction of the pathology followed by institution of resuscitative treatment.

© 2014 The Authors. Published by Elsevier Ltd. on behalf of Surgical Associates Ltd. This is an open access article under the CC BY-NC-SA license (<http://creativecommons.org/licenses/by-nc-sa/3.0/>).

1. Introduction

Gastric volvulus is a rare surgical emergency defined as an abnormal rotation of the stomach of more than 180°. The incidence of gastric volvulus is unknown. It may present as an acute abdomen secondary to rapidly developing strangulation, incarceration, and perforation.¹ There are no specific clinical or laboratory findings, and the diagnosis is usually established intraoperatively. Preoperative radiologic diagnosis of gastric volvulus is extremely difficult and requires experience. This case series presents three cases of gastric volvulus (two idiopathic and one secondary) and serves as a review of the contemporary literature on gastric volvulus.

2. Case reports

2.1. Case 1

A 19-year-old male patient was referred to our clinic with a prediagnosis of acute abdominal syndrome. The patient was intubated on admission. The medical history obtained from the family

was remarkable for mental retardation and congenital deafness. Six hours prior to admission to our center, the patient had presented to another clinic with a sudden onset of severe abdominal pain and vomiting. On admission to the intensive care unit at our clinic, the patient was intubated, his blood pressure was very low (unrecordable), and his peripheral pulses were thready. Physical examination showed extensive abdominal distention, and his laboratory findings were unremarkable other than leukocytosis (21,000/mm³). Abdominal computed tomography (CT) scans initially revealed extensive free air and fluid within the abdomen. A review of the CT scans confirmed the presence of free air and fluid, but the appearance was consistent with an extensively enlarged visceral organ (Fig. 1a). The patient underwent emergency surgery under rapid intravenous (IV) parenteral fluid resuscitation and positive inotropic support (dopamine, 10 µg/kg). Abdominal exploration revealed ~5000 mL of free fluid. The retained gastric content was discharged, and the stomach was found to be extensively enlarged and rotated around the greater and lesser curvatures (mesenteroaxial volvulus); a 6–7-cm perforation site was also observed in the fundus (Fig. 1b). The stomach was detorsioned, and the perforated site was surgically repaired. The operation lasted ~90 min, and the patient was moved to the surgical intensive care unit while intubated. During his stay in the intensive care unit, hypotension persisted despite parenteral

* Corresponding author. Tel.: +90 5335483415.

E-mail address: fatihaltintoprak@yahoo.com (F. Altintoprak).

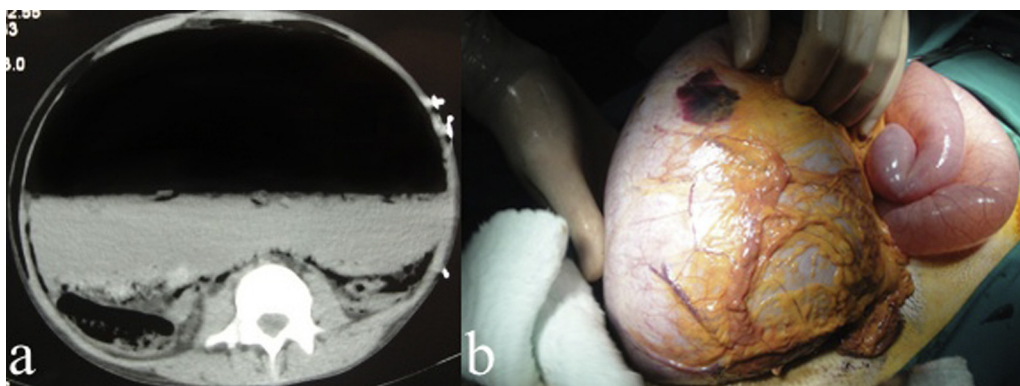


Fig. 1. (a) Abdominal CT; intraabdominal free air and fluid with extensively enlarged stomach. (b) operative view; extensively enlarged stomach.

fluid replacement and inotropic support. The patient died after 8 h.

2.2. Case 2

A 50-year-old female patient with a known history of congenital deafness and epilepsy was admitted to the emergency service due to sudden-onset and gradually increasing abdominal pain and vomiting that began 12 h previously. Her blood pressure on admission was 80/50 mmHg, pulse was 110 rpm, and physical examination revealed extensive abdominal distention (Fig. 2a). Laboratory examinations were not remarkable other than leukocytosis ($34,000/\text{mm}^3$). Attempts to install a nasogastric tube failed. Abdominal CT scans showed extensive free air and fluid within the abdomen and an extensively enlarged stomach that rotated around the axis of the lesser–greater curvature (Fig. 2b). Because the patient had a history and radiologic findings similar to those of the previous case, she underwent emergency surgery with a prediagnosis of perforation due to gastric volvulus. During the abdominal exploration, the stomach was found to be rotated 180° around the axis of the greater–lesser curvature, and a 3-cm perforation site was observed in the lesser curvature. The stomach was detorsioned, the perforation site was surgically repaired, and an omentoplasty was performed. During the follow-up in the intensive care unit, the patient suffered from acute abdomen on the fifth postoperative day, and a second laparotomy was performed. Exploration revealed multiple perforations (five perforations, 1 cm apart) in the jejunal segment 90 cm proximal to the ileocecal valve. The etiology was speculated to be associated with the development of microemboli. A segmental jejunal resection and end jejunostomy

were performed, and the abdomen was closed with a Bogota bag. On the sixth postoperative day following the second operation, the patient redeveloped acute abdomen. Exploration revealed multiple new perforations (three perforations in a 20-cm-long area) in a jejunal segment 30 cm proximal to the previous perforation site. Segmental jejunal resection and end jejunostomy were performed again. The patient died on day 32 of follow-up in the intensive care unit.

2.3. Case 3

A 60-year-old female patient was admitted to the emergency service due to severe nausea and vomiting for the previous week and the inability to urinate for the previous day. The patient was admitted to the nephrology clinic because the initial assessment showed hypochloremic metabolic acidosis and acute renal failure. Her past history was not remarkable for major trauma or abdominal intervention. Conventional abdominal X-ray images were consistent with eventration of the right diaphragm and a diaphragmatic hernia (Fig. 3), and thoracoabdominal CT revealed a right diaphragmatic hernia (Fig. 4a and b). The patient underwent elective surgery after preoperative preparation, and abdominal exploration revealed a diaphragmatic defect ($8\text{ cm} \times 5\text{ cm}$ in size) through which the omentum was herniated into the thorax, causing a mesenteroaxial gastric volvulus. The omentum was reduced into the abdomen, the stomach was detorsioned, and the diaphragmatic defect was primarily repaired. The clinical and laboratory findings returned to normal, oral intake was allowed on day 2, and the patient was discharged on postoperative day 4. The patient has been monitored for the past 6 months with no further problems.

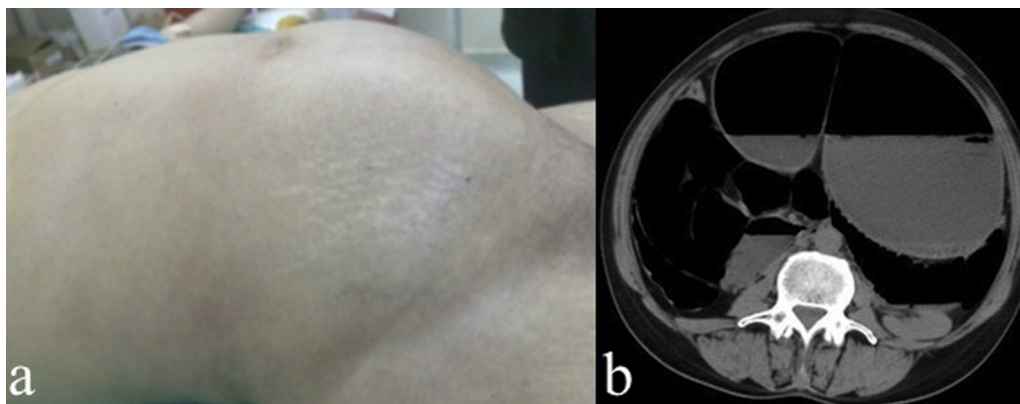


Fig. 2. (a) Preoperative abdominal distention. (b) Abdominal CT; the stomach: severe dilated and volvulus axis where located at the distal 1/3 part.

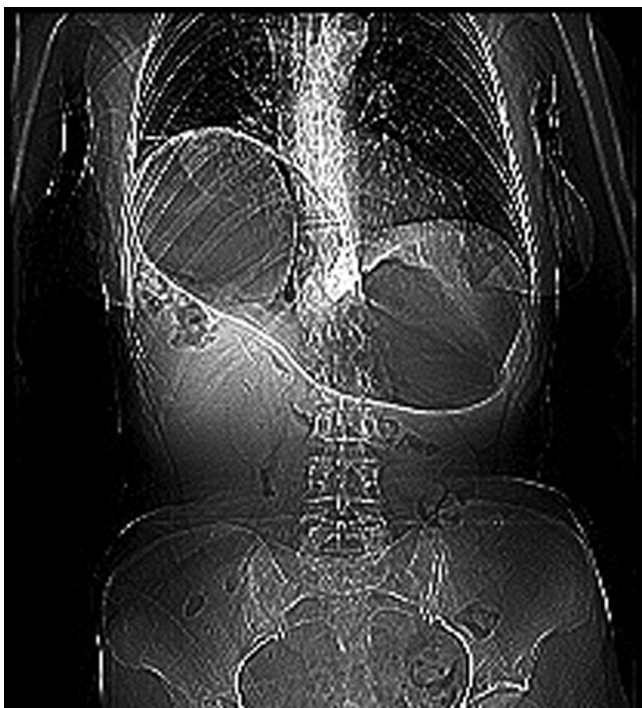

Fig. 3. Abdominal X-ray image; eventration of the right diaphragm and a diaphragmatic hernia.

3. Discussion

Gastric volvulus is defined as rotation of the stomach around its short or long axis. A surgical emergency occurs if the rotation causes a gastric outlet obstruction or compromises the blood supply to the stomach. It has the same incidence in all races and shows a balanced female-to-male ratio. The literature reports that the clinical picture is usually accompanied by hiatal hernia, left diaphragmatic eventration, pyloric stenosis, intra-abdominal adhesions, and other intra-abdominal pathologies.² The condition is defined as idiopathic gastric volvulus in the absence of other accompanying pathologies, and this type is seen more rarely than secondary gastric volvulus. Two of the present cases (Cases 1 and 2) were classified as idiopathic gastric volvulus; the other case (Case 3) was classified as secondary gastric volvulus.

Gastric volvulus is classified into four subgroups depending on the mechanism of development.³ Type 1 (organoaxial form): This form results from rotation of the stomach around the pylorus–cardia axis. This is the most common type of

gastric volvulus. It may cause obstruction in the gastroesophageal junction, pylorus, or both and accounts for 59% of cases. Type 2 (mesenteroaxial form): This form occurs as a result of rotation of the stomach around the lesser–greater curvature axis. Gastrosplenic ligament laxity in particular is a predisposing factor.⁴ Type 3 (combined form): This is the least common form and accounts for 2% of cases. Type 4 (unclassified form): This form accounts for approximately 10% of cases. The organoaxial form (Type 1) is mostly seen in middle-aged to elderly individuals, whereas the mesenteroaxial form (Type 2) is mostly seen in childhood. All three patients in this report had Type 2 (mesenteroaxial) gastric volvulus.

Gastric volvulus may present with findings of acute abdomen syndrome or chronic gastrointestinal symptoms. Symptoms on admission can vary depending on the patient age, disease progression rate, degree of rotation, and presence of obstruction–strangulation or perforation. The coexistence of epigastric pain, vomiting, and failure to install a nasogastric tube is known as Borchardt's triad and is useful in the diagnosis of gastric volvulus.⁵ However, approximately three-fourths of affected patients may manifest classic Borchardt's triad, whereas the remaining one-fourth may not. All patients in the current study suffered from abdominal pain and vomiting. The patients with idiopathic gastric volvulus (Cases 1 and 2) had sudden-onset complaints, and a nasogastric tube could not be installed in the second case (Case 2). We were unable to evaluate this nasogastric sign in the first case (Case 1) due to the fact that the patient was intubated on admission. A nasogastric tube was installed successfully in the third case (Case 3).

The most challenging step in diagnosing gastric volvulus is the consideration of this diagnosis. Although the esophagus–stomach–duodenum passage images with barium contrast and CT scans of the upper abdomen may aid in the diagnosis of gastric volvulus,⁶ accurate diagnosis, particularly in cases of sudden onset, requires advanced clinical and radiologic experience. In the retrospective review of the abdominal CT scans in the first case (Case 1), the radiologic appearance was typical of gastric volvulus. However, the diagnosis of gastric volvulus was not immediately considered because it is a very rare clinical entity. In the second patient with idiopathic gastric volvulus (Case 2), the history and radiologic findings resembled those of the first case. More importantly, the case was evaluated by the same surgeon and radiologists as in Case 1; therefore, the possibility of gastric volvulus was taken into consideration. In the last case (Case 3), the diagnosis of gastric volvulus was based on perioperative findings and not on radiologic findings.

The development of necrosis and perforation of the stomach wall is uncommon due to the rich blood supply of the stomach and

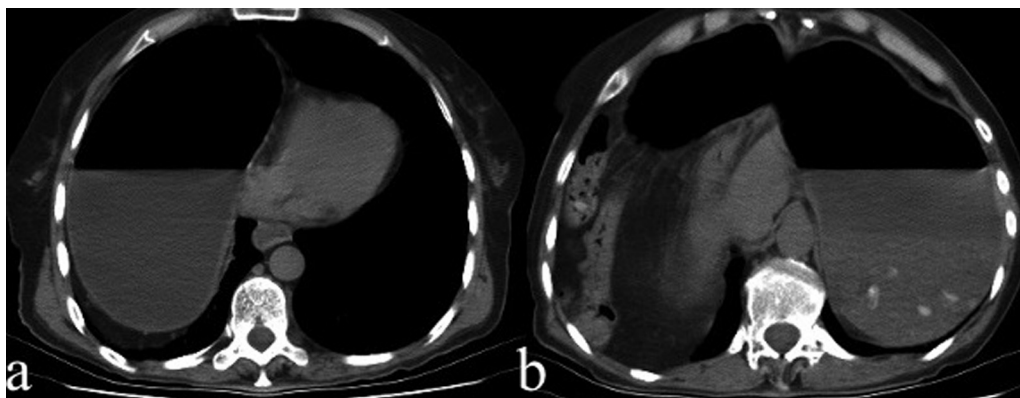


Fig. 4. Abdominal CT; thoracic herniated part of the stomach (a) and remaining part of the stomach in the abdomen (b).

the presence of strong collateral circulation.⁷ However, the presence of strangulation and perforation has been associated with high mortality rates (60%).⁸ The management of gastric volvulus involves surgery.^{9,10} The surgical approach in sudden-onset gastric volvulus is detorsion and fixation. Partial or total gastrectomy can be performed if ischemic injury exists. The first and second cases presented with acute abdominal syndrome and shock, and detorsion was thus performed, the perforation site was repaired in accordance with the principles of damage-control surgery, and the patients were moved to the intensive care unit upon the completion of surgery.

Chronic gastric volvulus is also treated surgically, and the surgical method involves detorsion of the stomach and fixation through an open or laparoscopic approach. Other pathologies accompanying chronic gastric volvulus can be simultaneously repaired.

In conclusion, the fact that gastric volvulus may be associated with a high mortality rate despite its rare occurrence should be kept in mind. Preoperative diagnosis is usually not possible, and its management involves surgical correction of the pathology followed by institution of resuscitative treatment.

Conflict of interest

The authors declare that they have no conflict of interest.

Funding

None.

Ethical approval

We have obtained written consent from the patient (in case 3) and relatives' (in cases 1 and 2) for publication of this case report and accompanying images

Author contributions

Fatih Altintoprak and Omer Yalkin contributed to study design. Enis Dikicier, Taner Kivilcim, Yusuf Arslan and Yasemin Gunduz contributed to data collection. Fatih Altintoprak, Omer Yalkin and Orhan Veli Ozkan contributed to data analysis. Fatih Altintoprak and Omer Yalkin contributed to writing.

Key learning points

- A real emergency surgical cases.
- Emergency surgery decision.
- Intraoperative management.

References

1. Wasselle JA, Norman L. Acute gastric volvulus: pathogenesis, diagnosis, and treatment. *Am J Gastroenterol* 1993;**88**(10):1780–4.
2. Chau B, Dufel S. Gastric volvulus. *Emerg Med J* 2007;**24**(6):446–7.
3. Lee TC, Liu KL, Lin MT, Wang HP. Unusual cause of emesis in an octogenarian: organoaxial gastric volvulus associated with paraesophageal diaphragmatic hernia. *J Am Geriatr Soc* 2006;**54**(3):555–7.
4. Luk SY, Fung KH. Twists and turns in the body: an imaging spectrum. *Hong Kong Med J* 2010;**16**(5):390–6.
5. Germanos S, Gourgiotis S, Saedon M, Lapatsanis D, Salemis NS. Severe abdominal pain as a result of acute gastric volvulus. *Int J Emerg Med* 2010;**3**(1):61–2.
6. Peterson CM, Anderson JS, Hara AK, Carezza JW, Menias CO. Volvulus of the gastrointestinal tract: appearances at multimodality imaging. *Radiographics* 2009;**29**(5):1281–93.
7. Aydin M, Yasar M, Aslaner A, Yazici B, Ertas E. Volvulated paraesophageal gastric herniation with perforation into bursa omentalis: report of a case. *Acta Chir Belg* 2006;**106**(2):257–60.
8. Haas O, Rat P, Christophe M, Friedman S, Favre JP. Surgical results of intrathoracic gastric volvulus complicating hiatal hernia. *Br J Surg* 1990;**77**(12):1379–81.
9. Singham S, Sounness B. Mesenteroaxial volvulus in an adult: time is of the essence in acute presentation. *Biomed Imaging Interv J* 2009;**5**(3):e18. <http://dx.doi.org/10.2349/bij.5.3.e18>.
10. Lesquereux-Martinez L, Macias-Garcia F, Ferreiro R, Martinez-Castro J, Gamborino-Carames E, Beiras-Torrado A. Acute gastric volvulus: a surgical emergency. *Rev Esp Enferm Dig* 2011;**103**(4):219–20.

Open Access

This article is published Open Access at sciedirect.com. It is distributed under the [IJSCR Supplemental terms and conditions](#), which permits unrestricted non commercial use, distribution, and reproduction in any medium, provided the original authors and source are credited.