

Long-standing chin-augmenting costochondral graft creating a diagnostic challenge: A case report and literature review

Fatma Fayeze Badr^{1,*}, Mark Mintline², Axel Ruprecht¹, Donald Cohen², Barton R. Blumberg³,
Madhu K. Nair¹

¹Department of Oral and Maxillofacial Diagnostic Sciences, Oral and Maxillofacial Radiology, College of Dentistry, University of Florida, Gainesville, FL, USA

²Department of Oral and Maxillofacial Diagnostic Sciences, Oral and Maxillofacial Pathology, College of Dentistry, University of Florida, Gainesville, FL, USA

³Barton Blumberg, DMD Oral and Maxillofacial Surgery Center, The Villages, FL, USA

ABSTRACT

To our knowledge, the imaging features of costochondral grafts (CCGs) on cone-beam computed tomography (CBCT) have not been documented in the literature. We present the case of a CCG in the facial soft tissue to the anterior mandible, with changes mimicking a cartilaginous neoplasm. This is the first report to describe the CBCT imaging features of a long-standing graft in the anterior mandible. Implants or grafts may be incidental findings on radiographic images made for unrelated purposes. Although most are well-defined and radiographically homogeneous, being of relatively inert non-biological material, immune reactions to some grafts may stimulate alterations in the appearance of surrounding tissues. Biological implants may undergo growth and differentiation, causing their appearance to mimic neoplastic lesions. We present the case of a cosmetic autogenous CCG that posed a diagnostic challenge both radiographically and histopathologically. (*Imaging Sci Dent* 2016; 46: 279-84)

KEY WORDS: Cone-Beam Computed Tomography; Mandibular Reconstruction; Genioplasty

Oculo-auriculo-vertebral spectrum (OAVS) represents a collection of anomalies due to the dysmorphogenesis of the first and second branchial arches, and incorporates Goldenhar syndrome and hemifacial microsomia.¹⁻³ It has been suggested that these two conditions represent different manifestations of a similar error in morphogenesis.⁴ Although the etiology of this spectrum is uncertain, animal models have suggested that OAVS is due to a disruption in the vascular supply to the first and second branchial arches.⁵ The most prominent features of the spectrum related to the head and neck are aural, oral, and mandibular anomalies including, but not limited to, facial asymmetry, cleft lip, cleft palate, microtia, accessory tra-

gus, epibulbar dermoid, parotid gland agenesis, and dental malocclusion.⁶ Cosmetic and reconstructive surgery, including soft tissue implants or grafts, is often indicated to address these facial abnormalities.

An implant is defined as “an object or material inserted or grafted into the body for prosthetic, therapeutic, diagnostic, or experimental purposes,” and a graft as “any tissue or organ [used] for implantation or transplantation.”⁷ Facial implant materials that have been used for soft tissue contouring include silicon rubber (SilasticTM), expanded polytetrafluoroethylene (Gore-Tex[®]), polytetrafluoroethylene (TeflonTM), porous polyethylene (Medpor[®]), and hydroxyapatite.⁸ Among the most successful and commonly used grafts in maxillofacial reconstruction are autogenous costochondral grafts (CCGs), which were introduced by Gillies in 1920.⁹⁻¹⁵

CCGs are most commonly used for mandibular condyle and ramus reconstruction, due to their biological and mor-

Received May 18, 2016; Revised July 13, 2016; Accepted July 24, 2016

*Correspondence to : Dr. Fatma Fayeze Badr
Oral and Maxillofacial Radiology, Oral and Maxillofacial Diagnostic Sciences, College of Dentistry, University of Florida, 1395 Center Drive, Gainesville, FL 32610, USA
Tel) 1-352-273-6697, Fax) 1-352-294-5311, E-mail) fbadr@dental.ufl.edu

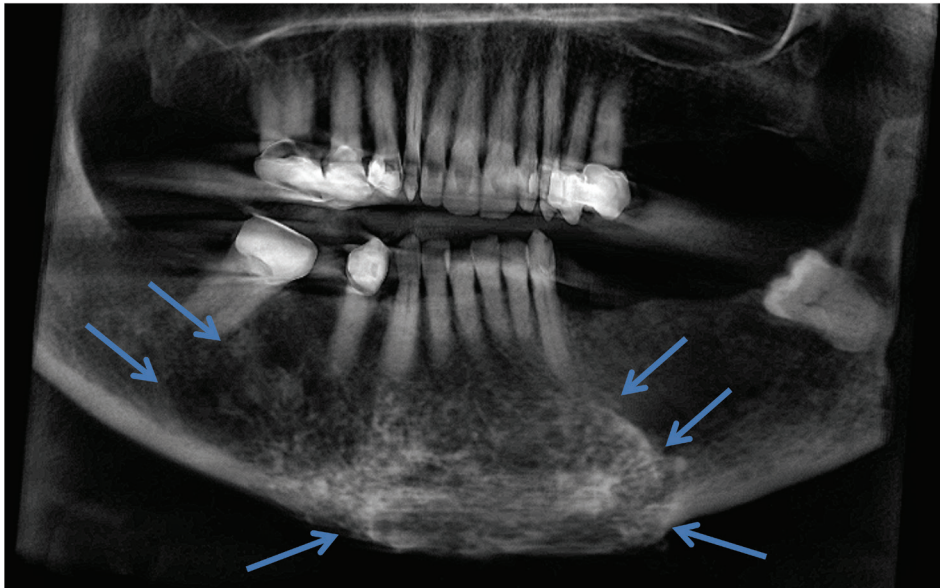


Fig. 1. A panoramic reconstructed cone-beam computed tomographic image shows the extent of the lesion from the mandibular left premolar area to the mesial aspect of mandibular right third molar, and from the level of the root apices through the inferior border of the mandible.

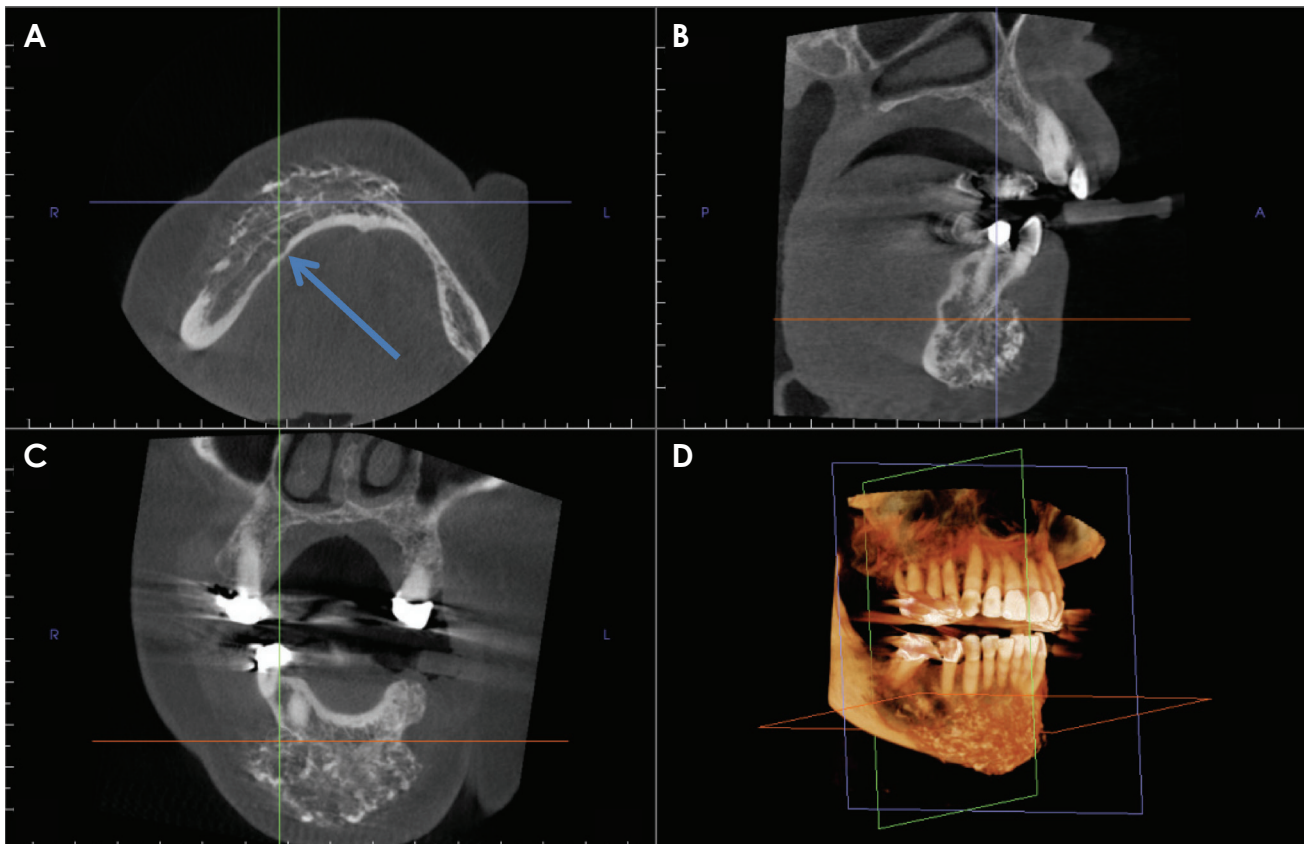


Fig. 2. Multiplanar reconstruction images such as axial (A), sagittal (B), coronal (C), and 3-dimensional reconstruction (D) images show the heterogeneously radiopaque mass in the chin area. Note the effacement of the labial cortical plate and the altered jaw morphology. The lingual cortical plate is thinned in one area (arrow).

phological resemblance to the mandibular condyle. The growth potential of these grafts is substantial, and can be unpredictable.⁹ Unfavorable growth, fractures, and rean-

kylosis of the mandibular condyle are well-documented complications of this type of graft.⁹ The overgrowth can be attributed to the primary cartilage in CCGs, which acts

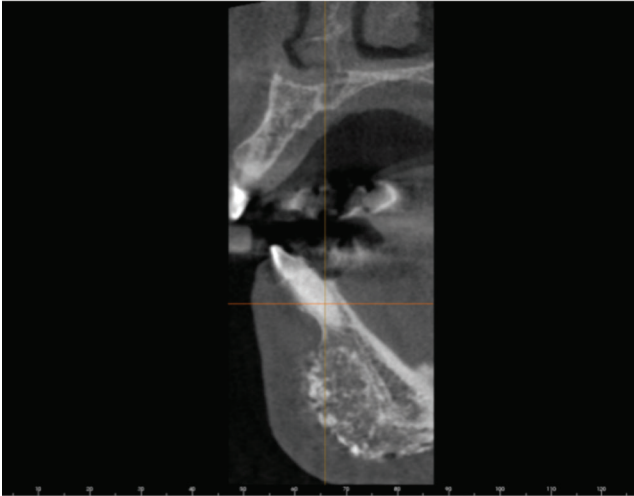


Fig. 3. A cross-sectional (orthoradial) image through the right parasymphiseal region of the mandible shows the heterogeneity of the mass. Multiple small radiopaque masses suggestive of a cartilaginous neoplasm are present.

as a growth center. In addition, the size of the cartilaginous cap, degree of physiologic function, and hormonal influences may play a role in the incidence and degree of overgrowth. It is uncertain whether these grafts grow as a result of inherent or adaptive growth, or a combination of both processes.⁹ Autogenous CCGs have also been used as cosmetic grafts. They are subject to the same patterns of growth and overgrowth.

We present the case of a cosmetic autogenous CCG that posed a diagnostic challenge both radiographically and histopathologically. To our knowledge, the imaging features of such grafts on cone-beam computed tomography (CBCT) have not been documented in the literature.

Case Report

An 81-year-old female with OAVS presented to a general dentist for a dental implant consultation. Her medical history was remarkable for an epibulbar dermoid and previous grafting of an anterior mandibular defect at the age of 16. The patient was asymptomatic. After a routine examination, the patient was referred to an oral and maxillofacial surgeon for implant treatment planning. The surgeon requested a maxillofacial CBCT scan extending from the level of the nasal fossa through the inferior border of the mandible, and from the anterior border of one ramus to the anterior border of the contralateral ramus.

Upon radiographic examination, the bilateral paramedian area of the mandible appeared abnormally heteroge-

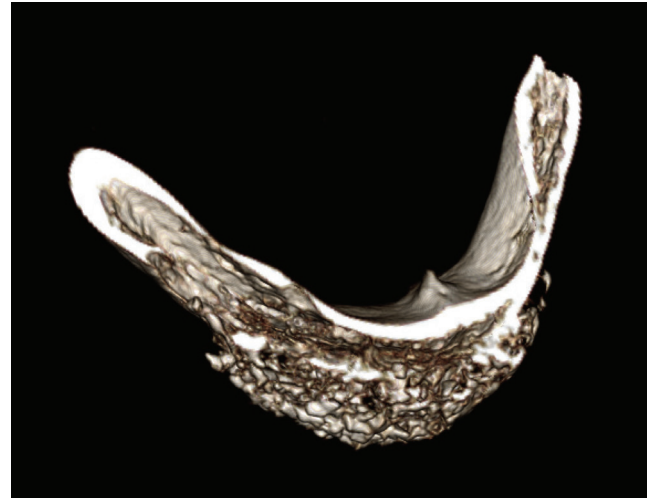

Fig. 4. A 3-dimensional volumetric rendering image reveals the mixed radiopaque and radiolucent appearance of the chin area, consistent with the appearance in Figure 3.

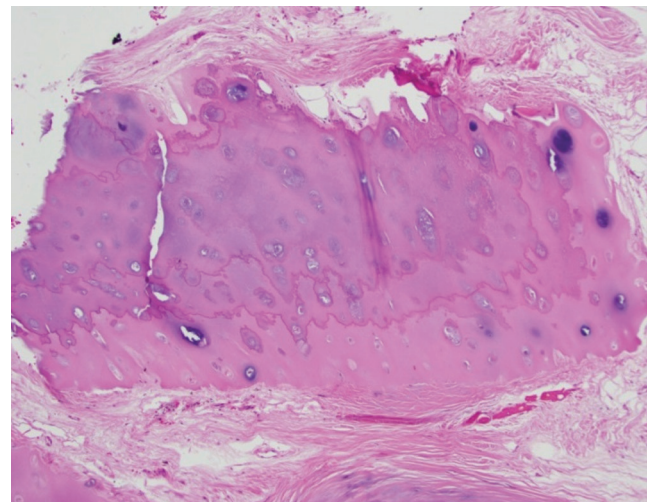


Fig. 5. A photomicrograph shows benign hyaline cartilage and adherent fibrosis (H&E stain, original magnification $\times 100$).

neous with a poorly defined border on the right. The mandibular canals anterior to the right second molar and the left mental foramen were untraceable (Fig. 1). Multiplanar reconstructions revealed a large, heterogeneous, expansile entity of mixed density along the facial side of the mandible, extending from the mandibular left premolar area to the mesial aspect of the mandibular right third molar, and from the level of the root apices through the inferior border of the mandible. Thinning of the lingual cortical plate was noted in some areas (Fig. 2). Effacement of the facial cortical plate without an effect on the neighboring teeth was observed (Fig. 3). Three-dimensional volume render-

ing depicted the considerable size of the entity in question (Fig. 4). A cartilaginous neoplasm could not be ruled out based on CBCT imaging and an incisional osseous biopsy was therefore performed.

Hematoxylin and eosin-stained slides prepared after formalin fixation and decalcification were reviewed (Fig. 5). Multiple fragments of benign and hypocellular cartilage with adherent fibrous tissue were present. No osseous-cartilaginous integration could be detected from the limited sample. The appearance was consistent with normal cartilage.

Discussion

Growth or overgrowth is a recognized sequela of CCGs. Almost all patients that seek corrective surgery following CCG overgrowth in the mandibular body or condyle present with facial asymmetry. This happens even when the grafts are placed bilaterally due to their unpredictable growth potential. For a definitive diagnosis to be made, radiographic examination followed by a histopathological evaluation is indicated.⁹

Most of the published cases of CCG overgrowth in the mandible were described radiographically using panoramic images and/or multi-detector computed tomography (MDCT).^{10,11,14-18} Yang et al.⁹ reviewed 68 cases of CCG overgrowth in the maxillofacial region. The authors described a case of overgrowth of a CCG that replaced the right mandibular body using panoramic, lateral cephalometric, and posteroanterior skull radiographs, and MDCT. None of the radiographs demonstrated asymmetry due to the inherent limitations of this imaging modality. MDCT allowed better visualization of the facial deformity and chin deviation in all dimensions.⁹ The advantage of the 3-dimensional visualization of such complex cases using MDCT is indisputable. However, plain radiography is still commonly used due to its availability, low cost, and reduced patient exposure to ionizing radiation. Raustia et al.¹⁷ analyzed 11 cases of CCGs replacing the mandibular condyles using MDCT. The authors reported 4 cases that demonstrated low-attenuation grafts with occasional foci of high attenuation, clear borders between the graft and host bone, and lateral and superior rims of ossification using MDCT. The follow-up period of these cases ranged from 5 months to 8 years. A clear border was only seen in the case in which only 5 months had elapsed since surgery. Fukuta et al.¹⁶ published a case of recurrent overgrowth of a CCG placed for hemimandibular reconstruction using panoramic images, MDCT, and a nuclear

medicine bone scan. These images were of poor quality, but the authors noted the deviation of the mandible on MDCT on 2 occasions (before each corrective operation) and increased uptake of the radionuclide by the graft on the third day after surgery. This profound growth potential may have been due to the patient's young age (2 years old). Similarly, Samman et al.¹⁸ demonstrated an increase in isotope uptake by the graft using technetium scintigraphy, supporting the theory that CCGs have an inherent growth potential. Kaban et al.¹¹ described the incorporation and calcification of a CCG replacing the mandibular condyle, and ultimately resembling a normal condyle upon periodic follow-up. Unfortunately, the quality of the images was poor in the previous articles, which made us unable to evaluate the imaging findings.

Eckardt et al.¹⁰ described a case of CCG reconstruction after hemimandibulectomy in which follow-up was performed at regular intervals, up to 6 years after surgery, using panoramic images. The authors used linear and angular measurements to calculate the ratio between the operated and unoperated side to evaluate overgrowth versus growth retardation. Although this approach is inaccurate, as panoramic images are prone to positioning errors and unpredictable distortion between successive images and within the same image;¹⁹ significant growth of the CCG along the vertical dimension was evident. Ko et al.¹³ accurately used landmarks on lateral and posteroanterior cephalometric radiographs to assess CCG growth. The authors noted that the follow-up period was critical when evaluating overgrowth; the longer the follow-up period, the more growth they found in their sample. They did not display any radiographs. Jang et al.²⁰ described the case of a CCG extending from the angle of the mandible and replacing the condyle using CT. The graft appeared stable with no signs of resorption or overgrowth at 10 months after surgery. This may have been due to the short follow-up period.

Schatz and Ginat⁸ pointed out that autografts have the disadvantage of resorption hindering their cosmetic effect. The authors demonstrated a low-attenuation cartilage graft with a peripheral rim of ossification using an axial MDCT image. Karacaoğlan et al.²¹ also demonstrated that cartilage grafts had a tendency to undergo resorption, using magnetic resonance imaging (MRI) after a 12-month follow-up period to assess the degree of resorption. The majority of the grafts had a low signal with a few foci of high signal near the soft tissue periphery on follow-up imaging.

No article in the literature described similar growth or

changes in synthetic cosmetic implants in the soft tissue. This is attributed to the fact that they lack growth potential. However; cosmetic implants, like autogenous grafts, can become incorporated into the underlying bone. Other complications associated with cosmetic implants include migration, extrusion, erosion, and foreign bone reaction.⁸

With the increased use of radiographic imaging to diagnose and treat a variety of dental and medical conditions, there is an increased likelihood of incidental findings, such as implants that were not expected based on the patient's history. A history of implants for cosmetic purposes may not be elicited because the patient may not feel that they are important to the issue being discussed. Although most implants and grafts will present as benign-looking entities within the soft tissue that can easily be interpreted as such, some may present as unusual entities that may mimic a more serious disease, such as a benign or malignant neoplasm. The current case was such a situation, in which a CCG appeared suspicious.

The common management of facial defects in OAVS includes reconstructive surgery, often using implants or grafts to improve patients' cosmetic appearance. We present the case of an incidentally found cosmetic graft. According to the patient, an autogenous rib graft was harvested and sectioned to augment the mandibular symphysis. On imaging, no surgical hardware was identified. Attempts to recover previous medical and surgical notes were unsuccessful, as the surgeon who performed the procedure in 1950 was deceased. The exact surgical technique used was unclear; however, the graft had maintained its proper anatomical location and aesthetic shape for over 65 years. The most probable surgical technique may have involved the surgeon dicing the osteocartilage into multiple pieces and creating a tunnel between the mandibular periosteum and overlying mucosa to hold the diced cartilage graft in place during the healing period.²¹ To our knowledge, this is the last published case of an anterior mandibular costochondral graft. No case with long-term follow-up has been published and a review of the literature concerning imaging related to cosmetic facial grafts did not identify any similar cases.

Clinical correlations, imaging, and histology were essential to render a final diagnosis of costochondral graft material. The histopathology suggested a benign cartilaginous process; however, the anterior mandible is a rare site for benign cartilaginous neoplasms, and without proper clinical and radiographic correlations the lesion could have been misdiagnosed.

Other possibilities in the histological differential diag-

nosis included the cartilaginous cap of an osteochondroma. However, mandibular osteochondromas have almost exclusively been reported in the condyle.²² The characteristic imaging findings of an osteochondroma, involving a pedunculated or sessile bony cortical mass continuous with the underlying bone, were absent.

Facial implants and grafts are found incidentally in many CBCT studies performed for dental treatment. A thorough knowledge of their normal appearance is important in order to recognize what is abnormal. Based on imaging alone, chondrosarcoma was initially considered due to the speckled diffuse flocculent calcification and the infiltration into adjacent normal bone. Chondrosarcomas occur where cartilaginous tissues may be present and may occasionally occur in the symphyseal region.²³

Schatz and Ginat⁸ discussed the imaging appearance of these augmentation materials using CT and MRI. Chin augmentation materials such as hydroxyapatite, silicone implants, and cartilage grafts have been described. The authors concluded that cartilage grafts appear to have a soft tissue density that "may form a rim of calcification or ossification."⁸ Our case involved a more diffuse calcification pattern, which may have been due to the longer follow-up period.

Implants or grafts may be incidental findings on radiographic images made for unrelated purposes. Although most are well defined and radiographically homogeneous, being of relatively inert non-biological material, immune reactions to some may stimulate alterations in the appearance of surrounding tissues. Biological implants may undergo growth and differentiation, causing their appearance to mimic neoplastic lesions.

We present the case of a costochondral graft in the soft tissue anterior and facial to the mandible, with changes mimicking a cartilaginous neoplasm. In light of the fact that chondrosarcomas are known to occur in the anterior rib cage, an evaluation of random growth is warranted when a CCG is used for reconstructive surgery. A vascularized graft is thought to be more controlled in growth than a nonvascularized graft. This is the first case to report the CBCT imaging features of a long-standing graft in the anterior mandible.

References

1. Rollnick BR, Kaye CI, Nagatoshi K, Hauck W, Martin AO. Oculoauriculovertebral dysplasia and variants: phenotypic characteristics of 294 patients. *Am J Med Genet* 1987; 26: 361-75.

2. Gorlin RJ, Jue KL, Jacobsen U, Goldschmidt E. Oculoauriculo-vertebral dysplasia. *J Pediatr* 1963; 63: 991-9.
3. Pashayan H, Pinsky L, Fraser FC. Hemifacial microsomia - oculo-auriculo-vertebral dysplasia. A patient with overlapping features. *J Med Genet* 1970; 7: 185-8.
4. Cohen MM Jr, Rollnick BR, Kaye CI. Oculoauriculovertebral spectrum: an updated critique. *Cleft Palate J* 1989; 26: 276-86.
5. Poswillo D. The pathogenesis of the first and second branchial arch syndrome. *Oral Surg Oral Med Oral Pathol* 1973; 35: 302-28.
6. Beleza-Meireles A, Clayton-Smith J, Saraiva JM, Tassabehji M. Oculo-auriculo-vertebral spectrum: a review of the literature and genetic update. *J Med Genet* 2014; 51: 635-45.
7. Medical-dictionary.thefreedictionary.com [Internet]. The free dictionary by FARLEX. [cited 2016 April 4]. Available from: <http://medical-dictionary.thefreedictionary.com>.
8. Schatz CJ, Ginat DT. Imaging of cosmetic facial implants and grafts. *AJNR Am J Neuroradiol* 2013; 34: 1674-81.
9. Yang S, Fan H, Du W, Li J, Hu J, Luo E. Overgrowth of costochondral grafts in craniomaxillofacial reconstruction: rare complication and literature review. *J Craniomaxillofac Surg* 2015; 43: 803-12.
10. Eckardt A, Swennen G, Teltzrow T. Melanotic neuroectodermal tumor of infancy involving the mandible: 7-year follow-up after hemimandibulectomy and costochondral graft reconstruction. *J Craniofac Surg* 2001; 12: 349-54.
11. Kaban LB, Perrott DH, Fisher K. A protocol for management of temporomandibular joint ankylosis. *J Oral Maxillofac Surg* 1990; 48: 1145-52.
12. Kansy K, Mueller AA, Mucke T, Kopp JB, Koersgen F, Wolff KD, et al. Microsurgical reconstruction of the head and neck - current concepts of maxillofacial surgery in Europe. *J Craniomaxillofac Surg* 2014; 42: 1610-3.
13. Ko EW, Huang CS, Chen YR. Temporomandibular joint reconstruction in children using costochondral grafts. *J Oral Maxillofac Surg* 1999; 57: 789-800.
14. Nelson CL, Buttrum JD. Costochondral grafting for posttraumatic temporomandibular joint reconstruction: a review of six cases. *J Oral Maxillofac Surg* 1989; 47: 1030-8.
15. Obeid G, Guttenberg SA, Connole PW. Costochondral grafting in condylar replacement and mandibular reconstruction. *J Oral Maxillofac Surg* 1988; 46: 177-82.
16. Fukuta K, Jackson IT, Topf JS. Facial lawn mower injury treated by a vascularized costochondral graft. *J Oral Maxillofac Surg* 1992; 50: 194-8.
17. Raustia A, Pernu H, Pyhtinen J, Oikarinen K. Clinical and computed tomographic findings in costochondral grafts replacing the mandibular condyle. *J Oral Maxillofac Surg* 1996; 54: 1393-401.
18. Samman N, Cheung LK, Tideman H. Overgrowth of a costochondral graft in an adult male. *Int J Oral Maxillofac Surg* 1995; 24: 333-5.
19. Mallya SM, Lurie AG. Panoramic imaging. In: White SC, Pharoah MJ. *Oral radiology: principles and interpretation*. 7th ed. St. Louis, Mo.: Mosby/Elsevier; 2014. p. 166-84.
20. Jang HW, Kim NK, Lee WS, Kim HJ, Cha IH, Nam W. Mandibular condyle and infratemporal fossa reconstruction using vascularized costochondral and calvarial bone grafts. *J Korean Assoc Oral Maxillofac Surg* 2014; 40: 83-6.
21. Karacaoğlan N, Akbas H, Eroğlu L, İncesu L. Chin augmentation using diced cartilage. *Eur J Plast Surg* 1998; 21: 254-6.
22. Loftus MJ, Bennett JA, Fantasia JE. Osteochondroma of the mandibular condyles. Report of three cases and review of the literature. *Oral Surg Oral Med Oral Pathol* 1986; 61: 221-6.
23. Garrington GE, Collett WK. Chondrosarcoma. II. Chondrosarcoma of the jaws: analysis of 37 cases. *J Oral Pathol* 1988; 17: 12-20.