

Modified soft tissue cast for fixed partial denture: a technique

Pravinkumar G. Patil*, MDS

Department of Prosthodontics, Government Dental College & Hospital, Nagpur, Maharashtra, India

In process of fabrication of a fixed partial denture, dies are trimmed to expose margins of the preparations. The need for the soft tissue cast is quite evident as the soft tissue emergence profile that surrounds the prepared tooth is destroyed in the process of fabrication. This article describes a modified technique to fabricate the soft tissue cast for the conventional fixed partial denture. The impression made with the polyvinylsiloxane was first poured to prepare the die cast. After retrieval of the cast, the same impression was poured second time with the resin based resilient material to cover the facial and proximal gingival areas. The remaining portion of the impression was poured with the gypsum material. This technique does not require additional clinical appointment, second impression procedure, technique sensitive manipulations with impression, or cumbersome laboratory procedures. The simplicity of this technique facilitates and justifies its routine use in fabrication of the fixed partial denture. [J Adv Prosthodont 2011;3:33-6]

KEY WORDS. Soft tissue cast, Emergence profile, Fixed partial denture

INTRODUCTION

Though the soft tissue casts have become a popular aid in fabrication of the cervical contours of the implant crowns, their use in a conventional fixed partial denture also play an important role. In many clinical practices, dies are trimmed to expose margins of the preparations. The soft tissue emergence profile that surrounds the prepared teeth is destroyed in the process of fabrication. The resultant restorations either show triangular spaces above the tissues or become over or under contoured due to the loss of gingival architecture.¹ Overcontoured restorations result in food and plaque retention in the interproximal, facial, and lingual cervical areas which can lead to caries, gingival inflammation, and/or gingival hyperplasia.²⁻⁴ Undercontoured restorations may create excessive interproximal spaces and problems with phonetics and esthetics.³ Often, laboratory technicians are unable to contour the crowns properly in the interproximal regions without a soft tissue cast.⁵ Many procedures for fabrication of the soft tissue casts for conventional fixed partial denture have been reported in the literature.^{1,5-8} This article describes a modification of the technique described by Williamson *et al.* to fabricate the soft tissue cast for the conventional fixed partial denture.⁵ The modification comprises fabrication of the facial and proximal

gingival architecture associated with the prepared teeth in resilient material and remaining portion in hard dental stone.

TECHNIQUE

Abutment teeth were prepared to receive a fixed partial denture. The impression was made with a polyvinyl-siloxane material (Exaflex; GC America, Chicago, IL, USA) using the conservative tissue management technique (Fig. 1).^{5,6} The impression was disinfected in conventional manner and poured with the type IV gypsum material (Ultrarock; Kalabhai Karson, Mumbai, India) to make a master cast (Fig. 2). After retrieval of the master cast, impression was washed thoroughly to prepare it for second pour to fabricate a modified soft tissue cast. A polymethylmethacrylate based resilient liner (PermaSoft Denture Liner-Pink; Dentsply Austenal, York PA, USA) was carefully mixed and applied onto the facial and proximal aspects of the impression surface around the prepared teeth and edentulous spaces with a small painting brush (Camlin, Mumbai, India) (Fig. 3). Care was taken to prevent seepage of the resilient liner over the teeth and lingual gingival impression surfaces during the liner application. The undercuts (in the form of irregular surfaces) were prepared in the resilient liner as shown in figure 3 to achieve mechanical inter-

Corresponding author: Pravinkumar G. Patil

Department of Prosthodontics, Government Dental College & Hospital, GMC Campus, Medical Square, Nagpur, Maharashtra, India, 440003

Tel. +91 9923294699; e-mail, pravinandsmita@yahoo.co.in

Received January 4, 2011 / Last Revision January 21, 2011 / Accepted February 28, 2011

© 2011 The Korean Academy of Prosthodontics

This is an Open Access article distributed under the terms of the Creative Commons Attribution Non-Commercial License (<http://creativecommons.org/licenses/by-nc/3.0>) which permits unrestricted non-commercial use, distribution, and reproduction in any medium, provided the original work is properly cited.

locking in the gypsum material. The teeth and lingual gingival areas were reproduced in gypsum material to accomplish sufficient bulk for strength. In addition, lingual preparation margins were usually kept supra-gingivally, hence the use of resilient material in lingual surfaces was not necessary. The resilient liner was polymerized by immersing the liner-applied portion of the impression in the hot water (60°C for 2-4 minutes) as per the manufacturer's instructions. The water temperature should not be increased more than 70°C to prevent any dimensional change in the impression.⁹ After complete polymerization of the resilient liner, remaining portion of the impression was poured in type III gypsum material (Kalstone;

Kalabhai Karson, Mumbai, India). The cast was retrieved from the impression after setting of the gypsum material (Fig. 4). The polymethylmethacrylate based resilient liner could be easily separated from the silicone-based impression; hence, the separating medium was not required before pouring. The cast was examined for the defects or porosities. The resultant cast was produced with facial and proximal gingival surfaces in resilient liner material and rest of the cast in gypsum material. This soft tissue cast was used along with master cast to develop and evaluate ideal axial contours of the fixed partial denture (Fig. 5, 6).

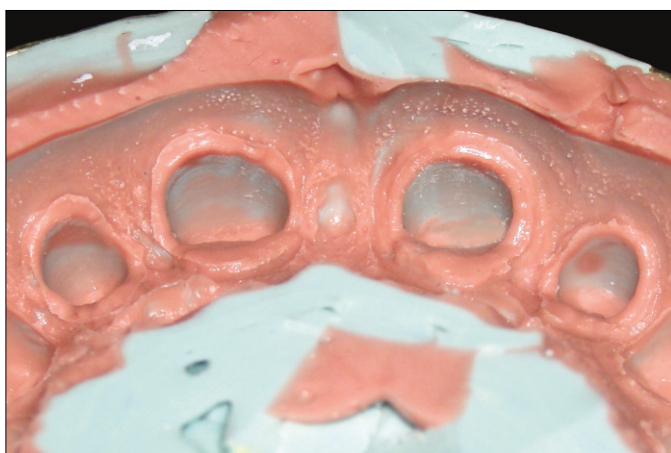

Fig. 1. Final impression in polyvinyl-siloxane.

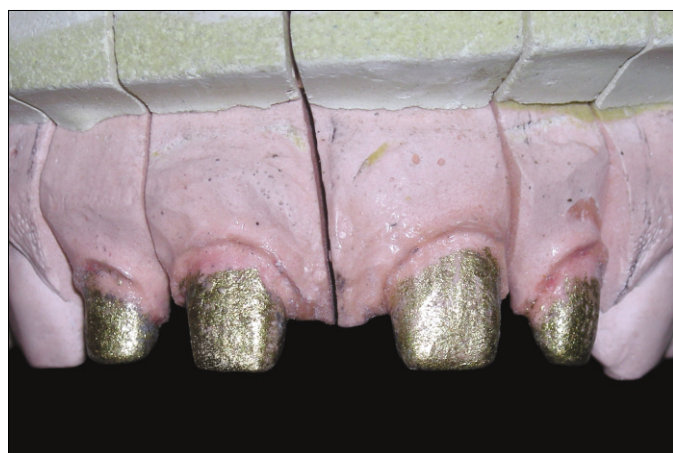

Fig. 2. Master cast.

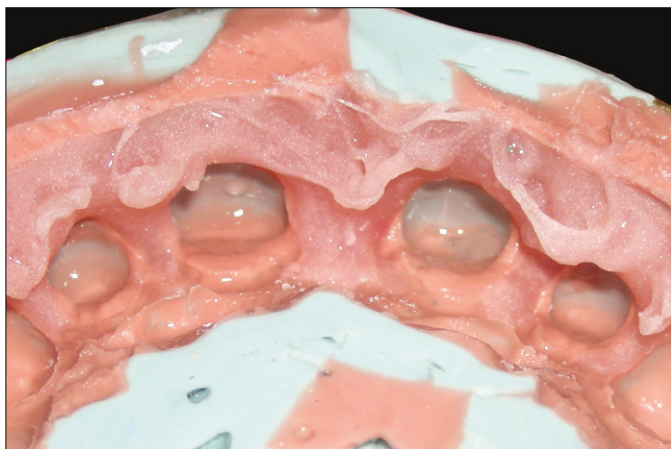


Fig. 3. Resilient liner applied onto the facial and proximal gingival surfaces of the impression surrounding the teeth in interest. Note that the multiple undercuts prepared to achieve mechanical interlocking in the gypsum material.

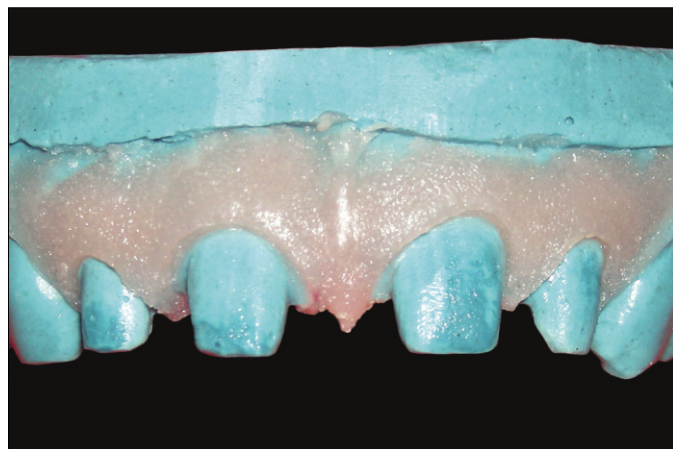

Fig. 4. Modified soft tissue cast.

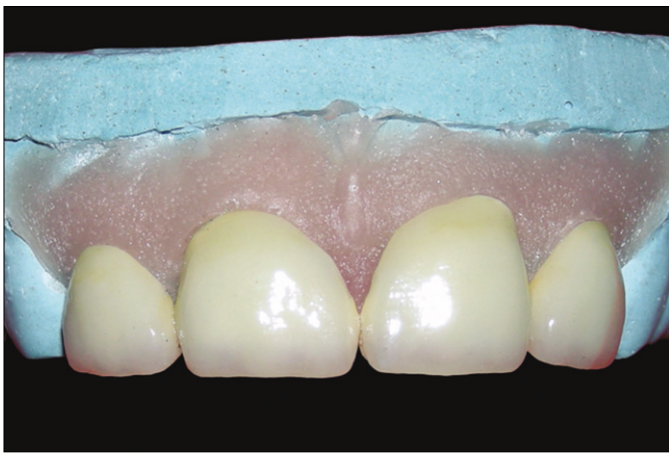

Fig. 5. Fabrication and evaluation of axial contours of the fixed partial denture on the modified soft tissue cast.

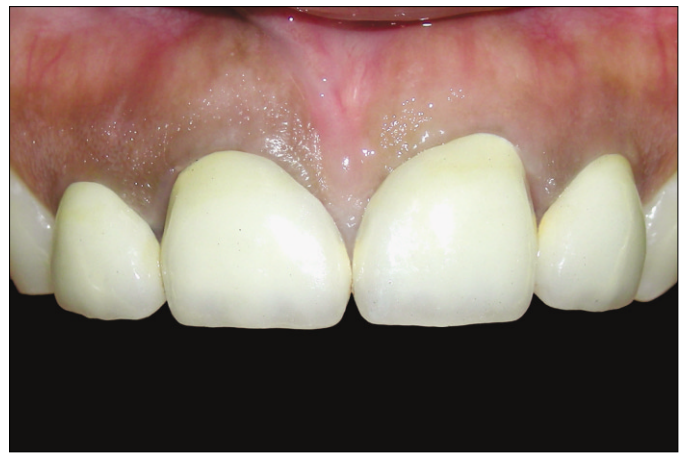

Fig. 6. Fixed partial denture in place with correct gingival emergence profile.

DISCUSSION

Merely pouring a second cast from the final impression in a rigid polyvinyl-siloxane impression material and using it as a soft tissue guide has been suggested.^{5,6} Similar procedure of pouring of a second cast in the final impression as a soft tissue cast was performed with changes in the materials. According to some authors, the problem with this approach is that the gingival tissue has been retracted, and the cast does not correspond accurately to the patient's intraoral situation.^{1,8} Hence these procedures require conservative tissue management for minimal acceptable retraction that helps reproducing the accessible margins without hampering the gingival tissues architecture much. Still some authors have critiqued this procedure, mentioning the problem that the gingiva is not reproduced in a passive state.¹ But recording the gingiva in passive state for correct reproduction of the cervical contours sometimes does not allow complete seating of the restorations on the soft tissue cast (especially for subgingival preparations) due to collapsing of the marginal gingiva onto the preparation margins. This will invariably lead to faulty reproduction of the cervical contours. Hence, the soft tissue cast reproduced from an impression made with conservative tissue management is safer than from the impression recorded with the gingiva in passive state. Tan and Ruder recorded gingival form with the partially prepared teeth sparing the marginal areas which is an ideal method, but required an additional impression and cumbersome laboratory procedures.⁸ Williamson *et al.* described the fabrication of a soft-tissue cast by completely pouring the impression with the elastomeric impression material, which can give the false seating of the restorations due to overall flexibility leading to faulty cervical contours.⁵ Tan and Ruder described a simplified technique for creating a soft tissue masque to aid in shaping the gingival contours.⁸ Although, this technique does not

require additional clinical visit but it definitely requires additional elastomeric impression and many manipulations with the additional impression to form the removable gingival masque, which is technique sensitive and time consuming. Tung *et al.* described a technique that simultaneously registers maximal intercuspal position and gingival emergence profile.¹ This technique requires additional clinical visit and the technique sensitive clinical as well as laboratory procedures to reproduce the gingival emergence profile. Bassiouny and Yearwood described establishment of gingival emergence profile by creating a soft tissue masque in which the additional manipulation with the final impression is required by making channels for incorporation of resilient material.⁶

The principal advantage of this technique is that, the consistencies of materials used to fabricate the cast simulate consistencies of the oral tissues as gingival areas (being soft) allow better perception for the technician to contour the marginal porcelain and the tooth-structure areas (being hard) facilitates accurate fit-checking of the restoration without flexion or distortion. In addition, pink color of the resilient material used in this technique provides gingival colored background (which is a closer looking platform) that helps technician in better color perception during evaluation of the final contours. Special care must be exercised when selecting materials to be used for soft tissue casts.¹⁰ Most of the resilient materials used for the soft tissue casts are incompatible with impression materials and often require a separating medium causing blockage of the impression details.¹¹ Gerrow and Price studied the surface detail reproduction of different flexible die material systems and concluded that the surface detail reproduction was adversely affected when a separator was required between the impression and flexible die material.¹¹ Polymethylmethacrylate based resilient material used in this technique is compatible with the silicone based elastomeric impression material and elim-

inates the use of separating medium. Pouring the desired area of the impression with soft material and remaining in hard material requires more time and technique sensitivity than pouring it completely in either of the material. Looking at the disadvantage versus advantage ratio the technique is more beneficial at the expense of additional time required. The resilient liner should be carefully poured to prevent the seepage into the tooth-surface areas. An accidental seepage of small amount of material on the tooth surfaces does not significantly affect the desired outcome. The resilient liner poured in the impression was carefully cured at the temperature about 60°C to avoid any possible dimensional changes. Holtan *et al.* studied dimensional stability of a polyvinylsiloxane impression material following ethylene oxide and steam autoclave sterilization.⁹ They concluded that impressions sterilized by ethylene oxide (71°C) were acceptable for use in the construction of fixed or removable prostheses compared to that with steam sterilization (132°C) which were not acceptable. The dimensional stability of the polyvinylsiloxane impression material is affected with increased steam autoclave temperature cycle. The materials used in this procedure are relatively less expensive, readily available, and easy to use.

CONCLUSION

The technique described in this article is relatively quicker and more cost effective than previously described techniques. This technique does not require additional clinical appointment, second impression procedure, technique sensitive manipulations with impression, and cumbersome laboratory procedures. The simplicity of this technique facilitates and justifies its routine use in fabrication of fixed dental prosthesis.

ACKNOWLEDGEMENT

Dr. Smita P. Patil (PG student, Department of Orthodontics and Dentofacial Orthopedics, PMNM Dental College and Hospital, Bagalkot, Karnataka, India) for her help in the manuscript preparation and Mr. Snehal Wankhede (Dental Technician, Nirmal Dental Lab, Nagpur, Maharashtra, India) for his assistance in the laboratory work.

REFERENCES

1. Tung FF, Nourbakhsh N, Bahn C. Accurate procedure for simultaneous registration of gingival emergence profile and maximal intercuspal position for metal ceramic restorations. *J Prosthet Dent* 2000;83:681-5.
2. Perel ML. Periodontal considerations of crown contours. *J Prosthet Dent* 1971;26:627-30.
3. Yuodelis RA, Weaver JD, Sapkos S. Facial and lingual contours of artificial complete crown restorations and their effects on the periodontium. *J Prosthet Dent* 1973;29:61-6.
4. Jameson LM, Malone WF. Crown contours and gingival response. *J Prosthet Dent* 1982;47:620-4.
5. Williamson RT, Breeding LC, Kinderknecht KE. Soft tissue cast aids in establishing interproximal contours for restorations. *J Prosthet Dent* 1993;69:630-1.
6. Bassioumy MA, Yearwood LL. Establishing the gingival emergence profile of restorations by using a resilient gingival replica. *J Prosthet Dent* 1996;76:386-9.
7. Nayyar A, Moskowitz M, Pollard BL. Improving the emergence profile of dental restorations with accurate reproduction of soft tissue topography. *J Esthet Dent* 1995;7:26-31.
8. Tan PL, Ruder GA. Simple(r) soft tissue masque for individual fixed restorations. *J Prosthodont* 2004;13:192-4.
9. Holtan JR, Olin PS, Rudney JD. Dimensional stability of a polyvinylsiloxane impression material following ethylene oxide and steam autoclave sterilization. *J Prosthet Dent* 1991;65:519-25.
10. Beyak BL, Chee WW. Compatibility of elastomeric impression materials for use as soft tissue casts. *J Prosthet Dent* 1996;76:510-4.
11. Gerrow JD, Price RB. Comparison of the surface detail reproduction of flexible die material systems. *J Prosthet Dent* 1998;80:485-9.