

“Honeycomb” pattern of gallbladder wall thickening - A forward step in early diagnosis of “Severe Dengue Fever”

Jitendra Parmar, Maulik Vora¹, Chander Mohan², Sandip Shah, Harsh Mahajan³, Tapan Patel

Department of Radiology, Apollo Hospitals International Limited, Gandhinagar, ¹Department of Radiology, Institute of Neuroscience, Surat, ²Department of Interventional Radiology, ³Department of Radiology, Dr. B. L. Kapur Hospital, New Delhi, India

Correspondence: Dr. Maulik Vora, Department of Radiology, Institute of Neuroscience, Surat, Gujarat, India.
E-mail: dr_maulikvora@yahoo.com

Abstract

Aims and Objectives: To study “Honeycomb” pattern of gallbladder wall thickening (GBWT) in dengue fever (DF) and to assess its clinical significance in early diagnosis of severe DF. **Materials and Methods:** A total 244 patients of DF were studied, 84 patients were classified as severe DF, 61 patients as DF with warning signs, and 99 patients as DF without warning signs. Abdominal ultrasound was performed for assessment of GBWT patterns, hepatomegaly, splenomegaly, pancreatic enlargement, ascites, pleural effusion, and other additional findings were recorded in severe DF cases. Statistical comparison between “Honeycomb” pattern of GBWT and clinically severe DF was done using Pearson correlation test. **Results:** Out of 244 patients, 145 patients were males and 99 patients were females, belonging to various age groups ranging from 1 to 81 years and 14.34% (35 patients) among them included in pediatric group. In total, 65.57% (160 patients) were non-severe DF cases and 34.42% (84 patients) were severe DF cases. A total of 84 patients of severe DF, 92.85% patients showed GBWT, and out of which, 71.42% patients had “Honeycomb” pattern, whereas a total of 160 patients of non-severe DF patients, 45% patients had GBWT and out of which, only 5.6% patients showed “Honeycomb” pattern. “Honeycomb” pattern of GBWT shows sensitivity of 71.4%, 94.37%, Positive predictive value of 86.95%, and Negative predictive value of 86.28% in severe DF. **Conclusion:** “Honeycomb” pattern of GBWT is significant finding in severe DF. Its sensitivity and specificity are high in severe DF with significant statistical correlation. It can aid in early diagnosis of severe DF.

Key words: Dengue; gallbladder; gallbladder wall thickening; honeycomb pattern; severe dengue fever; ultrasound

Introduction

Dengue fever (DF) is a viral disease transmitted by mosquitoes. It has emerged as a major public health problem affecting life of millions of people worldwide each year.^[1] Many recent epidemics have shown that ambiguity of clinical findings in severe DF, delays the diagnosis and treatment.^[2] Gallbladder wall thickening (GBWT) is one of the most common ultrasound (USG) finding

in DF. Few recent studies have confirmed that GBWT can play a significant role in assessing patients at risk of developing severe DF.^[3,4] The patterns of GBWT including “Honeycomb” pattern and its importance in diagnosis of severe DF have been described by few authors. In view of paucity of literature regarding role of “Honeycomb” pattern in diagnosis of severe DF,^[5-7] we conducted a prospective study with primary aim of examining “Honeycomb” pattern

This is an open access journal, and articles are distributed under the terms of the Creative Commons Attribution-NonCommercial-ShareAlike 4.0 License, which allows others to remix, tweak, and build upon the work non-commercially, as long as appropriate credit is given and the new creations are licensed under the identical terms.

For reprints contact: reprints@medknow.com

Cite this article as: Parmar J, Vora M, Mohan C, Shah S, Mahajan H, Patel T. “Honeycomb” pattern of gallbladder wall thickening – A forward step in early diagnosis of “Severe Dengue Fever”. Indian J Radiol Imaging 2019;29:14-8.

Access this article online

Quick Response Code:



Website:
www.ijri.org

DOI:
10.4103/ijri.IJRI_363_18

of GBWT in DF. The secondary aim was to study the clinical significance of "Honeycomb" pattern in early diagnosis of severe DF.

Materials and Methods

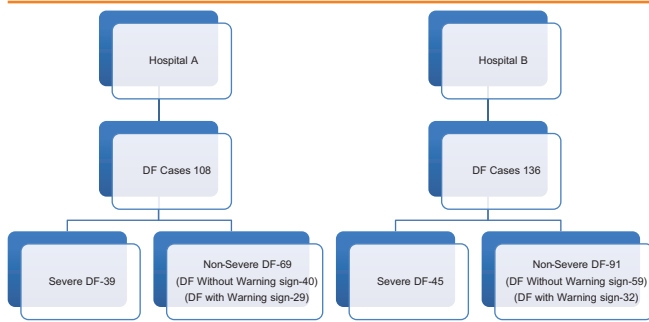
The study was conducted at two different multispecialty hospitals of India in 2016. Out of total 244 patients of DF (108 patients in "hospital A" and 136 patients in "hospital B"), 84 patients were classified as having severe DF, 61 patients as DF with warning signs, and 99 patients as DF without warning signs. The classification was done according to "suggested dengue case classifications and levels of severity" proposed by WHO in 2009.^[8] There was no gender bias followed and the study included patients of all the age groups. The study design is outlined in Table 1.

The clinical manifestations of DF included fever, headache, retro-orbital pain, muscle- joint pain, nausea-vomiting, rash, leukopenia, and thrombocytopenia. The diagnosis of DF was confirmed by NS1 antigen test or Dengue IgM or IgG antibody test.^[9]

Abdominal ultrasound was performed on a GE LOGIQ P5 unit, equipped with a 4C wide bandwidth (1.5 to 4.6 MHz) convex probe and 11L wide bandwidth (4 to 12 MHz) linear probe. The linear probe was used for pediatric patients. The abdominal ultrasound was done in all cases after 4 hours of fasting for better visualization of the gallbladder (GB). A single radiologist performed the ultrasound examinations to obviate inter-observer variation. The performing radiologist was blinded for the study.

A thickened GB wall was defined as being ≥ 3 mm and was measured by placing calipers between the two layers of anterior wall. GBWT was measured, and the "Honeycomb" pattern of GBWT was identified as multiple hypoechoic areas separated by multiple echogenic layers. The sensitivity of "Honeycomb" pattern in diagnosis of severe DF was assessed. In addition, the statistical comparison of "Honeycomb" pattern was assessed between severe DF and non-severe DF.

Table 1: Study design



Other patterns of GBWT, hepatomegaly, splenomegaly, pancreatic enlargement (whenever detected on sonography), ascites, pleural effusion, and other additional findings were recorded for severe DF.

The cases of liver parenchymal disease, hepatobiliary disease, renal parenchymal disease, and cardiac failure were excluded from the study.

Ethics statement

Institutional ethics committee and scientific research committee of both institutes approved the study.

Informed consent

All adult subjects and the parent/guardian of the pediatric subjects provided informed written consent.

Statistical analysis and methods

Statistical testing was conducted with the Statistical Package for the Social Sciences (SPSS) software. The comparison between "Honeycomb" pattern of GBWT and clinically severe DF was done using Pearson correlation test [Correlation is significant at ≤ 0.01 level (2-tailed)].

Results

Total of 244 patients were admitted with DF with 145 males (59.42%) and 99 females (40.57%), belonging to various age groups, ranging from 1 to 81 years. Thirty-five patients were included in pediatric group. In total, 160 patients (65.57%) were having non-severe DF and 84 patients (34.42%) were classified as severe DF. There was no mortality recorded in subjects during the hospitalization.

Of the total admitted DF patients, 150 cases (61.47%) demonstrated GBWT. Among severe DF cases, GBWT was most common USG finding and was found in 78 (92.85%) cases. Out of 160 cases of non-severe DF, only 72 patients (45%) had GBWT [Figure 1]. "Honeycomb" pattern was the most common pattern among various GBWT patterns in severe DF, whereas normal wall thickness was most common in non-severe DF and "Uniform Echogenic" pattern being second most.

"Honeycomb" pattern was found in 60 (71.42%) severe DF cases [Figure 2]. However, only 8 (5.6%) cases out of 160 non-severe DF cases showed "Honeycomb" pattern. Various patterns of GBWT in severe and non-severe DF are summarized in Table 2.

In severe DF, ascites (79.76%) and pleural effusion (63.1%) were second and third most common findings respectively with splenomegaly (45.23%) and hepatomegaly (41.66%) being relatively less common findings [Table 3].

The sensitivity of "Honeycomb" pattern in diagnosis of severe DF was 71.42% with positive predictive value of

Table 2: Gallbladder wall thickening pattern in dengue fever

		Gallbladder wall thickening pattern				
		Normal Gallbladder wall	Uniform echogenic	Tram Track or Striated	Asymmetric	Honeycomb
Severe dengue fever	Hospital A	1	4	5	1	28
	Hospital B	5	3	4	1	32
		6	7	9	2	60
Dengue fever with warning signs	Hospital A	11	8	6	1	3
	Hospital B	9	10	6	2	5
		20	18	12	3	8
Dengue fever without warning signs	Hospital A	28	10	2	0	0
	Hospital B	40	13	5	0	1
		68	23	7	0	1
Total		94	48	28	5	69

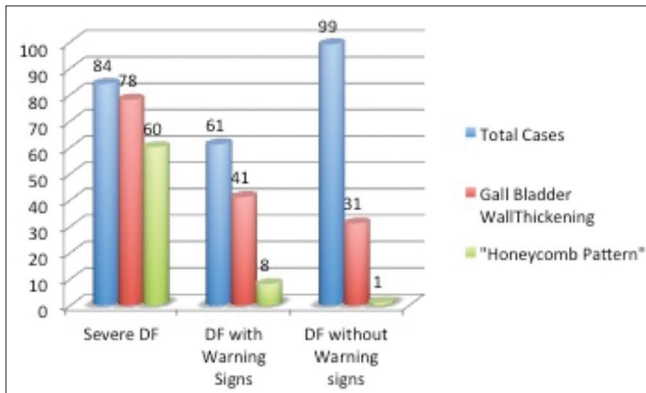


Figure 1: Gallbladder wall thickening and "Honeycomb" pattern in dengue fever

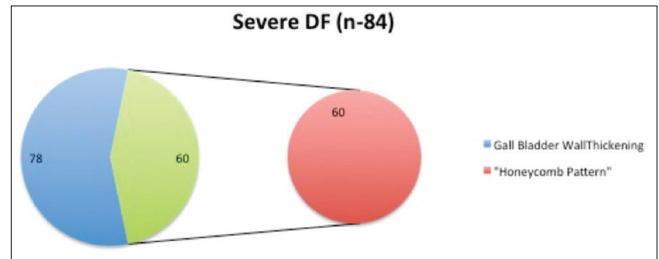


Figure 2: Gallbladder wall thickening and "Honeycomb" pattern in severe dengue fever

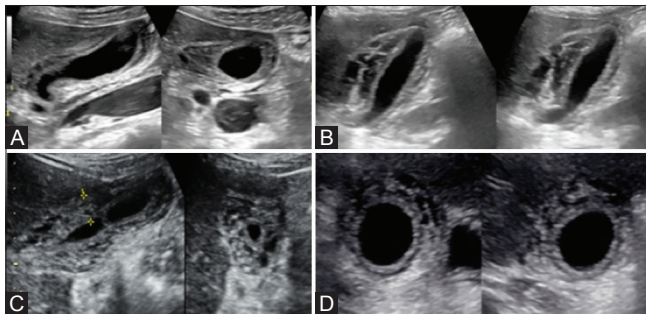


Figure 3 (A-D): Four different patients of severe dengue fever showing "Honeycomb" pattern of gallbladder wall thickening

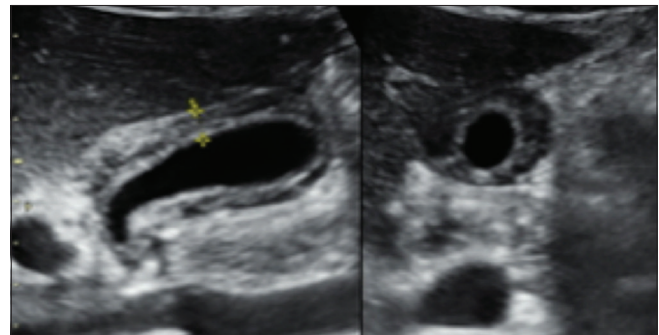


Figure 4: A patient of non-severe dengue fever (dengue fever with warning signs) showing "Honeycomb" pattern of gallbladder wall thickening

86.95% and specificity of 94.37% with negative predictive value of 86.28% [Table 4]. On multivariate analysis, GBWT was significantly associated with severe DF. GBWT with "Honeycomb" pattern was the most specific finding in severe DF in present study and significantly associated with severe DF [Table 5].

Discussion

The incidence of DF has grown dramatically around the world in recent decades with manifolds increase in severe DF related deaths. The diagnosis of DF is suspected on the

basis of clinical findings, laboratory results, and confirmed by serologic detection of the virus, antiviral antibodies, or virus culture from a blood sample in the acute phase.^[1,2,9] The results are often too late, therefore, additional diagnostic modalities for use in emergency of suspected DF patients are being increasingly sought. Although not specific, the USG findings in DF are obtained more rapidly than the results of serologic tests. Many early USG findings of DF have been reported in the literature, GBWT being the most common.^[3,10,11] Recently, various patterns of GBWT have been described in DF according to disease severity.^[12]

As demonstrated by this study GBWT was the most common USG findings in DF, with GBWT being more common in severe DF as compared to non-severe DF.

Many studies conducted in severe DF by many authors recently, demonstrated similar findings as the present study, stating GBWT being the most common finding in DF, and specifically in severe DF.^[3-6,10]

Various non-biliary conditions causing GBWT, including ascites, hypoalbuminemia, portal venous hypertension, end-stage cirrhosis, various types of hepatitis, pancreatitis, chronic heart failure, and renal insufficiency, were excluded from the present study. These causes should be kept in differentials, as GBWT is a non-specific finding.^[13-15] However, in an epidemic region of DF, patient presenting with fever, headache, retro-orbital pain with USG findings of GBWT, ascites, pleural effusion, hepatomegaly or splenomegaly, the diagnosis of DF should be considered first.^[11]

Among specific patterns of GBWT, "Honeycomb" was found to be more common in severe DF [Figures 3 and 4].^[12] Few

authors have described this pattern previously, stating its importance in early diagnosis of severe DF.^[5,7] Sachar *et al.* found "Honeycomb" pattern in 19 out of 20 patients of severe DF (95%), whereas the present study demonstrated "Honeycomb" pattern in 71.4% of severe DF cases.^[7] The difference might be because of difference in the sample size, as Sachar *et al.* had very small sample size of 20 cases of severe DF only, and the present study included 84 cases of severe DF. "Honeycomb" pattern of GBWT is statistically correlated with severity of DF. One of the authors has described transient reticular GBWT in severe DF as a reliable sign of plasma leakage.^[6] With sensitivity of 71.4%, specificity of 94.37%, PPV of 86.95%, and NPV of 86.28%, "Honeycomb" pattern of GBWT can favor diagnosis of severe DF in epidemic areas of DF with appropriate clinical scenario.

The limitations of this study were that serial sonography was not done. There was no follow-up available once the patient was discharged from hospital.

This type of pattern of GBWT can also be seen in acute cholecystitis or gangrenous cholecystitis; however, there is mild difference in the findings, as in acute cholecystitis, GB calculus is associated finding in calculus cholecystitis, and sloughed membrane is seen in the lumen in case of gangrenous cholecystitis. Other USG findings of DF included ascites, pleural effusion, hepatomegaly, and splenomegaly, similar to previously described in literatures.

Conclusion

GBWT is important USG finding in diagnosed cases of DF. GBWT when combined with other USG findings such as ascites, pleural effusion, hepatomegaly, or splenomegaly, the suspicion of DF should be raised in epidemic region. "Honeycomb" pattern of GBWT is significant finding in severe DF. Its sensitivity and specificity is high in severe DF with significant statistical correlation, so it can aid into the early diagnosis of severe DF.

Table 3: Ultrasound findings in severe dengue fever

	Hospital A	Hospital B	Total	Percentage
Gallbladder wall thickening pattern	38	40	78	92.85
Hepatomegaly	14	19	33	41.66
Splenomegaly	17	21	38	45.23
Ascites	33	34	67	79.76
Plef	28	25	53	63.1

Table 4: A 2 × 2 contingency table of "Honeycomb" pattern in severe dengue fever

	Severe dengue fever		Total	
	Yes	No		
Honeycomb pattern				
Yes	60	9	69	86.95% (PPV)
No	24	151	175	86.28% (NPV)
	84	160	244	
	71.42% (sensitivity)	94.37% (specificity)		

DF=Dengue fever, PPV=Positive predictive value, NPV=Negative predictive value

Table 5: Cross tabulation and correlation of "Honeycomb" pattern and severe dengue fever

	Chi-Square Tests			
	Value	DF	Asymptotic Significance (2-sided)	Exact Sig. (1-sided)
Pearson Chi-Square	117.598 ^a	1	0.000	
Continuity Correction ^b	114.376	1	0.000	
Likelihood Ratio	120.840	1	0.000	
Fisher's Exact Test				0.000
N of Valid Cases	244			

^a0 cells (0.0%) have expected count <5. The minimum expected count is 23.75. ^bComputed only for a 2 × 2 table

	Symmetric Measures ^c	
	Value	Approximate Significance
Nominal by Nominal Contingency Coefficient	0.570	0.000
N of Valid Cases	244	

^cCorrelation statistics are available for numeric data only

Abbreviations

GBWT = Gallbladder wall thickening

DF = Dengue fever

USG = Ultrasound

Financial support and sponsorship

Nil.

Conflicts of interest

There are no conflicts of interest.

References

1. Hadinegoro S. The revised WHO dengue case classification: Does the system need to be modified? *Pediatr Int Child Health* 2012;32:33-8.
2. World Health Organization. Working to overcome the global impact of neglected tropical diseases. First WHO report on neglected tropical diseases. Geneva, Switzerland: WHO; 2010.
3. Setiawan M, Samsi T, Pool T, Wulur H, Sugianto D, Pool T. Gallbladder wall thickening in dengue hemorrhagic fever: An ultrasonographic study. *J Clin Ultrasound* 1995;23:357-62.
4. Setiawan MW, Samsi TK, Wulur H, Sugianto D, Pool T. Dengue haemorrhagic fever: Ultrasound as an aid to predict the severity of the disease. *Pediatr Radiol* 1998;28:1-4
5. Pothapregada S, Kullu P, Kamalakannan B, Thulasingham M. Is ultrasound a useful tool to predict severe dengue infection?: *Indian J Pediatr* 2016;83:500-4.
6. Oliveira G, Machado R, Horvat J, Gomes L, Guerra L, Vandestein L, *et al.* Transient reticular gallbladder wall thickening in severe dengue fever: A reliable sign of plasma leakage. *Pediatr Radiol* 2010;40:720-4.
7. Sachar S, Goyal S, Sachar S. Role of ultrasound ("Honeycomb sign") in early detection of dengue hemorrhagic fever. *Arch Clin Exp Surg* 2013;2:38-42.
8. WHO. 2009; Dengue: Guidelines for diagnosis, treatment, prevention and control. Available from: http://whqlibdoc.who.int/publications/2009/9789241547871_eng.pdf.
9. Gubler D. Dengue and dengue hemorrhagic fever. *Clin Microbiol Rev* 1998;11:480-96.
10. Gopalakrishna S, Mohan K. Correlation of clinical, serological and radiological features of severe dengue fever. *Sch J App MedSci* 2015;3:1397-9.
11. Santhosh VR, Patil PG, Srinath MG, Kumar A, Jain A, Archana M. Sonography in the diagnosis and assessment of Dengue fever. *J Clin Imaging Sci* 2014;4:14.
12. Parmar JP, Mohan C, Vora M. Patterns of Gall Bladder Wall Thickening in Dengue Fever: A Mirror of the Severity of Disease. *Ultrasound Int Open* 2017;3:E76-81.
13. Patriquin HB, DiPietro M, Barber FE, Teele RL. Sonography of thickened gallbladder wall: Causes in children. *AJR Am J Roentgenol* 1983;141:57-60.
14. Shlaer WJ, Leopold GR, Scheible FW. Sonography of the thickened gallbladder wall: A nonspecific finding. *AJR Am J Roentgenol* 1981;136:337-9.
15. Wegener M, Börsch G, Schneider J, Wedmann B, Winter R, Zacharias J. Gallbladder wall thickening: A frequent finding in various nonbiliary disorders-a prospective ultrasonographic study. *J Clin Ultrasound* 1987;15:307-12.