

Case Report

Iatrogenic displacement of the metacarpal head of the index finger while attempting closed reduction of a complex dorsal metacarpophalangeal joint dislocation

Masahiko Tohyama^{a,b,*}, Ken Iida^b, Sadahiko Konishi^b

^a Department of Orthopaedic Surgery, Osaka Rosai Hospital, Osaka, Japan

^b Department of Orthopaedic Surgery, Osaka General Hospital of West Japan Railway Company, Osaka, Japan

ARTICLE INFO

Keywords:

Complex dislocation
Metacarpophalangeal joint
Iatrogenic displacement
Metacarpal head

ABSTRACT

We describe the case of an 84-year-old woman with a dorsal dislocation of the metacarpophalangeal (MCP) joint of the left index finger. Closed reduction was performed at an orthopaedic clinic which led to an iatrogenic complete displacement of the second metacarpal head to the volar side. Because reduction was impossible, surgery was performed. The metacarpal head was reduced and fixed with two headless intramedullary screws. Careless attempting a closed reduction of the complex dorsal MCP joint dislocation might be contraindicated in elderly patients with bone fragility.

Introduction

Except for the thumb, metacarpophalangeal (MCP) joint dislocation are relatively uncommon. These dislocations can be classified based on ease of reduction into simple reducible or complex irreducible. Dorsal MCP joint dislocations occur as a result from hyperextension of the joint and are often irreducible due to soft tissue interposition or entrapment. We present a case of an iatrogenic complete displacement of the metacarpal head caused by careless attempting a closed reduction of the complex dorsal MCP joint dislocation of the index finger.

Case presentation

An 84-year-old woman fell while walking and injured her left hand. She visited a nearby orthopaedic clinic and was diagnosed with a dorsal dislocation of the MCP joint of her left index finger, a second metacarpal neck fracture, and a distal radius fracture. A closed reduction of the index finger MP joint dislocation was done under local anaesthesia without fluoroscopy. This resulted in an iatrogenic displacement of the second metacarpal head due to which reduction was impossible. Therefore, she was transferred to our institution.

On examination, the MCP joint of the left index finger was painful and swollen. Active motion was difficult and limited, but there was no sensory loss. Radiography at the time of injury revealed a dorsal dislocation of the MCP joint followed by a second metacarpal neck fracture with no displacement (Fig. 1). Radiography and three-dimensional computed tomography reconstruction after a closed reduction revealed the complete displacement of the second metacarpal head to the volar side, whereas the proximal phalangeal base

* Corresponding author at: Department of Orthopaedic Surgery, Osaka Rosai Hospital, 1179-3 Nagasone-cho, Kita-ku, Sakai City, Osaka 591-8025, Japan.

E-mail address: m-tohyama@k5.dion.ne.jp (M. Tohyama).

<https://doi.org/10.1016/j.tcr.2019.100243>

Accepted 19 August 2019

Available online 28 August 2019

2352-6440/ © 2019 The Authors. Published by Elsevier Ltd. This is an open access article under the CC BY-NC-ND license (<http://creativecommons.org/licenses/by-nc-nd/4.0/>).

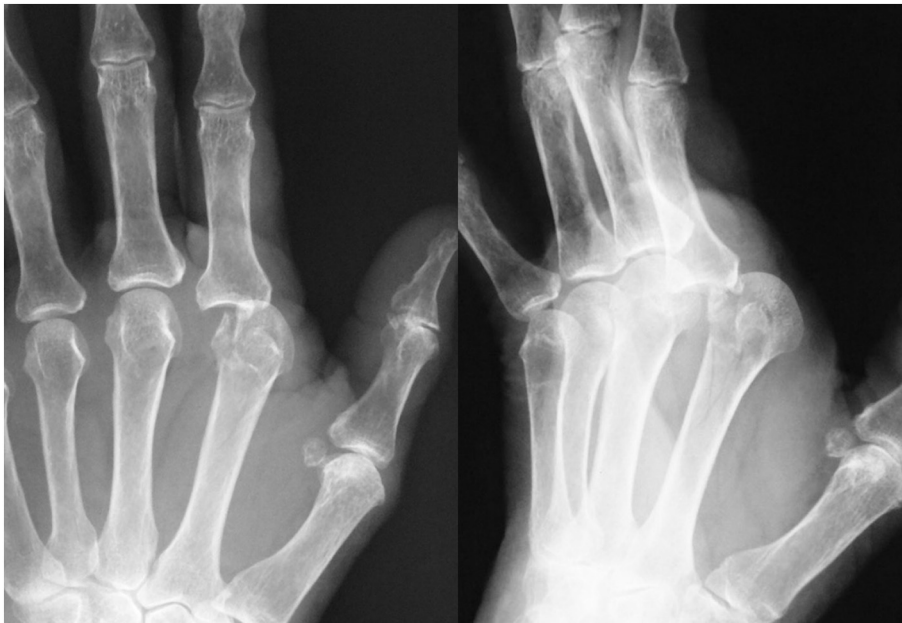

Fig. 1. Radiography showing dorsal dislocation of the MP joint.

was fitted into the metacarpal neck (Figs. 2, 3).

Four days after the injury, surgery was performed under general anaesthesia. The distal radius fracture was fixed using a volar locking plate. The fracture-dislocation of the MCP joint was reduced through a dorsal approach with a longitudinal incision. The volar plate of the MCP joint was discovered to be interposed between the fracture sites and inhibited the reduction. Therefore, the volar plate was longitudinally split, and the metacarpal head was reduced. Because the distal fracture part was unstable, the bone defect was filled with β -tricalcium phosphate granules, and two headless screws were intramedullary inserted using the Y-strutting technique from the metacarpal head as described by del Piñal's method [1]. This fixation achieved satisfactory stability. Postoperatively, an active mobilisation of the left index finger started after bandage fixation with the middle finger. Four months postoperatively, bone union was obtained without any sign of avascular necrosis of the metacarpal head (Fig. 4). The MCP joint of the index finger presented no pain. The active extension was 0°, flexion was 40°, and the total active range of motion was 150°.

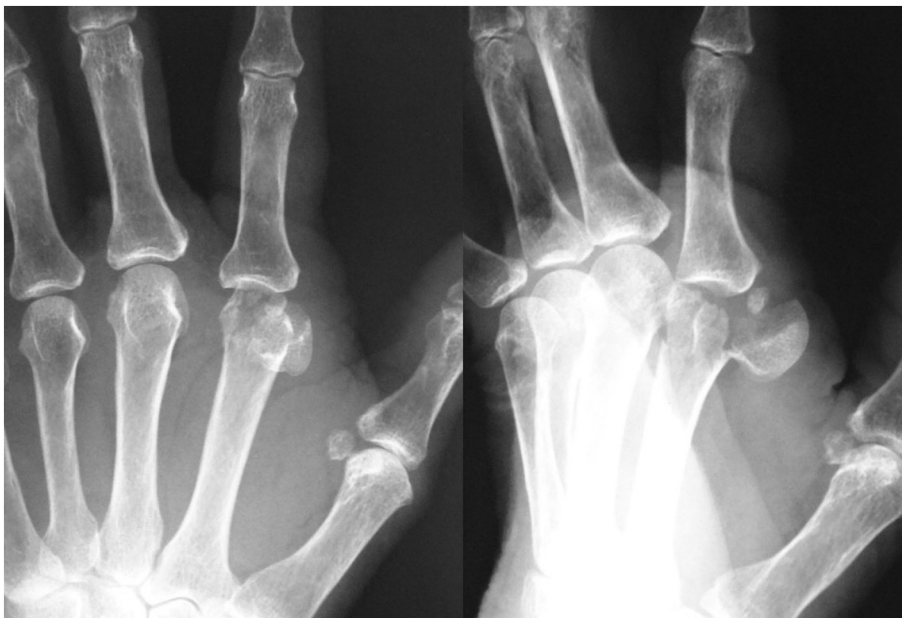


Fig. 2. Radiography after closed reduction showing complete displacement of the second metacarpal head to the volar side.

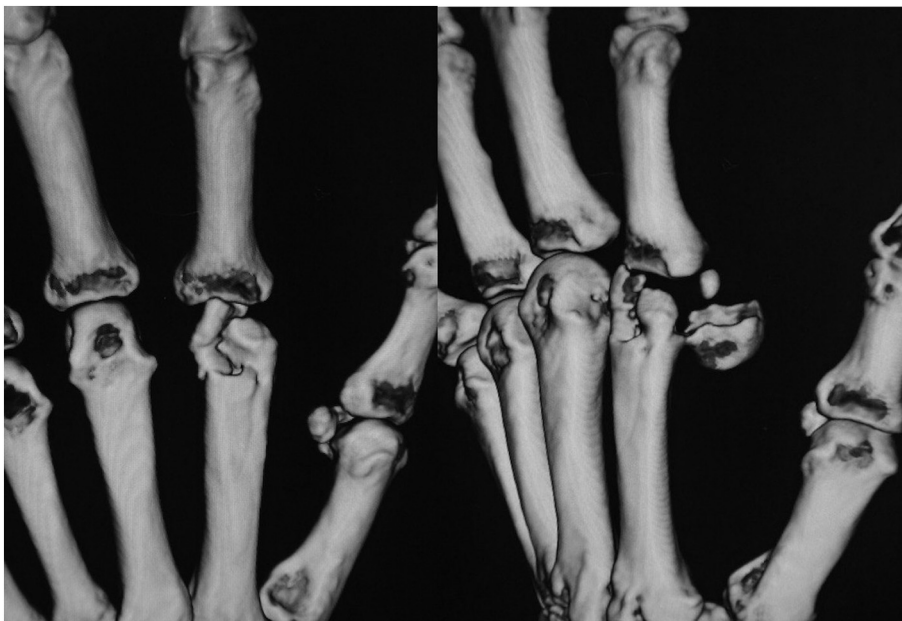

Fig. 3. Three-dimensional computed tomography reconstruction after closed reduction.

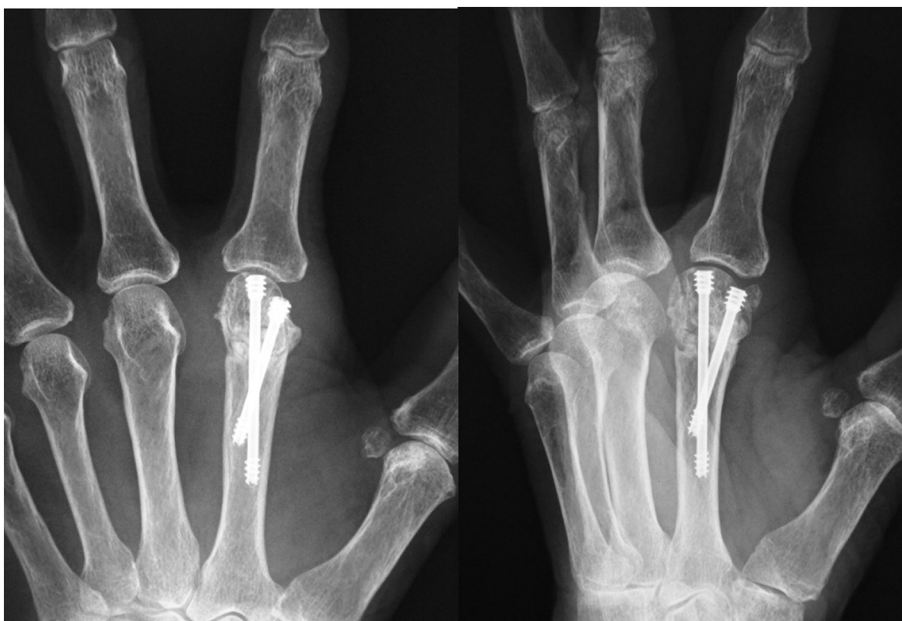

Fig. 4. Radiography at 4 months postoperatively showing bone union without an indication of avascular necrosis.

Discussion

Complex dorsal MCP joint dislocation of the finger is a rather uncommon injury, especially in the elderly. They are almost always irreducible and operative treatment is required to free soft tissues frequently interposed between the metacarpal head and proximal phalanx. Kaplan first described the pathogenesis and anatomy of irreducible MCP joint dislocations in detail [2]. The anatomic basis of the complexity and irreducibility of MCP joint dislocations involves the volar plate, A1 pulley, flexor tendons, and lumbricals. The interposition of the volar plate is regarded as a major factor inhibiting the closed reduction. The anatomy of the structures surrounding the MCP joint is variable, and careful dissection to prevent iatrogenic injuries is mandatory [3].

To our knowledge, the iatrogenic displacement of the metacarpal head during a closed reduction of MCP joint dislocations has not been reported so far. However, iatrogenic fractures during closed reduction have been reported in dislocations of the shoulder joint.

In the shoulder joint, a careful reduction, the use of fluoroscopy, an adequate anaesthesia, etc. help in preventing damage during the process [4,5]. Although care and attention are crucial, a closed reduction of a dislocated shoulder joint is relatively easy to achieve. On the other hand, it is unlikely that a closed reduction of the complex dorsal MCP joint dislocations will be successful, apart from the possibility of complications.

Conclusion

Careless attempting a closed reduction of the complex dorsal MCP joint dislocations might be contraindicated especially in elderly patients who often show bone fragility.

Declaration of competing interest

The authors declare no conflict of interest.

References

- [1] F. del Piñal, E. Moraleda, J.S. Rúas, G.H. de Piero, L. Cerezal, Minimally invasive fixation of fractures of the phalanges and metacarpals with intramedullary cannulated headless compression screws, *J. Hand Surg. Am.* 40 (4) (2015) 692–700.
- [2] E.B. Kaplan, Dorsal dislocation of the metacarpophalangeal joint of the index finger, *J. Bone Joint Surg. Am.* 39 (5) (1957) 1081–1086.
- [3] A.M. Afifi, A. Medoro, C. Salas, M.R. Taha, T. Cheema, A cadaver model that investigates irreducible metacarpophalangeal joint dislocation, *J. Hand Surg. Am.* 34 (8) (2009) 1506–1511.
- [4] O. Hersche, C. Garber, Iatrogenic displacement of fracture-dislocations of the shoulder. A report of seven cases, *J. Bone Joint Surg. Br.* 76 (1) (1994) 30–33.
- [5] M. Koda, J. Hisamitsu, S. Nakayama, et al., Successful closed reduction for iatrogenic displacement of the anatomical neck of the humerus: a case report, *BMC Research Notes* 7 (2014) 770.