

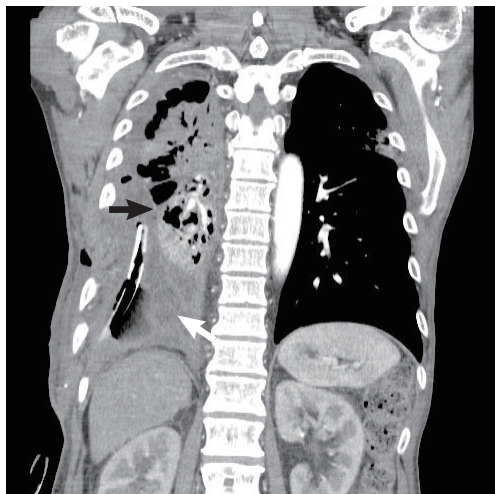

Fig. 5. Two weeks postoperatively, a chest computed tomography scan shows the pleural space filled by the intrathoracic transposition of the latissimus dorsi muscle flap (white arrow). A chest computed tomography scan of the right upper lobe shows pneumonia (black arrow).

adduction, and internal rotation of the shoulder joint, it does not function independently. Since it moves in synchrony with a number of synergistic shoulder girdle muscles, the LD muscle can be sacrificed safely without affecting shoulder or arm action [5].

A major surgical advantage of using the LD muscle flap in the field of thoracic surgery is the fact that, because it is an extrathoracic muscle, ipsilateral lung surgery can be performed while simultaneously obtaining the LD muscle through a single posterolateral thoracotomy incision. Furthermore, due to its large bulk and long vascular pedicle, the LD muscle flap can move in apical or mid-thoracic dead space easily with minimal tension, obliterating the pleural space. However, because a LD flap based on the thoracodorsal artery can be short, alternative flaps (e.g., a rectus abdominis flap) should be considered for movement to the lower, supra-diaphragmatic recess of the pleural space. Various flaps can also be used depending on the location of the dead space, such as a serratus anterior flap for the upper region of the thorax and a pectoralis flap or a trapezius flap for the apical region.

Tuberculous empyema is uncommon and, unlike other types of empyema, difficult to treat. We performed a lobectomy and used the intrathoracic transposition of a LD muscle flap into the resulting cavity to treat a tuberculous empyema patient who had not improved from the administration of antituberculosis drugs and chest tube drainage. This operation was relatively easy and the patient had no

recurrence of empyema or other complications.

References

1. World Health Organization. Global tuberculosis report 2015 [Internet]. Geneva, Switzerland: World Health Organization; c2015 [cited 2015 Dec 29]. Available from: http://www.who.int/tb/publications/global_report/en/.
2. Jess P, Brynitz S, Friis Moller A. Mortality in thoracic empyema. *Scand J Thorac Cardiovasc Surg* 1984;18:85-7.
3. Iseman MD, Madsen LA. Chronic tuberculous empyema with bronchopleural fistula resulting in treatment failure and progressive drug resistance. *Chest* 1991;100:124-7.
4. Meyer AJ, Krueger T, Lepori D, et al. Closure of large intrathoracic airway defects using extrathoracic muscle flaps. *Ann Thorac Surg* 2004;77:397-404.
5. Abolhoda A, Bui TD, Milliken JC, et al. Pedicled latissimus dorsi muscle flap: routine use in high-risk thoracic surgery. *Tex Heart Inst J* 2009;36:298-302.

Non-Invasive Imaging of Preoperative Mapping of Superficial Veins in Free Flap Breast Reconstruction

Michael W Chu¹, Jonathon R Sarik², Liza C Wu³, Joseph M Serletti³, Jonathan Bank⁴

¹Division of Plastic and Reconstructive Surgery, Indiana University, Indianapolis, IN; ²Department of Surgery, Thomas Jefferson University, Philadelphia, PA; ³Division of Plastic and Reconstructive Surgery, University of Pennsylvania, Philadelphia, PA; ⁴New York Breast Reconstruction Associates, Great Neck, NY, USA

Correspondence: Michael W Chu
Division of Plastic and Reconstructive Surgery, Indiana University, 545 Barnhill Drive #232, Indianapolis, IN 46202, USA
Tel: +1-215-662-7300, Fax: +1-215-662-2172
E-mail: dr.michael.chu@gmail.com

No potential conflict of interest relevant to this article was reported.

Received: 20 Jul 2015 • Revised: 21 Sep 2015 • Accepted: 24 Sep 2015
pISSN: 2234-6163 • eISSN: 2234-6171
<http://dx.doi.org/10.5999/aps.2016.43.1.119>
Arch Plast Surg 2016;43:119-121

Copyright © 2016 The Korean Society of Plastic and Reconstructive Surgeons
This is an Open Access article distributed under the terms of the Creative Commons Attribution Non-Commercial License (<http://creativecommons.org/licenses/by-nc/3.0/>) which permits unrestricted non-commercial use, distribution, and reproduction in any medium, provided the original work is properly cited.

Vascular anatomy is imperative in reconstructive surgery to ensure perfusion and accurate flap design,

but venous anatomy can be difficult to determine preoperatively. Anatomic landmarks can be used to locate structures; however there can be considerable variation in anatomy and location of veins.

Techniques such as radiographic imaging, Doppler probes, and ultrasonography have been used to assess veins. However, radiographic imaging incurs a cost and radiation exposure. Doppler probes are easy to use but are more useful for arterial anatomy. Ultrasonography is limited by cost, time, and accessibility.

Several vein visualization devices, including the AccuVein (Avant Medical, Cold Spring Harbor, NY, USA), have been previously reported as an adjuvant to locate veins [1] and to aid intravenous cannulation. These devices were helpful to visualize veins, especially in difficult patients (extremes of age, obese, dark-skinned) [2-4]. The AccuVein is a portable device (size, 5 × 6 × 20 cm; weight, 275 g) that emits a red laser at 642 nm and an infrared laser at 785 nm. Hemoglobin preferentially absorbs infrared light so the skin the skin illuminated a red color and veins are silhouetted as dark outlines (Fig. 1). The color schemes can also be inverted to display veins as red silhouettes on the skin.

The AccuVein device was used in our study for abdominal-based free flap breast reconstruction to aid in locating abdominal veins and to evaluate candidacy for superficial inferior epigastric artery (SIEA) perforator flaps. To the best of our knowledge the use of this device in breast reconstruction has not been reported.

The current practice at our institution for planned

free flap breast reconstruction involves intraoperative decision-making to determine flap type [5]. Routine preoperative radiographic imaging is not obtained. After making the inferior incision on the abdomen the SIEA is carefully identified. If the SIEA is absent, injured, or of insufficient caliber (< 1.5 mm) then an SIEA flap is not used and the deep inferior epigastric system is assessed next. Medial and lateral row perforators are identified and a decision is then made to use either a deep inferior epigastric artery perforator flap or a muscle-sparing free transverse rectus abdominis musculocutaneous flap [5].

In our study the AccuVein was used for preoperative venous mapping of the superficial inferior epigastric veins (SIEV), superficial circumflex iliac veins, and to help guide dissection and flap design of the inferior skin paddle incision (Fig. 2). If an adequate SIEV was visualized preoperatively, the inferior skin incision was occasionally redesigned and made more inferior to ensure inclusion of the vascular pedicle before it arborizes.

The AccuVein was used on ten patients. In eight patients at least one SIEV was identified preoperatively in all patients and there was 100% positive and negative correlation of preoperative markings with intraoperative exploration (Fig. 3), and all veins were able to be identified intraoperatively. In the other two patients had abdominal striae that interfered with venous imaging and abdominal veins were not able to be visualized. In two patients preoperative vein mapping changed the flap design: the inferior incision was lowered to explore the vein before it bifurcates to include a larger caliber vessel in the flap for flap drainage or when patients were possible SIEA flap candidates. There were no AccuVein related complications and no false

Fig. 1.
(A, B) Hand-held vein visualization device, (AccuVein) uses a red laser and infrared laser to illuminate basilic and cephalic venous vasculature for the forearm.

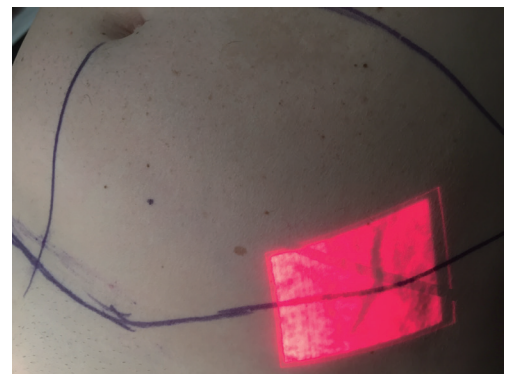
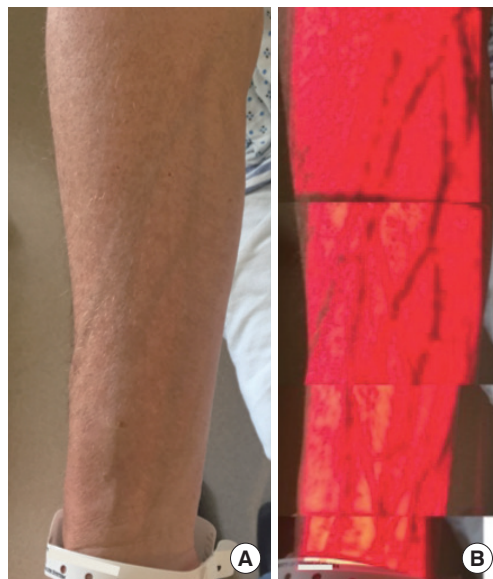

Fig. 2.
Preoperative visualization of left superficial epigastric vein before breast reconstruction.

negatives that led to adverse flap planning. There were also no other perioperative complications or microvascular complications or flap losses for all ten patients and patients were on average, discharged on postoperative day 4.1 (range, 4–5).

The AccuVein is a non-invasive, portable, fast, and easy to use device to assess veins in real time. The disadvantages of this device are that it only produces a two dimensional image and the vein is displayed based on vessel content and not the actual vessel caliber. Although there were no false positives in our study, we recommend direct visualization of vessel caliber before any surgical decisions are made. The AccuVein can provide preoperative information about venous anatomy that can be useful in aiding dissecting veins and flap design.

The AccuVein is not necessary to successfully perform free flap breast reconstruction but we believe the AccuVein is an effective adjuvant that can help aid flap design and expedite dissection. The SIEV is a useful lifeboat that can be used as venous outflow for abdominal-based flaps and also used as a vein graft. Anatomic landmarks exist for most critical structures, and the SIEV is also consistently found midway between the anterior superior iliac spine and the midline. But anatomy can be variable and the AccuVein can expedite dissection and flap design.

Preoperative vein mapping can be useful for those starting to perform SIEA perforator breast free flap reconstructions. Preoperative venous mapping can help guide flap design and speed dissection of the SIEV and SIEA vena comitans. Radiographic imaging provide much more information than can AccuVein, but also costs more, is invasive if contrast-enhanced imaging is used, may require radiation exposure, and needs time to schedule, perform, and review images. On the other hand, the AccuVein device is often already available in many hospitals in the nursing units and is a simple, cheap, noninvasive, and quick method for preoperative mapping of superficial veins.

References

1. Iida T, Mihara M, Yoshimatsu H, et al. Versatility of a near-infrared vein visualization device in plastic and reconstructive surgery. *Plast Reconstr Surg* 2012;130:636e-638e.
2. Kaddoum RN, Angheliescu DL, Parish ME, et al. A randomized controlled trial comparing the AccuVein AV300 device to standard insertion technique for intravenous cannulation of anesthetized children.

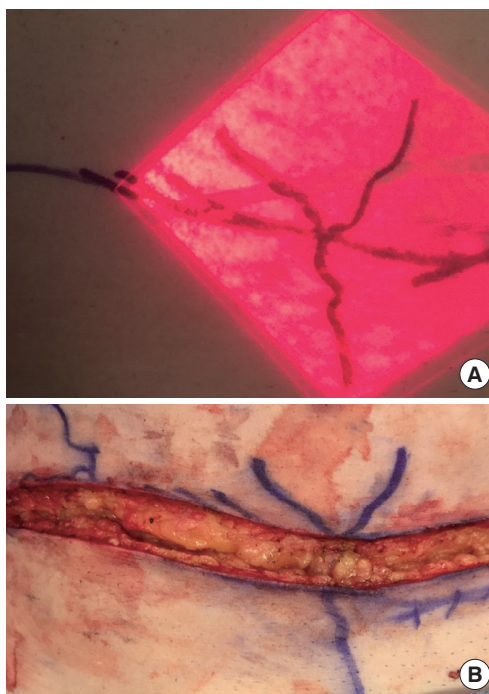


Fig. 3. (A, B) Preoperative and intraoperative photographs of superficial epigastric vein during the donor site dissection of abdominal-based free flap breast reconstruction using right hemi-abdomen.

Paediatr Anaesth 2012;22:884-9.

3. de Graaff JC, Cuper NJ, Mungra RA, et al. Near-infrared light to aid peripheral intravenous cannulation in children: a cluster randomised clinical trial of three devices. *Anaesthesia* 2013;68:835-45.
4. Aulagnier J, Hoc C, Mathieu E, et al. Efficacy of AccuVein to facilitate peripheral intravenous placement in adults presenting to an emergency department: a randomized clinical trial. *Acad Emerg Med* 2014;21:858-63.
5. Vega S, Smartt JM Jr, Jiang S, et al. 500 Consecutive patients with free TRAM flap breast reconstruction: a single surgeon's experience. *Plast Reconstr Surg* 2008;122:329-39.