



eTEP-RS for incisional hernias in a non-robotic center. Is laparoscopy enough to perform a durable MIS repair of the abdominal wall defect?

Kryspin Mitura^{1,2} · Michał Romańczuk² · Krystian Kisielewski² · Bernard Mitura³

Received: 8 March 2022 / Accepted: 22 May 2022

© The Author(s), under exclusive licence to Springer Science+Business Media, LLC, part of Springer Nature 2022

Abstract

Introduction Incisional hernias can complicate up to 25% of laparotomies, and successful repair remains a significant clinical challenge for surgeons. Recently, the surgical technique of ventral hernia repair (eTEP-RS) has been introduced. The method was presented relatively recently and continues to evolve. The use of a robotic platform in eTEP-RS resulted in a significant improvement in ergonomics. Therefore, the questions arise as to whether the laparoscopic technique might still be feasible for such long procedures. The objective of this study is to present our early results in the treatment of patients with incisional ventral hernias using eTEP-RS and to discuss key technical aspects.

Patients and methods A prospective case-controlled study was conducted for all incisional ventral hernia patients (hernia orifice between 4 and 10 cm) who underwent eTEP-RS between March 2019 and December 2021. Demographic data were recorded; and perioperative and postoperative results were analyzed.

Results We performed 34 eTEP-RS procedures. The mean duration of the surgery was 211 min (145–295). The mean width of the defect was 6.8 cm and the defect area was 42.5 cm². The mean mesh size was 498 cm² (270–625). After an average follow-up of 16 months (2–30), there was no recurrence or major complication.

Conclusions The eTEP-RS is a safe alternative to open ventral hernia repair in selected cases and allows for the placement of a large piece of mesh in accordance with current recommendations, even in non-robotic centers. Excellent knowledge of the detailed anatomy of the abdominal wall is essential for safe and effective hernia repair. Compliance with certain rules of the laparoscopic eTEP-RS facilitates improved ergonomics for this procedure even in non-robotic centers.

Keywords Hernia repair · eTEP · Laparoscopic · Incisional · Ventral · MIS

Laparoscopic repair of ventral incisional hernia repair was developed nearly three decades ago and has since proven to reduce surgical site infection rates, allow quick recovery, and reduce recurrence rates [1]. This technique has gained worldwide popularity due to its technical simplicity and low learning curve. Initially, the defect was covered intraperitoneally with mesh anchored to abdominal wall (intra-peritoneal underlay mesh; IPUM), which in some cases led to bulging due to mesh protrusion through an open defect.

A decade later surgeons started to close the defect, which allowed the reduction of bulging and seroma formation (IPUM-plus) [2]. However, the main limitation remained the direct contact between the viscera and the mesh leading to mesh shrinkage and erosion, chronic pain due to penetrating fixation. Despite the use of a mesh with a protective anti-adhesive layer, surgeons still witnessed some delayed complications, such as peritoneal adhesions, bowel obstruction, and rarely enterocutaneous fistula formation [3]. Again, the initial enthusiasm associated with a novel technique turned into a disappointment as some above-mentioned limitations associated with IPUM were revealed, and many surgeons still perform open retromuscular sublay repair. To avoid placing the mesh in the peritoneal cavity, new techniques have been developed. In 2018, Belyansky et al. published a report on a new technique of minimally invasive retromuscular mesh placement, incorporating the benefits of laparoscopic approach with the durability of open sublay

✉ Kryspin Mitura
chirurgia.siedlce@gmail.com

¹ Faculty of Medical and Health Sciences, Siedlce University of Natural Sciences and Humanities, Siedlce, Poland

² Siedlce Hospital, ul. Starowiejska 15, 08-110 Siedlce, Poland

³ Faculty of Medicine, Jagiellonian University Medical College, Cracow, Poland

techniques [4]. The presented technique, known as eTEP-RS (enhanced view totally extraperitoneal Rives Stoppa repair), was a further development of an eTEP (extended-view totally extraperitoneal) technique introduced for a laparoscopic repair of inguinal hernias as described six years earlier by Daes [5]. The eTEP-RS showed promising results and low postoperative complication rates, and its popularity has recently increased significantly among surgeons performing abdominal wall reconstruction [6–8]. This innovative repair offers a reliable and reproducible reconstruction of the abdominal wall that allows a midline approximation of the myofascial compartment. Furthermore, the application of polypropylene mesh instead of composite mesh greatly reduces the total cost of a repair [9]. Placing a mesh into extraperitoneal plane allows one to decrease the need for penetrating mesh fixation, thus minimizing expenses even more.

Since the initial presentation of the outcomes by Belyansky et al. in 2018, various articles have been published presenting the results of eTEP-RS in the repair of abdominal incisional hernia [4]. The use of the robotic platform allowed to perform these repairs in a more facilitated manner with the added ergonomics [6]. Several studies with solid evidence supporting eTEP-RS performed with only laparoscopic approach have been published recently [7, 8]. The objective of this study is to present our early results in treating patients with ventral incisional hernias using the eTEP-RS technique and to discuss key technical aspects affecting the safety and efficiency of this reconstructive surgery. We believe that eTEP-RS can be safely and effectively performed in laparoscopy and allows a surgeon to place a large flat synthetic mesh in retrorectus plane without additional fixation which might have a beneficial influence on the postoperative pain.

Materials and methods

A prospective case-controlled study of early outcomes was conducted for all adult patients presenting with incisional ventral hernia who underwent eTEP-RS between March 2019 and December 2021 at our institution. We included only patients with a hernia defect classified by EHS (European Hernia Society) as W2 (diameter between 4 and 10 cm) [10]. Defects below 4 cm were treated with TAPP (totally preperitoneal) or open sublay approach and were not included in the study. Defects larger than 10 cm were repaired with the open sublay technique and were not included in the study. Patients with recurrent hernias after previous mesh insertion in the retromuscular plane were excluded. Patients with skin ulcerations, enterocutaneous fistulas, or domain loss were excluded from the study. The exclusion criteria included patients with contraindication for

general anesthesia and patients with incarcerated or strangulated hernias. Demographic data were recorded; perioperative and early postoperative outcomes were analyzed. Patient demographics included age, sex, body mass index (BMI), previous abdominal operations, history of smoking and alcoholism, and concomitant comorbidities. The hernia characteristics recorded included the hernia site, the size of the defect, and the number of previous repairs, if any. Intraoperative and perioperative data included mesh size, duration of the procedure, unintended entry into peritoneal cavity (peritoneal rents) and complications (bleeding, hematoma, seroma, wound infection, postoperative ileus, pain), drain use, and length of stay. The postoperative satisfaction assessment according to the Likert scale (the intensity of the pain on the VAS scale (0—no pain; 10—most intense pain) and other delayed complications occurring after 30 days in these patients were carried out using a questionnaire at the time of the termination of the study.

Preoperative workup

The detailed history of all patients was analyzed, and a systemic examination was performed including the location of the hernia, its size, the evaluation and reducibility of the content, and the location of the scar after previous surgery. Computed tomography was performed in all cases prior to the operation to assess hernia. We used the European Hernia Society (EHS) classification for primary and incisional abdominal wall hernias [10]. After a comprehensive workup, informed consent was collected. According to local guidelines, a deep vein thrombosis (DVT) prophylaxis (enoxaparine 40 mg) was applied in each patient twelve hours before surgery. A single broad-spectrum prophylactic antibiotic dose (cephazoline 2 g) was administered approximately 0–30 min before incision time.

Operating technique

The eTEP technique was performed as previously described by Belyansky et al., with a few modifications [4].

Port placement

The location of the initial ports depends on the hernia site. For epigastric hernias, first ports are inserted below umbilicus, while for umbilical or infraumbilical hernias an upper approach in epigastrium is more feasible (Fig. 1). After placing the first 10 mm trocar into the retromuscular plane, this space is expanded with ‘telescoping’ and carbon dioxide insufflation (12 mmHg). Then, two

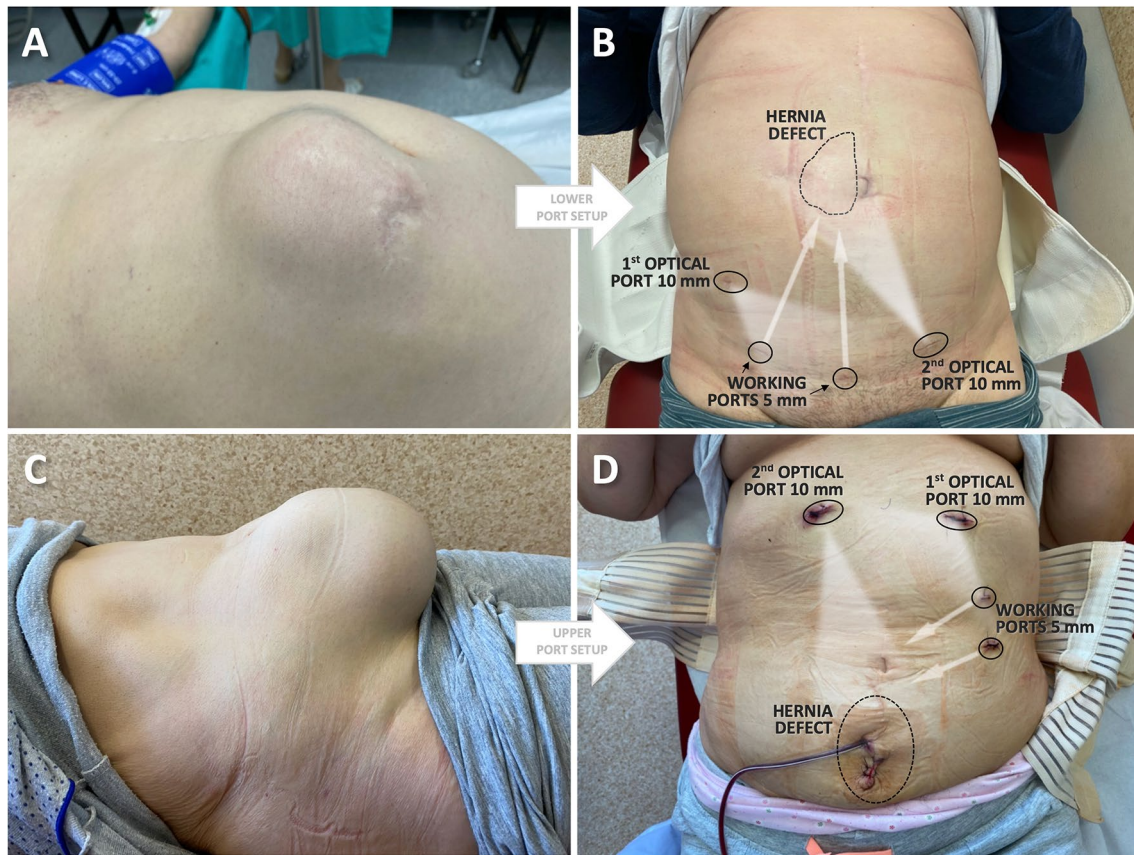


Fig. 1 Port placement in e-TEP-RS ventral hernia repair for periumbilical or epigastric hernia (A, B) and hypogastric or suprapubic hernia (B–D)

additional 5 mm working ports are inserted just medially to the semilunar line, and a dissection of the posterior rectus sheath (PRS) from the rectus muscle is performed using monopolar electrocautery with hook or scissors. The lateral extension of the dissection is performed up to the semilunar line where neurovascular bundles are identified ('lamppost sign') [11]. The medial extent of the dissection reaches the medial border of the rectus muscle as close as possible to a linea alba.

Crossover

This maneuver is performed using a monopolar hook and allows one to open a contralateral retrorectus plane (Fig. 2A). First, a surgeon must incise an ipsilateral PRS at a distance of 5–7 mm from its insertion to linea alba. The falciform ligament fatty tissue (or median umbilical ligament in hypogastrium) becomes visible and needs to be dissected bluntly downward from an intact linea alba. On the opposite side, a contralateral PRS is incised 5–7 mm lateral to its insertion to the linea alba. Extreme caution

is necessary to avoid damaging a linea alba, which could potentially lead to new iatrogenic hernia.

Dissection of the hernia sac

After preliminary dissection of contralateral retrorectus plane, another 10 mm trocar is introduced on the opposite side for camera placement. The dissection is then performed behind the rectus muscles on both sides toward the hernia defect (Fig. 2B). Once the hernia sac is reached, it should not be dissected until both retromuscular planes are broadened as inferior as possible, preferably below the level of a hernia defect (270° around the hernia defect). This maneuver allows us to visualize a 'volcano' sign (Fig. 2C). Then a hernia site is dissected, the content is reduced, and the sac is incised if needed (Fig. 2D). The caudal and cranial dissection range must allow for a mesh placement with at least 5 cm in each direction, which in the case of infraumbilical hernia can result in a Retzius space dissection as in groin hernias.

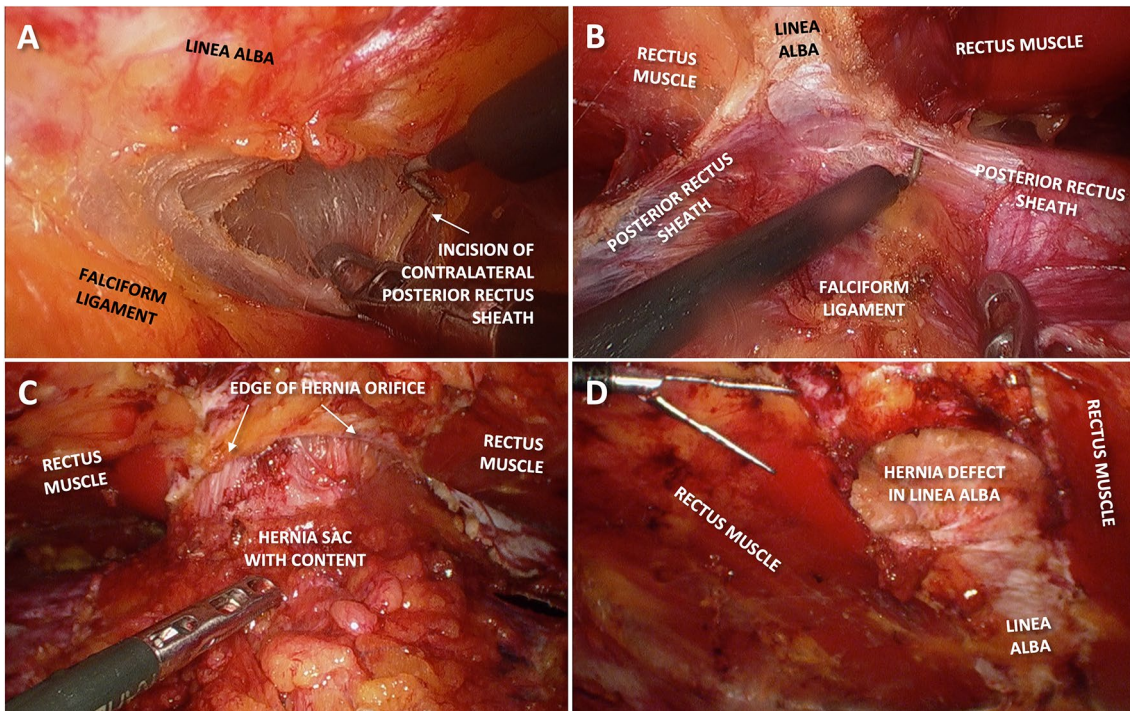


Fig. 2 Retromuscular dissection in e-TEP-RS repair. Crossover to the contralateral side (A). Medial incision of both posterior sheaths (B). Volcano sign (C). Dissected hernia defect with reduced content (D)

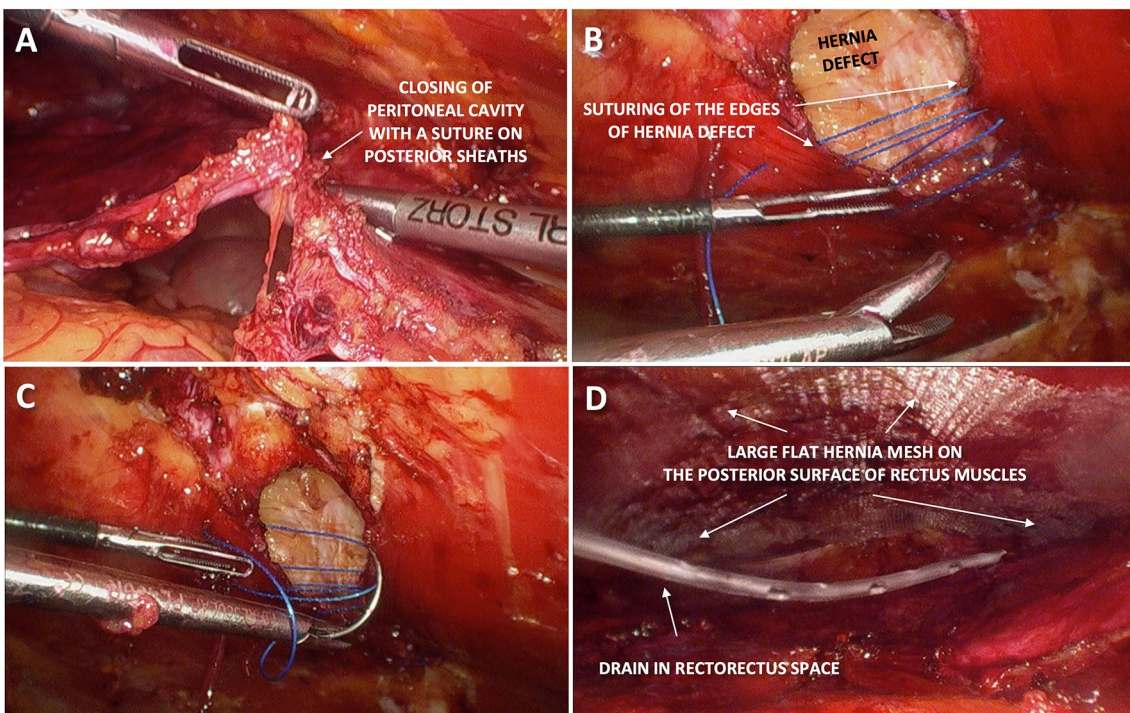


Fig. 3 Reconstruction of the abdominal wall in the repair of e-TEP-RS. Closure of the posterior layer (A). Closure of hernia defect (B, C). Large flat mesh positioned below the rectus muscles and a drain placed beneath (D)

Closure of the hernia defect and peritoneum/PRS

If the peritoneum around the hernia defect was opened, it should be closed beforehand (Fig. 3A). Usually, closing both PRS laminas together is cumbersome and may cause some tension leading to fascia disruption. Therefore, closing the peritoneum alone is enough to complete the separation of the viscera from the mesh. Then both margins of hernia defect are sutured together with a non-absorbable barbed suture (V-Loc™ No. 0 by Medtronic, Dublin, Ireland) in a continuous manner with a shoe-lacing technique (Fig. 3B, C).

Mesh placement and fixation

The dissected space is measured in both directions and appropriate margins of at least 5 cm are needed for most hernia defects; however, we always attempt to maintain mesh-to-defect surface ratio of 16:1. A self-fixating macroporous polyester mesh with resorbable polylactic acid microgrips (Progrid™ by Medtronic, Dublin, Ireland) is inserted and positioned flat with microhooks directed upward. For the largest defects, a heavyweight mesh was used (Optilene, B.Braun, Melsungen, Germany). Then, the gas is temporarily deflated from the retrorectus plane, allowing mesh adherence to the posterior aspect of the reapproximated medially rectus muscles. Subsequent gas insufflation confirms the proper position of the mesh. One or two drains are inserted below the mesh, the gas is finally deflated and the trocars are removed with the port sites closed (Fig. 3D).

Table 1 Demographic data

	Total (n=34)	%	Range
Mean age (years)	51.7 ± 11.5		23–76
Males	15	44.1	
Females	19	55.9	
BMI (kg/m ²)	31.2 ± 4.8		24.5–37.8
<i>Concomitant diseases</i>			
Hypertension	9	26.5	
Diabetes mellitus	8	23.5	
Coronary disease	2	5.9	
Chronic obstructive pulmonary disease	3	8.8	
Smoking	10	29.4	
Alcoholism	3	8.8	
<i>Previous hernia repairs</i>			
One	5	14.7	
Two	2	5.9	
Three and more	1	2.9	

Data analysis

All data are presented as means, standard deviations, and percentages. Descriptive statistics were produced for the data set. Categorical variables are presented as *n* (%), and continuous variables are presented as the mean ± SD and range. Statistical analysis of all data was performed using the Statistica 13.1 (StatSoft, Round Rock, TX, USA) program.

Results

A total of 34 patients underwent e-TEP-RS repair for incisional hernia between March 2019 and December 2021 (this period includes three lockdowns in elective surgery due to the COVID-19 pandemic, resulting in total in 7 months of inactivity). The demographic data and comorbidities of the patients are listed in Table 1. Of these, 15 (44.1%) were men and the mean age was 51.7 ± 11.5 years (range 23–76) with an average BMI of 31.2 ± 4.8 kg/m² (range 24.5–37.8). Hypertension and diabetes were the most common comorbidities (26.5 and 23.5%, respectively). 29.5% of the patients were smokers.

Table 2 Hernia characteristics and classification according to EHS

	Total (n=34)	%
Incisional	34	100
Without previous repair	27	79.4
Recurrent	7	20.6
<i>Location</i>		
M1 (subxiphoid)	2	5.9
M2 (epigastric)	7	20.6
M3 (umbilical)	16	47.1
M4 (infraumbilical)	8	23.5
M5 (suprapubic)	1	2.9

Table 3 Technical details and intraoperative complications

	Total (n=34)	%	Range
Average defect width (cm)	6.8 ± 4.8		4.0–9.5
Mean defect area (cm ²)	42.5 ± 32.8		16.0–93.0
Mean mesh area (cm ²)	498 ± 114.2		270–625
Duration of surgery (min)	211 ± 53.8		145–295
Drain placement	29	85.3	
<i>Complications</i>			
Conversion to open surgery	0	0	
Enterotomy	0	0	
Need for IPUM repair due to PRS defect unable to close	2	5.9	
Length of stay (days)	4 ± 1.6		2–7

The cases were classified according to the EHS classification for incisional abdominal wall hernias and categorized (Table 2).

The mean width of the defect was 6.8 ± 4.8 cm (range 4.0–9.5) and the mean area of the defect was 42.5 ± 32.8 cm² (range 16.0–93.0) (Table 3). The mean mesh area was 498 ± 114.2 cm² (range 270–625). Almost all patients had a drain inserted into the retrorectus plane (85.3%). In four cases (11.8%), we were unable to close the posterior defect in the peritoneum and PRS due to excessive tension in the suture line. Two of these patients received additionally an IPUM anti-adhesive mesh patch to cover a posterior defect, and the remaining two had a greater omentum sutured to the defect margins. The mean duration of surgery was 211 ± 53.8 min (range 145–295); however, this time was significantly decreasing with growing experience (Fig. 4). The mean surgery time for the first five cases was 243 min, while for the last 5 cases it was only 174 min. The mean stay duration was 4 ± 1.6 days (range 2–7).

The main early complications ($n = 4$; 11.8%) included a hematoma (2.9%) and two seromas (5.9%) (Table 4). None of these required surgical intervention and resolved spontaneously. There was one minor superficial surgical site infection (2.9%), treated with antibiotics and antimicrobial dressings. After a mean follow-up of 16 ± 9.7 months (range 2–30), there were no recurrences. The mean pain intensity was 1.2 ± 0.8 (range 0–3) according to visual analog scale. The vast majority (94.1%) of the patients reported complete satisfaction after the surgery, and the remaining group (5.9%) declared moderate satisfaction.

Table 4 Postoperative findings, outcomes and complications

	Total ($n = 34$)	%	Range
<i>Early postoperative complications</i>			
SSI	1	2.9	
Hematoma	1	2.9	
Seroma	2	5.9	
Recurrence	0	0	
Mean follow-up (months)	16 ± 9.7		2–30
Mean pain intensity (VAS points)	1.2 ± 0.8		0–3
<i>Patient's satisfaction</i>			
Poor	0	0	
Moderate	2	5.9	
Full	32	94.1	
<i>Late complications</i>			
Recurrence	0	0	

Discussion

Ventral hernia repair is one of the most common surgical procedures in general surgery [12]. The incidence of incisional ventral hernia reaches 28% after ventral surgeries. The optimal treatment for incisional abdominal wall hernias is still under debate [12]. The main goal of safe and successful surgery is durable repair with low morbidity and recurrence rates [13]. In general, open repair is correlated with a slow recovery course and a higher risk of wound infection. The success of TAPP (transabdominal preperitoneal) and TEP (totally extraperitoneal) repair for groin hernias

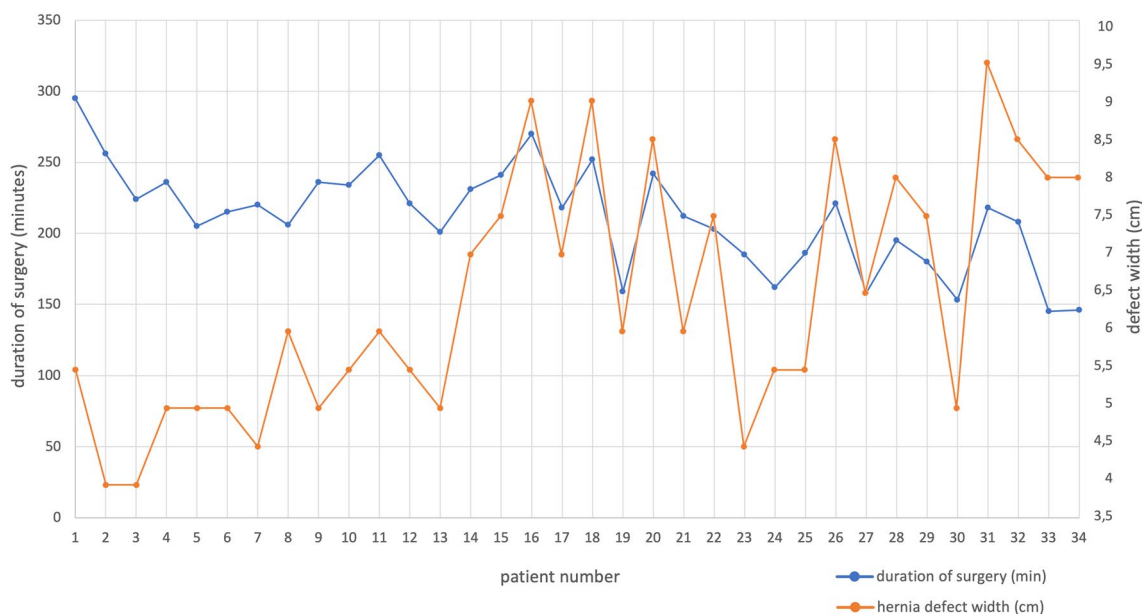


Fig. 4 Duration of surgery and width of the defect after laparoscopic repair of the ventral hernia of e-TEP-RS

was undisputable, so the extraperitoneal plane began to be noticed in minimally invasive repair for incisional hernias [14]. Although laparoscopic surgery for abdominal wall hernia has gained recognition in the twenty-first century, there is still a dispute about the ideal approach. Nowadays, so many diverse alternatives for the management of these hernias are available from different open to other minimally invasive techniques [1–3, 5, 14]. The diversity of methods makes the decision-making process more demanding in incisional hernia. Surgeons still look for the optimal or standardized technique that adequately minimizes complications and improves results. Current evidence shows that the laparoscopic approach has the advantage of a shorter hospital stay after repair, an early return to work, and reduced surgical wound complications compared to the open approach [15]. The latest developments in abdominal wall reconstruction have offered surgeons a wide range of methods to repair various ventral hernias. Closure of parietal defects simplifies mesh integration and restores the structure of the abdominal wall, which has a significant implication for its function [16]. The e-TEP-RS approach, according to Pascal's law, provides a plane for reinforcement of the abdominal wall [17]. There was no recurrence of hernia during the follow-up period in our group. Other researchers show similar results with recurrence rates not exceeding 3%, but the heterogeneity of these groups should be acknowledged [2, 3, 10].

The benefits of eTEP-RS are derived from the creation of the extraperitoneal retromuscular plane, excluding the need for a barrier mesh or its fixation. Furthermore, and most importantly, it prevents direct contact between the bowel and a mesh. In retromuscular position, mesh is sandwiched between rectus muscles and posterior rectus sheath, and thus can be positioned without additional fixation. In other types of ventral hernia repair, multiple sutures or tacks have been shown to contribute to pain in the immediate postoperative period, and to chronic postoperative pain due to nerve entrapments [18]. None of our patients reported chronic pain or was dissatisfied with the outcome. According to Penchev et al. retrospective comparative study between eTEP-RS and IPUM, a reduced pain score has been reported in eTEP-RS patients [19]. As the mesh is placed in the retrorectus plane and no fixation technique is used, these aspects might be the most valuable feature of the eTEP approach allowing for a low pain intensity. In a studied group, we did not use TAP (transversus abdominis plane) blocks, as this technique was introduced just recently in our department. In postoperative period there was no need for an opioid use, and patients routinely were administered paracetamol or nonsteroidal anti-inflammatory drugs (NSAIDs) on demand. The lower cost of flat non-barrier mesh compared to intraperitoneal mesh may help reduce costs compared to IPUM, but in the early phase of the learning curve these advantages might be offset by a prolonged duration of the procedure [20]. As a

vast space develops in a retrorectus plane, there is a higher risk of occurrence of seroma. In our series, we encountered 2 cases (5.9%) with seroma which were treated conservatively on ambulatory basis. To prevent this complication, we routinely used a vacuum suction drain below the mesh for a period of 2–3 days with an abdominal binder.

During surgery, the ability to judge tension during closure of the peritoneum and PRS layer is imperative for surgeons. Overlooked defects or rupture of the posterior layer can possibly cause internal hernias and an increased risk of incarceration and strangulation of the bowel. e-TEP-RS repair ventral hernias surgery is associated with few essential complications related to the method, such as rupture or dehiscence of the posterior layer or damage to the linea alba while crossing, unintentional injury to the neurovascular bundle or disruption of the linea semilunaris while performing lateral dissection. Good understanding of an appropriate endoscopic anatomy and meticulous dissection in the retromuscular plane prevent these events [21]. The pressure of carbon dioxide insufflation can be decreased before closure of the ventral defect for convenience and to avoid excessive fascial tension. Up to 6–8 mmHg pressure is tolerable and provides sufficient space for endo-suturing in most cases [21]. The crucial advantage of e-TEP-RS, especially in large incisional hernia, is that if closure of the defect is not achievable, then release of the transversus abdominis as a form of a posterior component separation technique can be performed as the dissection space stays the same [22, 23]. Another potential solution could be the application of a barrier mesh or greater omentum that can be sutured into the defect, and these maneuvers were used in our group in four patients.

The learning curve for laparoscopic eTEP-RS repair seems long, requiring advanced technical skills from the surgeon. Therefore, the limitations of e-TEP-RS according to published evidence are prolonged surgery time, steep learning curve, requirement for superior laparoscopic skills, and troublesome crossover to the contralateral side in large defects with previous incision [19].

Usually, patients with incisional hernias are offered open repair due to the frequent need for adhesiolysis, increasing the risk of unintentional enterotomy [8]. With the gain of experience and adaptation to e-TEP-RS repair, more complicated cases with larger hernias and recurrent defects were qualified for surgery. This trend was also noticed by other surgeons [4, 24]. However, robotic eTEP-RS may have added advantages compared to laparoscopy, especially when suturing the midline in larger hernias and when performing transversus abdominis release.

The eTEP-RS is a demanding procedure that requires a comprehensive knowledge of the anatomy of the preperitoneal and retromuscular plane and where superior laparoscopic skills are crucial to successfully perform these maneuvers [25]. Furthermore, there are several approaches

and procedural aspects to consider when performing ventral hernia repair with eTEP-RS. Due to the inconvenience of this technique and its recent use, some articles proved a prolonged operative time for the eTEP-RS approach compared to other laparoendoscopic repair techniques [26]. However, once the learning curve is overcome, a reduction in operative times and unfavorable outcomes is noticed [27, 28].

Despite the difficulty of this procedure, eTEP-RS seems to be safe in terms of perioperative adverse events. The number of intraoperative complications and the conversion rate in the meta-analysis presented by Köckerling et al. [29] was 2.0% and 1.0%, respectively. These results appear to be comparable with laparoscopic IPUM and seem to improve those derived from sublay open ventral repair [28]. However, the surgeon must be cautious, since there is still a risk of visceral injury due to a possible thermal injury below the posterior layer, especially around the hernia defect and also during the crossover maneuver, particularly in patients who have had previous abdominal surgery [28, 30].

Our study has indisputable limitations, being an analysis of an early cohort of 34 patients. This is not a comparative study between different endoscopic or even open techniques for hernia repair. A thorough analysis of the outcome of the characteristics of the hernia in our group was not possible due to the small sample. An additional limitation of our study is the relatively short follow-up. However, the series presented describes our initial experience with this approach, where surgeons began their experience with this repair, biases in inclusion of patients, extensive irregularities in operative parameters: duration of procedure, length of stay, slight differences in surgical techniques, etc. must be acknowledged. Moreover, despite our results characterizing only a single institution experience, the involvement of highly specialized hernia surgeons may lack generalizability.

Conclusions

The eTEP-RS technique is a safe alternative to open ventral hernia repair in selected cases and allows for the placement of a large piece of mesh according to current recommendations, even in non-robotic centers. The eTEP-RS can be performed effectively by surgeons familiar with laparoscopic techniques for groin and ventral hernia repairs with satisfactory results and low rates of complication, including recurrence. Excellent knowledge of the detailed anatomy of the abdominal wall is essential for safe and effective hernia repair. Compliance with certain rules of the laparoscopic eTEP-RS operation facilitates improved ergonomics for this procedure even in non-robotic centers. As a new approach to hernia repair, e-TEP-RS requires further analyses to determine its benefits over the approaches most frequently used.

Declarations

Disclosures All authors K. Mitura, M. Romanczuk, K. Kisielewski, and B. Mitura have no relevant conflict of interest or financial ties to disclose.

Ethical approval All authors certify that they accept responsibility as an author and have contributed to the concept, data gathering, analysis, manuscript drafting, and give their final approval. This study was approved by the local ethics committee according to the specific requirements of the country.

Informed consent Informed consent was obtained from all participants and the data are available in institutional electronic repositories.

References

1. LeBlanc KA, Booth WV (1993) Laparoscopic repair of incisional abdominal hernias using expanded polytetrafluoroethylene: preliminary findings. *Surg Laparosc Endosc* 3:39–41
2. Orenstein SB, Dumeer JL, Monteagudo J, Poi MJ, Novitsky YW (2011) Outcomes of laparoscopic ventral hernia repair with routine defect closure using “shoelacing” technique. *Surg Endosc* 25:1452–1457. <https://doi.org/10.1007/s00464-010-1413-3>
3. Robinson TN, Clarke JH, Schoen J, Walsh MD (2005) Major mesh-related complications following hernia repair: events reported to the food and drug administration. *Surg Endosc Other Interv Tech* 19:1556–1560
4. Belyansky I, Daes J, Radu VG, Balasubramanian R, Reza Zahiri H, Weltz AS, Sibia US, Park A, Novitsky Y (2018) A novel approach using the enhanced-view totally extraperitoneal (eTEP) technique for laparoscopic retromuscular hernia repair. *Surg Endosc* 32:1525–1532. <https://doi.org/10.1007/s00464-017-5840-2>
5. Daes J (2012) The enhanced view-totally extraperitoneal technique for repair of inguinal hernia. *Surg Endosc* 26:1187–1189. <https://doi.org/10.1007/s00464-011-1993-6>
6. Belyansky I, Reza Zahiri H, Sanford Z, Weltz A, Park A (2018) Early operative outcomes of endoscopic (eTEP access) robotic-assisted retromuscular abdominal wall hernia repair. *Hernia* 22(5):837–847. <https://doi.org/10.1007/s10029-018-1795-z>
7. Quezada N, Grimaldi M, Besser N, Jacobovsky I, Achurra P, Crovari F (2022) Enhanced-view totally extraperitoneal (eTEP) approach for the treatment of abdominal wall hernias: mid-term results. *Surg Endosc* 36(1):632–639. <https://doi.org/10.1007/s00464-021-08330-3>
8. Taşdelen HA (2022) The extended-view totally extraperitoneal (eTEP) approach for incisional abdominal wall hernias: results from a single center. *Surg Endosc*. <https://doi.org/10.1007/s00464-021-08995-w>. Advanceonlinepublication.10.1007/s00464-021-08995-w
9. Jain M, Krishna A, Prakash O, Kumar S, Sagar R, Ramachandran R, Bansal VK (2022) Comparison of extended totally extra peritoneal (eTEP) vs intra peritoneal onlay mesh (IPOM) repair for management of primary and incisional hernia in terms of early outcomes and cost effectiveness—a randomized controlled trial. *Surg Endosc* (Advance online publication). <https://doi.org/10.1007/s00464-022-09180-3>
10. Muysoms FE, Miserez M, Berrevoet F, Campanelli G, Champault GG, Chelala E et al (2009) Classification of primary and incisional abdominal wall hernias. *Hernia* 13(4):407–414
11. Ramana B, Arora E, Belyansky I (2021) Signs and landmarks in eTEP Rives-Stopppa repair of ventral hernias. *Hernia* 25(2):545–550. <https://doi.org/10.1007/s10029-020-02216-4>

12. Poulouse BK, Shelton J, Phillips S, Moore D, Nealon W, Penson D, Beck W, Holzman MD (2012) Epidemiology and cost of ventral hernia repair: making the case for hernia research. *Hernia* 16:179–183. <https://doi.org/10.1007/s10029-011-0879-9>
13. Breuing K, Butler C, Ferzoco S, Franz M, Hultman C, Kilbridge J, Rosen M, Silverman V, Vargo R (2010) Incisional ventral hernias: review of the literature and recommendations regarding the grading and technique of repair *The Ventral Hernia. Surgery* 148(3):544–558
14. Skolimowska-Rzewuska M, Romanczuk M, Mitura B, Wyrzykowska D, Mitura K (2022) Laparoscopic transabdominal preperitoneal repair (umbilical TAPP) versus open ventral patch repair for medium size umbilical hernias in overweight and obese patients. *Videosurgery Other Miniinvasive Tech* 17(1):170–178. <https://doi.org/10.5114/wiitm.2021.110415>
15. Poelman M, Apers J, Brand H, Cense H, Consten E, Deelder J, Dwarsb GN, Lange E, Simmermacher R, Simons M, Sonneveld E, Schreurs H, Bonjer J (2013) The INCH-trial: a multicenter randomized controlled trial comparing the efficacy of conventional open surgery and laparoscopic surgery for incisional hernia repair. *BMC Surg* 13(8):13–18
16. Stoikes N, Quasebarth M, Brunt LM (2013) Hybrid ventral hernia repair: technique and results. *Hernia*. <https://doi.org/10.1007/s10029-013-1092-9>
17. Srivastava A, Sood A, Joy PS, Mandal S, Panwar R, Ravichandran S et al (2010) Principles of physics in surgery: the laws of mechanics and vectors physics for surgeons—part 2. *Indian J Surg* 72(5):355–361
18. Bittner R, Bingener-Casey J, Dietz U, Fabian M, Ferzli GS, Fortelny RH et al (2014) Guidelines for laparoscopic treatment of ventral and incisional abdominal wall hernias (International Endohernia Society [IEHS])—Part 2. *Surg Endosc* 28(2):353–379
19. Penchev D, Kotashev G, Mutafchiyski V (2019) Endoscopic enhanced-view totally extraperitoneal retromuscular approach for ventral hernia repair. *Surg Endosc* 33(11):3749–3756. <https://doi.org/10.1007/s00464-019-06669-2>
20. Mitura K (2020) New techniques in ventral hernia surgery - an evolution of minimally-invasive hernia repairs. *Pol Przegl Chir* 92(3):48–56. <https://doi.org/10.5604/01.3001.0013.7857>
21. Khetan M, Dey A, Bindal V, Suviraj J, Mittal T, Kalhan S, Malik VK, Ramana B (2021) e-TEP repair for midline primary and incisional hernia: technical considerations and initial experience. *Hernia* 25(6):1635–1646. <https://doi.org/10.1007/s10029-021-02397-6>
22. Kumar N, Palanisamy NV, Parthasarathi R, Sabnis SC, Nayak SK, Palanivelu C (2021) A comparative prospective study of short-term outcomes of extended view totally extraperitoneal (e-TEP) repair versus laparoscopic intraperitoneal on lay mesh (IPOM) plus repair for ventral hernia. *Surg Endosc* 35(9):5072–5077. <https://doi.org/10.1007/s00464-020-07990-x>
23. Novitsky YW, Elliott HL, Orenstein SB, Rosen MJ (2012) Transversus abdominis muscle release: a novel approach to posterior component separation during complex abdominal wall reconstruction. *Am J Surg* 204:709–716
24. Radu VG, Lica M (2019) The endoscopic retromuscular repair of ventral hernia: the eTEP technique and early results. *Hernia* 23:945–955. <https://doi.org/10.1007/s10029-019-01931-x>
25. Daes J, Belyansky I (2021) Anatomical considerations and tips for laparoscopic and robotic-assisted enhanced view totally extraperitoneal rives stoppa repair for midline hernia. *J Am Coll Surg* 233:e1–e11. <https://doi.org/10.1016/j.jamcollsurg.2021.05.007>
26. Kudsı OY, Chang K, Bou-Ayash N, Gokcal F (2020) A comparison of robotic mesh repair techniques for primary uncomplicated midline ventral hernias and analysis of risk factors associated with postoperative complications. *Hernia*. <https://doi.org/10.1007/s10029-020-02199-2>
27. Kudsı OY, Bou-Ayash N, Gokcal F et al (2020) Learning curve of robotic rives-stoppa ventral hernia repair: a cumulative sum analysis. *J Laparoendosc Adv S*. <https://doi.org/10.1089/lap.2020.0624>
28. Mitura K, Rzewuska A, Skolimowska-Rzewuska M, Romanczuk M, Kisielewski K, Wyrzykowska D (2020) Laparoscopic enhanced-view totally extraperitoneal Rives-Stoppa repair (eTEPRS) for ventral and incisional hernias: early operative outcomes and technical remarks on a novel retromuscular approach. *Videosurgery Other Miniinvasive Techniq* 15(4):533–545. <https://doi.org/10.5114/wiitm.2020.99371>
29. Köckerling F, Simon T, Adolf D et al (2019) Laparoscopic IPOM versus open sublay technique for elective incisional hernia repair: a registry-based, propensity score-matched comparison of 9907 patients. *Surg Endosc* 33:3361–3369. <https://doi.org/10.1007/s00464-018-06629-2>
30. Skolimowska-Rzewuska M, Mitura K (2021) Essential anatomical landmarks in placement of an adequate size mesh for a successful ventral hernia repair. *Pol Przegl Chir* 93(5):1–5. <https://doi.org/10.5604/01.3001.0014.9349>

Publisher's Note Springer Nature remains neutral with regard to jurisdictional claims in published maps and institutional affiliations.