

Subcutaneous Implant-based Breast Reconstruction with Acellular Dermal Matrix/Mesh: A Systematic Review

Ara A. Salibian, MD
Jordan D. Frey, MD
Mihye Choi, MD
Nolan S. Karp, MD

Background: The availability of acellular dermal matrix (ADM) and synthetic mesh products has prompted plastic surgeons to revisit subcutaneous implant-based breast reconstruction. The literature is limited, however, with regards to evidence on patient selection, techniques, and outcomes.

Methods: A systematic review of the Medline and Cochrane databases was performed for original studies reporting breast reconstruction with ADM or mesh, and subcutaneous implant placement. Studies were analyzed for level of evidence, inclusion/exclusion criteria for subcutaneous reconstruction, reconstruction characteristics, and outcomes.

Results: Six studies (186 reconstructions) were identified for review. The majority of studies (66.7%) were level IV evidence case series. Eighty percent of studies had contraindications for subcutaneous reconstruction, most commonly preoperative radiation, high body mass index, and active smoking. Forty percent of studies commenting on patient selection assessed mastectomy flap perfusion for subcutaneous reconstruction. Forty-five percent of reconstructions were direct-to-implant, 33.3% 2-stage, and 21.5% single-stage adjustable implant, with ADM utilized in 60.2% of reconstructions versus mesh. Pooled complication rates included: major infection 1.2%, seroma 2.9%, hematoma 2.3%, full nipple-areola complex necrosis 1.1%, partial nipple-areola complex necrosis 4.5%, major flap necrosis 1.8%, wound healing complication 2.3%, explantation 4.1%, and grade III/IV capsular contracture 1.2%.

Conclusions: Pooled short-term complication rates in subcutaneous alloplastic breast reconstruction with ADM or mesh are low in preliminary studies with selective patient populations, though techniques and outcomes are variable across studies. Larger comparative studies and better-defined selection criteria and outcomes reporting are needed to develop appropriate indications for performing subcutaneous implant-based reconstruction. (*Plast Reconstr Surg Glob Open* 2016;4:e1139; doi: 10.1097/GOX.0000000000001139; Published online 23 November 2016.)

Implant-based reconstruction remains the most common form of postmastectomy breast reconstruction in the United States.¹ Although several variations of this procedure exist, the most frequently reported techniques

involve implant placement either completely or partially behind the musculature of the anterior chest wall.²⁻¹¹

Submuscular implant placement provides an additional layer of tissue support between the prosthesis and mastectomy flaps, aids in prevention of implant “bottoming-out”, and has been associated with a lower incidence of capsular contracture (CC).¹² Disadvantages of this technique, however, may include increased postoperative pain secondary to muscle dissection,^{13,14} animation deformity,^{15,16} and a less natural esthetic result given implant positioning under the pectoralis muscle. The introduction of the dual-plane technique utilizing acellular dermal matrix (ADM),¹⁷ and more recently synthetic mesh products,^{18,19} has allowed surgeons to improve definition of the infra-

From the Hansjörg Wyss Department of Plastic Surgery, New York University School of Medicine, New York, N.Y.

Presented at the Northeastern Society of Plastic Surgeons Annual Meeting, October 14, 2016, Baltimore, Md.

Received for publication August 12, 2016; accepted September 30, 2016.

Copyright © 2016 The Authors. Published by Wolters Kluwer Health, Inc. on behalf of The American Society of Plastic Surgeons. All rights reserved. This is an open-access article distributed under the terms of the Creative Commons Attribution-Non Commercial-No Derivatives License 4.0 (CCBY-NC-ND), where it is permissible to download and share the work provided it is properly cited. The work cannot be changed in any way or used commercially without permission from the journal.

DOI: 10.1097/GOX.0000000000001139

Disclosure: The authors have no financial interest to declare in relation to the content of this article. The Article Processing Charge was paid for by the authors.

mammary fold and lower pole shape and projection.^{20–22} However, this technique does not address pectoralis detachment, deficiencies in superior pole contour, postoperative pain,²³ and animation deformity.¹⁶

Implant placement in the subcutaneous or prepectoral plane has recently been reported in single- and 2-stage breast reconstruction.^{24–26} Proponents advocate that this technique provides a more natural esthetic result while avoiding the negative sequelae of pectoralis disinsertion and submuscular implant positioning.^{27,28} Although the early experience with subcutaneous reconstruction was associated with higher rates of CC, implant exposure, and implant loss,^{12,29} advances in mastectomy techniques and the use of ADM and synthetic mesh have been suggested to decrease the risk of these complications.^{28,30}

This study utilizes a systematic review to analyze the available evidence on subcutaneous alloplastic breast reconstruction with ADM/mesh with regards to study quality, indications, techniques, and outcomes. As this procedure develops among plastic surgeons, a critical evaluation of the current literature will help determine the appropriate application and execution of this new technique.

METHODS

A comprehensive review of the literature was performed following the Preferred Reporting Items for Systematic Reviews and Meta-Analyses guidelines.^{31,32} The PubMed/MEDLINE and Cochrane databases were queried for articles up until June 2016 using combinations of the following keywords: “prepectoral,” “subcutaneous,” “breast reconstruction,” “acellular dermal matrix,” “acellular dermis,” “ADM,” “Alloderm” (LifeCell Corporation, Branchburg, N.J.), “Strattice” (LifeCell Corporation, Branchburg, N.J.) and “mesh.”

Headings were screened to include all original studies reporting on alloplastic subcutaneous breast reconstruc-

tion utilizing ADM or mesh after nipple-sparing mastectomy (NSM) or skin-sparing mastectomy (SSM). Selected abstracts were reviewed and included if studies presented data on indications for subcutaneous reconstructions or outcomes. Case reports, abstracts, non-English studies, and review articles were excluded. References from selected articles were additionally searched for other relevant articles.

Included studies were analyzed for study quality. Patient selection criteria for subcutaneous reconstructions were tabulated for each study when available. Data for procedural characteristics were extracted on mastectomy type, stage of reconstruction, type of implant, type of ADM or mesh, and technique. Complications analyzed included major infection (infection requiring return to operating room), minor infection (infection treated with oral or intravenous antibiotics), seroma, hematoma, nipple-areola complex (NAC) necrosis, wound healing complications, explantation, and Baker grade III/IV CC.³³ Compiled data for 1- versus 2-stage and ADM- versus mesh-assisted reconstructions was compared. Additionally, evaluation of esthetic outcomes was analyzed for each study.

Data were extracted only for articles that adequately reported results or variables in question. When appropriate, these data were combined to obtain pooled rates for particular outcomes. Ninety-five percent confidence intervals (CIs) were determined for these proportions accordingly.

RESULTS

Four hundred forty-three titles were initially identified for screening of which 6 articles were deemed appropriate after applying inclusion and exclusion criteria (Fig. 1). One study was removed due to duplicate data and 2 were added from references of relevant articles, yielding a total of 6 studies published from 2014 to 2016 (Table 1).^{25–28,30,34}

The majority of studies were level IV evidence case series (66.7%) with the exception of one retrospective co-

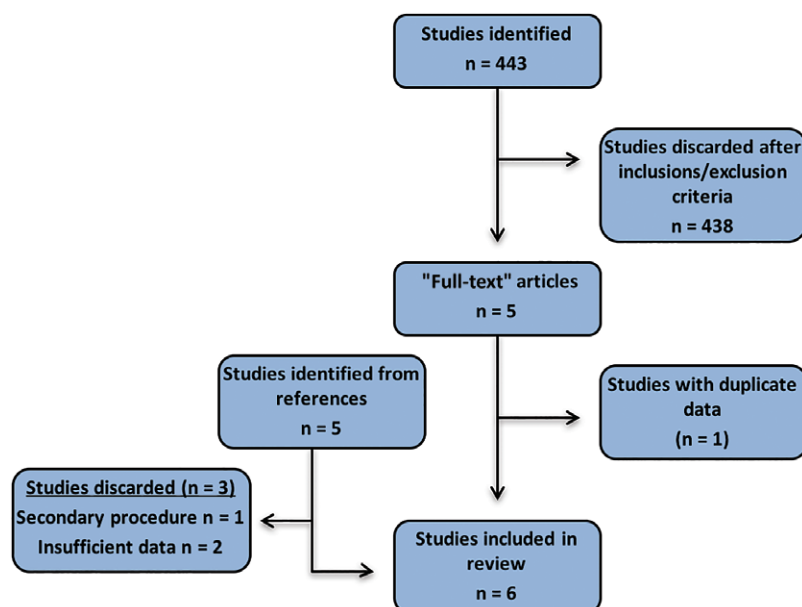


Fig. 1. Search strategy and article selection.

Table 1. Summary of Included Studies

Authors	Year	Study Design (LOE)	Patients/Breasts	ADM/Mesh	Mastectomy	Stage	Follow-up (mo)
Berna et al ²⁶	2014	CS (IV)	17/23	ADM	SSM, NSM	Single: DTI	14 (mean)
Reitsamer and Peintinger ²⁸	2015	CS (IV)	13/22	ADM	NSM	Single: DTI	6 (median)
Becker et al ³⁴	2015	CS (IV)	31/62	ADM, Mesh	SSM, NSM	Single: AI	24 (mean)
Bernini et al ²⁷	2015	NRCT (II)	34/39	Mesh	SSM, NSM	Single: DTI	25 (median)
Casella et al ²⁵	2015	CS (IV)	25/25	Mesh	SSM, NSM	Two-stage	24 (median)
Zhu et al ³⁰	2016	RCS (III)	-/15	ADM	SSM, NSM	Two-stage	17 (mean)

ADM, acellular dermal matrix; AI, adjustable implant; CS, case series; DTI, direct-to-implant; LOE, level of evidence; NRCT, nonrandomized controlled trial; NSM, nipple-sparing mastectomy; RCS, retrospective cohort study; SSM, skin-sparing mastectomy.

hort study³⁰ and one nonrandomized controlled trial.²⁷ Pooling data from all studies resulted in a total of 120 patients and 186 reconstructions. The longest mean and median follow-up times were 24 and 25 months, respectively, with a range of 1–55 months when cited.

Inclusion criteria for subcutaneous reconstruction were defined as methods of assessing mastectomy flap perfusion to determine suitability for subcutaneous reconstruction. Out of the studies that reported inclusion criteria, 60% did not cite the quality of mastectomy flaps as a consideration in determining the plane of implant placement.^{25,27,34} Of the 2 studies that utilized mastectomy flap perfusion as inclusion criteria, one study only performed clinical assessment²⁶ and the other utilized indocyanine green angiography and clinical assessment.³⁰ Exclusion criteria encompassed various patient demographics and characteristics that would preclude the decision to pursue subcutaneous reconstruction. Almost all articles (80.0%) reported exclusion criteria for subcutaneous reconstruction (Fig. 2).^{25–27,30} The majority of studies (60.0%) listed preoperative radiation,^{25–27} all active smoking,^{27,30} and patients with high body mass indices (BMIs) as contraindications to subcutaneous reconstruction.^{25–27} One study excluded patients with a BMI ≥ 30 ²⁶ and 2 studies excluded those with a BMI ≥ 25 or BMI < 18.5 .^{25,27}

The majority of reported reconstructions were single-stage, direct-to-implant (DTI) reconstructions (45.2%),

followed by single-stage, adjustable implant (33.3%) and two-stage (21.5%) reconstructions. ADM was more commonly used than mesh (60.2% versus 39.8% of cases, respectively), with a complete implant wrap as the most common technique compared with an anterior sling (63.7% versus 36.3%, respectively). Of note, the one study that performed anterior slings with vertical mastectomy incisions (62 reconstructions) also utilized dermal flaps.³⁴ Types of ADM included AlloDerm (13.4%), Strattice (19.6%), Flex HD (46.5%) (Musculoskeletal Transplant Foundation, Edison, NJ), and Braxon (20.5%) (Decomed, Marcon, Italy). Types of mesh included titanium (86.5%) and vicryl (13.5%). Five studies provided information on implants. Of these, 4 studies^{25–28} utilized anatomic silicone implants (109 cases) and 1 study used adjustable round saline implants (62 cases).³⁴

Data on complications were available for 5 studies (Table 2).^{25–28,34} Rates of major complications including major infection, full NAC necrosis, major flap necrosis, explantation and Baker grade III/IV CC were low in the majority of studies. One study reported a high rate of explantation (13.0%) secondary to chronic seromas with delayed wound healing (n = 2) and infection (n = 1).²⁶ Pooled complication rates and respective 95% CIs are listed in Table 3. The most common complication was partial NAC necrosis (4.5%), followed by explantation (4.1%), minor infection (2.3%), seroma (2.9%), hematoma (2.3%), and wound healing problems (2.3%).

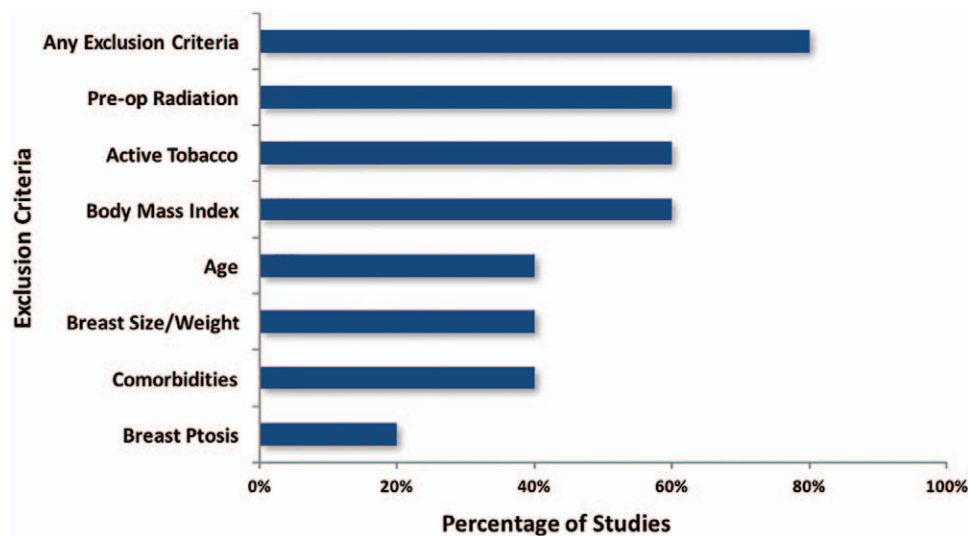


Fig. 2. Exclusion criteria for subcutaneous reconstruction with acellular dermal matrix/mesh.

Table 2. Complications by Study

Authors	Major Infection†	Minor Infection‡	Seroma	Hematoma	Full NAC Necrosis	Partial NAC Necrosis	Major Flap Necrosis	Wound Healing	Explantation	CC: Grade III/IV
Berna et al ²⁶	1 (4.3)	0 (0)	4 (17.4)	0 (0)	0 (0)	0 (0)	0 (0)	2 (8.7)	3 (13.0)	0 (0)
Reitsamer et al ²⁸	0 (0)	0 (0)	0 (0)	1 (4.5)	0 (0)	2 (9.1)	0 (0)	0 (0)	0 (0)	0 (0)
Becker et al ^{34*}	1 (1.6)	0 (0)	1 (1.6)	1 (1.6)	0 (0)	0 (0)	2 (3.2)	1 (1.6)	2 (3.2)	2 (3.2)
Bernini et al ²⁷	0 (0)	0 (0)	0 (0)	1 (2.6)	1 (2.8)§	1 (2.8)	1 (2.6)§	1 (2.6)	2 (5.1)	0 (0)
Casella et al ²⁵	0 (0)	4 (16)	0 (0)	1 (4)	0 (0)	1 (8.3)	0 (0)	0 (0)	0 (0)	0 (0)

*Study does not specify number of NSM versus SSM.
 †Major infection: infection requiring return to operating room.
 ‡Minor infection: infection requiring oral or intravenous antibiotics.
 §Same patient.
 CC, Capsular contracture.

Table 3. Pooled Complication Rates

Complication	n (%)‡	95% CI
Major infection*	2 (1.2)	0.0–3.5
Minor infection†	4 (2.3)	0.1–4.6
Seroma	5 (2.9)	0.4–5.4
Hematoma	4 (2.3)	0.1–4.6
Full NAC necrosis	1 (1.1)	0.0–3.3
Partial NAC necrosis	4 (4.5)	0.2–8.8
Major flap necrosis	3 (1.8)	0.0–3.8
Wound healing	4 (2.3)	0.1–4.6
Explantation	7 (4.1)	1.1–7.1
CC: grade III/IV	2 (1.2)	0.0–2.8

*Major infection: infection requiring return to operating room.
 †Minor infection: infection requiring oral or intravenous antibiotics.
 ‡n=171 with exception of NAC necrosis (n=88).
 CI, Confidence interval.

Subgroup analysis was also performed to compare complications in DTI cases versus 2-stage and ADM versus mesh reconstructions (Tables 4 and 5, respectively). Although statistical analysis was not possible given differing study designs, confounding variables, and lack of comparative data in each study for meta-analysis, the results showed relatively similar rates of most complications. Explantation (6.0%) was higher in the DTI group and minor infection (16.0%) was higher in the 2-stage group. Rates of minor infection were higher in mesh-assisted reconstructions (6.3%) and rates of seromas were higher in ADM-assisted reconstructions (8.9%).

One study provided an “objective” evaluation of esthetic outcomes in the form of a quantifiable rating scale.²⁷ “Subjective” reporting of esthetic outcomes was defined as assessment of one or more esthetic complications and was described in 4 studies (Table 6).^{26–28,34} Palpable implants were most commonly reported (8.5% of cases), followed by rippling (4.7%) and “visible” implants (4.3%). Revisionary procedures were reported in 3 studies and were necessary in 21.4% of patients.^{25,27,34} These procedures included fat grafting in 11.9% of cases and implant exchange in 14.3% of cases. All implant exchanges involved adjustable saline to silicone gel implant conversion in a single study.³⁴

DISCUSSION

Alloplastic breast reconstruction with subcutaneous implant placement was introduced 40 years ago.³⁵ Despite the evolution of the procedure over the next few decades, it lost favor to submuscular positioning given higher reported rates of major complications with subcutaneous

Table 4. Complications in Direct-to-implant versus 2-stage Reconstruction

Complication	DTI (n = 84)‡	Two-Stage (n = 25)‡
Major infection*	1 (1.2)	0 (0)
Minor infection†	0 (0)	4 (16)
Seroma	4 (4.8)	0 (0)
Hematoma	2 (2.4)	1 (4.0)
Full NAC necrosis	1 (1.3)	0 (0)
Partial NAC necrosis	3 (3.9)	1 (8.3)
Major flap necrosis	1 (1.2)	0 (0)
Wound healing	3 (3.6)	0 (0)
Explantation	5 (6.0)	0 (0)
CC: grade III/IV	0 (0)	0 (0)

*Major infection defined as infection requiring return to operating room.
 †Minor infection defined as infection requiring oral or intravenous antibiotics.
 ‡n=76 (NAC necrosis, DTI), n=12 (NAC necrosis, two-stage).

Table 5. Complications in ADM- Versus Mesh-assisted Reconstruction

Complication	ADM (n = 45)‡	Mesh (n = 64)‡
Major infection*	1 (2.2)	0 (0)
Minor infection†	0 (0)	4 (6.3)
Seroma	4 (8.9)	0 (0)
Hematoma	1 (2.2)	2 (3.1)
Full NAC necrosis	1 (2.5)	0 (0)
Partial NAC necrosis	2 (5.0)	2 (4.2)
Major flap necrosis	0 (0)	1 (1.6)
Wound healing	2 (4.4)	1 (1.6)
Explantation	3 (6.7)	2 (3.1)
CC: grade III/IV	0 (0)	0 (0)

*Major infection defined as infection requiring return to operating room.
 †Minor infection defined as infection requiring oral or intravenous antibiotics.
 ‡n=40 (NAC necrosis, ADM), n=48 (NAC necrosis, mesh).

Table 6. Esthetic Complications

Complication	Studies/Sample Size	n (%)	95% CI
Implant migration	4/146	0 (0)	—
Visible implant*	2/47	2 (4.3)	0.0–10.1
Palpable implant	2/47	4 (8.5)	0.0–16.5
Rippling	3/64	3 (4.7)	0.0–9.9

*Visible implant—implant edge causing visible overlying contour deformity.

techniques.^{12,29,36} Recently, plastic surgeons have revisited subcutaneous reconstruction, though there is a paucity of studies on this “new” technique.

We identified 6 studies reporting cases of subcutaneous breast reconstruction with ADM or mesh. Rates of

complications historically high for subcutaneous reconstructions were low across the majority of these studies. Baker grade III/IV CC was seen in 1.2% of cases. Several factors may have contributed to the low rates of CC including the utilization of anatomic gel implants³⁷ and the use ADM^{38–40} and mesh,^{7,41} which are associated with decreased incidences of CC. Capsules around textured subcutaneous prostheses may also be thinner than those found with sub-muscular placement at short-term follow-up.⁴² Individual risk factors for CC such as radiation therapy should additionally be considered,⁴³ which was reported in 1 out of the 2 cases of grade III/IV CC in this review.³⁴ Limited follow-up length (maximum reported mean and median follow-up of 24 and 25 months, respectively) may also result in low reported CC rates.

Placements of implants subcutaneously, without interposed muscle, also raises concern for skin flap ischemia, NAC loss in NSM, and implant exposure. Pooled rates of major flap necrosis (1.8%), full NAC necrosis (1.1%), and explantation (4.1%), however, were also low in the reviewed studies. This may be due to relatively thick mastectomy flaps (greater than 1 cm in thickness in 2 studies)^{26,30} compared with what is performed in many institutions. Utilization of ADM or mesh provides an additional layer of tissue support between implants and mastectomy flaps and can become vascularized with incorporation into the overlying subcutaneous tissue.^{27,44} ADM/mesh may also relieve pressure on mastectomy flaps when anchored to the chest wall, possibly contributing to the decreased ischemic complications seen in this review.

Cases of explantation in the reviewed studies were secondary to wound healing problems in 57.1% of cases (28.6% associated with seroma), infection in 28.6%, and large flap necrosis in 14.3%. Increased rates of infection, seroma, and flap necrosis have been associated with certain types of ADM,^{38,45} and must be considered with regards to technique and evaluation of outcomes. Therefore, complications secondary to poor wound healing in subcutaneous breast reconstruction may still put reconstructions at greater risk of failure compared with dual-plane techniques, depending on incision placement.

Interestingly, DTI reconstructions were more common than 2-stage and single-stage adjustable implant cases. Single-stage, DTI reconstruction has been associated with higher rates of flap necrosis, reoperation, and implant loss.⁴⁶ Theoretically, immediate implant placement in the subcutaneous plane may further increase the risk of these complications. Though statistical conclusions cannot be drawn between DTI and 2-stage cohorts in this review given the lack of comparative studies and presence of confounding factors, comparison of the 2 cohorts showed similar rates of these complications with the exception of explantation, which was higher in the DTI group, and minor infection, which was higher in the 2-stage group. Several important variables, however, must be further elucidated when assessing the increased risk with DTI reconstructions, including patient comorbidities, radiation therapy, quality of mastectomy flaps,⁴⁶ and implant size. These are particularly relevant when single-stage reconstruction is combined with subcutaneous techniques.

Subcutaneous reconstructions utilizing ADM versus mesh were also compared. Minor infections trended toward being higher in the mesh group, and seromas and explantation trended toward being higher in the ADM group. Several factors may have contributed to the observed results including the synthetic nature of mesh and the higher rate of seromas associated with certain types of ADM.² These analyses, however, were similarly limited by the lack of direct comparative data in individual studies.

Patient selection is a critical component of subcutaneous breast reconstruction and is important to consider when interpreting the outcomes of the reviewed studies. Only 40.0% of studies commenting on patient selection reported assessing the quality of mastectomy flaps when determining appropriateness of subcutaneous reconstruction.^{26,30} However, of the 3 studies that did not include mastectomy flap perfusion in their decision-making algorithm, Bernini et al. and Casella et al. reported extensive exclusion criteria for subcutaneous reconstructions including age, BMI, history of radiation, comorbidities, and smoking.^{25,27} Becker et al. instead avoided initial filling of adjustable saline expanders if there was concern for flap ischemia.³⁴

The perfusion of mastectomy flaps and the NAC in NSM are critical in subcutaneous reconstruction. Necrosis of either component can result in exposure of the implant and ADM/mesh and compromise of esthetic outcomes. Thick, well-vascularized mastectomy flaps are needed to provide adequate coverage of the implant and improve flap survival, especially with the lack of an additional layer of tissue support. Although thickness of flaps is inherently variable secondary to discrepancies in BMI and patient anatomy, the principle of anatomic dissection is of paramount importance. Performing the mastectomy in the plane between the breast parenchyma and overlying subcutaneous fat is crucial in preserving the subdermal plexus while removing all breast tissue, unlike the historical subcutaneous mastectomy which left an increased amount of residual breast tissue behind.^{47,48} In this review, 2 studies performed subcutaneous reconstruction only with mastectomy flaps greater than 1 cm in thickness, measured by a subjective pinch test in one study²⁶ and not described in the other.³⁰ Indocyanine green angiography was also used to confirm adequate mastectomy flap perfusion.³⁰ Though thickness of mastectomy flaps was not described in all of the reviewed studies, the low rates of NAC and flap necrosis, particularly in DTI reconstructions, suggest the presence of thick, well-perfused flaps in these reconstructions. Ensuring the viability of these structures, whether by assessing perfusion, restricting reconstructions to specific patient populations, or adjusting one's technique, will serve to further promote safe outcomes in the development of this procedure.

Analysis of techniques in the reviewed studies showed that the majority of studies completely covered implants with ADM/mesh in subcutaneous reconstructions. Implant coverage was achieved either by using preformed ADM templates²⁶ or with pieces of ADM as previously reported for treatment of CC.⁴⁹ This can require multiple sheets of ADM per implant, which can be costly, especially

in bilateral reconstructions. As the number of mastectomies and subsequent reconstructions continue to increase, and with the evolving nature of the reimbursement in healthcare, cost may become a significant limiting factor. Other options include utilizing ADM as an anterior sling, in which only the entire anterior aspect of the prosthesis is covered by ADM.³⁴ In addition, synthetic mesh products, including vicryl,^{7,34} silk,⁵⁰ and titanium^{24,41,51} derivatives, among others, may be a less expensive alternative, and have shown promising results. Mesh was less commonly utilized in the studies in this review, likely because of its more recent introduction in implant-based breast reconstruction.^{7,51} Recent studies, however, have shown comparable outcomes between certain ADM- and mesh-assisted reconstructions.¹⁹

Achievement of a more natural breast shape has been cited as an advantage of subcutaneous reconstructions.²⁷ Only one study, however, provided objective evaluations of esthetic outcomes.²⁷ Implant malposition, reported to be higher in subcutaneous reconstructions,¹² was not seen in any of the evaluated cases. Visible or palpable implants and implant rippling were more common, though no significant difference in these complications was observed between dual-plane and subcutaneous cohorts in the single nonrandomized controlled trial.²⁷ Although ADM has been used for treatment and prevention of these complications,⁵² ancillary procedures, such as fat grafting, may likely be necessary, and were reported as secondary procedures to treat visible implants or rippling in three of the reviewed studies.^{25,27,34} With subcutaneous reconstruction, these complications are particularly important to consider in patients with low BMI, and reinforce the importance of preserving thick mastectomy flaps, when possible, to adequately cover and disguise the contour of the implant. Further long-term analysis is needed to determine whether subcutaneous reconstructions will require a higher revision rate to address these complications, especially in nonideal patient populations.

The majority of studies reviewed were level IV evidence case series. The single nonrandomized controlled trial was limited by small sample size; however, it demonstrated superior esthetic outcomes in the subcutaneous cohort based on objective evaluations.²⁷ Complications between the 2 groups were overall comparable, though implant failure was higher in the subcutaneous group, but not statistically significant. This review also demonstrated significant variability in the reporting of data. Certain variables such as patient demographics, smoking history, chemotherapy and radiation history, incision type, implant size in DTI reconstructions, and differentiation of complications in NSM versus SSM are especially relevant when evaluating subcutaneous reconstruction.

In this study, we were unable to perform a meta-analysis of effect sizes as only one comparative study reporting outcomes was found. Moving forward, further higher-level evidence studies directly comparing new techniques to dual-plane/submuscular reconstructions will be critical to clarify the risks of potential complications. There was also significant heterogeneity among studies with regards to study design, reconstruction techniques including mas-

tectomy type, number of reconstructions, and ADM/mesh utilized. The thickness of mastectomy flaps additionally needs to be documented in future studies as this variable is directly related to skin and nipple necrosis. These factors may have significant effects on results, and more standardized comparisons will be needed to accurately assess outcomes. Additionally, overall follow-up length was fairly short, limiting the interpretation of certain complication rates such as CC. Short follow-up periods also restricted the analysis of recurrence data, which were not reported in any study, and are critical components of any discussion involving breast cancer and reconstruction. Finally, several studies only reported outcomes in highly selective patient cohorts, likely underestimating complication rates when these experiences are extrapolated to a general patient population.

CONCLUSIONS

Subcutaneous implant placement in alloplastic breast reconstruction has recently been revisited with the aid of ADM and synthetic mesh reinforcement. Our review of the current data on this new technique demonstrated overall low pooled complications rates, including rates of major mastectomy flap and NAC necrosis, and CC. Complications rates across studies, however, were not consistent, and there was also significant variability with regards to techniques and analysis of outcomes. Importantly, the majority of results reflect outcomes in ideal patient populations, given the relatively strict patient selection in most studies.

The current literature demonstrates that subcutaneous implant-based breast reconstruction with ADM/mesh is a promising technique that may not be associated with the high rates of complications historically attributed to subcutaneous reconstructions. In the future, plastic surgeons will need to more accurately compare outcomes with current submuscular/dual-plane procedures, determine the ideal techniques and materials to optimize results, and further assess the appropriate indications to safely offer this reconstructive option to patients.

Nolan S. Karp, MD

Hansjörg Wyss Department of Plastic Surgery
New York University School of Medicine
305 East 47th Street, Suite 1A
New York, NY 10017
E-mail: nolan.karp@nyumc.org

REFERENCES

1. American Society of Plastic Surgeons. *2014 Plastic Surgery Statistics Report*. Available at: <http://www.plasticsurgery.org/Documents/news-resources/statistics/2014-statistics/plastic-surgery-statistics-full-report.pdf>. Accessed April 25, 2016.
2. Weichman KE, Wilson SC, Saadeh PB, et al. Sterile “ready-to-use” AlloDerm decreases postoperative infectious complications in patients undergoing immediate implant-based breast reconstruction with acellular dermal matrix. *Plast Reconstr Surg*. 2013;132:725–736.
3. Salzberg CA, Ashikari AY, Berry C, et al. Acellular dermal matrix-assisted direct-to-implant breast reconstruction and capsular contracture: a 13-year experience. *Plast Reconstr Surg*. 2016;138:329–337.

4. Freeman MD, Vemula R, Rao R, et al. Refinements in the techniques of 2-stage breast reconstruction. *Ann Plast Surg*. 2016;76(Suppl 4):S304–S311.
5. Mendenhall SD, Anderson LA, Ying J, et al. The BREASTrial: stage I. Outcomes from the time of tissue expander and acellular dermal matrix placement to definitive reconstruction. *Plast Reconstr Surg*. 2015;135:29e–42e.
6. Martin JB, Moore R, Paydar KZ, et al. Use of fenestrations in acellular dermal allograft in two-stage tissue expander/implant breast reconstruction. *Plast Reconstr Surg*. 2014;134:901–904.
7. Haynes DF, Kreithen JC. Vicryl mesh in expander/implant breast reconstruction: long-term follow-up in 38 patients. *Plast Reconstr Surg*. 2014;134:892–899.
8. Wurzer P, Rappl T, Friedl H, et al. The Austrian breast implant register: recent trends in implant-based breast surgery. *Aesthetic Plast Surg*. 2014;38:1109–1115.
9. Seth AK, Hirsch EM, Fine NA, et al. Utility of acellular dermis-assisted breast reconstruction in the setting of radiation: a comparative analysis. *Plast Reconstr Surg*. 2012;130:750–758.
10. Liu AS, Kao HK, Reish RG, et al. Postoperative complications in prosthesis-based breast reconstruction using acellular dermal matrix. *Plast Reconstr Surg*. 2011;127:1755–1762.
11. Susarla SM, Ganske I, Helliwell L, et al. Comparison of clinical outcomes and patient satisfaction in immediate single-stage versus two-stage implant-based breast reconstruction. *Plast Reconstr Surg*. 2015;135:1e–8e.
12. Gruber RP, Kahn RA, Lash H, et al. Breast reconstruction following mastectomy: a comparison of submuscular and subcutaneous techniques. *Plast Reconstr Surg*. 1981;67:312–317.
13. Bindingavele V, Gaon M, Ota KS, et al. Use of acellular cadaveric dermis and tissue expansion in postmastectomy breast reconstruction. *J Plast Reconstr Aesthet Surg*. 2007;60:1214–1218.
14. Wallace MS, Wallace AM, Lee J, et al. Pain after breast surgery: a survey of 282 women. *Pain* 1996;66:195–205.
15. Spear SL, Schwartz J, Dayan JH, et al. Outcome assessment of breast distortion following submuscular breast augmentation. *Aesthetic Plast Surg*. 2009;33:44–48.
16. Hammond DC, Schmitt WP, O'Connor EA. Treatment of breast animation deformity in implant-based reconstruction with pocket change to the subcutaneous position. *Plast Reconstr Surg*. 2015;135:1540–1544.
17. Breuing KH, Warren SM. Immediate bilateral breast reconstruction with implants and inferolateral AlloDerm slings. *Ann Plast Surg*. 2005;55:232–239.
18. Dieterich M, Angres J, Stubert J, et al. Patient-reported outcomes in implant-based breast reconstruction alone or in combination with a titanium-coated polypropylene mesh - a detailed analysis of the BREAST-Q and overview of the literature. *Geburtshilfe Frauenheilkd*. 2015;75:692–701.
19. Gschwantler-Kaulich D, Schrenk P, Bjelic-Radisic V, et al. Mesh versus acellular dermal matrix in immediate implant-based breast reconstruction—a prospective randomized trial. *Eur J Surg Oncol*. 2016;42:665–671.
20. Topol BM, Dalton EF, Ponn T, et al. Immediate single-stage breast reconstruction using implants and human acellular dermal tissue matrix with adjustment of the lower pole of the breast to reduce unwanted lift. *Ann Plast Surg*. 2008;61:494–499.
21. Breuing KH, Colwell AS. Inferolateral AlloDerm hammock for implant coverage in breast reconstruction. *Ann Plast Surg*. 2007;59:250–255.
22. Spear SL, Parikh PM, Reisin E, et al. Acellular dermis-assisted breast reconstruction. *Aesthetic Plast Surg*. 2008;32:418–425.
23. McCarthy CM, Lee CN, Halvorson EG, et al. The use of acellular dermal matrices in two-stage expander/implant reconstruction: a multicenter, blinded, randomized controlled trial. *Plast Reconstr Surg*. 2012;130(5 Suppl 2):57S–66S.
24. Casella D, Bernini M, Bencini L, et al. TiLoop® Bra mesh used for immediate breast reconstruction: comparison of retropectoral and subcutaneous implant placement in a prospective single-institution series. *Eur J Plast Surg*. 2014;37:599–604.
25. Casella D, Calabrese C, Bianchi S, et al. Subcutaneous tissue expander placement with synthetic titanium-coated mesh in breast reconstruction: long-term results. *Plast Reconstr Surg Glob Open* 2015;3:e577.
26. Berna G, Cawthorn SJ, Papaccio G, et al. Evaluation of a novel breast reconstruction technique using the Braxon® acellular dermal matrix: a new muscle-sparing breast reconstruction. *ANZ J Surg*. 2014 September 29. doi: 10.1111/ans.12849.
27. Bernini M, Calabrese C, Cecconi L, et al. Subcutaneous direct-to-implant breast reconstruction: surgical, functional, and aesthetic results after long-term follow-up. *Plast Reconstr Surg Glob Open* 2015;3:e574.
28. Reitsamer R, Peintinger F. Prepectoral implant placement and complete coverage with porcine acellular dermal matrix: a new technique for direct-to-implant breast reconstruction after nipple-sparing mastectomy. *J Plast Reconstr Aesthet Surg*. 2015;68:162–167.
29. Artz JS, Dinner MI, Foglietti MA, et al. Breast reconstruction utilizing subcutaneous tissue expansion followed by polyurethane-covered silicone implants: a 6-year experience. *Plast Reconstr Surg*. 1991;88:635–639; discussion 640.
30. Zhu L, Mohan AT, Abdelsattar JM, et al. Comparison of subcutaneous versus submuscular expander placement in the first stage of immediate breast reconstruction. *J Plast Reconstr Aesthet Surg*. 2016;69:e77–e86.
31. Liberati A, Altman DG, Tetzlaff J, et al. The PRISMA statement for reporting systematic reviews and meta-analyses of studies that evaluate health care interventions: explanation and elaboration. *PLoS Med*. 2009;6:e1000100.
32. Moher D, Liberati A, Tetzlaff J, et al; PRISMA Group. Preferred reporting items for systematic reviews and meta-analyses: the PRISMA statement. *PLoS Med*. 2009;6:e1000097.
33. Little G, Baker JL Jr. Results of closed compression capsulotomy for treatment of contracted breast implant capsules. *Plast Reconstr Surg*. 1980;65:30–33.
34. Becker H, Lind JG 2nd, Hopkins EG. Immediate implant-based prepectoral breast reconstruction using a vertical incision. *Plast Reconstr Surg Glob Open* 2015;3:e412.
35. Snyderman RK, Guthrie RH. Reconstruction of the female breast following radical mastectomy. *Plast Reconstr Surg*. 1971;47:565–567.
36. Radovan C. Breast reconstruction after mastectomy using the temporary expander. *Plast Reconstr Surg*. 1982;69:195–208.
37. Stevens WG, Hirsch EM, Tenenbaum MJ, et al. A prospective study of 708 form-stable silicone gel breast implants. *Aesthet Surg J*. 2010;30:693–701.
38. Lee KT, Mun GH. Updated evidence of acellular dermal matrix use for implant-based breast reconstruction: a meta-analysis. *Ann Surg Oncol*. 2016;23:600–610.
39. Vardanian AJ, Clayton JL, Roostaiean J, et al. Comparison of implant-based immediate breast reconstruction with and without acellular dermal matrix. *Plast Reconstr Surg*. 2011;128:403e–410e.
40. Komorowska-Timek E, Oberg KC, Timek TA, et al. The effect of AlloDerm envelopes on periprosthetic capsule formation with and without radiation. *Plast Reconstr Surg*. 2009;123:807–816.
41. Dieterich M, Paepke S, Zwiefel K, et al. Implant-based breast reconstruction using a titanium-coated polypropylene mesh (TiLOOP Bra): a multicenter study of 231 cases. *Plast Reconstr Surg*. 2013;132:8e–19e.
42. Tomita K, Yano K, Nishibayashi A, et al. Effects of subcutaneous versus submuscular tissue expander placement on breast capsule formation. *Plast Reconstr Surg Glob Open* 2015;3:e432.
43. Reish RG, Lin A, Phillips NA, et al. Breast reconstruction outcomes after nipple-sparing mastectomy and radiation therapy. *Plast Reconstr Surg*. 2015;135:959–966.

44. Novitsky YW, Rosen MJ. The biology of biologics: basic science and clinical concepts. *Plast Reconstr Surg*. 2012;130(5 Suppl 2):9S–17S.
45. Weichman KE, Wilson SC, Weinstein AL, et al. The use of acellular dermal matrix in immediate two-stage tissue expander breast reconstruction. *Plast Reconstr Surg*. 2012;129:1049–1058.
46. Basta MN, Gerety PA, Serletti JM, et al. A systematic review and head-to-head meta-analysis of outcomes following direct-to-implant versus conventional two-stage implant reconstruction. *Plast Reconstr Surg*. 2015;136:1135–1144.
47. Woods JE. Subcutaneous mastectomy: current state of the art. *Ann Plast Surg*. 1983;11:541–550.
48. Goodnight JE Jr, Quagliana JM, Morton DL. Failure of subcutaneous mastectomy to prevent the development of breast cancer. *J Surg Oncol*. 1984;26:198–201.
49. Cheng A, Lakhiani C, Saint-Cyr M. Treatment of capsular contracture using complete implant coverage by acellular dermal matrix: a novel technique. *Plast Reconstr Surg*. 2013;132:519–529.
50. Fine NA, Lehfelddt M, Gross JE, et al. SERI surgical scaffold, prospective clinical trial of a silk-derived biological scaffold in two-stage breast reconstruction: 1-year data. *Plast Reconstr Surg*. 2015;135:339–351.
51. Dieterich M, Dieterich H, Timme S, et al. Using a titanium-coated polypropylene mesh (TiLOOP® Bra) for implant-based breast reconstruction: case report and histological analysis. *Arch Gynecol Obstet*. 2012;286:273–276.
52. Spear SL, Seruya M, Clemens MW, et al. Acellular dermal matrix for the treatment and prevention of implant-associated breast deformities. *Plast Reconstr Surg*. 2011;127:1047–1058.