



Case study

GOT SHINGLES? TEST FOR HIV. Severe shingles as first presenting infection in HIV/AIDS patient

Catherine Brahe^{a,*}, Rachel Ellis^b^a 3rd Battalion 6th Marines, 2D Marine Division, PSC Box 20100, Camp Lejeune, North Carolina 28542-20100, United States^b Naval Medical Center Portsmouth, 620 John Paul Jones Circle, Portsmouth, Virginia 23708, United States

ARTICLE INFO

Article history:

Received 13 January 2020

Received in revised form 8 February 2020

Accepted 18 February 2020

Keywords:

HIV
Herpes zoster
Cutaneous infection
Antiretroviral
Screening
Diagnosis

ABSTRACT

Late diagnosis of HIV is associated with increased morbidity and mortality. Infected individuals need to be identified early and started on antiretroviral therapy to increase their survival and to limit transmission to the community. Historically speaking, late diagnosis has been a common occurrence in the United States, despite the majority of those patients having had a medical encounter in the year prior to their diagnosis. These visits represent missed opportunities for HIV testing and therefore delays in initiation of appropriate antiretroviral therapy. Herpes zoster is a common infection that may indicate a weakened immune system, and as such should prompt consideration for HIV testing, even in patients who lack or deny classic risk factors such as “risky sexual behavior” or drug use. Here, we present a case of severe herpes zoster in a middle aged woman with no other HIV risk factors, who was tested and found to be HIV positive. Her CD4 count at diagnosis was <200 cells/mcL, consistent with AIDS.

Published by Elsevier Ltd. This is an open access article under the CC BY-NC-ND license (<http://creativecommons.org/licenses/by-nc-nd/4.0/>).

Introduction

Since the virus' recognition in the early 1980s, the advent of antiretroviral therapy has transformed HIV infection from a slow, progressive, terminal diagnosis into a chronic, but treatable disease. Early initiation of highly active antiretroviral therapy (HAART) benefits both the individual and community at large, via reduction of HIV-related morbidity and mortality and development of acquired immune deficiency syndrome (AIDS) for the patient, and reduced risk of viral transmission for the collective. However, a large proportion of patients are still being diagnosed with HIV infection late in the course of their disease. The violaceous plaques of Kaposi's sarcomas may be the most well-known cutaneous manifestations of HIV, but there are numerous other dermatoses which give insight as to the status of the immune system. Here, we present a severe case of herpes zoster in a middle aged, otherwise healthy appearing woman, which ultimately led to her late diagnosis of HIV.

Case report

A 53 year old woman presented to her primary care provider with a two week history of a painful, vesicular rash which extended from her low back to her left abdomen. The rash followed a dermatomal distribution and did not cross the midline. She reported experiencing sharp pain in the area for several days prior to development of small vesicles, which were grouped on an erythematous base (Fig. 1, A). The patient denied any significant medical history, and her only medications were aspirin and atorvastatin for mild hyperlipidemia. She was diagnosed with herpes zoster. She was started on valacyclovir (1 g, three times daily, for 7 days) and was given hydrocodone/acetaminophen for the pain.

Eleven days later, the patient presented to the emergency department. She had completed her week course of valacyclovir, however her shingles had yet to improve. The pain was persistent and severe, and while the majority of the area had crusted over, there were areas of significant ulceration into the dermis (Fig. 1, B). The area was swabbed for bacterial and viral cultures, both of which were negative. She was given 1 mg IM hydromorphone for pain, and topical clobetasol to apply twice daily to the area. She was instructed to follow up with dermatology the next morning.

Given the alarming, out of proportion presentation of zoster, the length of symptoms, and the failure to respond to valacyclovir, dermatology performed a punch biopsy and sent the patient for

* Corresponding author at: 140 Cavalier Drive, Jacksonville, North Carolina 28546, United States.

E-mail addresses: Catherine.a.brahe@mail.mil (C. Brahe), Rachel.m.ellis2@mail.mil (R. Ellis).

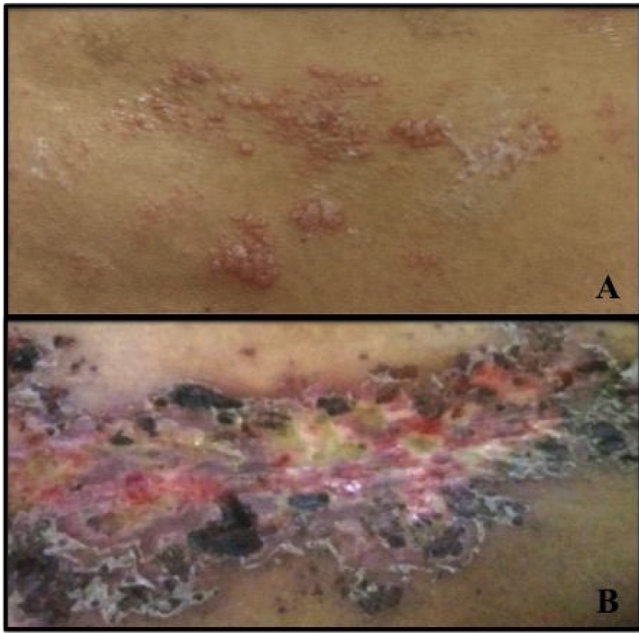


Fig. 1. *Herpes zoster infection of multiple dermatomes in a middle aged woman. A)* Early infection presented numerous groups of small vesicles on an erythematous base, with associated sharp pain. Infection located on the left lateral trunk. *B)* Shingles infection persists, with ulceration into the dermis and significant crusting and scab formation at four weeks, even after a one week course of valacyclovir.

further laboratory evaluation, to include HIV screening. Biopsy results showed mild epidermal spongiosis, vague superficial dermal scar, and both superficial and deep perivascular and periadnexal lymphoplasmacytic dermal inflammation. These changes are not entirely specific, but may be seen in the setting of connective tissue disease or an infectious process. Subsequently, she tested positive for HIV. Additional testing revealed CD4 count of 181 cells/mcL and viral load of 76800, consistent with AIDS.

The patient has since been referred to Infectious Disease and started on antiretroviral therapy and trimethoprim-sulfamethoxazole prophylaxis. Her shingles improved with a combination of valacyclovir, gabapentin, and topical lidocaine.

Discussion

Advances in antiretroviral therapy have transformed HIV infection from a terminal diagnosis to a chronic and treatable disease. This hinges on the timely identification of HIV positive individuals. Early identification leads to early initiation of appropriate therapy, which reduces the occurrence of opportunistic infections and minimizes risk of viral transmission to the patients' partners and contacts.

Late diagnosis of HIV is associated with increased morbidity and mortality [1]. Late testing and diagnosis of HIV is common in the United States. A Centers for Disease Control and Prevention (CDC) report revealed that from 1996 to 2005, 38 % of patients diagnosed across 34 states had an AIDS diagnosis within one year of testing positive for HIV [1,2]. At the time of that report, it was estimated that 21 % of HIV infections in the United States are undiagnosed [2]. By the end of 2016, that metric fell to 14 %, or 162,500 HIV infections yet to be diagnosed [3].

Historically, aside from within military populations, routine HIV screening has not been incorporated into general medical practice. Among US adults aged 18–64, only 54 % report ever being tested for

HIV. Often, testing is considered mainly for patients who endorse or exhibit high risk factors that may place them at a higher likelihood of exposure [1]. These factors include intravenous drug use, multiple sexual partners, and men who have sex with men (MSM). However, testing only based on these factors may lead to what is referred to as "framing bias," in which diagnostic tests are prescribed based on how physicians perceive their patients [1]. In many cases, patients may not feel comfortable disclosing their sexual practices or drug use. Others may be completely unaware of their exposure to HIV. Others still may not realize or understand the virus' mode of transmission, and their omission of key information may be completely unintentional. For these reasons, the CDC officially recommended op-out, routine HIV screening for all persons aged 13–64 years old in 2006 [4]. Six years later, the US Preventive Services Task Force followed suit, releasing similar recommendations [5].

Aside from routine screening for HIV, there are various cutaneous manifestations that should prompt physicians to consider HIV testing. These dermatoses include herpes zoster, genital warts, genital herpes, and seborrheic dermatitis. While these infections can also occur in HIV negative individuals, they may present as more widespread or severe in immunocompromised hosts. A prospective study based in India screened all patients presenting with any skin or mucocutaneous infections, and found that in the HIV negative patients, the signs and symptoms of the skin lesions were less severe, and much more limited in distribution [6]. In specific regards to herpes zoster, the researchers commented that in patients with HIV, zoster may present with "necrotizing ulcers in a multidermatomal pattern . . . last longer than the usual 2–3 weeks, and it can heal, leaving prominent scars," findings all consistent with our patient's case [6].

Numerous studies have identified herpes zoster as one of the most common cutaneous infections associated with HIV infection [7–10]. Zoster has a classic presentation and is easily diagnosed. Reactivation of the herpes zoster virus is known to occur in immunocompromised hosts, and as such, it can serve as a missed opportunity for HIV testing among infected individuals. Here, we presented a case of an otherwise healthy seeming middle aged woman, with no clear risk factors for HIV infection, who presented with a severe, ulcerating, multidermatomal, long lasting herpes zoster infection and was found to be HIV positive with a low CD4 + T cell count <200 cells/mcL, as a means to highlight the importance of HIV screening, despite historic conceptions of who is or is not at risk.

Written informed consent was obtained from the patient for publication of this case report and accompanying images. A copy of the written consent is available for review by the Editor-in-Chief of this journal on request.

Author statement

The authors have no conflicts of interest to declare. There are no sources of funding for this manuscript.

CRedit authorship contribution statement

Catherine Brahe: Investigation, Writing - original draft. **Rachel Ellis:** Conceptualization, Writing - review & editing.

Declaration of Competing Interest

None.

References

- [1] Kirchner Jeffrey T. HIV: 3 Cases that hid in plain sight. *J Fam Pract* 2015;64(1):20–6.
- [2] Centers for Disease Control and Prevention (CDC). Late HIV testing – 34 states, 1996–2005. *MMWR Morb Mortal Wkly Rep* 2009;58:661–5.
- [3] Centers for Disease Control and Prevention (CDC). HIV surveillance report 2017;29:.. Published November 2018. Accessed [6 October 2019] <http://www.cdc.gov/hiv/library/reports/hiv-surveillance.html>.
- [4] Branson BM, Handsfield HH, Lampe MA, et al. Centers for Disease Control and Prevention (CDC). Revised recommendations for HIV testing of adults, adolescents, and pregnant women in health-care settings. *Morb Mortal Weekly Rep* 2006;55:1–17.
- [5] Moyer Virginia A. Screening for HIV: U.S. preventive services task force recommendation statement. *Ann Intern Med* 2013;159(1):51, doi:<http://dx.doi.org/10.7326/0003-4819-159-1-201307020-00645>.
- [6] Shashi C. Skin and mucocutaneous manifestations: useful clinical predictors of HIV/AIDS. *J Clin Diagn Res* 2012;6(10):1695–8, doi:<http://dx.doi.org/10.7860/jcdr/2012/4615.2633>.
- [7] Maxime I, Serge N, Albert M, Michel YJ, Lambert D, Abo Y, et al. Missed opportunities for HIV testing among newly diagnosed HIV-infected adults in Abidjan, Cote d'Ivoire. *PLoS One* 2017;12(10), doi:<http://dx.doi.org/10.1371/journal.pone.0185117>.
- [8] Nasrin M, Mohammadali D, Farideh J. Dermatological manifestations of HIV/AIDS individuals in Shiraz, south of Iran. *J Glob Infect Dis* 2018;10(2):80–3, doi:<http://dx.doi.org/10.4103/0974-777x.233000>.
- [9] Jeong KY, Hee WJ, Ja KM, Won PD, Joon-Young S, Woo KS, et al. Opportunistic diseases among HIV-infected patients: a multicenter-nationwide Korean HIV/AIDS cohort study, 2006–2013. *Korean J Intern Med* 2016;31(5):953–60, doi:<http://dx.doi.org/10.3904/kjim.2014.322>.
- [10] Tominski D, Katchanov J, Driesch D, Mb D, Kiedtke A, Schneider A, et al. The late-presenting HIV-infected patient 30 years after the introduction of HIV testing: spectrum of opportunistic disease and missed opportunities for early diagnosis. *HIV Med* 2016;18(2):125–32, doi:<http://dx.doi.org/10.1111/hiv.12403>.