



Diagnosis and treatment of adult Langerhans cell histiocytosis in the rib: a case report and literature review

Xin Li^{1#^}, Xufeng Liu^{2#}, Daqiang Sun¹

¹Department of Thoracic Surgery, Tianjin Chest Hospital (Affiliated Hospital of Tianjin University), Tianjin, China; ²Department of Thoracic Surgery, Tianjin Haibin People's Hospital, Tianjin, China

#These authors contributed equally to this work.

Correspondence to: Daqiang Sun, MD. Department of Thoracic Surgery, Tianjin Chest Hospital (Affiliated Hospital of Tianjin University), No. 261 Taierzhuang South Road, Jinnan District, Tianjin, China. Email: sdqmd@163.com.

Background: Langerhans cell histiocytosis (LCH) is a rare proliferative disease caused by the proliferation of Langerhan's cells and aggregation in multiple organs. Rib involvement is extremely rare and easily misdiagnosed. The biologic behavior of LCH is largely unknown, and it is of utmost importance to differentiate it from tuberculosis and tumors. Herein, we present a male adult diagnosed with Langerhans cell histiocytosis of the rib which was successfully treated with surgery.

Case Description: This study retrospectively reports a rare case of rib-only LCH in a 34-year-old male patient who complained of persistent stabbing pain in the left chest and back for 45 days. The pain increased after bending, and was accompanied by chest tightness, shortness of breath, and night sweats. The patient denied any family history of LCH. CT showed an isolated mass on the left chest wall invading the seventh posterior rib. The diagnosis was confirmed by immunohistochemical staining and pathological analysis. The immunohistochemistry showed VIM (+), Ki-67 (+30%), CD1a (+), CD 68 (+) and S-100 (+). After surgical resection, the patient was followed up for more than 5 years without recurrence or complication. In addition, we reviewed and summarized 11 reported LCH cases with rib involvement, in which patients were either asymptomatic, or reported chest or back pain. Surgical resection was the main therapy in each case, and after 4–63 months of follow up, all patients were disease-free.

Conclusions: This case presents a rare instance of adult LCH in the rib. Pathological typical Langerhans cells and positive protein S100, CD1a, and CD207 are the key evidences for LCH, and surgical resection is currently an effective therapy with satisfactory outcomes.

Keywords: Langerhans cell histiocytosis (LCH); rib; adult; case report

Submitted Jul 05, 2022. Accepted for publication Aug 05, 2022.

doi: 10.21037/atm-22-3601

View this article at: <https://dx.doi.org/10.21037/atm-22-3601>

Introduction

Langerhans cell histiocytosis (LCH) is a rare disease characterized by the proliferation of dendritic cells specific to the monocyte-phagocyte system. It is mainly characterized by the infiltration of Langerhans cells (1), which commonly cause skeletal damage and rash, although localized or extensive organ damage can also occur. LCH

in the skeletal system is most commonly seen in the mandible (30%) and least commonly in the rib (6%) (2). The incidence of adult LCH is conservatively estimated at 1–2 per million (3,4), and the incidence ratio of male to female is 1.2:1 to 2:1 (5). The pathogenesis of LCH is still unclear, and there is no satisfactory diagnostic indicator (6). At present, the diagnosis is mainly based on comprehensive clinical manifestations, pathological examinations, and

[^] ORCID: 0000-0002-3142-4223.

auxiliary examinations, and most clinicians are prone to misdiagnosis or missed diagnosis due to the lack of understanding of the disease (7). Most patients receive clinical treatment to alleviate their symptoms, thus there is no standard treatment. For the purpose of providing some suggestions for clinical diagnosis and treatment of LCH, we report the case of adult LCH with rib involvement in a 34-year-old man and review the 11 cases reported in the literatures. We present the following article in accordance with the CARE reporting checklist (available at <https://atm.amegroups.com/article/view/10.21037/atm-22-3601/rc>).

Case presentation

A 34-year-old male was referred to Tianjin Chest Hospital on May 31, 2016 due to persistent stabbing pain in the left chest and back for 45 days. The pain increased after bending, and was accompanied by chest tightness, shortness of breath, and night sweats, with no chills, fever, or fatigue, and no obvious inducements. The patient reported a history of otherwise good health, with no chronic or infectious disease or significant family history. Chest enhanced CT

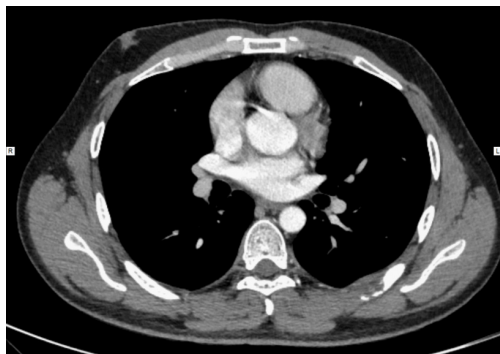

Figure 1 Enhanced CT scan of the patient's chest.

showed an isolated mass on the left chest wall invading the seventh posterior rib, and tuberculosis was initially considered (*Figure 1*). Tuberculin skin test and sputum smear examination were conducted and the results were negative. A puncture biopsy was further performed, and the pathology was considered to indicate a malignant small round cell tumor, although a hematopoietic tumor could not be excluded. The immunohistochemical results were keratin (-), VIM (+), Ki-67 (+70%), Cal (-), LCA (-), CD117 (-), CD99 (-), CD79a (-), actin (-), desmin (-), SMA (-), and specially stained PAS (-). Immunofixation electrophoresis for urine detection showed no IgG, IgA, IgM, light chain κ , or light chain λ monoclonal components, and there was no obvious abnormality in the bone penetration examination. Nevertheless, due to the increasing severity of the patient's symptoms, surgical resection was performed to obtain a definitive diagnosis.

The patient underwent thoracotomy and the left 6th, 7th, and 8th posterior ribs were resected. The mass was 5 cm × 4 cm × 2 cm in size and completely removed (*Figure 2*). The postoperative pathological outcome was LCH (*Figure 3*), which involved the ribs and intercostal muscles, and immunohistochemistry showed keratin (-), desmin (-), P53 (-), VIM (+), Ki-67 (+30%), CD34 (-), CD45R0 (-), CD79a (-), CD1a (+), CD 138 (-), CD 68 (+), actin (-), and S-100 (+). No complications were observed, and the patient was discharged 1 week after surgery, with no further treatment and no evidence of recurrence or metastasis after 6 years of follow-up.

All procedures performed in this study were in accordance with the ethical standards of the institutional and/or national research committee(s) and with the Declaration of Helsinki (as revised in 2013). Written informed consent was obtained from the patient for publication of this case report and accompanying images. A copy of the written consent is available for review by the editorial office of this journal.

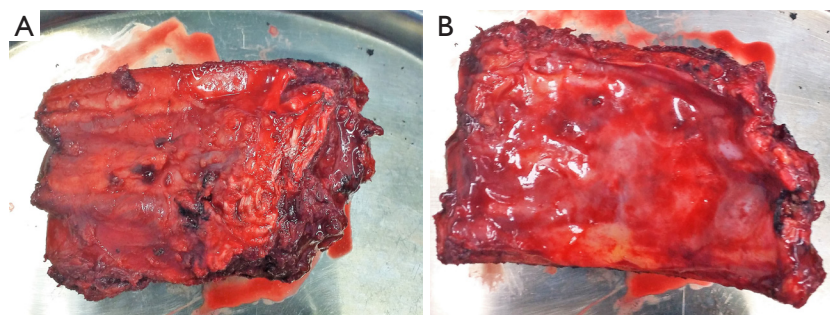


Figure 2 Surgically resected left posterior chest wall mass.

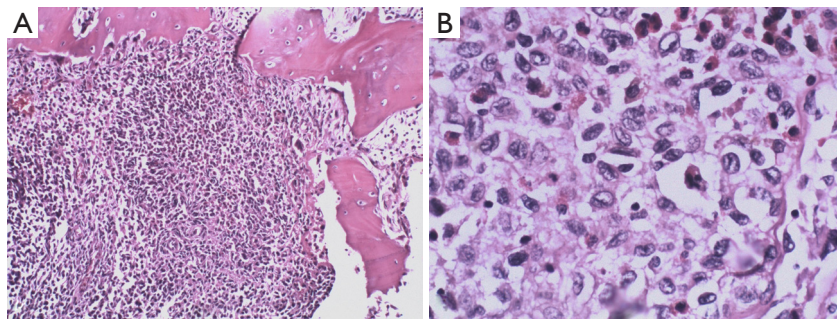


Figure 3 Hematoxylin-eosin staining for pathological section of left posterior chest wall mass (A, $\times 100$; B, $\times 400$).

Table 1 Summary of case reports of LCH in the rib

Author	Sex	Age, years	Site	Symptom	Treatment	Outcome	Follow-up period, months
Hashimoto (8)	Female	24	Left 7th rib	Pain and swelling	None	Disease-free	13
Hashimoto (8)	Male	60	Right 4th rib	None	Chemotherapy	Disease-free	63
Hashimoto (8)	Female	30	Right 4th rib	Pain	None	Alive with disease	4
Yolcu (9)	Female	32	Right 10th rib	Right-side chest pain	Rib resection	Disease-free	5
Zuo (10)	Female	52	Left 5th rib	Left chest pain	Rib resection	Disease-free	24
Kim (2)	Male	35	Left 6th rib	Upper back pain	Partial rib resection	Disease-free	24
Wu (11)	Male	24	Left 6th rib	Intermediate dry cough for 1 month	Vats	Disease-free	23
Ozkan (12)	Male	39	Left 5th rib	Chest pain	Partial resection of the left fifth to the sixth rib	Unknown	None
Ai (13)	Male	47	Right 5th rib	Chest pain for 20 days	Rib resection	Chest pain relieved	None
Shimoyama (14)	Male	57	Right 8th rib	None	Rib resection	Unknown	None
Wang (15)	Female	47	Right 7th rib	Chest pain	Rib resection	Disease-free	7

LCH, Langerhans cell histiocytosis.

Literature review

Current data for the treatment of solitary rib LCH is limited. A total of 11 cases have been reported to date (8-15) (Table 1), with five females, six males, and an age range of 24 to 60 years old. Eight cases presented with chest or back pain, while two were asymptomatic and were diagnosed incidentally during routine chest X-ray or CT scans for unrelated reasons. One patient reported an intermediate dry cough. Eight patients underwent rib resection, one received chemotherapy and two underwent observation only. Follow-up information was obtained in eight patient's and all were disease-free. The results suggested that rib resection was an effective therapy with a good prognosis.

Discussion

Bone LCH has a low incidence, with no specific clinical manifestations. In the case at hand, LCH was differentiated from chest wall tuberculosis and plasma cell myeloma. Chest wall tuberculosis has typically suspicious symptoms such as long-term low-grade fever, hyperhidrosis, exaggerated thoracic kyphosis, and local tenderness. Chest wall tuberculosis patients also often have a history of tuberculosis exposure, which can be help differentiate from LCH along with the OT test and biopsy. Plasma cell myeloma, also called multiple myeloma, is mainly characterized by osteoporosis, fracture, pain, and renal dysfunction (16). Monoclonal immunoglobulins (M component) often

occur in the serum, or as monoclonal immunoglobulin light chain in urine >10 g/24 h, and a few cases appear to contain biclonal or triclinal immunoglobulins. In this case, as immunofixation electrophoresis for urine detection showed no IgG, IgA, IgM, or light chain κ and light chain λ monoclonal components, the patient was not diagnosed as plasma cell myeloma before surgery.

LCH is a rare disease caused by cytopathic hyperplasia and aggregation of Langerhans cells in various organs. Due to the wide range of LCH lesions and clinical manifestations, there has been a diversity of approaches to its diagnosis and treatment (17). Chest or back pain is the most common symptom of LCH, and even some patients didn't describe any pain or discomfort, perhaps because the mass was small and didn't invade in adjacent tissues or intercostal nerve. As MRI and PET-CT offer a detection rate of only 50–60% (18), once LCH is considered as a possibility, pathological results are indispensable in confirming its diagnosis. Langerhans cell morphology is characterized by different sizes, gray-blue or gray-purple color, a kidney-shaped or oval nucleus, with different nuclei and folds, dendritic processes, inconspicuous nucleoli, and abundant cytoplasm, commonly with fine particles and vacuoles (19). The Langerhans Cell Histiocytosis Evaluation and Treatment Guidelines issued in 2009 (20) point out that typical LCH cells are seen under light microscopy with positive for protein S100, CD1a, and CD207 (Langerin) in immunohistochemical staining (21). In this case, postoperative immunohistochemistry results showed S-100 and CD1a were positive, which could confirm the diagnosis of LCH.

As the treatment of LCH is still controversial and the effect is still under investigation, comprehensive and systematic assessment should be made before treatment (22). LCH in the rib can be treated by surgery, radiotherapy, and typical application of glucocorticoids, and the 5-year local control rate can reach over 95% (23). However, given the rarity of the condition and the relatively good prognosis, treatment has not been standardized (24). Different approaches such as observation only, surgical resection, and chemotherapy have been implemented in our review, and the results show VATS can achieve the same outcome as traditional open thoracic surgery with less pain. While all patients obtained a good prognosis without deaths or recurrence, the long-term efficacy and prognosis require further follow-up observation (25).

In summary, LCH of the rib is a rare disease with complex and non-specific clinical manifestations, which is

easy to miss or misdiagnose. Pathological typical Langerhans cells and positive protein S100, CD1a, and CD207 are the key evidence for its presence, and surgical resection of the lesion is an effective therapy with a good prognosis.

Acknowledgments

The authors would like to acknowledge the patient and his family for providing their information and giving consent to its publication.

Funding: The study was supported by grants from the National Natural Science Foundation of Tianjin (No. 21JCYBJC00260) and Tianjin Key Medical Discipline (Thoracic Surgery) Construction Project (No. TJYXZDXK-018A).

Footnote

Reporting Checklist: The authors have completed the CARE reporting checklist. Available at <https://atm.amegroups.com/article/view/10.21037/atm-22-3601/rc>

Conflicts of Interest: All authors have completed the ICMJE uniform disclosure form (available at <https://atm.amegroups.com/article/view/10.21037/atm-22-3601/coif>). The authors have no conflicts of interest to declare.

Ethical Statement: The authors are accountable for all aspects of the work in ensuring that questions related to the accuracy or integrity of any part of the work are appropriately investigated and resolved. All procedures performed in this study were in accordance with the ethical standards of the institutional and/or national research committee(s) and with the Declaration of Helsinki (as revised in 2013). Written informed consent was obtained from the patient for publication of this case report and accompanying images. A copy of the written consent is available for review by the editorial office of this journal.

Open Access Statement: This is an Open Access article distributed in accordance with the Creative Commons Attribution-NonCommercial-NoDerivs 4.0 International License (CC BY-NC-ND 4.0), which permits the non-commercial replication and distribution of the article with the strict proviso that no changes or edits are made and the original work is properly cited (including links to both the formal publication through the relevant DOI and the license). See: <https://creativecommons.org/licenses/by-nc-nd/4.0/>.

References

- Bakry OA, Samaka RM, Kandil MA, et al. Indeterminate cell histiocytosis with naïve cells. *Rare Tumors* 2013;5:e13.
- Kim SH, Choi MY. Langerhans Cell Histiocytosis of the Rib in an Adult: A Case Report. *Case Rep Oncol* 2016;9:83-8.
- Zhang XR, Tang WW, Gao XC, Bian CP. Imaging diagnosis of osseous langerhans cell histiocytosis in children. *Chinese Computed Medical Imaging* 2009;15:473-80.
- Ng-Cheng-Hin B, O'Hanlon-Brown C, Alifrangis C, et al. Langerhans cell histiocytosis: old disease new treatment. *QJM* 2011;104:89-96.
- Horibe K, Saito AM, Takimoto T, et al. Incidence and survival rates of hematological malignancies in Japanese children and adolescents (2006-2010): based on registry data from the Japanese Society of Pediatric Hematology. *Int J Hematol* 2013;98:74-88.
- Ong HY, Goh LC, Santhi K, et al. Concurrent Mastoid Cellulitis and Langerhans Cells Histiocytosis: A Challenging Diagnosis. *Oman Med J* 2018;33:167-70.
- Zhou Y, Liu QL. Progress on langerhans cell histiocytosis: pathogenesis, diagnosis and treatment. *Chinese Journal of Disaster Medicine* 2017;5:106-10.
- Hashimoto K, Nishimura S, Sakata N, et al. Treatment Outcomes of Langerhans Cell Histiocytosis: A Retrospective Study. *Medicina (Kaunas)* 2021;57:356.
- Yolcu A, Tulay CM, Temiz P, et al. Langerhans cell histiocytosis: A rare cause of pathological rib fracture. *Turk Gogus Kalp Damar Cerrahi Derg* 2021;29:126-8.
- Zuo T, Jiang P, Yu J, et al. Langerhans cell histiocytosis of the rib presenting with pathological fracture: a case report. *J Cardiothorac Surg* 2020;15:332.
- Wu Y, Guan J, Zhang K, et al. Rare chondroblastoma of the 6th left rib, video-assisted thoracoscopy resected: one case report and literature review. *J Cardiothorac Surg* 2021;16:192.
- Ozkan D, Demiroz ŞM, Sayan M, et al. Metachronous Eosinophilic Granuloma of Rib in an Adult Patient. *Cureus* 2021;13:e20670.
- Ai L, Li J, Wang W, et al. Chest pain caused by isolated rib Langerhans cell histiocytosis in an adult. *Asian J Surg* 2022;45:1601-2.
- Shimoyama T, Kimura B, Nakamura K, et al. Langerhans cell histiocytosis of the rib in adult male. *Kyobu Geka* 2011;64:135-8.
- Wang Q, Yang S, Tang W, et al. Solitary Adult Rib Langerhans Cell Histiocytosis Evaluated by 18F-FDG PET/CT. *Clin Nucl Med* 2021;46:756-8.
- Zhang J, Li P, Song JF, An QJ. Signal pathways, biomechanics and treatment progress of multiple myeloma bone disease. *World Latest Medicine Information* 2018;18:79-81.
- Gkrouzman E, Cuadra RH, Jacob J. Langerhans Cell Histiocytosis of the Bone Presenting as Back Pain: An Unusual Diagnosis for a Common Complaint. *Conn Med* 2015;79:409-14.
- Kim JR, Yoon HM, Jung AY, et al. Comparison of whole-body MRI, bone scan, and radiographic skeletal survey for lesion detection and risk stratification of Langerhans Cell Histiocytosis. *Sci Rep* 2019;9:317.
- Fletcher CD, Lazar AJ. WHO classification of tumors of soft tissue and bone. In *Soft Tissue and Bone Tumours*, 5th ed. Lyon, France: IARC Publications, 2020; 492-4.
- Wu SH. Introduction of guidelines on evaluation and treatment of Langerhans cell histiocytosis. *Zhonghua Er Ke Za Zhi* 2012;50:155-8.
- Nakamine H, Yamakawa M, Yoshino T, et al. Langerhans Cell Histiocytosis and Langerhans Cell Sarcoma: Current Understanding and Differential Diagnosis. *J Clin Exp Hematop* 2016;56:109-18.
- Minkov M. Multisystem Langerhans cell histiocytosis in children: current treatment and future directions. *Paediatr Drugs* 2011;13:75-86.
- Ioannidis O, Sekouli A, Paraskevas G, et al. Long term follow up of eosinophilic granuloma of the rib. *Klin Onkol* 2011;24:460-4.
- Song MG, Nam DC, Lee JS, et al. Langerhans cell histiocytosis in the adult clavicle: A case report. *Int J Surg Case Rep* 2020;75:286-91.
- Suzuki T, Izutsu K, Kako S, et al. A case of adult Langerhans cell histiocytosis showing successfully regenerated osseous tissue of the skull after chemotherapy. *Int J Hematol* 2008;87:284-8.

(English Language Editor: B. Draper)

Cite this article as: Li X, Liu X, Sun D. Diagnosis and treatment of adult Langerhans cell histiocytosis in the rib: a case report and literature review. *Ann Transl Med* 2022;10(18):1025. doi: 10.21037/atm-22-3601