

Received: 2015.04.27  
Accepted: 2015.05.28  
Published: 2015.08.28

ISSN 1941-5923  
© Am J Case Rep, 2015; 16: 577-580  
DOI: 10.12659/AJCR.894468

## Hyponatremia due to Secondary Adrenal Insufficiency Successfully Treated by Dexamethasone with Sodium Chloride

Authors' Contribution:  
Study Design A  
Data Collection B  
Statistical Analysis C  
Data Interpretation D  
Manuscript Preparation E  
Literature Search F  
Funds Collection G

ABCDEFG 1 **Itsuro Kazama**  
B 2 **Tsutomu Tamada**  
B 3 **Toshiyuki Nakajima**

1 Department of Physiology I, Tohoku University Graduate School of Medicine, Sendai, Miyagi, Japan  
2 Department of Respiratory Medicine, Tohoku University Graduate School of Medicine, Sendai, Miyagi, Japan  
3 Department of Internal Medicine, Iwakiri Hospital, Sendai, Miyagi, Japan

**Corresponding Author:** Itsuro Kazama, e-mail: [kazaitsu@med.tohoku.ac.jp](mailto:kazaitsu@med.tohoku.ac.jp)  
**Conflict of interest:** None declared

**Patient:** Female, 60  
**Final Diagnosis:** Hyponatremia due to secondary adrenal insufficiency  
**Symptoms:** prolonged general fatigue and anorexia  
**Medication:** —  
**Clinical Procedure:** Successfully treated by dexamethasone with sodium chloride  
**Specialty:** Nephrology





**Objective:** Rare co-existence of disease or pathology  
**Background:** Patients who were surgically treated for Cushing's syndrome postoperatively surrender to "primary" adrenal insufficiency. However, the preoperative over-secretion of cortisol or the postoperative administration of excessive glucocorticoids can cause "secondary" adrenal insufficiency, in which the prevalence of hyponatremia is usually lower than that of primary adrenal insufficiency.

**Case Report:** A 60-year-old woman with a past medical history of Cushing's syndrome developed hyponatremia with symptoms of acute glucocorticoid deficiency, such as prolonged general fatigue and anorexia, after upper respiratory tract infection. A decrease in the serum cortisol level and the lack of increase in the ACTH level, despite the increased demand for cortisol, enabled a diagnosis of "secondary" adrenal insufficiency. Although the initial fluid replacement therapy was not effective, co-administration of dexamethasone and sodium chloride quickly resolved her symptoms and ameliorated the refractory hyponatremia.

**Conclusions:** In this case, the hypothalamic-pituitary axis of the patient was thought to have become suppressed long after the surgical treatment for Cushing's syndrome. This case suggested a mechanism of refractory hyponatremia caused by secondary adrenal insufficiency, for which the administration of dexamethasone and sodium chloride exerted additional therapeutic efficacy.

**MeSH Keywords:** Adrenal Insufficiency • Cushing Syndrome • Dexamethasone • Hyponatremia • Sodium Chloride

**Full-text PDF:** <http://www.amjcaserep.com/abstract/index/idArt/894468>

 1338   1  17



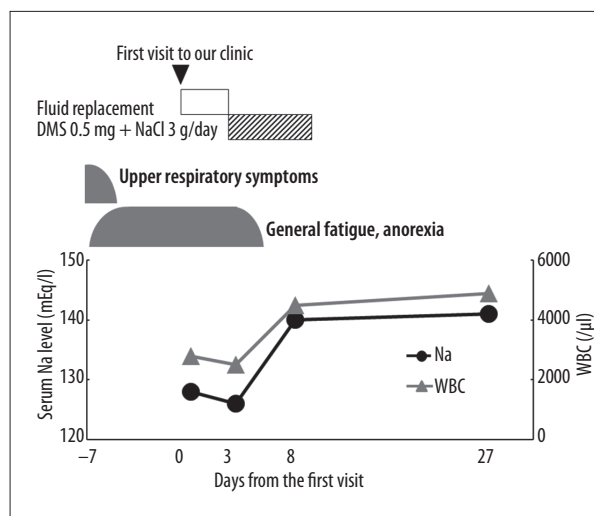
## Background

Patients with Cushing's syndrome, who undergo unilateral adrenalectomy or the surgical resection for adrenal tumors, postoperatively surrender to "primary" adrenal insufficiency (or also known as "Addison's disease"), since the contralateral adrenal gland is often suppressed by the prolonged over-secretion of cortisol [1]. In these patients, in addition to the symptoms caused by the glucocorticoid deficiency, such as general fatigue, anorexia or weight loss [2], the decreased activity of mineralocorticoids often causes hyponatremia and hypotension, which sometimes results in severe volume depletion [3] and the increased risks of cardiovascular morbidity and mortality [4]. Therefore, to prevent the occurrence of such symptoms, the exogenous replacement therapy with both glucocorticoids and mineralocorticoids is usually required postoperatively [5,6]. However, as we previously reported in a case [7], the preoperative over-secretion of cortisol or the postoperative administration of excessive glucocorticoids can cause "secondary" adrenal insufficiency, in which the hypothalamic-pituitary axis is functionally suppressed [8]. In secondary adrenal insufficiency, the prevalence of hyponatremia is usually lower compared to that of primary adrenal insufficiency, since the release of mineralocorticoids is usually preserved [2]. Here, we report an additional case of secondary adrenal insufficiency that developed hyponatremia long after the surgical treatment for Cushing's syndrome. This case suggested a mechanism of refractory hyponatremia caused by secondary adrenal insufficiency, for which the administration of dexamethasone and sodium chloride exerted additional therapeutic efficacy.

## Case Report

A 60-year old woman came to our outpatient clinic because of general fatigue and anorexia which persisted for 7 days after she first noticed the symptoms of an upper respiratory tract infection, including pharyngalgia and mild fever (Figure 1). She had a past medical history of Cushing's syndrome at the age of 14, for which a left adrenal adenoma was surgically resected, followed by radiation therapy. Oral administration of prednisolone was initiated postoperatively, although it was quickly tapered off in an outpatient clinic near her home.

On physical examination, the patient was pale and appeared exhausted. Her body temperature was 35.6°C, blood pressure was 107/60 mmHg, and pulse rate was 62 beats/min. She weighed 45 kg and was 155 cm tall. Her skin was not dry and there was no pigmentation. Her oral mucosa was moist and the pharynx was slightly reddish. On physical examination of the neck, cervical lymph nodes or thyroid masses were not palpable. No murmurs or 3<sup>rd</sup> sound were heard on cardiac auscultation and there was no pitting edema on either leg. Laboratory



**Figure 1.** Clinical course and the changes in free serum sodium level (Na) and peripheral white blood cell counts (WBC). The patient developed hyponatremia, presenting general fatigue and anorexia after upper respiratory tract infection. Although fluid replacement therapy with 0.9% saline was insufficient, co-administration of dexamethasone (DMS) and sodium chloride (NaCl) quickly resolved the symptoms and ameliorated the hyponatremia, which did not recur after withdrawal of the drugs. DMS – dexamethasone; NaCl – sodium chloride; Na – sodium; WBC – peripheral white blood cells.

data showed severe hyponatremia (128 mEq/l) with a marked decrease in the peripheral white blood cell counts (2800/μl), in which neutrophils were absolutely decreased (1168/μl) but lymphocytes were relatively increased (1179/μl). For her hyponatremia, fluid replacement with 0.9% saline was started as the initial treatment, although the treatment did not ameliorate the electrolyte disorder, nor did it improve her clinical symptoms (Figure 1). In the present case, we did not initially examine urinary sodium concentration or osmolality to differentiate sodium depletion from the other causes of hyponatremia, such as polydipsia and syndrome of inappropriate secretion of antidiuretic hormone (SIADH) [9]. However, since both the serum creatinine and blood urea nitrogen (BUN) levels were normal (Cr, 0.51 mg/dl; BUN, 12.1 mg/dl) and the patient did not show any signs of volume depletion or overload, her hyponatremia refractory to the initial treatment was not likely to be caused by salt wasting or excessive water retention as a result of renal insufficiency. Instead, a significant decrease in the serum cortisol level (5.0 μg/dl) with prolonged symptoms of glucocorticoid deficiency enabled a diagnosis of hyponatremia caused by acute adrenal insufficiency. In this case, we did not perform endocrinological examinations that stimulate the hypothalamic-pituitary axis, such as the loading tests of adrenocorticotropic hormone (ACTH) or corticotropin-releasing hormone (CRH). However, as we previously described

in a case report [7], the lack of an increase in the serum ACTH (34.6 pg/ml) despite the increased demand for cortisol during physical stress, such as having a viral infection, strongly suggested the diagnosis of "secondary" adrenal insufficiency, in which the hypothalamic-pituitary axis is functionally damaged. Immediately after the diagnosis, oral administration of dexamethasone (0.5 mg/day) and sodium chloride (3 g/day) was simultaneously started (Figure 1). Shortly after the initiation of the drugs, the patient's clinical symptoms, including general fatigue and anorexia, quickly disappeared without any recurrence (Figure 1). By 5 days after the initiation of the drugs, both the serum sodium level and the peripheral white blood cell counts returned to normal, which was maintained thereafter despite the discontinuation of the drugs, indicating the complete remission of the disease (Figure 1).

## Discussion

In the literature, there have been several cases of acute adrenal insufficiency after unilateral adrenalectomy for adrenal adenoma [10–12]. In those cases, the contralateral adrenal glands became postoperatively unresponsive to any internal stimuli of ACTH, possibly through their atrophy, the involvement of autoimmune mechanisms, or precipitation of a certain drug in the glands, causing "primary" adrenal insufficiency. However, we previously reported a case of "secondary" adrenal insufficiency, in which the hypothalamic-pituitary axis of the patient was functionally suppressed long after the unilateral adrenalectomy [7]. In patients with Cushing's syndrome, the prolonged over-secretion of cortisol from adrenal tumors is known to cause a functional disorder in the hypothalamic-pituitary axis [1]. Therefore, those who undergo unilateral adrenalectomy or surgical resection of the tumors require continuous glucocorticoid replacement therapy followed by its gradual withdrawal, until the hypothalamic-pituitary axis functionally recovers [8]. In the present case, however, the patient had not undergone adequate glucocorticoid replacement therapy postoperatively, which possibly caused a decrease in the secretory capacity of cortisol. Therefore, despite the increased demand for cortisol during the adrenal crisis in the present episode, the serum levels of both cortisol and ACTH remained relatively low, causing "secondary" adrenal insufficiency.

In secondary adrenal insufficiency where the pituitary secretion of ACTH is deficient, the clinical symptoms are primarily caused by the decreased secretion of glucocorticoids from adrenal glands, including general fatigue, anorexia, and weight loss [2]. However, electrolyte disturbances, such as hyponatremia, are less common in secondary adrenal insufficiency, since the secretion of mineralocorticoids (aldosterone), which

mostly depends on the renin-angiotensin system rather than on ACTH, is usually preserved [2]. In our case, although the patient did not show any apparent signs of volume depletion or overload, she presented hyponatremia refractory to the initial fluid replacement therapy with saline. Because the administration of dexamethasone, despite its lack of mineralocorticoid activity, quickly restored her serum sodium level (Figure 1), the glucocorticoid deficiency alone was thought to have induced the hyponatremia. In cases of hyponatremia, differentiating sodium depletion from the other causes of hyponatremia, such as polydipsia and SIADH, is important, because the treatment strategies vary depending on the mechanisms of hyponatremia [9]. In this case, we did not examine the serum level of antidiuretic hormone (ADH), nor did we initially evaluate the values of urinary sodium concentration or osmolality. However, the cortisol deficiency, which inversely stimulates the pituitary release of ADH [13], may have caused the water retention and thus decreased the serum sodium concentration of the patient. In this context, dexamethasone, which suppresses the ADH release [13], was thought to be effective for her refractory hyponatremia by halting the further retention of excessive water [14]. Additionally, according to previous basic studies, dexamethasone stimulates the expression of sodium transporters [15], such as bumetanide-sensitive cotransporter 1 (BSC1/NKCC2) [16,17], in the thick ascending limb of Henle's loop, and thus enhances the renal reabsorption of sodium [15]. Therefore, in this regard, the co-administration of sodium chloride with dexamethasone was thought to have exerted increased therapeutic efficacy in ameliorating the refractory hyponatremia caused by the secondary adrenal insufficiency.

## Conclusions

We reported a case of secondary adrenal insufficiency that developed hyponatremia long after the surgical treatment for Cushing's syndrome. This case suggested a mechanism of refractory hyponatremia caused by secondary adrenal insufficiency, for which the administration of dexamethasone and sodium chloride exerted additional therapeutic efficacy. Ameliorating hyponatremia is important to reduce the risks of cardiovascular morbidity and mortality [4].

## Conflict of interest

None declared.

## Acknowledgements

We thank the staff at Iwakiri Hospital for their assistance.

## References:

1. Graber AL, Ney RL, Nicholson WE et al: Natural history of pituitary-adrenal recovery following long-term suppression with corticosteroids. *J Clin Endocrinol Metab*, 1965; 25: 11–16
2. Burke CW: Adrenocortical insufficiency. *Clin Endocrinol Metab*, 1985; 14(4): 947–76
3. Spital A: Hyponatremia in adrenal insufficiency: review of pathogenetic mechanisms. *South Med J*, 1982; 75(5): 581–85
4. Lasek-Bal A, Holecki M, Kret B et al: Evaluation of influence of chronic kidney disease and sodium disturbances on clinical course of acute and sub-acute stage first-ever ischemic stroke. *Med Sci Monit*, 2014; 20: 1389–94
5. Peacey SR, Guo CY, Robinson AM et al: Glucocorticoid replacement therapy: are patients over treated and does it matter? *Clin Endocrinol (Oxf)*, 1997; 46(3): 255–61
6. Jadoul M, Ferrant A, De Plaen JF, Crabbe J: Mineralocorticoids in the management of primary adrenocortical insufficiency. *J Endocrinol Invest*, 1991; 14(2): 87–91
7. Kazama I, Komatsu Y, Ohiwa T et al: Delayed adrenal insufficiency long after unilateral adrenalectomy: prolonged glucocorticoid therapy reduced reserved secretory capacity of cortisol. *Int J Urol*, 2005; 12(6): 574–77
8. Plager JE, Cushman P Jr: Suppression of the pituitary-ACTH response in man by administration of ACTH or cortisol. *J Clin Endocrinol Metab*, 1962; 22: 147–54
9. Siegel AJ: Is urine concentration a reliable biomarker to guide vaptan usage in psychiatric patients with symptomatic hyponatremia? *Psychiatry Res*, 2015; 226(1): 403–4
10. Nagai Y, Ohsawa K, Hayakawa T et al: Acute adrenal insufficiency after unilateral adrenalectomy in Cushing's syndrome: precipitation by lithium-induced thyrotoxicosis during cortisol replacement. *Endocr J*, 1994; 41(2): 177–82
11. Mohler JL, Flueck JA, McRoberts JW: Adrenal insufficiency following unilateral adrenalectomy: a case report. *J Urol*, 1986; 135(3): 554–56
12. König KB, Krarup T, Lund JO: [Adrenal insufficiency after unilateral adrenalectomy for primary hyperaldosteronism]. *Ugeskr Laeger*, 2002; 164(3): 340–42
13. Raff H: Glucocorticoid inhibition of neurohypophysial vasopressin secretion. *Am J Physiol*, 1987; 252(4 Pt 2): R635–44
14. Oelkers W: Hyponatremia and inappropriate secretion of vasopressin (antidiuretic hormone) in patients with hypopituitarism. *N Engl J Med*, 1989; 321(8): 492–96
15. Attmane-Elakeb A, Sibella V, Vernimmen C et al: Regulation by glucocorticoids of expression and activity of rBSC1, the Na<sup>+</sup>-K<sup>+</sup>-(NH<sub>4</sub><sup>+</sup>)-2Cl<sup>-</sup> cotransporter of medullary thick ascending limb. *J Biol Chem*, 2000; 275(43): 33548–53
16. Kazama I, Hatano R, Michimata M et al: BSC1 inhibition complements effects of vasopressin V2 receptor antagonist on hyponatremia in SIADH rats. *Kidney Int*, 2005; 67(5): 1855–67
17. Kazama I, Arata T, Michimata M et al: Lithium effectively complements vasopressin V2 receptor antagonist in the treatment of hyponatremia of SIADH rats. *Nephrol Dial Transplant*, 2007; 22(1): 68–76