

[CASE REPORT]

Sorafenib Rechallenge and Sorafenib after Lenvatinib Failure in a Patient with Hepatocellular Carcinoma

Atsuyuki Ikeda¹, Kentaro Aoki¹, Masahito Kawamura¹,
Daisuke Yamaguchi² and Hiroyuki Kokuryu¹

Abstract:

A 70-year-old man was diagnosed with multiple lung metastases from hepatocellular carcinoma, and lenvatinib was initiated. Three months later, the response was progressive disease. Sorafenib therapy as a second-line drug was started. Three months later, the lung metastases had shrunk. After the sorafenib failure, the patient received regorafenib treatment for six months until failure. After the regorafenib failure, sorafenib rechallenge therapy as a fourth-line treatment was initiated. The sorafenib rechallenge, which continued for two months, induced a partial response. Sorafenib after lenvatinib failure and sorafenib rechallenge may be a good option, but further prospective studies are needed.

Key words: hepatocellular carcinoma (HCC), lenvatinib, lenvatinib failure, sorafenib, regorafenib, rechallenge

(Intern Med 60: 403-407, 2021)

(DOI: 10.2169/internalmedicine.5552-20)

Introduction

Lenvatinib is the first multikinase inhibitor reported to be non-inferior to sorafenib treatment for cases of advanced hepatocellular carcinoma (HCC) (1). A subgroup analysis revealed that lenvatinib significantly improves the progression-free survival, time to progression, and objective response rate. In addition, lenvatinib is more cost-effective than sorafenib (2). Accordingly, lenvatinib is considered as the first-line agent for treatment of advanced HCC. In Japan, besides lenvatinib, sorafenib, regorafenib, and ramucirumab can now also be used as systemic therapy for advanced HCC. Evidence for second-line treatments in patients who fail or are intolerant to lenvatinib, however, is lacking.

We herein report an advanced HCC case with good responses to sorafenib and regorafenib as secondary and tertiary lines of therapy and then to rechallenge therapy, first with sorafenib and then with regorafenib, in a patient who failed lenvatinib.

Case Report

A 66-year-old man was diagnosed with HCC tumors having diameters of 26, 14, and 8 mm by magnetic resonance imaging. Serologic markers for hepatitis B and C viruses were all negative. His liver function was Child-Pugh class A. He was initially treated with partial resection and radiofrequency ablation. The tumor was diagnosed as moderately differentiated HCC, and the background liver was histologically diagnosed as non-alcoholic steatohepatitis.

He experienced a recurrence of HCC two times, and radiofrequency ablation was performed two and three years after the first treatment. Seven months later, when he was 70 years old, multiple lung metastases were detected (Fig. 1a, b), and we introduced systemic treatment with lenvatinib.

At the beginning of the lenvatinib therapy, his alpha fetoprotein (AFP) level was 379 ng/mL. Four weeks after starting the lenvatinib, his AFP level decreased to 117 ng/mL. The lenvatinib treatment had to be suspended for two weeks, and the restart dose was reduced due to grade 3 proteinuria, as defined by the Common Terminology Criteria for Ad-

¹Department of Gastroenterology and Hepatology, Kyoto Katsura Hospital, Japan and ²Department of Medical Oncology, Kyoto Katsura Hospital, Japan

Received for publication June 8, 2020; Accepted for publication July 7, 2020

Correspondence to Dr. Atsuyuki Ikeda, atsiked@katsura.com

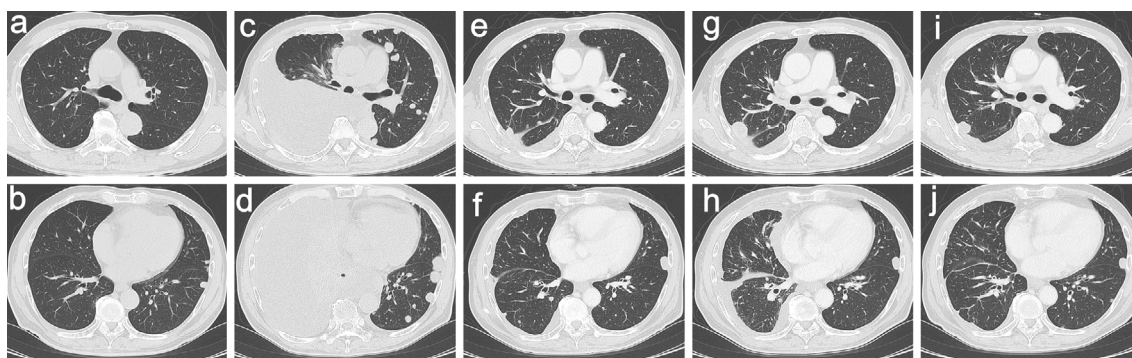


Figure 1. Computed tomography of lung metastases from lenvatinib failure to sorafenib and regorafenib. (a, b) Multiple small lung metastases before lenvatinib treatment. (c, d) Numerous lung metastases and massive right pleural effusion were observed three months after starting lenvatinib. (e, f) The lung metastases had shrunk, and the pleural effusion had nearly disappeared three months after starting sorafenib. (g, h) Five months after starting sorafenib, the pleural effusion had returned, and the lung metastases had grown. (i, j) The lung metastases shrank again four months after starting regorafenib.

verse Events. Two months after starting the lenvatinib, his AFP level significantly increased to 1,089 ng/mL. Three months after starting the lenvatinib, the AFP level had further increased to 1,891 ng/mL, and numerous lung metastases were observed (Fig. 1c, d). At this time, the response to lenvatinib treatment was judged to be progressive disease (PD) according to the modified Response Evaluation Criteria in Solid Tumors (mRECIST) (3). The lenvatinib treatment was therefore discontinued, and he was emergently admitted to the hospital because of respiratory distress due to massive pleural effusion. Cytology of the pleural effusion revealed HCC.

At the time of the lenvatinib failure, there was no evidence to support any second-line treatment. He had a good liver function, so we proposed sorafenib therapy as a second-line treatment, and the patient agreed to receive it. After thoracic drainage of the pleural effusion by pleurodesis, his respiratory symptoms improved, and sorafenib was started at 400 mg per day. At the beginning of the sorafenib treatment, 3 weeks after stopping the lenvatinib, his AFP level further increased to 5,505 ng/mL. After confirming the absence of adverse events, the sorafenib dose was increased to 800 mg over 3 months. At this time, the AFP level remarkably decreased to 165 ng/mL. The lung metastases had shrunk, and the pleural effusion had nearly disappeared (Fig. 1e, f). We considered that the sorafenib had produced a partial response (PR) according to the mRECIST as a second-line treatment after lenvatinib failure.

Five months after starting the sorafenib, his AFP level increased to 1,840 ng/mL, the pleural effusion increased, and the lung metastases became enlarged (Fig. 1g, h). At this point, sorafenib treatment was stopped due to PD, and regorafenib 80 mg per day (21 days on, 7 days off treatment) was initiated as a third-line treatment. After confirming, the absence of adverse events, the regorafenib dose was increased to 160 mg over 3 months. During the dose escalation, the patient's AFP level decreased to 257 ng/mL, and

the lung metastases diminished (Fig. 1i, j). Six months after starting the regorafenib, his AFP level had increased to 439 ng/mL, and the lung metastases again showed progression. Mediastinal, axillary, and peritoneal lymph node metastases were observed (Fig. 2a-c).

At this time, regorafenib was discontinued due to PD, and ramucirumab was available in Japan for advanced HCC patients with AFP concentrations of at least 400 ng/mL. Although we were considering administering ramucirumab as a fourth-line chemotherapy, the patient was admitted to the hospital for an ileus due to peritoneal dissemination. We performed resection of the peritoneal dissemination to alleviate the ileus. The patient had a good postoperative course and was discharged one week after the operation. Before and after surgery, we discontinued all chemotherapy for 4 weeks, and his AFP level increased to 2,991 ng/mL. We again considered beginning the ramucirumab treatment but could not do so because of his baseline proteinuria. At the time of deciding not to administer ramucirumab therapy, there were no other established treatment options available in Japan. However, his liver function was good (Child-Pugh class A), so we proposed sorafenib rechallenge therapy as a fourth-line treatment, and the patient agreed.

One month after starting the sorafenib rechallenge, his AFP level remarkably decreased to 691 ng/mL, and some lesions, such as the mediastinal lymph node and lung metastases, had shrunk (Fig. 2d-f). We judged the effectiveness of the sorafenib rechallenge to be PR according to the mRECIST. Two months after starting the sorafenib rechallenge, the AFP level again increased to 1,048 ng/mL. We proposed regorafenib rechallenge therapy as a fifth-line treatment, and again the patient agreed. One month after starting the regorafenib rechallenge, the AFP level decreased to 821 ng/mL. Two months after starting the regorafenib rechallenge, some lymph nodes had shrunk slightly (Fig. 2g-i). The clinical course of the serum AFP levels and the administration of the therapeutic agents is summarized in Fig. 3.

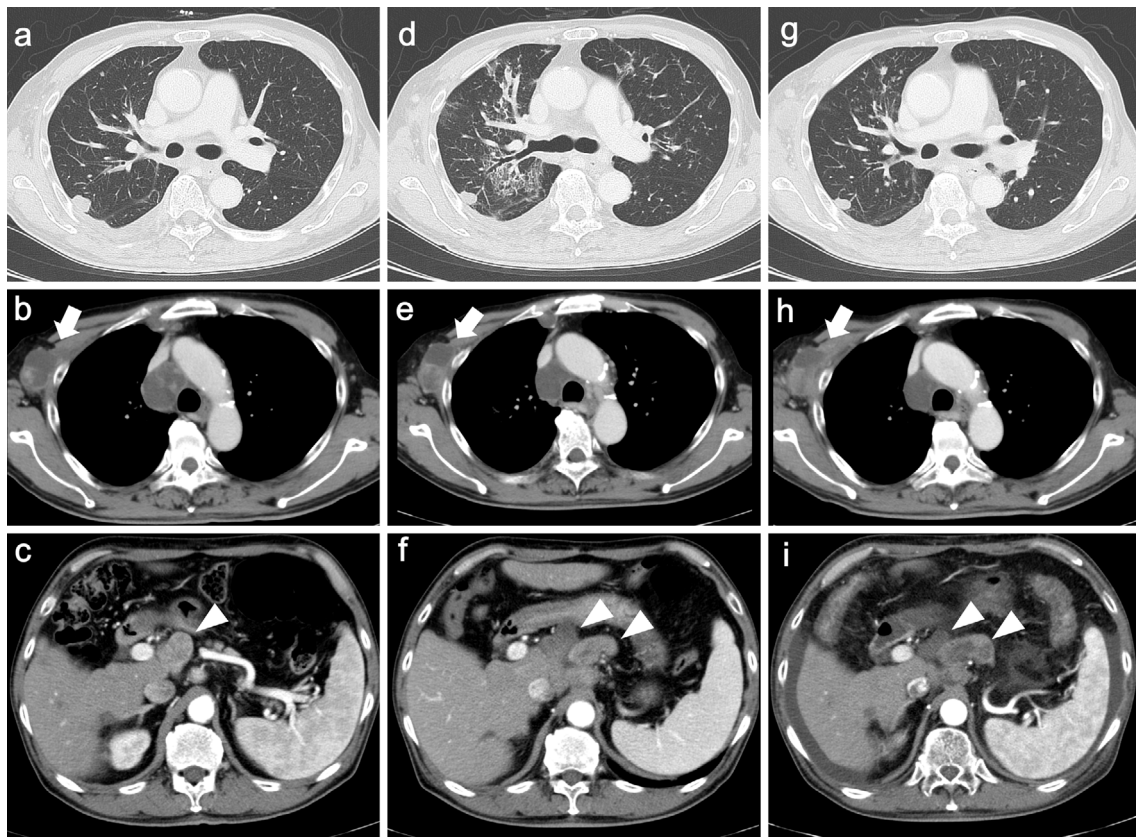


Figure 2. Findings of contrast enhanced computed tomography of mediastinal, axillary (white arrow), and peritoneal (white arrowhead) lymph nodes and lung metastases during sorafenib and regorafenib rechallenge treatment. (a, b, c) After resection of the peritoneal dissemination, the lung metastases had progressed. Mediastinal, axillary, and peritoneal lymph node metastases occurred. The mediastinal lymph node had an avascular area inside the lesion, which was thought to be necrotic due to the previous therapy. (d, e, f) One month after starting sorafenib rechallenge, the mediastinal and axillary lymph nodes and lung metastases had shrunk. An avascular area was detected in the peritoneal lymph node, indicating necrosis. (g, h, i) Two months after starting regorafenib rechallenge, the mediastinal and peritoneal lymph nodes had shrunk slightly, while the axillary lymph nodes showed no change.

Discussion

Patients with advanced HCC typically have poor survival outcomes. The treatment landscape for advanced HCC, however, is rapidly changing (4, 5). Sorafenib was the only approved standard systemic therapy as a first-line treatment for patients with unresectable HCC until lenvatinib became available. Lenvatinib was reported as the first drug that was non-inferior to sorafenib in terms of the overall survival in patients with untreated advanced HCC (1). In Japan, these two drugs can be used as first-line systemic therapy for advanced HCC. Lenvatinib is considered the most suitable drug for first-line therapy based on a subset analysis (2, 6).

Two other drugs, regorafenib and ramucirumab, are also available as second-line treatments in Japan (7, 8). Some evidence supports the use of these drugs as second-line treatment, but only after sorafenib failure and not after lenvatinib failure. In other countries, nivolumab, pembrolizumab, and cabozantinib have been approved as second-line

treatment after disease progression with sorafenib treatment (6), but there are no data regarding the effect of these drugs after lenvatinib failure. Thus, lenvatinib is considered a suitable first-line therapy, but evidence for second-line therapies after its failure is lacking.

In terms of sequential therapy, there is currently no evidence regarding the appropriate order of systematic therapy. In the REFLCT study (1), the overall survival of patients after lenvatinib failure with post-study anticancer medication was 20.8 months, while that without post-study anticancer medication was 11.5 months. Of the post-study anticancer medications examined, sorafenib treatment was used in 77.6% of the cases (1). Based on these results, sorafenib after lenvatinib failure might have some benefit as a sequential therapy.

Lenvatinib inhibits vascular endothelial growth factor receptors (VEGF) 1-3, fibroblast growth factor (FGF) receptors 1-4, platelet-derived growth factor receptor (PDGFR) α , RET, and KIT (1). In contrast, sorafenib inhibits VEGF receptors 1-3, PDGFR β , and the serine-threonine kinases

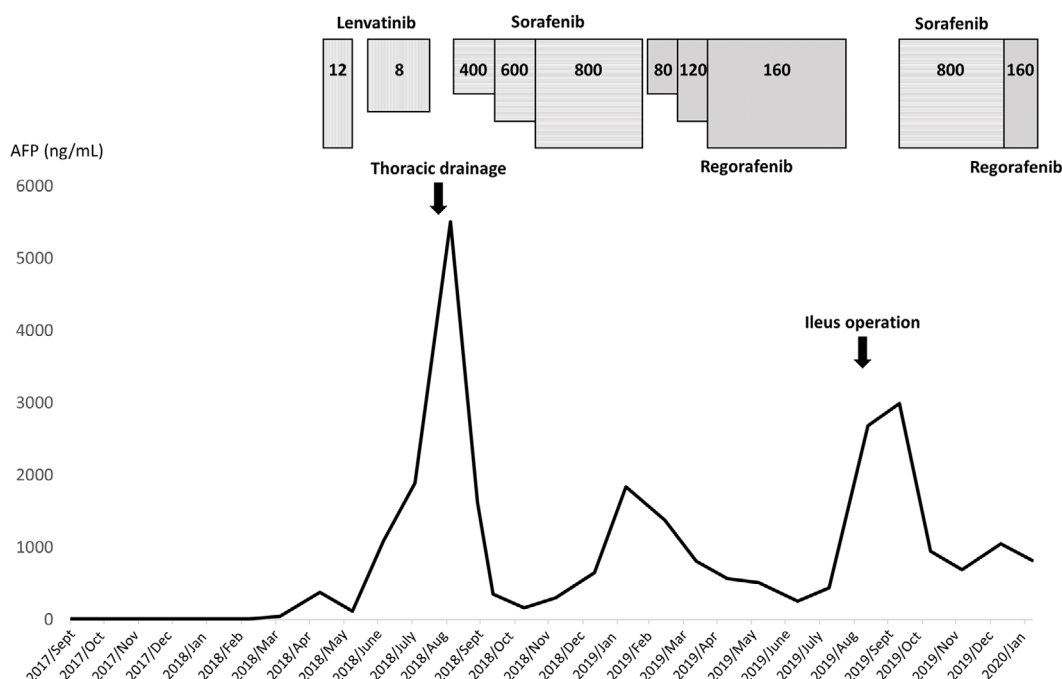


Figure 3. Summary of the clinical course of the serum alpha fetoprotein levels and the timing of administration of the therapeutic agents. The dose of each therapeutic agent is shown.

Raf-1 and B-Raf (9). Lenvatinib suppresses these various signals in cancer cells more strongly than sorafenib (10) and is distinguished from sorafenib in that it can target FGF signaling pathways (11). Sorafenib can only inhibit Raf-1 and B-Raf, whose levels correlate with tumor angiogenesis (12). The mitogen-activated protein kinase (MAPK) pathway and BRAF signaling play a crucial role in the regulation of the HCC cell proliferation and survival (13, 14). Specifically, MAPK kinase and MAPK mRNAs are overexpressed in 40% and 50% of HCC patients, respectively (15). These differences may induce variability in the effectiveness of anti-cancer agents. There are currently no biomarkers that predict the effectiveness before induction of the drug. Unfortunately, there is no evidence indicating that Raf-1 and B-Raf played an important role in our case. We do not know why our case showed a clinical response to only sorafenib and regorafenib.

Rechallenge with previous therapies, including tyrosine kinase inhibitors (TKIs), may be effective for various kinds of cancers (16-18). Drug rechallenge provides meaningful clinical benefits. First-generation TKIs, such as imatinib, specifically inhibit key molecules. Thus, a genetic alteration related to the key molecule directly correlates with drug resistance. However, with multikinase inhibitors, such as sorafenib, regorafenib, and lenvatinib, one genetic change does not directly cause drug resistance. Various genetic alterations and the expression of genes without mutations may be responsible for resistance to these drugs. The causes of primary resistance and secondary resistance differ (18). The new mutations responsible for secondary resistance to TKIs seem to arise from clonal and/or polyclonal secondary evolution after initial therapy. Drug cessation due to disease

progression or adverse events also may cause novel mutations or a return to the original genetic condition. In a previous report, the response to rechallenge depended on the initial response (19). In our case, the patient acquired resistance after the initial response to the first sorafenib treatment as second-line therapy. The patient again exhibited a good response, however, to the second sorafenib treatment as fourth-line therapy. While the mechanism involved is unclear, we speculate that the drug sensitivity had changed after cessation of the drug during the ileus operation or regorafenib administration. At present, data regarding sorafenib and regorafenib as a rechallenge for liver cancer are lacking, and further evidence is necessary.

In conclusion, we experienced a rare case of advanced HCC that did not show a good response to lenvatinib, and therefore was treated by sorafenib and regorafenib during a rechallenge. To our knowledge, this is the first report describing sorafenib after lenvatinib failure and sorafenib rechallenge for HCC. These drugs have different mechanisms, and the patient groups expected to have a good response differ between them as well. Sorafenib rechallenge may be a good option, especially for cases with a good initial response. Various drugs should be considered based on the previous treatment response, but further prospective studies are needed.

The authors state that they have no Conflict of Interest (COI).

References

1. Kudo M, Finn RS, Qin S, et al. Lenvatinib versus sorafenib in first-line treatment of patients with unresectable hepatocellular car-

- cinoma: a randomised phase 3 non-inferiority trial. *Lancet* **391**: 1163-1173, 2018.
2. Kobayashi M, Kudo M, Izumi N, et al. Cost-effectiveness analysis of lenvatinib treatment for patients with unresectable hepatocellular carcinoma (uHCC) compared with sorafenib in Japan. *J Gastroenterol* **54**: 558-570, 2019.
 3. Lencioni R, Llovet JM. Modified RECIST (mRECIST) assessment for hepatocellular carcinoma. *Semin Liver Dis* **30**: 52-60, 2010.
 4. Ikeda K. Recent advances in medical management of hepatocellular carcinoma. *Hepatol Res* **49**: 14-32, 2019.
 5. Rimassa L, Pressiani T, Merle P. Systemic treatment options in hepatocellular carcinoma. *Liver Cancer* **8**: 427-446, 2019.
 6. Yamashita T, Kudo M, Ikeda K, et al. REFLECT-a phase 3 trial comparing efficacy and safety of lenvatinib to sorafenib for the treatment of unresectable hepatocellular carcinoma: an analysis of Japanese subset. *J Gastroenterol* **55**: 113-122, 2020.
 7. Bruix J, Qin S, Merle P, et al. Regorafenib for patients with hepatocellular carcinoma who progressed on sorafenib treatment (RESORCE): a randomised, double-blind, placebo-controlled, phase 3 trial. *Lancet* **389**: 56-66, 2017.
 8. Zhu AX, Kang YK, Yen CJ, et al. Ramucirumab after sorafenib in patients with advanced hepatocellular carcinoma and increased α -fetoprotein concentrations (REACH-2): a randomised, double-blind, placebo-controlled, phase 3 trial. *Lancet Oncol* **20**: 282-296, 2019.
 9. Llovet JM, Ricci S, Mazzaferro V, et al. Sorafenib in advanced hepatocellular carcinoma. *N Engl J Med* **359**: 378-390, 2008.
 10. Yamamoto Y, Matsui J, Matsushima T, et al. Lenvatinib, an angiogenesis inhibitor targeting VEGFR/FGFR, shows broad antitumor activity in human tumor xenograft models associated with microvessel density and pericyte coverage. *Vasc Cell* **6**: 18, 2014.
 11. Llovet JM, Zucman-Rossi J, Pikarsky E, et al. Hepatocellular carcinoma. *Nat Rev Dis Primers* **2**: 16018, 2016.
 12. Liu L, Cao Y, Chen C, et al. Sorafenib blocks the RAF/MEK/ERK pathway, inhibits tumor angiogenesis, and induces tumor cell apoptosis in hepatocellular carcinoma model PLC/PRF/5. *Cancer Res* **66**: 11851-11858, 2006.
 13. Gnoni A, Licchetta A, Memeo R, et al. Role of BRAF in hepatocellular carcinoma: a rationale for future targeted cancer therapies. *Medicina (Kaunas)* **55**: 754, 2019.
 14. Calvisi DF, Ladu S, Gorden A, et al. Ubiquitous activation of Ras and Jak/Stat pathways in human HCC. *Gastroenterology* **130**: 1117-1128, 2006.
 15. Hoffmann K, Shibo L, Xiao Z, Longerich T, Büchler MW, Schemmer P. Correlation of gene expression of ATP-binding cassette protein and tyrosine kinase signaling pathway in patients with hepatocellular carcinoma. *Anticancer Res* **31**: 3883-3890, 2011.
 16. Felicetti F, Nervo A, Piovesan A, et al. Tyrosine kinase inhibitors rechallenge in solid tumors: a review of literature and a case description with lenvatinib in thyroid cancer. *Expert Rev Anticancer Ther* **17**: 1093-1098, 2017.
 17. Cremolini C, Rossini D, Dell'Aquila E, et al. Rechallenge for patients with RAS and BRAF wild-type metastatic colorectal cancer with acquired resistance to first-line cetuximab and irinotecan: a phase 2 single-arm clinical trial. *JAMA Oncol* **5**: 343-350, 2019.
 18. Agulnik M, Giel JL. Understanding rechallenge and resistance in the tyrosine kinase inhibitor era: imatinib in gastrointestinal stromal tumor. *Am J Clin Oncol* **37**: 417-422, 2014.
 19. Oudard S, Vano Y. The role of rechallenge with targeted therapies in metastatic renal-cell carcinoma. *Curr Opin Urol* **25**: 402-410, 2015.

The Internal Medicine is an Open Access journal distributed under the Creative Commons Attribution-NonCommercial-NoDerivatives 4.0 International License. To view the details of this license, please visit (<https://creativecommons.org/licenses/by-nc-nd/4.0/>).