



Review Article

Anticoagulants for cancer-associated ischemic stroke

Jin-Yi Hsu^a, An-Bang Liu^{a,b*}

^aDepartment of Neurology,
Hualien Tzu Chi Hospital,
Buddhist Tzu Chi Medical
Foundation, Hualien, Taiwan,
^bSchool of Medicine,
Tzu Chi University, Hualien,
Taiwan

Received : 09-Mar-2018
Revised : 24-May-2018
Accepted : 14-Feb-2019

ABSTRACT

Patients with cancer-associated ischemic stroke pose similar clinical manifestations and image characteristics, mainly embolic infarction, as patients with atrial fibrillation do. D-dimer, a degraded product of fibrin polymer, is a useful indicator of hypercoagulability, which frequently increases in cancer-associated stroke, but not in stroke resulted from atrial fibrillation. The level of serum D-dimer is associated with mortality, prognosis, and recurrence of systemic thromboembolism in these patients. Theoretically, drugs block coagulation cascade, such as heparin and low-molecular-weight-heparin (LMWH), oral direct anticoagulants, could attenuate the status of hypercoagulation and decrease the amount of D-dimer. These drugs may be helpful to prevent thromboembolic events in patients with cancer-associated hypercoagulability. Vitamin K antagonist, warfarin, decreases the production of coagulation factors, but not interrupts coagulation cascade may not be helpful to decrease hypercoagulability, but increase the risk of bleeding. However, the treatment of cancer-associated embolic stroke is still controversial. This article reviews relevant clinical studies and proposes the applicability of direct oral anticoagulants from the pathophysiological mechanism.

KEYWORDS: *Cancer-associated stroke, D-dimer, Hypercoagulability, Oral direct anticoagulants*

INTRODUCTION

Thrombosis is a well-known complication of cancer [1-3]. It causes either arterial thromboembolism or venous thrombosis before the diagnosis or during the treatment of cancer [4]. On the other hand, patients with thromboembolism of unknown causes sometimes have occult cancer [5,6]. A recent study found that occult cancer associated with unproved venous thromboembolism usually had poor outcome [7]. Although ischemic stroke is not the most common complication of cancer-associated thrombosis, it worsens the patient's life quality and indicates a poor prognosis [8-10]. Unlike a conventional ischemic stroke, the cancer-associated stroke usually presents embolic features at more than one vessel territory or at the border zone areas [11-13]. Since there is no significant causes after serial investigations including transesophageal echocardiography, Holter electrocardiogram, and computed tomography/magnetic resonance angiography, cancer-associated stroke have ever been classified as a cryptogenic stroke. Cancer survey is suggested [14,15]. D-dimer, a degraded product of fibrinolysis, has been used as an indicator of hypercoagulability caused by heterogeneous etiology in the clinical practice [16]. Tremendously, increased D-dimer has been found in patients with cryptogenic stroke and occult cancers as compared with the stroke patients without cancer [17,18]. The serum level of D-dimer correlates with

poor neurological outcome, early deterioration, 30-day mortality, and recurrence of thromboembolism [19-21].

PATHOPHYSIOLOGY OF CANCER-ASSOCIATED HYPERCOAGULABILITY

Although cancer-associated thromboembolism was found by Trousseau in 1865 [1], the nature of hypercoagulability was disclosed recently. There are several ways for cancer to induce thromboembolism by the release of cytokines, tissue factors, cancer procoagulants, and cancer mucin. Tumor cell-driving tissue factors and procoagulants accelerate coagulation cascade. Meanwhile, inflammatory cytokines and cancer-derived mucin also play an important role in platelet activation. By means of these factors, cancer cells induce hypercoagulability and result in disseminating thromboembolism [Figure 1] [22].

TREATMENT OF CANCER-ASSOCIATED THROMBOEMBOLISM

To correct hypercoagulability could improve overall survival after using anticoagulants. Thus, optimal anticoagulants

*Address for correspondence:

Dr. An-Bang Liu,
Department of Neurology, Hualien Tzu Chi Hospital,
Buddhist Tzu Chi Foundation, 707, Section 3,
Chung-Yang Road, Hualien, Taiwan.
E-mail: liuabpaper@yahoo.com.tw

Access this article online

Quick Response Code:



Website: www.tcmjmed.com

DOI: 10.4103/tcmj.tcmj_55_19

This is an open access journal, and articles are distributed under the terms of the Creative Commons Attribution-NonCommercial-ShareAlike 4.0 License, which allows others to remix, tweak, and build upon the work non-commercially, as long as appropriate credit is given and the new creations are licensed under the identical terms.

For reprints contact: reprints@medknow.com

How to cite this article: Hsu JY, Liu AB. Anticoagulants for cancer-associated ischemic stroke. Tzu Chi Med J 2019;31(3):144-8.

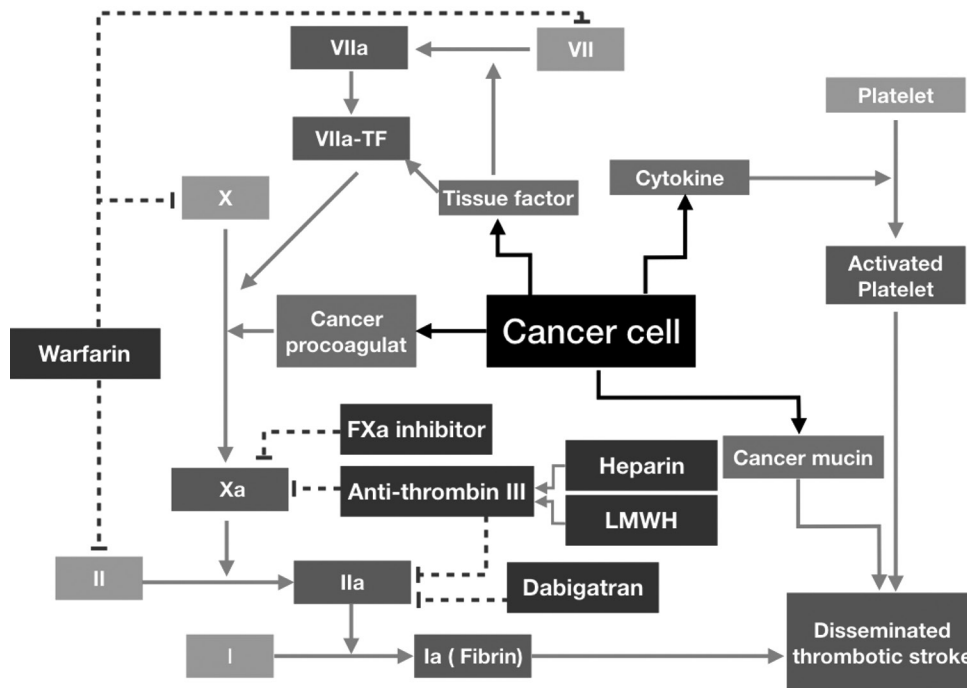


Figure 1: The pathophysiology of cancer-associated hypercoagulability and the pharmacological mechanism of anticoagulants. Cancer cell secretes several molecules, including tissue factors, cancer procoagulants, cytokines, and cancer mucin to accelerate coagulation cascade and platelet activation and then result in thromboembolism. Heparin promotes the activity of antithrombin III and then blocks the function of activated coagulation factors Xa and IIa. Low-molecular-weight-heparin blocks the function of Xa. Direct oral anticoagulants inhibit the function of coagulation factor Xa or IIa. Vitamin K antagonist, warfarin, block the synthesis of coagulation factors II, VII, IX, and X by inhibiting the function of carboxylase in hepatocytes (light gray line, activating; dot line inhibiting)

are warranted to prevent recurrent strokes in the patients with cancer-associated hypercoagulability [23]. However, cancer patients with conventional oral anticoagulant, Vitamin K antagonist, experience liability of international normalized ratio (INR) and have difficulty in maintaining therapeutic ranges [24], which results in a dilemma between of risk of recurrent stroke if not using anticoagulants or tendency of massive bleeding during necessary surgeries or cancer *per se*. Although some clinical consensuses suggest administrating LMWH in cancer-associated thrombosis, especially for venous thromboembolism [25,26], this recommended therapeutic option is burdensome and lowers medication adherence. In a current study for patients with cancer-associated thrombosis, warfarin and direct oral anticoagulants (DOACs) are least as similarly utilized as LMWH [27]. DOACs are potentially useful and convenient choices. A recent clinical trial showed noninferior effect of DOACs to LMWH for venous thromboembolism in cancer patients [28]. However, there are just few articles concerning the applicability of anticoagulants in the stroke patients with cancer-associated hypercoagulability.

SECONDARY PREVENTION FOR STROKE PATIENTS WITH CANCER-ASSOCIATED HYPERCOAGULABILITY

Although ischemic stroke is not uncommon in patients with cancer-associated hypercoagulability, there are limited literature and no clinical consensus concerning secondary prevention of stroke for patients with cancer-associated hypercoagulability. The application of anticoagulants remains controversial. In a series of 268 stroke patients with active cancer, to correct hypercoagulability by anticoagulants with

decreased D-dimer could improve 1-year survival in the stroke patients. Thus, optimal anticoagulant therapy may be warranted to prevent recurrent strokes in patients with cancer-associated hypercoagulability. However, the authors did not show what anticoagulants had been used in this paper [23]. The application of anticoagulant in stroke patients with cancer-associated hypercoagulability is till controversial. A recent claimed data analysis in the United States evaluated the occurrence of stroke and risk of bleeding among the atrial fibrillation patients with history of cancer. The results found that early cardiology involvement with oral anticoagulant reduced the risk of stroke with an increase of bleeding in patients with either active or remote history of cancer [29].

The following antiembolic agents have ever been used in the secondary prevention of cancer-associated stroke [Table 1].

Warfarin

Warfarin is the oldest anticoagulant used for thromboembolism. It inhibits blood clot formation by blocking Vitamin K epoxide reductase, which synthesizes coagulation factors II, VII, IX, and X in the liver. Warfarin has been used for stroke prevention for patients with atrial fibrillation and valvular heart diseases for a long time. It has ever been suggested as an alternative therapy for cancer-associated thromboembolism when LMWH was not available [26]. The difficulty to maintain adequate INR due to multiple drugs, drug-, or food-drug interactions is a trouble issue in clinical practice [35]. In addition, increased bleeding risk limits the application of warfarin in cancer-associated hypercoagulability [36]. The

Table 1: Current reports about direct oral anticoagulants for stroke prevention for patients with active cancer

Investigators	Study period	Study design	Case number	Medications	Outcome
Lee <i>et al.</i> [23]	January 2006-July 2015	Observational	268	Heparin/warfarin: 113 LMWH: 89 AP: 51 None: 20	Decreasing D-dimer improving outcome Efficacy of each antithromboembolic agents uncertain
Jang <i>et al.</i> [30]	July 2006-December 2012	Observational	79	Enoxaparin: 29 Warfarin: 50	Ischemic stroke 3.4% versus 16%, $P=0.249$ Major bleeding 6.9% versus 10%, $P=0.96$
Nam <i>et al.</i> [31]	May 2012-June 2015	Observational	48	DOACs: 7 LMWH: 41	Ischemic stroke 57% versus 59%, $P>0.05$ Mortality 57% versus 59%, $P>0.05$ Bleeding events 29% versus 39%, $P=0.696$
Laube <i>et al.</i> [32]	January 2014-March 2016	Observational Primary prevention for Af patients with active cancer	163	Rivaroxaban: 163	Stroke rate 1.4% [§] Major bleeding 1.2% Nonmajor bleeding 14%
Shah <i>et al.</i> [33]	January 2010-December 2014	Observational Claimed database of Af patients with active cancer, receiving anticoagulants	16,096	Rivaroxaban: 2808 Dabigatran: 2189 Apixaban: 1078 Warfarin: 10,021	Ischemic stroke HR: 0.71-0.89, $P>0.05^*$ Severe bleeding HR: 0.37-1.09, $P>0.05^*$ Other bleeding HR: 0.58-0.79, $P>0.05^*$
Fanola <i>et al.</i> [34]	November 2008-November 2010	Randomized control patients with Af getting new or recurrent cancer	1153	Warfarin: 395 HDER: 390 Edoxaban (30 mg): 368	Ischemic stroke warfarin 2.38%/year HDER 1.43%/year LDER 2.04%/year Severe bleeding warfarin 8.18%/year HDER 7.92%/year LDER 5.95%/year

[§]Similar to those presented in the ROCKET-AF study in the general population, *As compared with warfarin. LMWH: Low-molecular-weight heparin, AP: Antiplatelet agents, DOACs: Direct oral anticoagulants, HDER: High-dose edoxaban (60 mg/day), LDER: Low-dose edoxaban (30 mg/day), VTE: Venous thromboembolism, Af: Atrial fibrillation, HR: Hazard ratio

studies about the benefits and hazards of warfarin for cancer-associated stroke are lack. In views of pathophysiology, the antithrombotic effect of warfarin is by means of inhibiting the formation of coagulation factors but not attenuating hypercoagulability [Figure 1]. It proposes the increased bleeding tendency caused by warfarin in patients with cancer-associated stroke [36].

Heparin and low-molecular-weight heparin

Heparin and LMWH block hypercoagulation by activating antithrombin III [Figure 1]. There were few papers showing the benefits of heparin on the acute stage of patients with cancer-associated stroke, by decreasing D-dimer in the serum. It improved 1-year survival of the patients. Long-term follow-ups were lacked [23,37]. Due to ease in administration and stable half-life, LMWH has been recommended in several clinical guidelines for the treatment of patients with deep vein thrombosis [38,39]. There are few papers mentioning the effect of LMWH in secondary prevention of stroke in cancer patients. In a series of 79 patients with cancer-associated stroke, 29 patients receiving LMWH and 50 patients taking warfarin, the results showed that LMWH decreased D-dimer level. However, the recurrence of stroke was not demonstrated in this paper [30].

Direct oral anticoagulant-dabigatran, rivaroxaban, apixaban, and edoxaban

Several DOACs, including direct thrombin inhibitor (dabigatran), and Xa inhibitors (rivaroxaban, apixaban, and edoxaban)

have been used in pulmonary embolism, deep vein thrombosis, nonvalvular atrial fibrillation, and valvular heart disease. Up to these, anticoagulants have only been proved for stroke prevention of nonvalvular atrial fibrillation [40]. There are only a few studies on the efficacy of DOACs for stroke prevention in cancer patients. Laube *et al.* reported 163 patients had atrial fibrillation and active cancer receiving rivaroxaban for primary stroke prevention. They found that the 1-year cumulative stroke rate was 1.4%, and the major bleeding rate was 1.2%. The efficacy of stroke prevention and risk of bleeding was comparable to the results of ROCKET-AF study in the general population [32,41].

Another hospital-based retrospective study, enrolling seven patients receiving DOACs, (five patients receiving dabigatran and two patients taking rivaroxaban) and 41 patients being treated with LMWH, demonstrated that DOACs had similar clinical outcomes, and less major bleeding as compared with LMWH did in secondary prevention for patients with active cancer and cryptogenic stroke [31]. Recently, a large retrospective study from claimed database disclosed the efficacy and safety of DOACs as compared with warfarin in patients with atrial fibrillation and active cancer. It showed that DOACs were more effective in preventing deep vein thrombosis than warfarin was. They were similar to or superior to warfarin in stroke prevention and less major bleeding though it lacked statistical significance [33]. A clinical trial, ENGAGE AF-TIMI 48, recruited 21,105 atrial fibrillation patients with new or

recurrent cancer treated with warfarin or edoxaban. Over a median of 495-day follow-up, there were 1153 patients got new or recurrent malignancy. These patients were divided into three groups for warfarin ($n = 395$), 60-mg edoxaban per day ($n = 390$), and 30-mg edoxaban per day. The results show that malignancy associated with increased risk of major bleeding but neither stroke nor systemic embolism. High-dose and low-dose edoxaban decreased stroke and systemic embolic events as compared with warfarin, but there was no statistical significance. They also had a low tendency of major bleeding. There was no statistical significance either [34].

Due to DOACs are suggested for stroke prevention for patients with nonvalvular atrial fibrillation, but not for cancer-associated stroke. The aforementioned studies are assessed the safety and risk of DOACs in patients with atrial fibrillation with active cancer, either recurrent or newly diagnosed not for pure cancer-associated stroke. A clinical trial, anticoagulation in cancer-related stroke (OASIS-CANCER, NCT02743052) would be completed in December 2018. The achievements of this study may offer more useful information about the efficacy and safety of DOACs for stroke prevention in cancer patients.

Unlike, the usage of INR in monitoring the effect of warfarin, it is suggested that coagulation assessments are not necessary for the patients receiving DOACs. However, drug-drug interaction through cytochrome CYP3A4 and P-glycoprotein competitor should be taken in to account. Chemotherapy, hormone therapy, immunotherapy, immunosuppressant drugs, and even antiemetics influence the metabolism of DOACs may increase the risk of major bleeding or the risk of recurrence of ischemic stroke [42]. Furthermore, the bleeding tendency with thrombocytopenia, or repeated major surgical procedures or even tumor bleeding are usually found in patients with active cancer. The complexity of patients with active cancer and associated stroke increases the necessity of reliable assessments and effective reversal agents during the application of DOACs. Dabigatran is the only DOACs can be reversed by its antidote, idarucizumab [43]. That might be a crucial point for the choice of DOACs for active cancer patients with cancer-associated stroke. Off-label usage of DOACs should be taken into account. The payment of DOAC for stroke prevention in patients with hypercoagulability may not be allowed by many insurance systems such as Taiwan's National Health Insurance. In addition to increasing the financial burden of the patients, the off-label prescription may let the physicians fall into embarrassments or lawsuits while massive or unpredictable hemorrhage exists. Therefore, the physicians should prescribe DOACs with caution and comprehensively elucidate the dilemma of choice to the patient and patient's family.

CONCLUSION

Cancer-associated stroke is not an uncommon neurological disease. In several patients, cerebral infarction occurred before the diagnosis of cancer. Multiple embolic strokes with elevated D-dimer alert the possibility of occult cancer. Serial cancer survey may be indicated. Currently, LMWH is recommended

for cancer patients with deep vein thrombosis, and it is also suggested for secondary prevention of cancer-associated stroke. Repeated subcutaneous injections decrease the drug adherence. In views of pathophysiology, DOACs may be the choices of treatment.

Financial support and sponsorship

Nil.

Conflicts of interest

There are no conflicts of interest.

REFERENCES

- Rickles FR, Edwards RL. Activation of blood coagulation in cancer: Trousseau's syndrome revisited. *Blood* 1983;62:14-31.
- Francis JL, Biggerstaff J, Amirkhosravi A. Hemostasis and malignancy. *Semin Thromb Hemost* 1998;24:93-109.
- Caine GJ, Stonelake PS, Lip GY, Kehoe ST. The hypercoagulable state of malignancy: Pathogenesis and current debate. *Neoplasia* 2002;4:465-73.
- Rickles FR, Levine MN. Venous thromboembolism in malignancy and malignancy in venous thromboembolism. *Haemostasis* 1998;28 (Suppl 3):43-9.
- Monreal M, Lafoz E, Casals A, Inaraja L, Montserrat E, Callejas JM, et al. Occult cancer in patients with deep venous thrombosis. A systematic approach. *Cancer* 1991;67:541-5.
- Prandoni P, Lensing AW, Büller HR, Cogo A, Prins MH, Cattelan AM, et al. Deep-vein thrombosis and the incidence of subsequent symptomatic cancer. *N Engl J Med* 1992;327:1128-33.
- Robin P, Otten HM, Delluc A, van Es N, Carrier M, Salaün PY, et al. Effect of occult cancer screening on mortality in patients with unprovoked venous thromboembolism. *Thromb Res* 2018;171:92-6.
- Navi BB, Singer S, Merkler AE, Cheng NT, Stone JB, Kamel H, et al. Cryptogenic subtype predicts reduced survival among cancer patients with ischemic stroke. *Stroke* 2014;45:2292-7.
- Shin YW, Lee ST, Jung KH, Kim DY, Park CK, Kim TM, et al. Predictors of survival for patients with cancer after cryptogenic stroke. *J Neurooncol* 2016;128:277-84.
- Kassubek R, Bullinger L, Kassubek J, Dreyhaupt J, Ludolph AC, Althaus K, et al. Identifying ischemic stroke associated with cancer: A multiple model derived from a case-control analysis. *J Neurol* 2017;264:781-91.
- Xie X, Chen L, Zeng J, Qin C, Cheng D, Wei X, et al. Clinical features and biological markers of lung cancer-associated stroke. *J Int Med Res* 2016;44:1483-91.
- Achiha T, Takagaki M, Oe H, Sakai M, Matsui H, Nakanishi K, et al. Voxel-based lesion mapping of cryptogenic stroke in patients with advanced cancer: A detailed magnetic resonance imaging analysis of distribution pattern. *J Stroke Cerebrovasc Dis* 2017;26:1521-7.
- Mai H, Xia J, Wu Y, Ke J, Li J, Pan J, et al. Clinical presentation and imaging characteristics of occult lung cancer associated ischemic stroke. *J Clin Neurosci* 2015;22:296-302.
- Saver JL. Cryptogenic stroke. *N Engl J Med* 2016;375:e26.
- Pearce LA, McClure LA, Anderson DC, Jacova C, Sharma M, Hart RG, et al. Effects of long-term blood pressure lowering and dual antiplatelet treatment on cognitive function in patients with recent lacunar stroke: A secondary analysis from the SPS3 randomised trial. *Lancet Neurol* 2014;13:1177-85.
- Thomas RH. Hypercoagulability syndromes. *Arch Intern Med* 2001;161:2433-9.
- Kim SJ, Park JH, Lee MJ, Park YG, Ahn MJ, Bang OY. Clues to occult cancer in patients with ischemic stroke. *PLoS One* 2012;7:e44959.
- Gon Y, Sakaguchi M, Takasugi J, Kawano T, Kanki H, Watanabe A, et al. Plasma D-dimer levels and ischaemic lesions in multiple vascular

- regions can predict occult cancer in patients with cryptogenic stroke. *Eur J Neurol* 2017;24:503-8.
19. Nam KW, Kim CK, Kim TJ, An SJ, Oh K, Mo H, et al. Predictors of 30-day mortality and the risk of recurrent systemic thromboembolism in cancer patients suffering acute ischemic stroke. *PLoS One* 2017;12:e0172793.
 20. Nam KW, Kim CK, Kim TJ, An SJ, Demchuk AM, Kim Y, et al. D-dimer as a predictor of early neurologic deterioration in cryptogenic stroke with active cancer. *Eur J Neurol* 2017;24:205-11.
 21. Navi BB, Singer S, Merkler AE, Cheng NT, Stone JB, Kamel H, et al. Recurrent thromboembolic events after ischemic stroke in patients with cancer. *Neurology* 2014;83:26-33.
 22. Varki A. Trousseau's syndrome: Multiple definitions and multiple mechanisms. *Blood* 2007;110:1723-9.
 23. Lee MJ, Chung JW, Ahn MJ, Kim S, Seok JM, Jang HM, et al. Hypercoagulability and mortality of patients with stroke and active cancer: The OASIS-CANCER study. *J Stroke* 2017;19:77-87.
 24. Ambrus DB, Reisman JJ, Rose AJ. The impact of new-onset cancer among veterans who are receiving warfarin for atrial fibrillation and venous thromboembolism. *Thromb Res* 2016;144:21-6.
 25. Lyman GH, Bohlke K, Khorana AA, Kuderer NM, Lee AY, Arcelus JJ, et al. Venous thromboembolism prophylaxis and treatment in patients with cancer: American society of clinical oncology clinical practice guideline update 2014. *J Clin Oncol* 2015;33:654-6.
 26. Lee AY, Peterson EA. Treatment of cancer-associated thrombosis. *Blood* 2013;122:2310-7.
 27. Khorana AA, McCrae KR, Milentijevic D, Fortier J, Nelson WW, Laliberté F, et al. Current practice patterns and patient persistence with anticoagulant treatments for cancer-associated thrombosis. *Res Pract Thromb Haemost* 2017;1:14-22.
 28. Raskob GE, van Es N, Verhamme P, Carrier M, Di Nisio M, Garcia D, et al. Edoxaban for the treatment of cancer-associated venous thromboembolism. *N Engl J Med* 2018;378:615-24.
 29. O'Neal WT, Sandesara PB, Claxton JS, MacLehose RF, Chen LY, Bengtson LG, et al. Provider specialty, anticoagulation prescription patterns, and stroke risk in atrial fibrillation. *J Am Heart Assoc* 2018;7. pii: e007943.
 30. Jang H, Lee JJ, Lee MJ, Ryoo S, Yoon CH, Kim GM, et al. Comparison of enoxaparin and warfarin for secondary prevention of cancer-associated stroke. *J Oncol* 2015;2015:502089.
 31. Nam KW, Kim CK, Kim TJ, An SJ, Oh K, Ko SB, et al. Treatment of cryptogenic stroke with active cancer with a new oral anticoagulant. *J Stroke Cerebrovasc Dis* 2017;26:2976-80.
 32. Laube ES, Yu A, Gupta D, Miao Y, Samedy P, Wills J, et al. Rivaroxaban for stroke prevention in patients with nonvalvular atrial fibrillation and active cancer. *Am J Cardiol* 2017;120:213-7.
 33. Shah S, Norby FL, Datta YH, Lutsey PL, MacLehose RF, Chen LY, et al. Comparative effectiveness of direct oral anticoagulants and warfarin in patients with cancer and atrial fibrillation. *Blood Adv* 2018;2:200-9.
 34. Fanola CL, Ruff CT, Murphy SA, Jin J, Duggal A, Babilonia NA, et al. Efficacy and safety of edoxaban in patients with active malignancy and atrial fibrillation: Analysis of the ENGAGE AF – TIMI 48 trial. *J Am Heart Assoc* 2018;7:e008987.
 35. Holbrook AM, Pereira JA, Labiris R, McDonald H, Douketis JD, Crowther M, et al. Systematic overview of warfarin and its drug and food interactions. *Arch Intern Med* 2005;165:1095-106.
 36. Prandoni P, Lensing AW, Piccioli A, Bernardi E, Simioni P, Girolami B, et al. Recurrent venous thromboembolism and bleeding complications during anticoagulant treatment in patients with cancer and venous thrombosis. *Blood* 2002;100:3484-8.
 37. Seok JM, Kim SG, Kim JW, Chung CS, Kim GM, Lee KH, et al. Coagulopathy and embolic signal in cancer patients with ischemic stroke. *Ann Neurol* 2010;68:213-9.
 38. Streiff MB, Holmstrom B, Ashrani A, Bockenstedt PL, Chesney C, Eby C, et al. Cancer-associated venous thromboembolic disease, version 1.2015. *J Natl Compr Canc Netw* 2015;13:1079-95.
 39. Kearon C, Akl EA, Comerota AJ, Prandoni P, Bounameaux H, Goldhaber SZ, et al. Antithrombotic therapy for VTE disease: Antithrombotic therapy and prevention of thrombosis, 9th ed: American College of Chest Physicians Evidence-Based Clinical Practice Guidelines. *Chest* 2012;141:e419S-96S.
 40. Melnikova I. The anticoagulants market. *Nat Rev Drug Discov* 2009;8:353-4.
 41. Patel MR, Mahaffey KW, Garg J, Pan G, Singer DE, Hacke W, et al. Rivaroxaban versus warfarin in nonvalvular atrial fibrillation. *N Engl J Med* 2011;365:883-91.
 42. Short NJ, Connors JM. New oral anticoagulants and the cancer patient. *Oncologist* 2014;19:82-93.
 43. Tornkvist M, Smith JG, Labaf A. Current evidence of oral anticoagulant reversal: A systematic review. *Thromb Res* 2018;162:22-31.