



Since January 2020 Elsevier has created a COVID-19 resource centre with free information in English and Mandarin on the novel coronavirus COVID-19. The COVID-19 resource centre is hosted on Elsevier Connect, the company's public news and information website.

Elsevier hereby grants permission to make all its COVID-19-related research that is available on the COVID-19 resource centre - including this research content - immediately available in PubMed Central and other publicly funded repositories, such as the WHO COVID database with rights for unrestricted research re-use and analyses in any form or by any means with acknowledgement of the original source. These permissions are granted for free by Elsevier for as long as the COVID-19 resource centre remains active.



Review

SIRVA (Shoulder Injury Related to Vaccine Administration) following mRNA COVID-19 Vaccination: Case discussion and literature review



Wen Loong Paul Yuen*, Sir Young James Loh, Dehao Bryan Wang

Department of Orthopaedic Surgery, Changi General Hospital, 2 Simei Street 3, Singapore 5298892, Singapore

ARTICLE INFO

Article history:

Received 17 June 2021
 Received in revised form 6 March 2022
 Accepted 16 March 2022
 Available online 21 March 2022

Keywords:

SIRVA
 COVID-19 vaccination
 mRNA vaccine

ABSTRACT

Shoulder injury related to vaccine administration (SIRVA) is an increasingly recognised complication after vaccination and presents with significant shoulder pain and stiffness. SIRVA is thought to occur as a result of improper administration of vaccine into the subdeltoid bursa or shoulder joint. This results in an inflammatory cascade that damages the structures in the shoulder region. The incidence of SIRVA is relatively higher for influenza vaccination due its widespread administration. We present a reported case of SIRVA following a mRNA COVID-19 vaccination and review the current literature. As we embark on a worldwide scale of COVID-19 vaccination, it is of utmost important that we use proper vaccination techniques and screen patients at risk of SIRVA. This would improve the efficacy of the vaccine and improve the outcomes of the vaccination programme.

© 2022 Elsevier Ltd. All rights reserved.

Contents

1. Introduction	2546
2. Case discussion	2547
3. Discussion	2547
3.1. Mechanism of injury	2547
3.2. Vaccination technique	2547
3.3. SIRVA treatment	2549
3.4. Recommendations	2549
4. Conclusion	2549
5. Declaration of patient consent	2549
Declaration of Competing Interest	2550
References	2550

1. Introduction

Vaccination against the Severe Acute Respiratory Syndrome Coronavirus 2 (SARS – CoV-2) are being carried out on a worldwide scale and it is critical to monitor their safety profile and complications.

Localized soreness and pain following intramuscular vaccinations to the shoulder are common, typically mild and self-limiting. [1] Shoulder injury related to vaccine administration (SIRVA), is a more severe and rare complication, and results in

onset of shoulder pain and limited range of motion that persists after the vaccination. [2,3] It is thought to occur due to inadvertent administration of vaccine into the shoulder joint or subdeltoid bursa, leading to an inflammatory cascade damaging the surrounding structures including bursa, tendons and ligaments. [4] SIRVA encompasses conditions including adhesive capsulitis, subacromial bursitis, rotator cuff tendonitis or tears, and subcortical bone osteitis. [4] It has been reported more with influenza vaccinations due to its widespread usage and has also been observed after vaccinations for tetanus, pneumococcus and papillomavirus [4,5]. The first case of SIRVA following COVID-19 vaccination was reported by Tatiane et. al in April 2021, in which the patient was reported to suffer from subdeltoid bursitis and rotator cuff tendinopathy fol-

* Corresponding author.

E-mail address: paul_yuen@cgh.com.sg (W.L.P. Yuen).

lowing the vaccination. [6] The exact incidence of SIRVA is unknown, but is increasingly diagnosed in recent times. Based on the American federal Vaccine Injury Compensation Program statistics, it is the number one complication which patients seek compensation from the no-fault Vaccine Injury Compensation Program. [7].

The risk factors for SIRVA include female gender, thin habitus, small deltoid muscle bulk and improper injection techniques. [4] It is important to identify patients at higher risk of SIRVA, and perform relevant risk counselling and closer monitoring post-vaccination.

Injection technique is a modifiable risk. The risk of SIRVA can be mitigated by adopting measures such as adequate exposure, optimal patient positioning, accurate landmarking and usage of needles of appropriate lengths.

We report a unique case of a patient who developed massive shoulder effusion and synovitis following mRNA COVID-19 vaccination and review the current literature on the prevention and management of SIRVA.

2. Case discussion

The patient was an 84-year-old female of Southeast-Asian ethnicity, with a history of hypertension and hyperlipidaemia. She was 119 cm tall, weighed 47 kg and with BMI of 33.2. Three days after receiving her first dose of COVID-10 mRNA vaccination into her left deltoid region, she experienced severe shoulder pain and stiffness. She previously had mild shoulder pains which were mild and self-limiting. Clinical examination showed severe tenderness at the left shoulder with moderately-sized effusion and limited active range of motion. Her neurovascular examination of her left arm was normal.

Biochemical evaluation was unremarkable, with white cell count of $10.0 \times 10^3/\mu\text{L}$ and CRP of $<0.6 \text{ mg/L}$. X-rays showed soft tissue swellings over the deltoid region with no other significant findings. (Fig. 1) A magnetic resonance imaging (MRI) scan of her shoulder one week after the vaccination showed chronic near-complete rotator cuff tears of the supraspinatus and infraspinatus with muscle atrophy. (Fig. 2) There was significant synovitis and massive joint effusion communicating with the subacromial and subdeltoid bursa, extending into the subcoracoid recess and dissection into the musculotendinous junction of the rotator cuff. The degree of effusion and synovitis was disproportionate to the above chronic findings and represented a reactive inflammatory response to the vaccine.

The patient was treated conservatively with analgesia and physiotherapy focusing on progressive range of motion exercises. She was reviewed at 6-weeks and 3-month post injury and demonstrated good recovery. Clinical examination of her shoulder showed resolution of effusion, and improved range of motion. Patient felt that her pain had completely resolved and that her shoulder function was back to her baseline levels. She was able to return to independent daily functions. (Fig. 3) Interval radiograph taken at 3-month interval also showed resolution of soft tissue swelling. (Fig. 1b).

3. Discussion

With the advent of large scale COVID-19 vaccination programs, we foresee a rise in complications following vaccine administration. Fear and perceptions of vaccine complications and their safety profile can lead to barriers for patients to receive their vaccinations. It is imperative for safe administration of vaccines and prevent avoidable complications such as SIRVA. SIRVA risk can be reduced with good injection techniques and timely intervention can be done by screening for individuals at risk and close monitoring post vaccination.

3.1. Mechanism of injury

Vaccination for our patient was given likely 'too high' and 'too deep' with resultant entry into the subdeltoid bursa. Her small stature and habitus likely made it difficult to identify the relevant anatomical landmarks for an optimal injection site. As the subdeltoid bursa communicates with the subacromial bursa and in the setting of a pre-existing near complete full-thickness rotator cuff tear, the vaccine entered the glenohumeral joint. This resulted in the severe synovitis and massive effusion of the shoulder. The vaccine administered contained both antigenic (mRNA of glycoprotein S of SARS-CoV-2) and non-antigenic (polyethylene glycol, cholesterol, salts and sucrose) components, both able to incite an inflammatory reaction resulting in the above sequelae.

3.2. Vaccination technique

There is a series of precautionary measures for safe intramuscular deltoid vaccine administration. Table 1 summarises the tips for avoiding SIRVA.

Adequate exposure is required for visualisation of the deltoid injection site and palpation of bony landmarks. The vaccine admin-

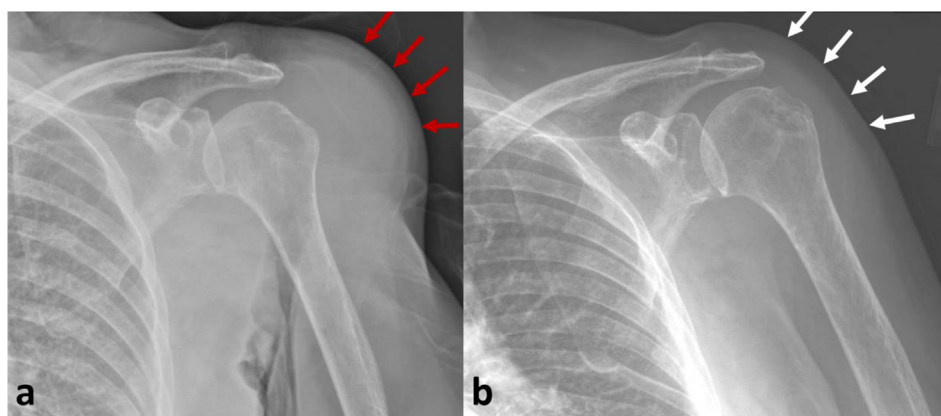


Fig 1. Anteroposterior (AP) plain radiographs of the patient's left shoulder. **1a** shows the initial radiograph taken on first visit, a week after COVID-19 vaccination. It demonstrates significant soft tissue swelling over the deltoid region (annotated with red arrows). **1b** shows the interval radiograph taken three months post injury, showing resolution of soft tissue swelling, corresponding with the recovery from shoulder synovitis and effusion (annotated with white arrows). (For interpretation of the references to colour in this figure legend, the reader is referred to the web version of this article.)

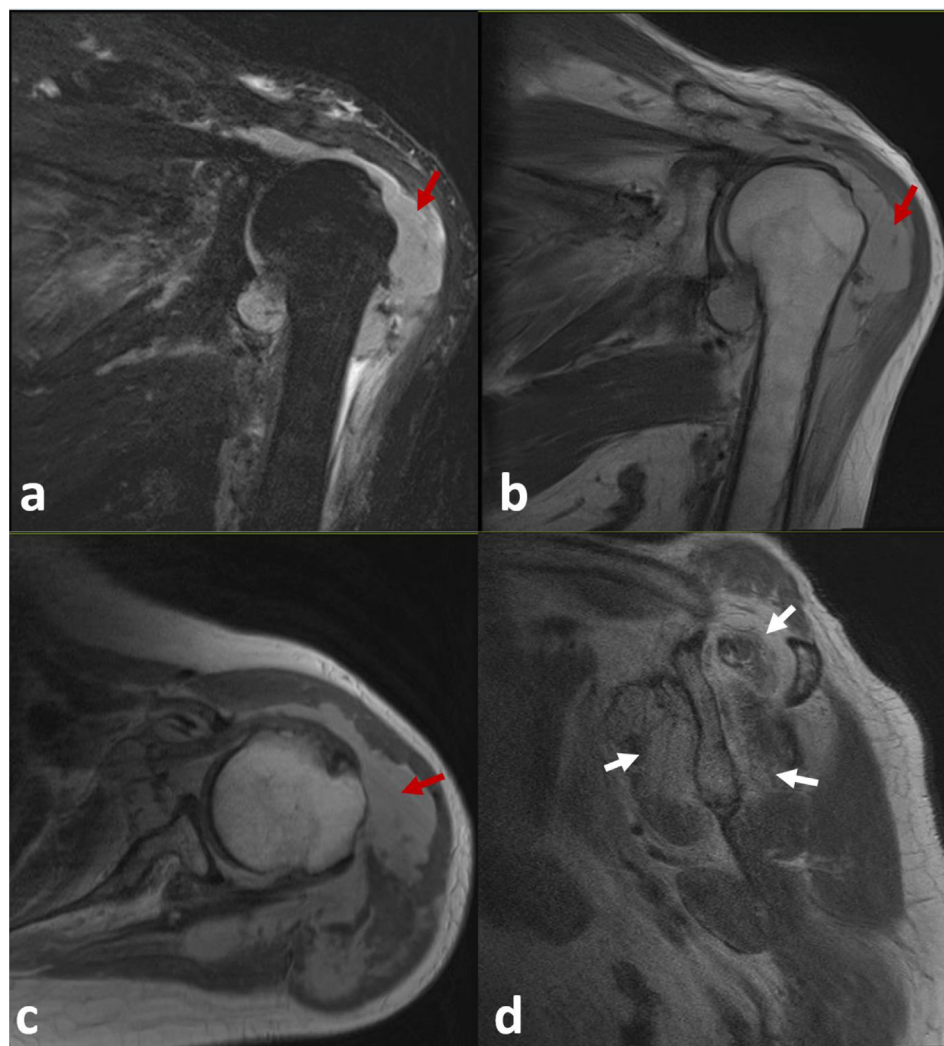


Fig. 2. Magnetic resonance imaging (MRI) of the patient's left shoulder taken one week after vaccination on initial presentation. **2a** (Coronal T2 Dixon sequence), **2b** (Coronal PD BLADE sequence) and **2c** (Axial TSE-PD sequence) shows the massive shoulder joint effusion (annotated with red arrows) with synovitis, communicating with the subdeltoid and subacromial bursa. **2d** (Sagittal TSE-PD sequence) shows the chronic rotator cuff tears of the supraspinatus, infraspinatus and subscapularis (annotated in white arrows) with muscle atrophy.

istrator needs to take the same position as the vaccine recipient to perform an accurate and safe injection.

Surface landmarking is essential for safe vaccine administration. There are a number of methods for identifying the injection site. One commonly used method measures the distance below the lateral border of the acromion in centimetres or by fingerbreadth, but there is no consensus on the exact safe distance. [9] Another technique involves using the acromion as the base of a triangle against the apex on the deltoid determined by a lateral line drawn from the anterior axilla fold. The injection site is in the midpoint of the triangle. [9] Ultrasound studies of healthy volunteers had shown that the subacromial bursa extends distal to the lateral border of the acromion by 3–6 cm. [4 10] Placing any vaccinations at the proximal third of the deltoid muscle carries an risk of penetration into the subacromial space and should be avoided. [3,10] Studies by Cook suggest that patients should be positioned with abduction of the vaccination arm at 60 degrees and placing the hand on the ipsilateral hip. The deltoid muscle is targeted at the midpoint between the acromion and the deltoid tuberosity. This avoids the subacromial and subdeltoid bursa and moves the axillary nerve away. [9 11] The placement of the hand on the ipsilateral hip relaxes the deltoid muscle. This reduces the pain from

the injection and facilitates recognition of the deltoid tuberosity in larger sized patients. [9] Nakajima et al. proposed an alternate injection site [12] which is at the intersection point between a perpendicular line drawn from the mid-acromion lateral border and the anteroposterior axillary line. They suggested that this location best avoids the axillary nerve, anterior circumflex humeral artery, subacromial and subdeltoid bursae. Using Nakajima's method generally results in a lower injection point than Cook's method, with average distances of 10.5–13.8 cm for males and 8.5–11.0 cm for females, compared to 6.8–8.5 cm for males and 5.5–7.3 cm for females from the lateral acromion border.

The length of the syringe needle is determined according to the body habitus and weight of the patient [2]. A long needle can result in penetration into the subdeltoid bursa or impact the humeral head. A short needle might result in cutaneous reactions such as subcutaneous nodules, sterile abscesses, lipoatrophy and subcutaneous emphysema. [13] Bansci et al. recommends usage of 16 mm needles for patients weighing less than 60 kg, 25 mm needles for patients between 60 kg and 90 kg for females, and 60–118 kg for males. Beyond these weight-groups, a 38 mm needle is recommended. [2,13] Based on Bansci's recommendation, a 16 mm needle should have been used for our patient who weighed 47 kg. MRI



Fig. 3. Clinical photo of patient done at three months review showing patient back to her baseline left shoulder functions. She was able to flexed actively up to 60 degrees and was able to reach the back of her head.

scan of her left shoulder also collaborated with this recommendation, showing combined thickness of her subcutaneous tissue and deltoid bulk between 16.5 mm and 20.0 mm taken at levels 5–8 cm from the lateral acromion border. Nakajima et al. suggested

that needle selection can be optimized by measuring subcutaneous thickness via pinching the skin, usage of callipers, and using needle depth 5 mm greater than the measured thickness. [12] The needle needs to be introduced at a 90-degree angle [13]. This enables an accurate assessment of the depth of penetration of the needle.

3.3. SIRVA treatment

There is no consensus regarding the gold standard of treatment for SIRVA. Current management strategies include conservative approaches with physiotherapy, analgesia and intra-articular corticosteroid injections, with surgical procedures reserved for refractory cases. [4] Hexter et al. suggested surgery when patients fail to respond to conservative measures. They reported a case of glenohumeral joint synovitis secondary to influenza vaccination treated successfully by arthroscopic surgery. [14] A systemic review by Gail et al suggested that the majority of patients demonstrated good recovery, with studies showing resolution of symptoms taking from weeks up to 6 months. However, some patients have residual pain and limited range of motion for years. [4] Our patient responded well to conservative treatment with anti-inflammatory and physiotherapy and did not require surgical intervention.

3.4. Recommendations

The deltoid is the commonest site for vaccination in adults. Adequate training and education of vaccine administrators are required to mitigate modifiable risk factors for vaccination complications, such as injection technique. Vaccinators should have working knowledge of the shoulder anatomy and the relevant skillsets for effective vaccine injection. A pre-existing shoulder pathology is a risk factor for SIRVA and screening is needed to identify as well as perform appropriate counselling for such patients. Timely intervention can be performed when required with appropriate monitoring of such patients.

4. Conclusion

SIRVA is a possible complication from a COVID-19 vaccination. Injection technique is a modifiable risk factor that is potentially mitigated with appropriate and relevant training of the healthcare providers. Screening of patients at risk of SIRVA helps with risk counselling, post-vaccination monitoring and timely interventions. With COVID-19 vaccination programs happening on a worldwide scale, this emphasis is of paramount importance to optimize vaccine efficacy, provide risk control and ensure success of the vaccination programme.

5. Declaration of patient consent

The authors certify that they have obtained all appropriate patient consent forms. In the form the patient has given his/her consent for his/her images and other clinical information to be

Table 1
Tips for avoiding SIRVA.

Both patient and vaccinator should be seated at the same level
Vaccinated arm should be completely exposed for proper visualization and palpation of anatomical landmarks
Vaccinated shoulder side should be placed in a 60 degrees abducted position with hand placed on ipsilateral hip
Pre procedural landmarking of the lateral acromion border, deltoid tuberosity, and the midpoint of the deltoid muscle between these two mentioned landmarks
Needle selection based on body habitus and weight of patient
Insertion of needle at 90-degree angle
Post procedural monitoring including return advice
Early recognition of SIRVA and administration of appropriate treatment

reported in the journal. The patient understands that his/her name and initials will not be published and due efforts will be made to conceal their identity, but anonymity cannot be guaranteed.

Declaration of Competing Interest

The authors declare that they have no known competing financial interests or personal relationships that could have appeared to influence the work reported in this paper.

References

- [1] Szari S, Belgard A, Adams K, Freiler J. Shoulder injury related to vaccine administration: a rare reaction. *Fed Pract* 2019;36(8):380–4 [Online]. Available: <http://www.ncbi.nlm.nih.gov/pubmed/31456630><http://www.pubmedcentral.nih.gov/articlerender.fcgi?artid=PMC6707642>.
- [2] Bancsi A, Houle SKD, Grindrod KA. Shoulder injury related to vaccine administration and other injection site events. *Can Fam Physician* 2019;65(1):40–2.
- [3] Atanasoff S, Ryan T, Lightfoot R, Johann-Liang R. Shoulder injury related to vaccine administration (SIRVA). *Vaccine* 2010;28(51):8049–52. <https://doi.org/10.1016/j.vaccine.2010.10.005>.
- [4] Cross GB, Moghaddas J, Buttery J, Ayoub S, Korman TM. Don't aim too high: Avoiding shoulder injury related to vaccine administration. *Aust Fam Physician* 2016;45(5):303–6.
- [5] Martín Arias LH, Sanz Fadrique R, Sáinz Gil M, Salgueiro-Vazquez ME. Risk of bursitis and other injuries and dysfunctions of the shoulder following vaccinations. *Vaccine* 2017;35(37):4870–6. <https://doi.org/10.1016/j.vaccine.2017.07.055>.
- [6] Cantarelli Rodrigues T, Hidalgo PF, Skaf AY, Serfaty A. Subacromial-subdeltoid bursitis following COVID-19 vaccination: a case of shoulder injury related to vaccine administration (SIRVA). *Skeletal Radiol* 2021;50(11):2293–7.
- [7] Natanzi N, Hebroni F, Bodor M. Teres minor injury related to vaccine administration. *Radiol Case Reports* 2020;15(5):552–5. <https://doi.org/10.1016/j.radcr.2020.02.009>.
- [9] Cook IF. An evidence based protocol for the prevention of upper arm injury related to vaccine administration (UAIRVA). *Human Vaccines* 2011;7(8):845–8.
- [10] Bodor M, Montalvo E. Vaccination-related shoulder dysfunction. *Vaccine* 2007;25(4):585–7. <https://doi.org/10.1016/j.vaccine.2006.08.034>.
- [11] Cook IF. Subdeltoid/subacromial bursitis associated with influenza vaccination. *Hum Vaccines Immunother* 2014;10(3):605–6. <https://doi.org/10.4161/hv.27232>.
- [12] Nakajima Y, Mukai K, Takaoka K, Hirose T, Morishita K, Yamamoto T, et al. Establishing a new appropriate intramuscular injection site in the deltoid muscle. *Hum Vaccines Immunother* 2017;13(9):2123–9. <https://doi.org/10.1080/21645515.2017.1334747>.
- [13] Cook IF. Best vaccination practice and medically attended injection site events following deltoid intramuscular injection. *Hum Vaccines Immunother* 2015;11(5):1184–91. <https://doi.org/10.1080/21645515.2015.1017694>.
- [14] Hexter AT, Gee E, Sandher D. Management of glenohumeral synovitis secondary to influenza vaccination*. *Shoulder Elb* 2015;7(2):100–3. <https://doi.org/10.1177/1758573214560258>.