


ORIGINAL RESEARCH

Recovery of Absolute Coronary Blood Flow and Microvascular Resistance After Chronic Total Occlusion Percutaneous Coronary Intervention: An Exploratory Study

Daniëlle C. J. Keulards , MD; Grigoris V. Karamasis, MD; Osama Alsanjari, MBBS; Jesse P. A. Demandt, MD; Marcel van't Veer, MSc, PhD; Jo M. Zelis, MD; Simon A. Dello, MD, PhD; Mohamed El Farissi, MD; Klio Konstantinou, MBBS; Kare H. Tang, MD; Paul A. Kelly, MBChB, MD; Thomas R. Keeble, MBBS, MD; Nico H. J. Pijls, MD, PhD; John R. Davies, MBBS, PhD; Koen Teeuwen, MD, PhD

BACKGROUND: This study aimed to investigate longitudinal physiological changes in the recanalized coronary chronic total occlusion (CTO) vessel and its dependent myocardium after successful percutaneous coronary intervention (PCI).

METHODS AND RESULTS: In this pilot study, 25 patients scheduled for elective CTO PCI with viable myocardium and angiographically visible collaterals were included. Absolute coronary blood flow and absolute microvascular resistance were measured invasively using continuous thermodilution. Measurements were performed immediately after successful CTO PCI and at short-term follow-up. In a subgroup of patients, physiological measurements were performed at the predominant donor vessel before CTO PCI, immediately afterwards, and at follow-up. Absolute coronary blood flow in the recanalized CTO artery increased from 148 ± 53 mL/min immediately after PCI to 221 ± 77 mL/min at follow-up ($P<0.001$). In agreement, absolute resistance in the myocardial territory perfused by the CTO artery, decreased from 545 ± 255 Wood units immediately after the procedure to 387 ± 128 Wood units at follow-up ($P=0.014$). There were no significant changes in the absolute coronary blood flow and resistance in the predominant donor between baseline and follow-up. Positive remodeling of the distal CTO vessel with an increase in lumen diameter was observed.

CONCLUSIONS: After successful CTO PCI, blood flow in the recanalized artery and microvascular function of the dependent myocardium are not immediately normal but recover over time.

Key Words: chronic total coronary occlusion ■ coronary flow ■ coronary microvascular function ■ coronary microvascular resistance ■ coronary revascularization

Successful percutaneous coronary intervention (PCI) of chronic total occlusions (CTOs) relieves ischemia, improving patients' symptoms, functional status, and quality of life.¹⁻⁴ It has been recognized that after successful recanalization of a CTO, there is no immediate complete recovery of the distal artery and the dependent myocardial territory, but its function might improve over time.⁵⁻⁷ In most CTOs with viable distal myocardium, collateral blood

supply is present and sufficient to maintain resting metabolism (hibernation) or even contraction at rest. However, evident ischemia occurs with increasing demand during stress/exercise.^{8,9} Due to reduced blood flow and perfusion pressure, negative remodeling of the distal part of the occluded vessel occurs, while microvascular changes become present in the distal myocardium, with an increase in microvascular resistance in the CTO territory. Both phenomena

Correspondence to: Daniëlle C. J. Keulards, MD, Department of Cardiology, Catharina Hospital Eindhoven, Michelangelolaan 2, 5623 EJ Eindhoven, The Netherlands. E-mail: danielle_keulards@hotmail.com

For Sources of Funding and Disclosures, see page 8

© 2020 The Authors. Published on behalf of the American Heart Association, Inc., by Wiley. This is an open access article under the terms of the Creative Commons Attribution-NonCommercial-NoDerivs License, which permits use and distribution in any medium, provided the original work is properly cited, the use is non-commercial and no modifications or adaptations are made.

JAHA is available at: www.ahajournals.org/journal/jaha

CLINICAL PERSPECTIVE

What Is New?

- This study demonstrates that chronic total occlusion physiology in the distal coronary artery and microvasculature does not normalize immediately after successful chronic total occlusion percutaneous coronary intervention but recovers over time.

What Are the Clinical Implications?

- Our findings provide the physiologic basis for justifying percutaneous coronary intervention of a chronic total occlusion artery in case of viable distal myocardium, indicated by either chest pain, a positive stress test, or preserved resting wall motion on the echocardiogram and absence of Q waves at the ECG.

Nonstandard Abbreviations and Acronyms

CTO	chronic total occlusion
FFR	fractional flow reserve
J-CTO	Japanese Chronic Total Occlusion
PCI	percutaneous coronary intervention
Q	flow in mL/min
R	resistance in Wood units
Ti	infusion temperature in °C
WU	Wood Units in mm Hg/L per min

contribute to incomplete, delayed, and suboptimal recovery of physiology even after technically successful PCI.

A recent study showed that fractional flow reserve (FFR) of both the coronary artery and the myocardium of a recanalized CTO, increased over time, paralleled by regression of collaterals.¹⁰ These observations strongly suggest that recovery of both the distal coronary artery and the dependent myocardium often occurs because an increase in FFR (without additional intervention in the epicardial artery) implicates a decrease of distal epicardial resistance. Although this study provides indirect evidence of recovery of microvascular function over time along with the positive remodeling of the distal CTO artery, there were no direct measurements of microvascular function or coronary blood flow.

Recently, a novel methodology has become available that allows accurate and quantitative invasive measurements of absolute coronary blood flow and resistance during coronary catheterization.^{11,12}

The aim of the present study was to perform such serial measurements of absolute coronary flow and microvascular resistance in the recanalized CTO and major donor vessels after successful PCI. Based upon the observations of the present study in combination with the previous work by Karamasis et al,¹⁰ we aimed to propose a complete model explaining the physiologic changes after successful CTO PCI.

METHODS

Study Design and Population

This was a prospective observational exploratory study on coronary physiology after CTO percutaneous revascularization. Patients with a clinical indication for elective CTO PCI were recruited in the Catharina Hospital (Eindhoven, The Netherlands) and the Essex Cardiothoracic Centre (Basildon, UK). All patients had stable angina and viability of the myocardial territory supplied by the CTO vessel as evidenced by perfusion cardiac magnetic resonance imaging or preserved wall motion on transthoracic echocardiography at rest. As cardiac magnetic resonance criteria for ischemia and viability, >10% ischemic burden in the CTO territory was the cutoff that we used to justify CTO PCI. Delayed myocardial enhancement was the cardiac magnetic resonance sequence used for viability and >75% with delayed enhancement in the myocardial segment under interrogation was the cutoff for a territory to be considered not viable. In all cases, there were spontaneously visible collateral vessels supplied by a contralateral donor artery. All patients provided written informed consent, and the study was approved by the local ethics committee in Eindhoven (The Netherlands) and Basildon (United Kingdom). The data that support the findings of this study are available from the corresponding author upon reasonable request.

Chronic Total Occlusion PCI

CTO PCI was performed according to contemporary interventional techniques following the hybrid algorithm. Recanalization strategy was left at the discretion of the CTO operator. A procedure was considered successful if thrombolysis in myocardial infarction flow grade 3 with <30% angiographic residual stenosis in the CTO vessel was achieved. Patients were discharged on statins and on dual antiplatelet therapy (aspirin and clopidogrel) for at least 1 year.

Measurement of Absolute Blood Flow and Microvascular Resistance

After successful PCI of the CTO, complete physiological assessment in the recanalized vessel and its dependent myocardium was performed by calculating

absolute coronary blood flow and microvascular resistance using continuous thermodilution. The detailed method was previously published.^{11–15} In brief, after intracoronary administration of nitroglycerin, a guidewire equipped with a pressure and temperature sensor (Pressure Wire X™, Abbott Vascular, St Paul, MN) is equalized at the tip of the guide catheter and positioned in the distal vessel. Thereafter, a multifunctional monorail infusion catheter (RayFlow, Hexacath, Paris, France) is advanced over the wire and placed in the proximal coronary artery. The catheter is connected to an infusion pump and saline infusion at a prespecified flow rate (Q_i , usually 20 mL/min for the left anterior descending and left circumflex artery and 15 or 20 mL/min for the right coronary artery) is started. The distal temperature of the saline/blood mixture is recorded automatically by the guidewire sensor. The saline infusion itself creates a state of maximum hyperemia within seconds^{12,16} and when a steady hyperemic state is achieved the guidewire is pulled back to the tip of the catheter and the temperature of the infused saline (T_i) is measured. Absolute coronary flow during steady state maximum hyperemia (Q in mL/min) is calculated by assessment of the changes in distal coronary temperature compared with the infusion temperature of the saline (T_i) by the equation $Q = 1.08 \frac{T_i}{T_d} \times Q_i$. The microvascular resistance (R in dyn.s.cm⁻⁵, mm Hg/L per min, or Wood units [WU]) is calculated by dividing the distal coronary pressure (P_d) and the calculated blood flow (Q). Therefore, R is independent of the resistance of the epicardial coronary artery, which can be assessed separately by $(P_a - P_d)/Q$. Live wireless recording and analysis of coronary pressure traces and temperature and automated calculation of Q and R is performed using a dedicated software system (Coroventis, Uppsala, Sweden).

Physiological Measurements in the Donor Vessel

In a subgroup of patients ($n=10$) with intermediate coronary disease (30%–70% stenosis) in the donor artery, physiological assessment including calculation of absolute flow and resistance as described above was performed in the predominant donor vessel. The measurements were performed at the onset of the PCI procedure (before attempting the CTO vessel) and immediately after successful PCI of the CTO vessel.

Follow-Up Procedure

Patients with complete physiology measurements in the recanalized vessel returned for a follow-up procedure within 2 months (7–70 days, mean 46 days) according to institutional practice. During the follow-up

procedure, absolute flow and resistance were measured once more in the recanalized CTO vessel following exactly the same method. In cases where measurements were performed in the predominant donor artery during the baseline procedure, these were also repeated. To evaluate recovery of coronary flow and microvasculature function of the CTO artery, we compared the measurements from the index procedure with those at follow-up. Figure 1 illustrates such complete sequence of angiographic and physiologic assessment in 1 patient.

Quantitative Angiographic Assessment of the Distal CTO Artery

Collateral circulation to the chronically occluded vessel was graded using collateral connections grading method and the predominant donor vessel was determined. Procedure complexity was graded using the Japanese Multicenter CTO Registry score. After blinding for clinical and procedural data, mean and minimal lumen diameter of the distal coronary artery were assessed by quantitative coronary angiography after the baseline procedure and at follow-up. Quantitative coronary analysis was performed using Philips Intellispace Cardiovascular Software System (Amsterdam, The Netherlands).

Statistical Analysis

Data were checked for normality of distribution using Kolmogorov–Smirnov testing. Categorical variables are presented as counts and percentages. Continuous variables are presented as mean±SD or median and interquartile range as appropriate. Comparisons of the relative change in absolute blood flow or resistance were made using a paired t-test. Spearman correlation coefficients were used to assess the relationship between 2 variables as appropriate. ANOVA repeated measures test was performed to assess the difference between 3 following measurements in the donor artery. A 2-tailed level of significance of 0.05 was used. All preceding analyses were performed using SPSS 25 software (SPSS Inc, Chicago, IL).

RESULTS

Twenty-five patients with successful CTO PCI and complete physiology measurements in the recanalized vessel at baseline and follow-up were included. Baseline and procedural characteristics are listed in Table 1. The mean age was 66±8.7 years, and 19 of 25 patients were male. The most common CTO vessel was the right coronary artery and the mean Japanese–Chronic Total Occlusion score was 1.64±1.25. Antegrade wire escalation was the

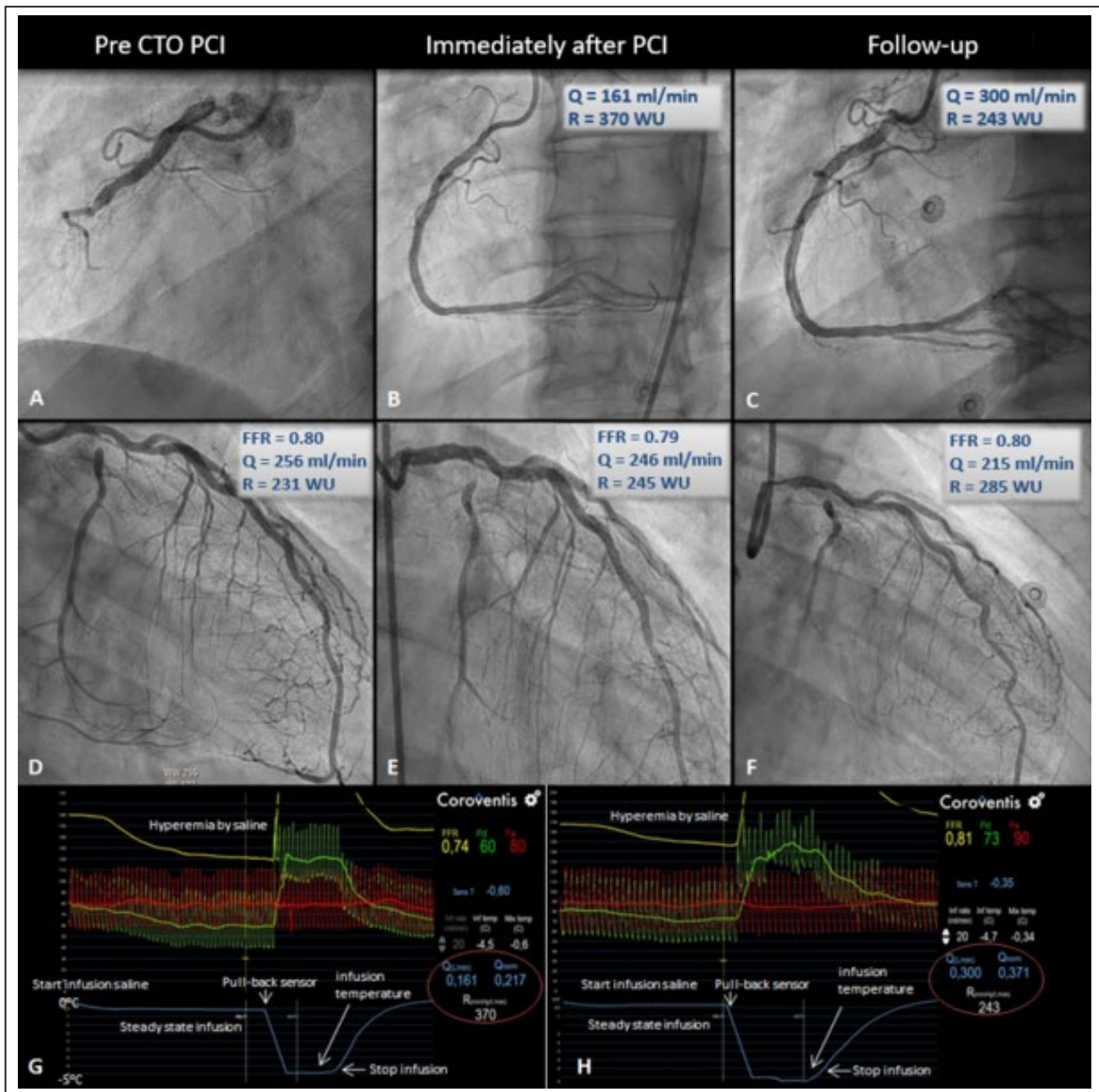


Figure 1. Typical case example.

Complete assessment of 1 patient at baseline and at follow-up. **A** and **D**, The CTO artery (right coronary artery) and the donor artery (left anterior descending) before PCI. The absolute flow in the donor vessel is 256 mL/min, with a resistance of 231WU. **B**, **E**, and **G**, Flow and resistance measured directly after PCI. **C**, **F** and **H**, At follow-up the CTO vessel showed an increase in flow from 161 mL/min to 300 mL/min, and resistance of the dependent myocardium decreased from 370 to 243 WU. Flow in the donor artery decreased further. CTO indicates chronic total occlusion; FFR, fractional flow reserve; PCI, percutaneous coronary intervention; Q, absolute coronary flow during steady state maximum hyperemia; R, microvascular resistance; and WU, Wood units. Reprinted from Keulards et al¹⁷ with permission. Copyright ©2018, Europa Group.

most commonly successful recanalization technique (56%), followed by retrograde dissection/reentry (20%) (Table 2). The follow-up procedure was performed within 2 months (7–70 days, mean 46 days). A subgroup of 10 patients had physiology measurements of the predominant donor vessel at baseline and follow-up.

No major side effects of the absolute flow/resistance measurement method were noted. Two patients showed rapidly transient atrioventricular block with a saline infusion rate of 20 mL/min in the right coronary artery. The atrioventricular block resolved immediately after the infusion was stopped. After adjustment of

Table 1. Baseline Characteristics

Number of Patients (n=25)	N (%) or Mean±SD
Male sex, N (%)	19 (76)
Age, mean (SD)	65.9±8.7
Medical history	
Hypertension, n (%)	20 (80)
Current smoking, n (%)	4 (16)
Diabetes mellitus, n (%)	7 (28)
Dyslipidemia, n (%)	19 (76)
Previous myocardial infarction, n (%)	12 (48)
Clinical details	
CCS angina class	
I	7 (28)
II	8 (32)
III	8 (32)
VI	2 (8)
Left ventricular ejection fraction	
<35%	0 (0)
35%-50%	10 (40)
>50%	15 (60)
Angiographic details	
Occluded target vessel	
Right coronary artery	20 (80)
Left anterior descending artery	3 (12)
Left circumflex artery	2 (8)
Predominant donor vessel	
Right coronary artery	5 (20)
Left anterior descending artery	17 (68)
Left circumflex artery	3 (12)
Collateral filling	
Bridge collaterals	3 (12)
Retrograde filling	18 (72)
Both	4 (16)
Collateral size	
CC0	2 (8)
CC1	17 (68)
CC2	6 (24)
J-CTO score	
Tapered/blunt	5/10 (20/40)
Calcification present	15 (60)
Bending >45 degrees	5 (20)
Length >20 mm	11 (44)
Retry lesion	2 (8)
Total J-CTO-score	
J-CTO 0	7 (28)
J-CTO 1	3 (12)
J-CTO 2	8 (32)
J-CTO 3	7 (28)
Total J-CTO score (mean, SD)	1.64±1.25

Summary values represent number (%) or mean±SD. CC indicates continuous connection; CCS, Canadian Cardiovascular Society; and J-CTO score, Japanese-Chronic Total Occlusion score.

Table 2. Procedural Characteristics

Number of Patients (n=25)	N (%) or Mean±SD
Technique	
Antegrade wire escalation	14 (56)
Retrograde wire escalation	4 (16)
Antegrade dissection and reentry	2 (8)
Retrograde dissection and reentry	5 (20)
Stent length	72.2±26
Other	
Procedure time, min	136.3±78.1
Fluoroscopy time, min	39.2±26.3
Wire crossing time, min	53.4
Radiation dose area product, mGy	200 464±155 497

Summary values represent mean±standard deviation. mGy indicates milligray.

the infusion pump to a lower infusion rate (ie, less decrease of distal temperature), the measurements were completed without difficulty.

Absolute Coronary Blood Flow and Resistance Measurement

There was a significant increase in absolute blood flow in the CTO vessel over time in the overall cohort (Figure 2A). Flow in the recanalized CTO artery increased by 49% from 148±53 mL/min immediately after opening to 221±77 mL/min at follow-up ($P<0.001$). Absolute flow increased in 23 of the 25 cases. In agreement, absolute resistance in the myocardial territory perfused by the CTO artery, decreased by 29% from 545±255 WU immediately after the procedure to 387±128 WU at follow up ($P=0.014$) (Figure 2B). There were no significant changes in the absolute coronary blood flow and resistance in the predominant donor between baseline and follow-up. Absolute blood flow changed from 162 mL/min before PCI to 175 mL/min immediately after PCI and to 189 mL/min at follow-up ($P=0.40$). Microvascular resistance was 473 WU before PCI, 542 WU immediately after PCI and 474 WU at follow-up ($P=0.44$; Figure 3). In these 10 patients in whom donor vessel measurements were available, a net gain in summed absolute blood flow to the CTO and donor vessel myocardial territory of 118 mL/min was observed.

Assessment of Vessel Diameter Changes

All patients had complete follow-up quantitative coronary analysis measurements. The distal CTO vessel lumen dimensions changed significantly from immediately after PCI to follow-up. The minimal lumen diameter increased from 1.17±0.39 mm to 1.42±0.45

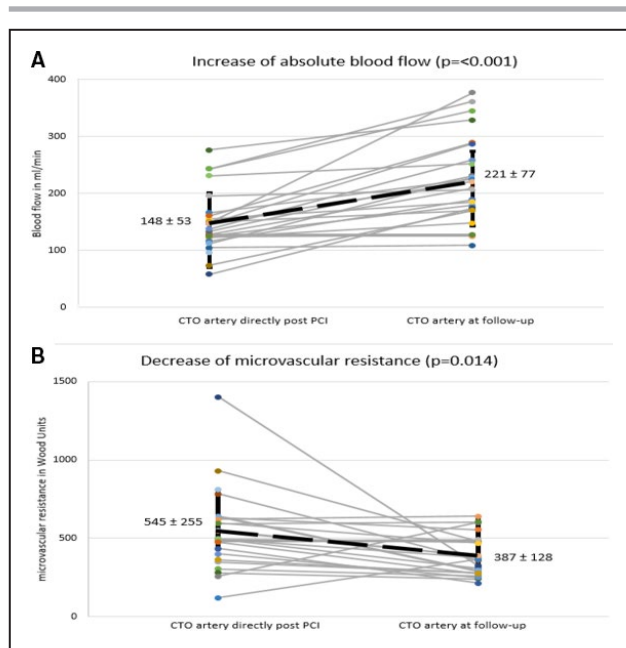


Figure 2. Increase of flow and decrease of microvascular resistance over time in the CTO vessel.

Overview of all performed measurements in the CTO vessel. **A**, Absolute blood flow measured in the CTO vessel directly after PCI and at follow-up. **B**, Microvascular resistance measured in the CTO vessel directly after PCI and at follow-up. CTO indicates chronic total occlusion; and PCI, percutaneous coronary intervention.

($P < 0.001$). The mean lumen diameter increased from 1.73 mm to 1.99 ($P < 0.05$; Table 3). In parallel, epicardial resistance of the CTO artery calculated as $(Pa-Pd)/Q$, decreased by 17% from 82 ± 55 WU to 68 ± 49 WU ($P = 0.155$; Table 3).

DISCUSSION

The present study is the first to perform sequential invasive measurements of absolute hyperemic coronary blood flow and microvascular resistance immediately after successful CTO PCI and at short-term follow-up. The study showed that coronary blood flow and microcirculatory function of the dependent myocardium of a recanalized CTO, are still far from normal immediately after technically successful PCI and significantly improve over time. At the same time, significant luminal increase of the distal CTO vessel was observed. In a subgroup of patients where absolute blood flow and resistance were assessed at the predominant donor vessel, there was no change among measurements before CTO PCI, immediately afterward, and at short-term follow-up.

Novel techniques, advanced equipment, and increasing operators' experience in contemporary CTO PCI have resulted in high procedural success and low

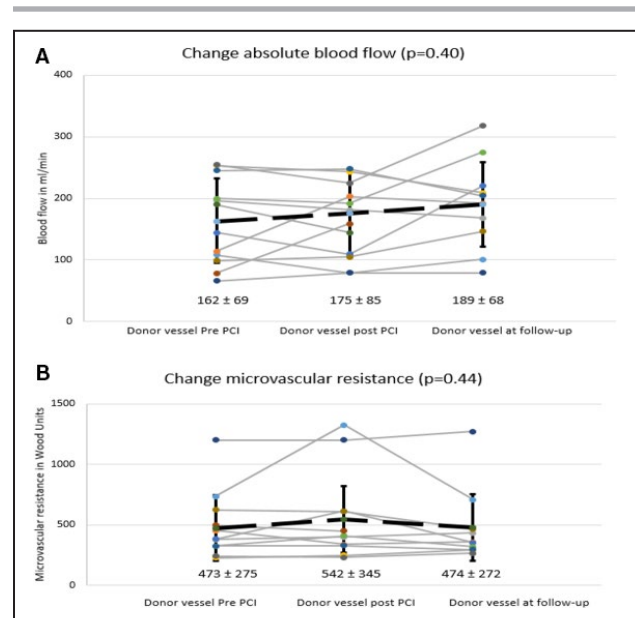


Figure 3. Flow and resistance over time in the donor artery. Overview of all performed measurements in the donor vessel. **A**, Absolute blood flow measured in the donor vessel before PCI, directly after PCI, and at follow-up. **B**, Microvascular resistance measured in the donor vessel before PCI, directly after PCI and at follow-up. PCI indicates percutaneous coronary intervention.

complications rates.^{18,19} However, target lesion failure remains higher compared with non-CTO angioplasty. Better understanding of physiological changes in the recanalized epicardial artery and the dependent myocardium could potentially provide useful insight in optimization of the procedure and improving long-term clinical outcomes.

Our study showed a significant increase in hyperemic coronary blood flow and improvement in microvascular function a few weeks after the procedure: Maximum blood flow increased by 49% and microvascular resistance decreased by 29% at follow-up compared with post-PCI. There was an accompanying increase in distal vessel diameter and a decrease of the epicardial resistance of the CTO artery by 17%. It appears that the increase of coronary flow is explained by 2 factors: decrease in microvascular resistance and distal vessel remodeling reflected by decrease of distal epicardial resistance. The increase in blood flow exceeds the decrease of microvascular resistance as the increase in flow results from both a lower epicardial and lower microvascular resistance.

Notably, almost all patients showed the phenomena described above, but in a few patients (generally mildly) increased resistance or decreased absolute flow at follow-up was observed despite normal cardiac magnetic resonance. Of the 5 patients with increased resistance at follow-up, 4 patients had diabetes mellitus. Werner et al⁵ also reported less or delayed recovery in such patients, but these numbers are too small to justify

Table 3. QCA and Physiologic Parameters of the Distal CTO Artery at Baseline and at Follow-Up

Number of Patients (n=25)			
	Baseline Procedure Mean±SD	Follow-Up Procedure mean±SD	P Value
Quantitative coronary analysis			
Segment length, mm	18±6.84	15.78±5.14	0.063
Mean lumen diameter, mm	1.77±0.42	1.99±0.48	0.028
Minimal lumen diameter, mm	1.17±0.39	1.42±0.45	<0.001
Mean lumen gain, mm	0.25±0.49		
Percentage mean lumen gain, %	17.53±30.14		
Minimal lumen gain, mm	0.26±0.40		
Percentage minimal lumen gain, %	30.47±61.63		
Physiologic measurements			
Absolute blood flow CTO vessel, mL/min	148±53	221±77	<0.001
Epicardial resistance, WU	82±55.4	67.9±48.9	0.155
Microvascular resistance, WU	545±255	387±128	<0.05

Summary values represent mean±SD. CTO indicates chronic total occlusion; and WU, Wood units.

conclusions. Further improvement in flow and resistance may happen over time and will be further investigated in the presently ongoing IMPACT-CTO 2 (Impact of Coronary Chronic Total Occlusion Percutaneous Coronary Intervention on Culprit Vessel Physiology) trial (ClinicalTrials.gov Identifier: NCT03830853).

Previous studies have suggested a sort of “vascular wall hibernation” at the distal coronary segments of a recanalized CTO and failed response to endothelium-dependent and -independent stimuli.^{6,7} In these studies, different hyperemic stimuli were applied immediately after successful CTO PCI and vasomotion was assessed; intracoronary administration of nitroglycerin, adenosine, and acetylcholine or incremental atrial pacing failed to provoke the expected vessel dilatation. The one study that included a follow-up assessment suggested transient impairment of vasomotion function.⁶ The increase in hyperemic absolute coronary blood flow demonstrated in our study can be partially explained by the above findings and strongly argues for improved distal coronary artery wall function. As in our study, it has been previously shown that restoration of flow, shear stress, and vasomotor properties lead to increase in distal vessel luminal dimensions mainly via external elastic membrane enlargement and plaque regression.^{20,21} Regarding microvascular function, a previous study by Werner et al⁵ suggested that microvascular dysfunction was frequently observed immediately after recanalization of a CTO and recovered over time in most of the cases. In that study, Doppler-derived coronary flow reserve (CFR) was used to quantify microvascular function. However, coronary flow reserve is determined by both the epicardial and microcirculatory function. Our study remains the first to report sequential invasive measurements of absolute microvascular resistance.

In a recently published study by Karamasis et al,¹⁰ comprehensive FFR and collateral FFR measurements were performed immediately after CTO PCI and at short-term follow-up. The study showed an FFR increase overtime accompanied by significant reduction of collateral function as expressed by collateral FFR. Furthermore, increased distal vessel diameter and “positive remodeling” with a significant increase in distal luminal diameter was observed. Our study adds essential information regarding microvascular resistance to these observations, completing the physiological concept.

In the subgroup of patients in whom physiological measurements were performed in the predominant donor vessel, there was no significant change in the hyperemic coronary blood flow immediately after CTO or at follow-up. Two recent studies assessed changes in the donor artery FFR after CTO PCI and reported a small but statistically significant increase.^{22,23} One of them suggested a concomitant reduction in coronary flow assessed by intracoronary Doppler. This change was explained by the decrease in the myocardial territory supplied by the donor artery after successful recanalization of the CTO vessel. In our study, possibly the small number of patients in whom donor measurements were performed did not allow a similar observation. Regarding microvascular resistance, as expected there were no changes in the remote to CTO myocardium.

LIMITATIONS

Our study has a number of limitations. First, it involved a small number of patients, and the results should be considered hypothesis generating and cannot be used to generalize the findings to a larger complex

population undergoing CTO-PCI. The magnitude of the changes was variable presumably because of the variability in collateral flow, microvascular and coronary artery wall dysfunction, and the amount of viable tissue perfused by the CTO artery. Nevertheless, the observations were consistent among most of the patients. The vast majority of the recanalized CTO vessels involved the right coronary artery. Although this reflects current CTO PCI practice, a more equal CTO vessel distribution would be more representative for the different vascular beds. We did not measure coronary wedge pressure, and therefore we couldn't calculate collateral FFR and provide a quantitative assessment of collateral blood flow enhancing further the interpretation of the observed physiological changes.

Also, the follow-up interval was not regular, which should be recognized. However, no further procedures were performed before physiological measurements, and if staged PCI was indicated, it took place after all study measurements so as not to affect these.

Finally, changes in the distal vessel lumen were assessed by quantitative coronary analysis. Intracoronary imaging would be more informative, as it would allow evaluation of vessel remodeling, plaque modification, and stent deployment features. The ongoing IMPACT-CTO 2 study combines sequential advanced physiological measurements, including absolute blood flow and resistance with optical coherence tomography in an attempt to provide further insight in coronary physiology and anatomy after CTO PCI.

CONCLUSIONS

This study demonstrates that after successful PCI of a chronically occluded coronary artery, physiology of the distal coronary artery and microvasculature does not normalize immediately but improves significantly within a few months. This is reflected by an increase of maximum coronary blood flow of 49%, decrease of microvascular resistance of the myocardium by 29%, and positive remodeling of the distal coronary.

ARTICLE INFORMATION

Received January 8, 2020; accepted March 25, 2020.

Affiliations

From the Catharina Hospital, Eindhoven, The Netherlands (D.C.J.K., J.P.A.D., M.v.V., J.M.Z., S.A.D., M.E.F., N.H.J.P., K.T.); Essex Cardiothoracic Centre, Basildon, United Kingdom (G.V.K., O.A., K.K., K.H.T., P.A.K., T.R.K., J.R.D.); School of Medicine, Anglia Ruskin University, Chelmsford, United Kingdom (G.V.K., O.A., K.K., T.R.K., J.R.D.); Eindhoven University of Technology, Eindhoven, The Netherlands (M.v.V., N.H.J.P.).

Sources of Funding

None.

Disclosures

Dr Karamasis reports honoraria and a research grant from Abbott Vascular. Dr Keeble reports research grants from Boston Scientific, Volcano, Terumo, and Abbott Vascular. Dr Pijls reports institutional grants from Abbott and Hexacath; consulting for Abbott, Opsens, and GE; and minor equities in Philips, ASML, and Heartflow. Dr Davies reports a research grant from Medtronic. The remaining authors have no disclosures to report.

REFERENCES

1. Brilakis ES, Mashayekhi K, Tsuchikane E, Abi Rafeh N, Alaswad K, Araya M, Avran A, Azzalini L, Babunashvili AM, Bayani B, et al. Guiding principles for chronic total occlusion percutaneous coronary intervention. *Circulation*. 2019;140:420–433.
2. Werner GS, Martin-Yuste V, Hildick-Smith D, Boudou N, Sianos G, Gelev V, Rumoroso JR, Erglis A, Christiansen EH, Escaned J, et al. A randomized multicentre trial to compare revascularization with optimal medical therapy for the treatment of chronic total coronary occlusions. *Eur Heart J*. 2018;39:2484–2493.
3. Sapontis J, Salisbury AC, Yeh RW, Cohen DJ, Hirai T, Lombardi W, McCabe JM, Karpaliotis D, Moses J, Nicholson WJ, et al. Early procedural and health status outcomes after chronic total occlusion angioplasty: a report from the OPEN-CTO registry (Outcomes, Patient Health Status, and Efficiency in Chronic Total Occlusion Hybrid Procedures). *JACC Cardiovasc Interv*. 2017;10:1523–1534.
4. Rossello X, Pujadas S, Serra A, Bajo E, Carreras F, Barros A, Cinca J, Pons-Lladó G, Vaquerizo B. Assessment of inducible myocardial ischemia, quality of life, and functional status after successful percutaneous revascularization in patients with chronic total coronary occlusion. *Am J Cardiol*. 2016;117:720–726.
5. Werner GS, Emig U, Bahrmann P, Ferrari M, Figulla HR. Recovery of impaired microvascular function in collateral dependent myocardium after recanalisation of a chronic total coronary occlusion. *Heart*. 2004;90:1303–1309.
6. Galassi AR, Tomasello SD, Crea F, Costanzo L, Campisano MB, Marzá F, Tamburino C. Transient impairment of vasomotion function after successful chronic total occlusion recanalization. *J Am Coll Cardiol*. 2012;59:711–718.
7. Brugaletta S, Martin-Yuste V, Padró T, Alvarez-Contreras L, Gomez-Lara J, Garcia-Garcia HM, Cola C, Liuzzo G, Masotti M, Crea F, et al. Endothelial and smooth muscle cells dysfunction distal to recanalized chronic total coronary occlusions and the relationship with the collateral connection grade. *JACC Cardiovasc Interv*. 2012;5:170–178.
8. Sachdeva R, Agrawal M, Flynn SE, Werner GS, Uretsky BF. The myocardium supplied by a chronic total occlusion is a persistently ischemic zone. *Catheter Cardiovasc Interv*. 2014;83:9–16.
9. Stuijzand WJ, Driessen RS, Rajmakers PG, Rijnierse MT, Maeremans J, Hollander MR, Lammertsma AA, van Rossum AC, Dens J, Nap A, et al. Prevalence of ischaemia in patients with a chronic total occlusion and preserved left ventricular ejection fraction. *Eur Heart J Cardiovasc Imaging*. 2017;18:1025–1033.
10. Karamasis GV, Kalogeropoulos AS, Mohd Nazri SR, Al-Janabi F, Jones R, Jagathesan R, Aggarwal RK, Glesham GJ, Tang KH, Kelly PA, et al. Serial fractional flow reserve measurements post coronary chronic total occlusion percutaneous coronary intervention. *Circ Cardiovasc Interv*. 2018;11:e006941.
11. Xaplanteris P, Fournier S, Keulards DCJ, Adjedj J, Ciccirelli G, Milkas A, Pellicano M, Van't Veer M, Barbato E, Pijls NHJ, et al. Catheter-based measurements of absolute coronary blood flow and microvascular resistance: feasibility, safety, and reproducibility in humans. *Circ Cardiovasc Interv*. 2018;11:e006194.
12. Everaars H, de Waard GA, Schumacher SP, Zimmermann FM, Bom MJ, van de Ven PM, Rajmakers PG, Lammertsma AA, Götte MJ, van Rossum AC, et al. Continuous thermodilution to assess absolute flow and microvascular resistance: validation in humans using [15O]H₂O positron emission tomography. *Eur Heart J*. 2019;40:2350–2359.

13. Aarnoudse W, Van't Veer M, Pijls NHJ, Ter Woort J, Vercauteren S, Tonino P, Geven M, Rutten M, van Hagen E, de Bruyne B, et al. Direct volumetric blood flow measurement in coronary arteries by thermodilution. *J Am Coll Cardiol*. 2007;50:2294–2304.
14. van't Veer M, Adjedj J, Wijnbergen I, Tóth GG, Rutten MCM, Barbato E, van Nunen LX, Pijls NHJ, De Bruyne B. Novel monorail infusion catheter for volumetric coronary blood flow measurement in humans: in vitro validation. *EuroIntervention*. 2016;12:701–707.
15. Keulards DCJ, Van 't Veer M, Zelis JM, El Farissi M, Zimmermann FM, de Vos A, Teeuwen K, Brueren GRG, Wijnbergen IF, Vlaar PJ, et al. Safety of absolute coronary flow and microvascular resistance measurements by thermodilution. *EuroIntervention*. 2020; pii: EIJ-D-20-00074. DOI: 10.4244/EIJ-D-20-00074. [Epub ahead of print]. No abstract available.
16. De Bruyne B, Adjedj J, Xaplanteris P, Ferrara A, Mo Y, Penicka M, Floré V, Pellicano M, Toth G, Barbato E, et al. Saline-induced coronary hyperemia: mechanisms and effects on left ventricular function. *Circ Cardiovasc Interv*. 2017;10:e004719.
17. Keulards DCJ, Zimmermann FM, Pijls NHJ, Teeuwen K. Recovery of absolute coronary flow and resistance one week after percutaneous coronary intervention of a chronic totally occluded coronary artery using the novel RayFlow® infusion catheter. *EuroIntervention*. 2018;14:e588–e589.
18. Konstantinidis NV, Werner GS, Deftereos S, Di Mario C, Galassi AR, Buettner JH, Avran A, Reifart N, Goktekin O, Garbo R, et al. Temporal trends in chronic total occlusion interventions in Europe. *Circ Cardiovasc Interv*. 2018;11:e006229.
19. Tajti P, Karpaliotis D, Alaswad K, Jaffer FA, Yeh RW, Patel M, Mahmud E, Choi JW, Burke MN, Doing AH, et al. The hybrid approach to chronic total occlusion percutaneous coronary intervention: update from the progress CTO registry. *JACC Cardiovasc Interv*. 2018;11:1325–1335.
20. Park JJ, Chae I-H, Cho Y-S, Kim S-W, Yang H-M, Seo J-B, Kim S-Y, Oh I-Y, Yoon C-H, Suh J-W, et al. The recanalization of chronic total occlusion leads to lumen area increase in distal reference segments in selected patients: an intravascular ultrasound study. *JACC Cardiovasc Interv*. 2012;5:827–836.
21. Gomez-Lara J, Teruel L, Homs S, Ferreiro JL, Romaguera R, Roura G, Sánchez-Elvira G, Jara F, Brugaletta S, Gomez-Hospital J-A, et al. Lumen enlargement of the coronary segments located distal to chronic total occlusions successfully treated with drug-eluting stents at follow-up. *EuroIntervention*. 2014;9:1181–1188.
22. Ladwiniec A, Cunningham MS, Rossington J, Mather AN, Alahmar A, Oliver RM, Nijjer SS, Davies JE, Thackray S, Alamgir F, et al. Collateral donor artery physiology and the influence of a chronic total occlusion on fractional flow reserve. *Circ Cardiovasc Interv*. 2015;8:e002219.
23. Mohd nazri SR, Karamasis GV, Al-Janabi F, Cook CM, Hampton-Till J, Zhang J, Al-Lamee R, Dzungu JN, Gedela S, Tang KH, et al. The impact of coronary chronic total occlusion percutaneous coronary intervention upon donor vessel fractional flow reserve and instantaneous wave-free ratio: implications for physiology-guided PCI in patients with CTO. *Catheter Cardiovasc Interv*. 2018;92:E139–E148.