

# Pregnancy complicated with agranulocytosis

Hai Wang, MD, Jiang-Li Sun, MD, Zheng-Liang Zhang, PhD\*, Hong-Hong Pei, PhD\*

## Abstract

**Rationale:** Pregnancy is a complicated physiological process. Physiological leukocytosis often takes place and it is primarily related to the increased circulation of neutrophils, especially during the last trimester of pregnancy. Noncongenital agranulocytosis during pregnancy is rare and reported only occasionally, while in most of the cases, the agranulocytosis has already occurred prior to pregnancy or induced by identified factors such as antibiotics, antithyroid agents, or cytotoxic agents. Gestation-induced agranulocytosis has not been reported, so we present a case of gestation-induced agranulocytosis in this article.

**Patients concern:** In this case, we present a Chinese woman (aged 25) in her 38th week of the first gestation who had the complication of agranulocytosis. No abnormality was detected in regular examinations before pregnancy and in the first trimester. Since the last trimester of pregnancy, the patient began to suffer from agranulocytosis and intermittent fever, the maximum being temperature 38.8°C. At admission, the neutrophil granulocytes were  $0.17 \times 10^9 L^{-1}$  and the bone marrow biopsy showed that agranulocytosis was detected, but the levels of red blood cell and megalokaryocyte were normal. In addition, antinuclear antibodies were detected at a dilution of 1:40, but anti-dsDNA, antiphospholipid antibody, and neutrophil granulocyte antibody were negative.

**Diagnoses:** The patient was empirically treated as having pneumonia.

**Interventions:** We tried to use granulocyte colony-stimulating factor,  $\gamma$ -globulin, glucocorticoids, antibiotics, and antifungi agents to treat the patient, but her symptoms were not alleviated until the patient had a cesarean section.

**Outcomes:** After 24 hours of cesarean section, the temperature and neutrophil granulocyte returned to normal. After a year of follow-up, we found that the patient and the baby were healthy.

**Lessons:** Agranulocytosis during pregnancy seems to be associated with immunosuppression induced by immunoregulations and termination of pregnancy may be effective for refractory pregnancy complicated with agranulocytosis, but further studies are needed to confirm this.

**Abbreviations:** ANA = antinuclear antibodies, G-CSF = granulocyte colony-stimulating factor.

**Keywords:** agranulocytosis, hypothyroidism, immunosuppression, pregnancy

## 1. Introduction

Pregnancy is a complicated physiological process.<sup>[1]</sup> In pregnant women, local adaptation of the maternal immune system allows for successful coexistence between the mother and the fetus/placenta.<sup>[2]</sup> There are multiple strategies for the adaptive immunity, including altered human leukocyte antigen expression, synthesis of immunosuppressive molecules (progesterone, prostaglandins), and expression of high levels of complement regulatory proteins and alterations in the relative proportions,

phenotype, and functions of leukocyte subpopulations, cytokine profiles across gestation, etc.<sup>[2,3]</sup> These alterations make mother and infant reach a state in which cytotoxic adaptive immune responses are diminished, bypassed, or even abrogated, while regulatory adaptive immunity is enhanced.<sup>[4]</sup> At the same time, pregnancy is associated with leukocytosis, primarily related to an increased circulation of neutrophils.<sup>[5]</sup> The neutrophil count begins to increase in the second month of pregnancy and plateaus in the second or third trimester, at which time the total white blood cell counts range from 9000 to  $15,000 \times 10^6/L$ .<sup>[5]</sup> During the gestational period, internal environmental changes can cause poor immunological functions. Simultaneous agranulocytosis makes the pregnant women more vulnerable to infection, which is one of the risk factors of intrauterine infection,<sup>[6]</sup> miscarriage, premature delivery, fetal growth restriction, fetus death, or, in extreme cases, death of both mother and baby.<sup>[7]</sup> Noncongenital agranulocytosis during pregnancy is rare and reported only occasionally, while in most of the cases, the agranulocytosis has already occurred prior to pregnancy or induced by identified factors such as genetic factors, antibiotics, antithyroid agents, or cytotoxic agents.<sup>[8–12]</sup> Gestation-induced agranulocytosis has not been reported, so we present a case of gestation-induced agranulocytosis in this article.

## 2. Case report

A Chinese woman (aged 25) in her 38th week of the first gestation, whose blood type was type B and RH-positive, had regularly received thyroid function tests and used levothyroxine sodium 75  $\mu g/d$  for her condition of hypothyroidism for 13 years.

Editor: Esaki M. Shankar.

HW and J-LS contributed equally to the article.

Authorship: HW wrote the manuscript; J-LS organized related information; Z-LZ and H-HP were responsible for checking and modification.

The authors have no conflicts of interest to disclose.

Emergency Department, The Second Affiliated Hospital of Xi'an Jiaotong University, Xi'an, Shaanxi, PR China.

\* Correspondence: Zheng-Liang Zhang; Hong-Hong Pei, Emergency Department, The Second Affiliated Hospital of Xi'an Jiao Tong University, 710004 Xi'an, Shaanxi, PR China (e-mails: 18991204398@163.com; 15109276591@163.com).

Copyright © 2016 the Author(s). Published by Wolters Kluwer Health, Inc. This is an open access article distributed under the Creative Commons Attribution-NoDerivatives License 4.0, which allows for redistribution, commercial and non-commercial, as long as it is passed along unchanged and in whole, with credit to the author.

Medicine (2016) 95:52(e5717)

Received: 22 April 2016 / Received in final form: 11 October 2016 / Accepted: 25 November 2016

<http://dx.doi.org/10.1097/MD.0000000000005717>

Latest thyroid function tests were conducted 4 months after pregnancy and no abnormal change was observed. She did not have any personal and family history of hyperthyroidism, agranulocytosis, and antithyroid medicinal drugs. During her gestational period, the repeated blood routine tests showed that the counts of white blood cell and neutrophil granulocyte were within the normal range. A month before being admitted to the hospital, she suffered intermittent fever, the maximum temperature being 38.8°C, and had other symptoms including oral ulcers, shivering, cough, and a small amount of white phlegm. The symptoms usually became serious at night. She was given symptomatic relief and supportive treatments, but the treatments did not work. Thus, the patient was transferred to several other medical centers; during this period, routine blood tests indicated a low level of the counts of white blood cell and neutrophil granulocyte. The result of the bone marrow biopsy conducted by another hospital showed that agranulocytosis was detected, but the levels of red blood cell and megalokaryocyte were normal. At admission, the counts of white blood cell were  $1.63 \times 10^9 L^{-1}$ , the counts of the neutrophil granulocyte were  $0.17 \times 10^9 L^{-1}$ , the hemoglobin concentration was 86 g/L, and the counts of platelet were  $247 \times 10^9 L^{-1}$ . Thyroid function tests—free thyroxine, total thyroxine, and thyroid-stimulating hormone—were within the normal range; free triiodothyronine was 2.22 pmol/L and total triiodothyronine was 1.05 nmol/L. Ultrasonography of abdomen, fetus, and urine showed that all tested areas were normal. The tests of immunoglobulin M (IgM) against cytomegalovirus, IgM against rubella virus, IgM against *Toxoplasma*, herpes simplex type I virus, herpes simplex type II virus, and interferon  $\gamma$  release assay were negative. Neutrophil granulocyte antibody was negative. Antinuclear antibodies (ANA) were detected at a dilution of 1:40, while anti-dsDNA, antiphospholipid antibody, and neutrophil granulocyte antibody were negative. Erythrocyte sedimentation rate was 113 mm/h; C-reactive protein was 8.74 mg/dL; hepatitis, human immunodeficiency virus, and *Treponema pallidum* were negative; and Epstein-Barr virus DNA was  $<1.0E+003$ . Women are more vulnerable to infections during the gestational period, and infections in pregnant women are often more hazardous. The patient was diagnosed as having pneumonia based on the symptoms (fever, cough, phlegm, and positive signs in the lungs), high procalcitonin shown by laboratory examinations, and positive results of phlegm cultivation.

During hospitalization, wide-spectrum antibiotics and fluconazole were given as anti-infective therapy. Pulse therapy of granulocyte colony-stimulating factor (G-CSF),  $\gamma$ -globulin, white blood cell-boosting agents, and glucocorticoids were given as auxiliary treatment. Four days after therapy, the counts of white blood cell and neutrophil had no obvious changes (white blood cell  $2.33 \times 10^9 L^{-1}$ , neutrophil  $0.3 \times 10^9 L^{-1}$ ). Bone marrow biopsy was reperformed; the results of bone marrow biopsy reperformed by our hospital also showed that agranulocytosis was detected, and levels of red blood cell and megalokaryocyte were normal. Then the tests of autoimmune antibody, cardiul-trasonography, and ultrasonography of abdomen, fetus, and urine were performed to reassure that no abnormality was missed. Since pregnancy was a contraindication of x-ray examination, x-ray was not performed. After receiving all therapy, the patient experienced a decrease of body temperature and procalcitonin level, but the levels of white blood cell and neutrophil did not increase (see Figs. 1 and 2). Six days later, the patient had a cesarean section and delivered a healthy infant in her 39th week of gestation. Apgar scores of the infant were 9, 10, and 10, respectively, at 1, 5, and 10 minutes.

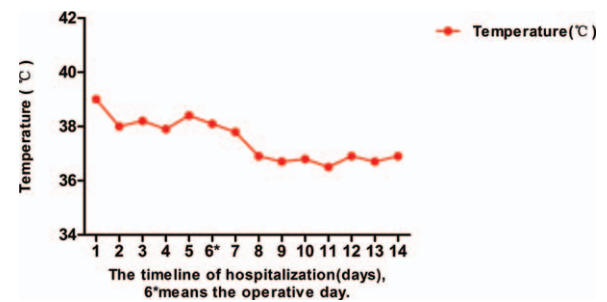


Figure 1. Variation tendency of body temperature. (\*) The operative day.

Anti-infective therapy was continued (no schemes were changed). The patient had a good recovery after 24 hours; her temperature returned to normal; the count of white blood cell rose to  $2.41 \times 10^9 L^{-1}$  and the count of neutrophils rose to  $1.38 \times 10^9$  days. Her counts of white blood cell and neutrophils gradually returned to a normal state. Three days later, the count of white blood cell was  $5.39 \times 10^9 L^{-1}$  and the count of neutrophil was  $1.49 \times 10^9 L^{-1}$ . A week later, the patient was successfully discharged without any complications. One-year postoperational follow-up showed that the tests of routine blood test, C-reactive protein, and neutrophil antibody were all within normal range and the baby was healthy, without any deformations or other diseases. The present case report was published on the premise of the patient's informed consent, and informed consent form was filled and signed.

### 3. Discussion

In this case report, the patient was a young woman who was regularly using levothyroxine sodium for her hypothyroidism for a long time. The patient did not suffer from agranulocytosis until the third trimester, in spite of the fact that levothyroxine sodium is safe for pregnant women and no evidence shows the side effects of levothyroxine sodium including agranulocytosis.<sup>[13]</sup> Hypothyroidism has been associated with an increased risk of several complications including preeclampsia, gestational hypertension, placental abruption, preterm delivery, etc.<sup>[14]</sup> At the same time, there is no evidence showing that hypothyroidism can lead to agranulocytosis and the patient had no history of using antibiotics, antithyroid drugs, cytotoxic drugs, or other medications that are the definite cause of agranulocytosis. Therefore,

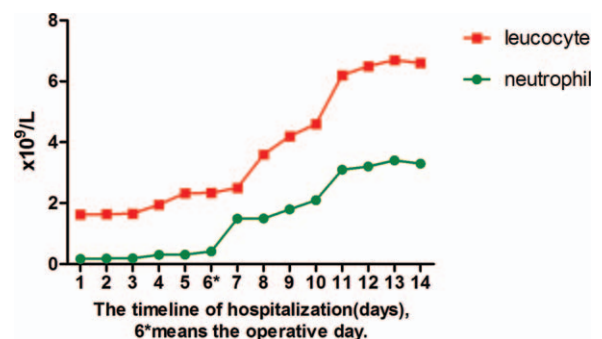


Figure 2. Variation tendency of leukocyte and neutrophil. (\*) The operative day.

we believe that drug-induced agranulocytosis is less possible in this case.

The test of autoantibodies showed that ANA was detected at a dilution of 1:40, but double-stranded DNA, antiphospholipid antibody, and neutrophil granulocyte antibody were negative. The literatures suggest that approximately 30% of the normal population with ANA detected at a dilution of 1:40 has a false-positive result.<sup>[15]</sup> At the same time, the treatments of G-CSF,  $\gamma$ -globulin, white blood cell-boosting agents, and glucocorticoids almost had no effect on the patient's condition.<sup>[9,10,16,17]</sup> So, we think that it is less likely that the patient was experiencing systemic lupus erythematosus or other autoimmune diseases.

In the second and third trimesters of gestation, the counts of neutrophil gradually fell, and pneumonia occurred in the third trimester, namely, neutropenia prior to lung infection. The anti-infection therapeutic strategy was not effective until 24 hours after delivery. In terms of time, the turning point at which the symptoms and counts of neutrophil returned to normal was the termination of pregnancy and anti-infective therapy was relatively short. Thus, we conclude that agranulocytosis seems to be associated with pregnancy itself and immune tolerance induced by the fetus during pregnancy. The maternal immune system may inhibit the immune response or generate some kinds of inhibitor to protect the fetus during pregnancy.<sup>[18]</sup> With the termination of pregnancy, the released immune suppression and some certain elevated related biomarkers may be the reason for the patient's rehabilitation. We also suggest that termination of pregnancy may be an effective treatment for pregnancy complicated with agranulocytosis.

### 3.1. Potential defects

First, agranulocytosis was prior to pneumonia, but the possibility that agranulocytosis was caused by pneumonia cannot be excluded. The patient received integrated treatment including anti-infection treatment, G-CSF,  $\gamma$ -globulin, hormone, antibiotics, antifungi agents, etc. However, her symptoms were not alleviated until the patient had a cesarean section, so we tend to believe that the pneumonia was an additional manifestation of agranulocytosis.<sup>[19]</sup> Second, due to the relatively long disease duration, the patient may have taken some drugs inducing agranulocytosis, but she could not remember, namely, the existence of information risk of bias.<sup>[20]</sup>

## 4. Conclusions

Agranulocytosis during pregnancy seems to be associated with immunosuppression induced by immunoregulations and termination of pregnancy may be effective for refractory pregnancy

complicated with agranulocytosis, but further studies are needed to confirm this.

## References

- [1] Medicine DCCOPhysiology of Pregnancy. Chapter 41. John Wiley & Sons Ltd, Hoboken, NJ:2015.
- [2] Robertson SA. Immune regulation of conception and embryo implantation—all about quality control? J Reprod Immunol 2010;85:51–7.
- [3] Leber A, Teles A, Zenclussen AC. Regulatory T cells and their role in pregnancy. Am J Reprod Immunol 2010;63:445–59.
- [4] Rukavina D. Immunology of the Pregnancy. Medicinska Naklada, Zagreb:2014.
- [5] Weetman AP. Immunity, thyroid function and pregnancy: molecular mechanisms. Nat Rev Endocrinol 2010;6:311–8.
- [6] Zhang S, Wan D, Cao W, et al. The Clinical significance of procalcitonin in hematological malignancies with agranulocytosis and infection after chemotherapy. Journal of Basic & Clinical Oncology 2012;01:17–20.
- [7] Whittle M. Infection and pregnancy. Rev Prat 1991;1:543–95.
- [8] Yoshida Y, Ueda K, Tomimatsu T, et al. A case of pregnancy associated with cyclic neutropenia. Acta Obstet Gynecol Scand 1995;74:836–8.
- [9] Candido HM, Bortolotto MR, Strabelli TM, et al. Case 4/2011—agranulocytosis and puerperal sepsis in women after the use of ceftriaxone. Arq Bras Cardiol 2011;97:e20–8.
- [10] Alter BP, Kumar M, Lockhart LL, et al. Pregnancy in bone marrow failure syndromes: Diamond–Blackfan anaemia and Shwachman–Diamond syndrome. Br J Haematol 1999;107:49–54.
- [11] Polcz TE, Stiller RJ, Whetham JC. Pregnancy in patients with cyclic neutropenia. Am J Obstet Gynecol 1993;169(2 pt 1):393–4.
- [12] Horne GA, Chevassut T. Pregnancy in Shwachman–Diamond syndrome: a novel genetic mutation with minimal consequence. BMJ Case Rep 2012;2012:
- [13] Mahler M, Ngo JT, Schulte-Pelkum J, et al. Limited reliability of the indirect immunofluorescence technique for the detection of anti-Rib-P antibodies. Arthritis Res Ther 2008;10:R131.
- [14] Tajiri J, Noguchi S. Antithyroid drug-induced agranulocytosis: how has granulocyte colony-stimulating factor changed therapy? Thyroid 2005;15:292–7.
- [15] Ryosuke S, Mutsuhiro I, Kazunori T, et al. Exposure of drugs for hypertension, diabetes, and autoimmune disease during pregnancy and perinatal outcomes: an investigation of the regulator in Japan. Medicine 2015;94:217–25.
- [16] Vaidya B, Hubalewskadydejczyk A, Laurberg P, et al. Treatment and screening of hypothyroidism in pregnancy: results of a European survey. Eur J Endocrinol 2012;166:49–54.
- [17] Männistö T, Mendola P, Grewal J, et al. Thyroid diseases and adverse pregnancy outcomes in a contemporary US cohort. J Clin Endocrinol Metab 2013;98:2725–33.
- [18] Song D, Shi Y. Immune system modifications and fetomaternal immune tolerance. Chin Med J (Engl) 2014;127:3171–80.
- [19] Su H, Zhang Q, Li L, et al. Urinary tract infection (UTI) caused by *Fusarium proliferatum* in an agranulocytosis patient and a review of published reports. Mycopathologia 2015;181:1–5.
- [20] Feng X, Ruan Y, He Y, et al. Prophylactic first-line antibiotics reduce infectious fever and shorten hospital stay during chemotherapy-induced agranulocytosis in childhood acute myeloid leukemia. Acta Haematol 2014;132:112–7.