






## Case Report

# Ruptured fungal mycotic internal carotid artery aneurysm successfully treated with stent-assisted coil embolization: A case report

Noritaka Sano<sup>1,2</sup>, Hiroyuki Ikeda<sup>1</sup>, Yoshitaka Tsujimoto<sup>1</sup>, Makoto Hayase<sup>1</sup>, Sadaharu Torikoshi<sup>1</sup>, Taiyo Morikawa<sup>3</sup>, Tadakazu Okoshi<sup>4</sup>, Masaki Nishimura<sup>1</sup>, Hiroki Toda<sup>1</sup>

<sup>1</sup>Department of Neurosurgery, Japanese Red Cross Fukui Hospital, Fukui, <sup>2</sup>Department of Neurosurgery, Kyoto University Graduate School of Medicine, Kyoto, Departments of <sup>3</sup>Otorhinolaryngology, <sup>4</sup>Pathology, Japanese Red Cross Fukui Hospital, Fukui, Japan.

E-mail: \*Noritaka Sano - n\_sano@kuhp.kyoto-u.ac.jp; Hiroyuki Ikeda - rocky@kuhp.kyoto-u.ac.jp; Yoshitaka Tsujimoto - ytsujimoto19891231@gmail.com; Makoto Hayase - hayase.makoto@gmail.com; Sadaharu Torikoshi - sr358@kuhp.kyoto-u.ac.jp; Taiyo Morikawa - taiyo1125@hotmail.co.jp; Tadakazu Okoshi - tokoshi.patho@gmail.com; Masaki Nishimura - masakins@kuhp.kyoto-u.ac.jp; Hiroki Toda - hi-toda@kitano-hp.or.jp



### \*Corresponding author:

Noritaka Sano,  
Department of Neurosurgery,  
Kyoto University Graduate  
School of Medicine, Kyoto,  
Japan.

n\_sano@kuhp.kyoto-u.ac.jp

Received : 21 June 2022

Accepted : 18 August 2022

Published : 02 September 2022

### DOI

10.25259/SNI\_567\_2022

### Quick Response Code:



## ABSTRACT

**Background:** Ruptured intracranial fungal mycotic aneurysms have a high mortality rate. It has been reported that the number of opportunistic infections has increased. Here, we report the first case of a patient in which a ruptured fungal carotid artery aneurysm was successfully treated by stent-assisted coil embolization.

**Case Description:** A 76-year-old male receiving dual antiplatelet therapy due to a recent percutaneous transluminal angioplasty presented with blurred vision of the right eye and diplopia. Magnetic resonance imaging revealed a fungal mass in the sphenoid sinus, and the patient was pathologically diagnosed with invasive aspergillosis. After receiving oral voriconazole for 4 weeks, he was admitted to the hospital with hemorrhagic shock from epistaxis. The right internal carotid artery angiography revealed a *de novo* irregularly shaped aneurysm at the cavernous portion, projecting into the sphenoid sinus, which was considered to be the source of bleeding. Due to the lack of ischemic tolerance and urgent demand for hemostasis, we performed a stent-assisted coil embolization of the aneurysm without interrupting the blood flow. Postoperatively, the patient had no neurological deficit, and treatment with voriconazole was continued for 12 months without rebleeding.

**Conclusion:** Stent-assisted coil embolization without parent artery occlusion might be a promising option for the urgent treatment of ruptured fungal mycotic aneurysms. Long-term administration of voriconazole might be continued for 12 months for such patients.

**Keywords:** *Aspergillus*, Coil embolization, Fungal aneurysm, Mycotic aneurysm, Stent

## INTRODUCTION

Invasive aspergillosis can cause a number of problems, including meningitis, brain abscess, orbital apex syndrome, or rarely, mycotic aneurysms, especially in immunocompromised patients.<sup>[2,7]</sup> Here, we describe a case of a patient with diabetes mellitus who developed a cavernous internal carotid artery (ICA) fungal mycotic aneurysm, associated with invasive aspergillosis of the

sphenoid sinus, which resulted in massive epistaxis. This is the first reported case in which a fungal mycotic aneurysm of the cavernous ICA due to invasive aspergillosis was successfully treated by stent-assisted coil embolization without interruption of the blood flow. Following endovascular therapy, he received oral voriconazole for 12 months without rebleeding and survived without any neurological deficits for 3 years so far.

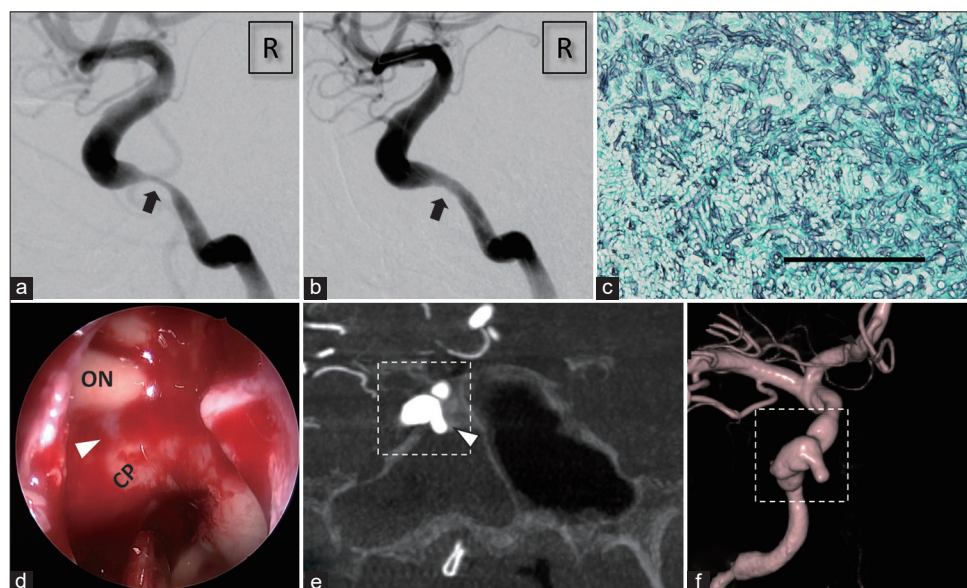
## CASE DESCRIPTION

### History

A 76-year-old right-handed male with a history of diabetes mellitus, hypertension, and coronary artery disease suffered from repetitive transient ischemic attacks due to severe progressive stenosis, which had been diagnosed 5 years before. He underwent a percutaneous transluminal angioplasty and stenting with Wingspan 4.5 mm\*15 mm (Stryker, MI, U.S.A.) of a cavernous-petrous portion of the right ICA [Figures 1a and b]. Three weeks after the procedure, he developed blurred vision in his right eye and diplopia, and magnetic resonance imaging revealed fungal sinusitis in the sphenoid sinus. The  $\beta$ -d-Glucan serum level was 46 pg/ml

(upper limit of normal: 19 pg/ml). Based on the pathological analysis of the fungal ball, the sinusitis was found to be due to an *Aspergillus* species [Figure 1c]. Therefore, following the operation, the patient was prescribed oral voriconazole. Five weeks after the debridement of the fungus ball, he developed massive epistaxis with hemorrhagic shock and was referred to our emergency unit.

A fiber endoscopy revealed that the source of bleeding was from the sphenoid sinus. Tentative hemostasis was achieved by a posterior tamponade with hemostatic balloon and gauze. However, soon after the hemostatic instrument had been removed, he suffered from massive epistaxis. A blood transfusion and urgent hemostasis were required. A retrospective review of the endoscopic hemostasis procedure revealed pulsatile projection on the roof of the sphenoid sinus [Figure 1d], and cerebral angiography showed an irregularly shaped *de novo* aneurysm at the medial side of the cavernous portion of the right ICA, the tip of which was projecting into the sphenoid sinus [Figures 1e and f]. Furthermore, the retrospective review of the computed tomography before the first stenting intervention revealed the gap of bony structure around the aneurysm, which suggested that the direct invasion of *Aspergillus* adjacent



**Figure 1:** Imaging findings before the embolization. (a and b) The right internal carotid artery (ICA) angiography before and after the percutaneous transluminal angioplasty and stent deployment of the petrous ICA stenosis (arrow). (c) Grocott (modified Gomori methenamine silver) stain of the fungus ball in the sphenoid sinus showing branching septate hyphae typical of *Aspergillus* species (original magnification  $\times 200$ , black bar = 100  $\mu$ m). (d) Endoscopic view in the sphenoid sinus during the hemostatic procedure. A pulsatile projection (arrowhead) between ON and CP was seen while no active bleeding was confirmed (ON: optic nerve and CP: carotid prominence). (e) Coronal section of the right three-dimensional rotational angiography. A tip of irregularly shaped aneurysm projected into the right sphenoid sinus (arrowhead), and the sinus was filled with blood. (f) Three-dimensional rotational angiography showing irregularly shaped stenosis and dilatation. Dotted rectangles in (e) and (f) indicate the same portion of the aneurysm.

to the cavernous ICA had been already occurred. To treat the bleeding and further invasion of the distal ICA wall, obliteration of the flow to the aneurysm and the parent artery using a coil or clip was considered. However, his medical history of the right hemispheric ischemia suggested a high risk of cerebral infarction after the occlusion of the parent artery. Furthermore, due to the length of time after the Wingspan deployment (8 weeks), antiplatelet drug withdrawal for direct surgery would result in-stent thrombosis. Furthermore, by the time of the endovascular procedure, the serum  $\beta$ -D-Glucan levels had continued to decrease close to the normal limit (23 pg/ml). Therefore, preservation of the parent artery seemed to be an acceptable strategy.

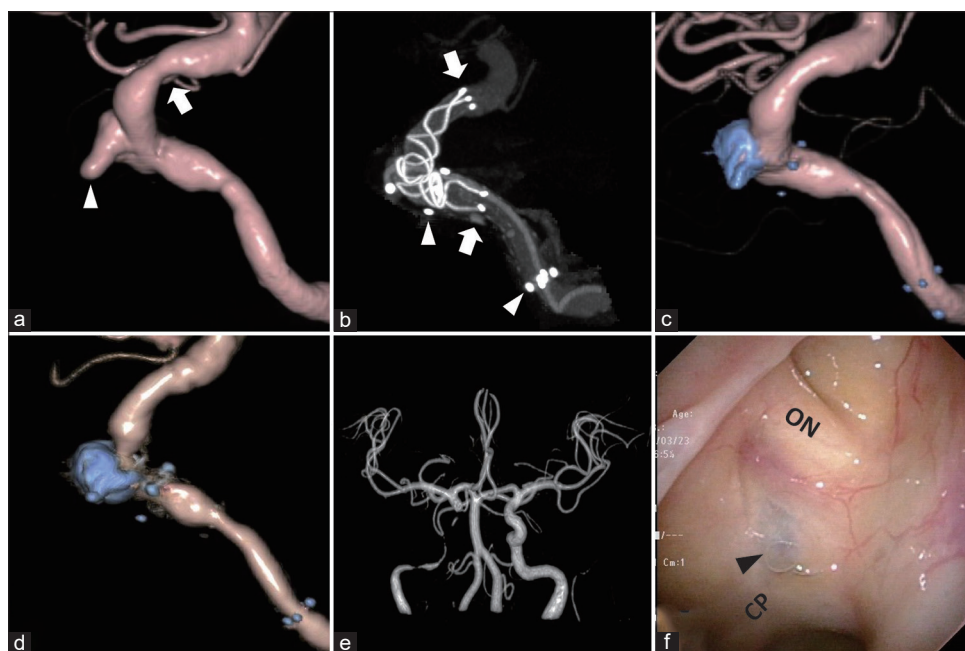
### Endovascular procedure

To achieve urgent hemostasis, we chose stent-assisted coil embolization to preserve the blood flow of the ICA. First, a microcatheter for coil embolization was navigated into the aneurysm. Then, we deployed LVIS BLUE 4.0 mm\*28 mm

(Terumo, Tokyo, JAPAN) in the ICA from just proximal to the posterior communicating artery. The coverage of the stent was increased at the protruding part, to the cavernous portion overlapping partially into the Wingspan stent. After that, we packed the aneurysm with a coil using the jailing technique [Figures 2a-c].

### Postoperative course

Immediately following the procedure, his blurred vision and diplopia completely resolved. Subsequently, he continued oral voriconazole, and his serum  $\beta$ -D-Glucan levels returned to a normal level within 3 months. The patient never experienced epistaxis or neurological deterioration postoperatively. Furthermore, we regularly conducted magnetic resonance angiography (MRA) and digital subtraction angiography in every 3 months, and there was no recurrence or the appearance of the *de novo* aneurysm in the downstream of the right ICA. Moreover, three-dimensional rotational ICA angiography revealed no recurrence of the aneurysm after



**Figure 2:** Imaging findings during and after the embolization. (a) The right internal carotid artery (ICA) three-dimensional rotational angiography, lateral view. There were *de novo* aneurysmal projection (arrowhead) and stenosis (arrow), which were not seen 8 weeks before [Figure 1a and b]. (b) Three-dimensional rotational angiography after the deployment of the LVIS BLUE stent. The stent was deployed between the arrows and the proximal part was overlapped with the Wingspan stent (between the arrowheads). (c) The right ICA angiography after embolization showing no blood flow in the aneurysm and slight improvement of stenosis indicated in (a). (d) The right ICA angiography 6 months after embolization. There was no relapse of the aneurysm, while slight in-stent restenosis was seen in the Wingspan stent. (e) Magnetic resonance angiography 12 months after the embolization. There was no *de novo* intracranial aneurysm. Blood flow around the coils and stents cannot be seen because of the magnetic substance effect. (f) Endoscopic view in the sphenoid sinus 12 months after the embolization. Coils in the aneurysm were seen through the mucous membrane in the sphenoid sinus (arrowhead).

6 months [Figure 2d]. Oral voriconazole was stopped after 12 months following the confirmation of no aneurysmal relapse in MR angiography [Figure 2e], no abnormal sphenoid sinus findings with endoscopy [Figure 2f], and a normal serum  $\beta$ -d-Glucan level. He has survived without any complications for 3 years after the endovascular procedure so far.

## DISCUSSION

To the best of our knowledge, this is the first report of a fungal mycotic intracranial ICA aneurysm preserving blood flow in the parent artery and being successfully treated with stent-assisted coil embolization. There are few reports of fungal mycotic aneurysms of the ICA, and almost all cases are associated with an immunocompromised condition, including chemotherapy or diabetes mellitus.<sup>[3,6,10,19]</sup> *Aspergillus* species are the most common organism followed by *Mucor* or *Candida*. A fungal mycotic aneurysm can affect both the intra and extracranial ICAs and result in subarachnoid hemorrhage, cerebral infarction, or epistaxis according to the affected site. There are two main possible explanations for the formation of *de novo* fungal intracranial aneurysms. First is the outward invasion of the vessel wall from the intima, which is often caused by seeding of the pathogen through the bloodstream from a remote organ such as the lung or heart. Second is the direct invasion of adventitia from a fungal infection in the adjacent tissue. Intracavernous ICA fungal mycotic aneurysms are often caused by the latter etiology because the segment is adjacent to the sphenoid sinus, which is the second most affected paranasal sinus next

to the maxillary sinus.<sup>[4]</sup> *Aspergillus* species produce elastase and decompose all vascular layers from the outside<sup>[12]</sup> and the thinned wall of the affected lesion results in a *de novo* aneurysm, which readily ruptures.

Ruptured intracranial fungal mycotic ICA aneurysms are generally fatal. Conservative treatment with antifungal drugs is not enough for hemostasis and resulted in death in all reported cases [Table 1].<sup>[1,8,11,13-15,18]</sup> Therefore, prompt management with surgical or endovascular intervention is mandatory for the survival of patients. Of the four patients that were treated surgically or with an endovascular procedure, two survived. Besides, there might be a considerable number of underreported cases with treatment failure. The primary strategy for this condition is to interrupt the blood flow of the parent artery, including the aneurysm, using a clip, coil, or balloon.<sup>[7,9]</sup> However, in cases without sufficient collateral blood flow from the circle of Willis, fatal cerebral infarction can occur after the treatment.<sup>[2,3]</sup> Neck clipping or coil embolization that preserves blood flow as with usual aneurysms seems to be inadequate because most of their walls are extremely vulnerable.<sup>[2]</sup> Yamaguchi *et al.* reported an unruptured case of a patient who was treated by trapping of the affected ICA with an extracranial-intracranial high-flow bypass, which led to favorable outcomes.<sup>[19]</sup> This might be the most reliable approach for patients without sufficient collateral blood flow because the affected lesions can be isolated while avoiding cerebral ischemia. We plan to conduct trapping with a high-/low-flow bypass if we detect an aneurysmal relapse in MRA and digital subtraction angiography. Kim *et al.* reported a case that was treated by a graft stent to preserve the blood flow that also

**Table 1:** Summary of the reported ruptured intracranial fungal mycotic internal carotid artery aneurysm cases.

Author (year)	Age (years)/Sex	Fungus	Underlying medical condition	Site of aneurysm <sup>#1</sup>	Procedure	Outcome
Ahuja <i>et al.</i> (1978) <sup>[11]</sup>	18/M	<i>Aspergillus</i>	Sinusitis	C1	None	Death
Iihara <i>et al.</i> (1990) <sup>[8]</sup>	61/F	<i>Aspergillus</i>	CLL	C4	None	Death
Komatsu <i>et al.</i> (1991) <sup>[11]</sup>	62/M	<i>Aspergillus</i>	Sinusitis and TSS	C1	None	Death
Okada <i>et al.</i> (1998) <sup>[15]</sup>	62/M	<i>Aspergillus</i>	Steroid and transcranial biopsy	C1	None	Death
Hurst <i>et al.</i> (2001) <sup>[7]</sup>	73/M	<i>Aspergillus</i>	CLL	C4	PAO with coil and balloon	Death
Thajeb <i>et al.</i> (2004) <sup>[18]</sup>	62/F	<i>Mucor</i>	DM	C4	None	Death
Lim <i>et al.</i> (2010) <sup>[13]</sup>	63/M	<i>Aspergillus</i>	DM	C2	None	Death
Jao <i>et al.</i> (2011) <sup>[9]</sup>	76/M	<i>Aspergillus</i>	DM	C4	PAO with coil and NBCA	Survive (death in 7 months)
Kim <i>et al.</i> (2012) <sup>[10]</sup>	46/F	<i>Aspergillus</i>	Steroid and cyclophosphamide for lupus erythematosus	C4	Graft stent	Survive
Bowers <i>et al.</i> (2015) <sup>[3]</sup>	76/F	<i>Aspergillus</i>	Steroid and methotrexate for rheumatoid arthritis	C2	Clip and wrapping	Death
Present case (2022)	76/M	<i>Aspergillus</i>	DM	C3/4	Stent-assisted coil without PAO	Survive

CLL: Chronic lymphoid leukemia, TSS: Transsphenoidal surgery, DM: Diabetes mellitus, <sup>#1</sup>Based on Fisher's segmentation of the internal carotid artery. C1: Communicating segment, C2: Ophthalmic segment, C3: Clinoidal segment, C4: Cavernous segment, C5: Petrous segment

achieved favorable outcomes. However, after cessation of the antifungal therapy, they had to treat the *de novo* aneurysm in the downstream of the original lesion.<sup>[10]</sup> Although they did not describe the laboratory findings before and after stenting, the  $\beta$ -d-Glucan serum levels should be carefully monitored due to the possibility of chronic infection or dissemination of fungus. Except for the stent-graft case mentioned above, all cases using foreign materials including a coil or balloon did not result in a latent infection during follow-up.

In our case, massive epistaxis due to the *de novo* aneurysm in cavernous ICA occurred only 8 weeks after the deployment of a Wingspan stent, and urgent cessation of the antiplatelet therapy would result in-stent thrombosis or occlusion. Direct surgery was considered less favorable due to the risk of bleeding from the patient being on dual antiplatelet therapy and the risk of ischemic complications if prompt parent artery occlusion without a maneuver to ensure collateral blood flow. Stent-assisted coil embolization of the aneurysm might be a good option, as it ensures the blood flow of the parent artery while blocking the inflow to the irregularly shaped aneurysm. There is the possibility of a rupture occurring in the fragile wall of the fungal mycotic aneurysm during the maneuver. However, we could stop the bleeding by occlusion of the aneurysm in the cavernous sinus with minimal access to the fragile bleb projecting into the sphenoid sinus. Moreover, even if the aneurysm ruptured into the cavernous sinus, it would not cause a fatal subarachnoid hemorrhage, but a direct carotid-cavernous fistula (CCF). Furthermore, CCF can be treated in the course of continuous endovascular embolization of cavernous sinus with coils. Despite this, an otolaryngologist was ready for direct hemostasis using fiber endoscopy in case of uncontrolled epistaxis during the procedure.

It can be challenging to select the antifungal agent to use and decide the duration of postoperative treatment. Voriconazole has become standard therapy for invasive aspergillosis involving the central nervous system,<sup>[5,16,17]</sup> because its lower molecular weight (349 Da) enables more effective penetration against the blood-brain barrier than other agents such as amphotericin B. The mean duration of treatment is around 3 months,<sup>[17]</sup> but in cases with foreign materials such as coils or stents in the affected lesion, a longer duration of treatment might be needed. In our case, the serum antigen or antibody for *Aspergillus* was not detected from the onset of symptoms, and the  $\beta$ -d-Glucan serum level had been monitored carefully. The serum  $\beta$ -d-Glucan level normalized within 3 months of the endovascular therapy, and we stopped voriconazole after 12 months without any complications. Even after the cessation of voriconazole,  $\beta$ -d-Glucan has not elevated for 2 years so far. On the contrary, Kim *et al.* reported a relapsed fungal mycotic aneurysm after 6 months of antifungal therapy.<sup>[10]</sup> Although there is no correct answer

for the duration of voriconazole, considering the remaining foreign materials in the affected lesion, 12 months might be a reasonable duration.

## CONCLUSION

Invasive aspergillosis can directly affect the cavernous ICA and cause a fungal mycotic aneurysm. If the aneurysm ruptures, this can cause subarachnoid hemorrhage or massive epistaxis, which is often fatal. In such cases, urgent hemostasis is needed. In cases with poor collateral blood flow and an aneurysm localized in the cavernous-petrous portion, stent-assisted coil embolization might be an alternative option for the occlusion of the parent artery. Continuing voriconazole for 12 months might be a reasonable strategy after such procedure.

## Acknowledgments

We wish to thank Tadashi Sagou for the precise radiological diagnosis and Daisuke Uesaka for making high-resolution digital subtraction angiography.

## Declaration of patient consent

The authors certify that they have obtained all appropriate patient consent.

## Financial support and sponsorship

Nil.

## Conflicts of interest

There are no conflicts of interest.

## REFERENCES

1. Ahuja GK, Jain N, Vijayaraghavan M, Roy S. Cerebral mycotic aneurysm of fungal origin. Case report. *J Neurosurg* 1978;49:107-10.
2. Baeesa SS, Bakhaidar M, Ahamed NA, Madani TA. Invasive orbital apex aspergillosis with mycotic aneurysm formation and subarachnoid hemorrhage in immunocompetent patients. *World Neurosurg* 2017;102:42-8.
3. Bowers CA, Saad D, Clegg DO, Ng P, Clayton F, Haydoura S, *et al.* Rapidly fatal internal carotid artery mycotic aneurysm rupture in a rheumatoid patient taking a TNF- $\alpha$  inhibitor: Case report and literature review. *J Neurol Surgery A Cent Eur Neurosurg* 2015;76:249-54.
4. Grosjean P, Weber R. Fungus balls of the paranasal sinuses: A review. *Eur Arch Otorhinolaryngol* 2007;262:461-70.
5. Herbrecht R, Denning DW, Patterson TF, Bennett JE, Greene RE, Oestmann JW, *et al.* Voriconazole versus amphotericin B for primary therapy of invasive aspergillosis. *N Engl J Med* 2002;347:408-15.

6. Hot A, Mazighi M, Lecuit M, Poirée S, Viard JP, Loulergue P, *et al.* Fungal internal carotid artery aneurysms: Successful embolization of an aspergillus-associated case and review. *Clin Infect Dis* 2007;45:e156-61.
7. Hurst RW, Judkins A, Bolger W, Chu A, Loevner LA. Mycotic aneurysm and cerebral infarction resulting from fungal sinusitis: Imaging and pathologic correlation. *Am J Neuroradiol* 2001;22:858-63.
8. Iihara K, Makita Y, Nabeshima S, Tei T, Keyaki A, Nioka H. Aspergillosis causing of the central nervous system from mycotic aneurysm of the basilar artery. *Neurol Med Chir* 1990;30:618-23.
9. Jao SY, Weng HH, Wong HF, Wang WH, Tsai YH. Successful endovascular treatment of intractable epistaxis due to ruptured internal carotid artery pseudoaneurysm secondary to invasive fungal sinusitis. *Head Neck* 2011;33:437-40.
10. Kim YC, Lee H, Ryu HH, Beom SH, Yang Y, Kim S, *et al.* Aspergillus-associated cerebral aneurysm successfully treated by endovascular and surgical intervention with voriconazole in lupus nephritis patient. *J Korean Med Sci* 2012;27:317-20.
11. Komatsu Y, Narushima K, Kobayashi E, Tomono Y, Nose T. Aspergillus mycotic aneurysm-case report. *Neurol Med Chir (Tokyo)* 1991;31:346-50.
12. Kothary MH, Chase T, Macmillan JD. Correlation of elastase production by some strains of aspergillus fumigatus with ability to cause pulmonary invasive aspergillosis in mice. *Infect Immun* 1984;43:320-25.
13. Lim SC, Choi JU, Bae SH. Rapid development of an infectious aneurysm of the internal carotid artery from orbital apex syndrome. *Otolaryngol Head Neck Surg* 2010;142:294-5.
14. Morriss FH, Spock A. Intracranial aneurysm secondary to mycotic orbital and sinus infection: Report of a case implicating penicillium as an opportunistic fungus. *Am J Dis Child* 1970;119:357-62.
15. Okada Y, Shima T, Nishida M, Yamane K, Yoshida A. Subarachnoid hemorrhage caused by aspergillus aneurysm as a complication of transcranial biopsy of an orbital apex lesion: Case report. *Neurol Med Chir (Tokyo)* 1998;38:432-7.
16. Schwartz S, Ruhnke M, Ribaud P, Corey L, Driscoll T, Cornely OA, *et al.* Improved outcome in central nervous system aspergillosis, using voriconazole treatment. *Blood* 2005;106:2641-5.
17. Schwartz S, Reisman A, Troke PF. The efficacy of voriconazole in the treatment of 192 fungal central nervous system infections: A retrospective analysis. *Infection* 2011;39:201-10.
18. Thajeb P, Thajeb T, Dai D. Fatal strokes in patients with rhino-orbito-cerebral mucormycosis and associated vasculopathy. *Scand J Infect Dis* 2004;36:643-8.
19. Yamaguchi J, Kawabata T, Motomura A, Hatano N, Seki Y. Fungal internal carotid artery aneurysm treated by trapping and high-flow bypass: A case report and literature review. *Neurol Med Chir (Tokyo)* 2016;56:89-94.

**How to cite this article:** Sano N, Ikeda H, Tsujimoto Y, Hayase M, Torikoshi S, Morikawa T, *et al.* Ruptured fungal mycotic internal carotid artery aneurysm successfully treated with stent-assisted coil embolization: A case report. *Surg Neurol Int* 2022;13:392.