

# Direct visualization of the syndesmosis for evaluation of syndesmotic disruption

## A cadaveric study

Nayla Gosselin-Papadopoulos, MD<sup>b</sup>, Jonah Hébert-Davies, MD<sup>b,c</sup>, G. Yves Laflamme, MD<sup>b,c</sup>, Jérémie Ménard<sup>b</sup>, Stéphane Leduc, MD<sup>b,c</sup>, Dominique M. Rouleau, MD, MSc<sup>b,c</sup>, Marie-Lyne Nault, MD, PhD<sup>a,b,c,\*</sup>

### Abstract

**Objectives:** Radiologic criteria for syndesmosis instability evaluation remain controversial and direct visualization (DV) of the distal tibiofibular articulation is an alternative diagnostic method worthy of further investigation. We speculate that DV is a more accurate way to evaluate syndesmosis instability than fluoroscopy. The purpose of this study is to determine whether syndesmosis instability can accurately be recognized through DV and if this new intraoperative diagnostic method is more sensitive than fluoroscopy in detecting syndesmosis instability.

**Methods:** Ten cadaveric ankles were tested using a sequential iatrogenic syndesmosis injury model. Specimens were tested incrementally with the lateral stress test (LST) and the external rotation stress test (ERT). The resulting instability was measured directly and fluoroscopically with a true mortise view by using medial clear space (MCS) and tibiofibular clear space (TFCS).

**Results:** DV detected a 2-ligaments injury at a mean diastasis of 3.02 mm ( $P=0.0077$ ) and 3.19 mm ( $P=0.0077$ ) with the LST and ERT, respectively. Fluoroscopically, TFCS showed a significant diastasis only with a complete syndesmosis rupture while MCS did not show any significant differences.

**Conclusions:** DV of the syndesmosis in a cadaver injury model appears to be more sensitive than fluoroscopy in identifying injury, especially incomplete syndesmotic disruption.

**Keywords:** ankle fracture, direct visualization, fluoroscopy, instability, syndesmosis

## 1. Introduction

Although syndesmotic injuries are commonly associated with ankle fractures, diagnostic criteria for syndesmosis instability remain controversial.<sup>[1–11]</sup> While complete disruption of the tibiofibular ligament complex is usually obvious on plain x-rays, partial ruptures may go undetected.<sup>[1,2,12]</sup> Residual tibiofibular instability can lead to progressive ankle mortise asymmetry, subsequent post-traumatic arthritis, and poor functional out-

come.<sup>[13,14]</sup> Accurate diagnosis of these subtle injuries is therefore necessary. Standard intraoperative techniques for evaluating syndesmosis stability consist of either a lateral stress (Cotton) or external rotation stress to the fibula.<sup>[3,6,17]</sup> Tibiofibular instability has traditionally been assessed on anteroposterior and mortise fluoroscopy using MCS, tibiofibular overlap (TFO), and TFCS. A lateral view has also been suggested to detect sagittal fibular displacement.<sup>[5]</sup> However, no consensus exists on which stress test and radiological parameter is most reliable.

Several recent studies have found conflicting results as to which intraoperative stress test is more sensitive.<sup>[4–6]</sup> Moreover, they were found to be insufficient to reliably detect syndesmosis injury.<sup>[3]</sup> Radiological parameters have also been questioned.<sup>[7]</sup> Intraoperative computed tomography scan, contralateral ankle radiography, and arthroscopic assessment have been suggested as more precise means for evaluating syndesmosis instability.<sup>[1,2,9,15–17]</sup> However, these modalities can be time consuming and increase radiation exposure for the patient and surgical team. DV of the syndesmosis during reduction has been found to decrease the rate of malreduction from 52% to 16% when compared to indirect fluoroscopic reduction.<sup>[14]</sup> To our knowledge, no study has assessed the ability of DV to detect syndesmotic injuries. We hypothesize that direct evaluation of ankle syndesmosis diastasis is more accurate than current intraoperative radiographic parameters for the detection of syndesmosis injury.

The purpose of this cadaveric study was to answer 2 questions: Can syndesmosis instability be accurately diagnosed under DV? Is DV more sensitive than fluoroscopic evaluation in detecting syndesmosis injury?

Ethics committee approval: granted by Hôpital du Sacré-Coeur de Montreal, # CÉR 2015-1169

Sponsorships or competing interests that may be relevant to content are disclosed at the end of this article.

<sup>a</sup> CHU Ste-Justine, Côte Ste-Catherine, <sup>b</sup> Hôpital du Sacré-Coeur de Montréal, Boul. Gouin O, <sup>c</sup> Université de Montréal, Department of Surgery, Boul. Edouard-Montpetit, Montreal, Canada

\* Corresponding author. Address: 7905-3175 Côte Ste-Catherine, Montréal, QC, Canada, H3T 1C5. Tel: +1 514 345 6672. E-mail address: [fabienne.bienvvenue.hsj@ssss.gouv.qc.ca](mailto:fabienne.bienvvenue.hsj@ssss.gouv.qc.ca) (M-L. Nault).

Copyright © 2018 The Authors. Published by Wolters Kluwer Health, Inc. on behalf of the Orthopaedic Trauma Association.

This is an open access article distributed under the terms of the Creative Commons Attribution-Non Commercial-No Derivatives License 4.0 (CCBY-NC-ND), where it is permissible to download and share the work provided it is properly cited. The work cannot be changed in any way or used commercially without permission from the journal.

OTA (2018) e006

Received: 20 December 2017 / Received in final form: 15 March 2018 /

Accepted: 1 May 2018

<http://dx.doi.org/10.1097/OI9.0000000000000006>

## 2. Materials and methods

A cadaveric study using 10 fresh frozen human lower limbs amputated above the knee was designed with approval from the ethics committee. The average age at death was 72 years old (range, 55–95). Three specimens were female and 2 were male. All ankles were screened using nonweight-bearing anteroposterior, lateral, and mortise radiographs to rule out osteoarthritis, post-traumatic changes and deformity. No gross asymmetry or joint space narrowing was noted upon fluoroscopic evaluation of the 10 cadaveric specimens, and no specimen was excluded. Syndesmosis ligaments integrity was confirmed on all ankles through DV during dissection.

A custom frame was created to stabilize the specimens and consistently reproduce specific ankle positions during testing (Fig. 1). The distal femur was dissected off the tibia on all specimens to allow access to the tibial plateau. All tissues of the proximal tibiofibular joint remained intact. The limbs were secured on the frame with multiple large cortical screws entering the tibial plateau in intersecting directions.

Prior to any dissection, ankle position was set at neutral dorsiflexion and was confirmed by taking true ankle mortise fluoroscopic views of each specimen. Skin, fatty tissue, and anterior compartment muscles were removed on all lower limbs from the mortise up to 15 cm proximally. This allowed excellent visualization of the bony and ligamentous structures of the syndesmosis. Two smooth 0.7 mm K-wire pins were inserted in the tibia and the fibula to act as reference points for anatomical measurements. Pins were inserted from anterior to posterior, perpendicular to the ground, in the anterior aspect of both the tibia and fibula 5 cm above the tibial plafond.

The antero-inferior tibio fibular ligament (AITFL), 10 cm of the interosseous membrane (IOM), and the postero-inferior tibio fibular ligament (PITFL) were sectioned sequentially, creating 4 different stages of dissection (stage 1=intact, stage 2=AITFL, stage 3=AITFL + IOM, stage 4=AITFL + IOM +PITFL). At each stage, the ERT and LST were successively performed. Strength was constantly monitored by using an axial load cell (LC8100-100-200, Omega, Stamford) with a maximum capacity of 200 lbf (890 N), calibrated by the manufacturer. The ERT and LST were performed according to the methods used in previous studies.<sup>[7,11,13]</sup> In those studies, the ERT was performed by pulling the midfoot in ER through a hoop placed 5 cm distal to the lateral malleolus with a 150 N force, which was chosen arbitrarily. During initial testing, we found this force to be significantly

higher than the one used intraoperatively in practice. Three surgeons successively performed the ERT, reproducing the force applied in a typical intraoperative setting, using the axial load cell. After several tests, a 45 N force was found to better reflect clinical practice, on average, and showed no significant changes in tibiofibular diastasis compared to 150 N in our initial sample. The LST examination was performed by grasping the distal fibula 2 cm proximal to the tibiotalar joint with a bone clamp and pulling laterally with a 100 N force.

For each test, a mortise fluoroscopic view was taken, and direct measurements were recorded using a manual caliper. DV measurements were made using the caliper at the base of each K-wire to measure the diastasis between the wires. This measurement takes into account 3-plane motion and creates a single value similar to what could be seen while evaluating the anterior syndesmosis intraoperatively.

All radiographs were processed and analyzed in a single center using the validated *sliceOmatic 5.0* software by (Tomovision, Magog, Canada). Each image was calibrated using the K-Wires implanted on the fibula. Measurements were taken at one hundredth of a millimeter by a single blinded senior orthopaedic surgery resident. Variables measured were the MCS and the TFCS as defined by previous studies. MCS was defined as the distance between the apex of the talar dome and the apex of the medial plafond.<sup>[5,18]</sup> TFCS consisted of the distance between the lateral border of the posterior tibia and the medial border of the fibula, measured 1 cm proximal to the tibial plafond.<sup>[5,9]</sup>

For the purpose of this study, instability was considered positive with a 2 mm shift. Previous studies involving syndesmosis stress tests have indicated that the maximum increase in tibiofibular diastasis compatible with satisfactory function is 1 to 2 mm.<sup>[19–21]</sup> In a typical intraoperative setting, a 1 mm difference can be difficult to estimate on fluoroscopy. As our objective is to create a diagnostic test that is clinically applicable we considered a 2 mm increase in diastasis to be a positive result for instability.

Statistical analyses were performed using STATISTICA v7.1 software (StatSoft Inc, Tulsa, Oklahoma). Measurements were compared using a nonparametric Wilcoxon test. Statistical significance was set at a *P* value lower than .05.

## 3. Results

A baseline physiologic tibiofibular diastasis was found with stress testing of the cadavers prior to syndesmosis dissection. The DV method showed a mean diastasis of 1.01 mm for ERT and 1.36 mm for LST. Radiographic measurements revealed a diastasis of <1 mm. Instability (defined in this study as a 2 mm shift) was detected with DV at stage 3 (2 ligament rupture) with a mean tibiofibular diastasis of 3.02 mm ( $P=0.0077$ ) for the LST and of 3.19 mm ( $P=0.0077$ ) using the ERT (Tables 1 and 2).

At every stage of dissection, DV showed a markedly larger measured diastasis than radiologic parameters with both stress tests (Fig. 2). MCS did not vary significantly with incremental ligamentous section using either stress test. TFCS did not reach the 2 mm criteria set for instability at stage 3 with either test. With a complete injury, (all 3 ligaments sectioned), the mean TFCS was 2.28 mm ( $P=.02$ ) using the LST and 2.01 mm ( $P=.1097$ ) using the ERT. The corresponding mean DV tibiofibular diastasis was 3.80 mm ( $P=0.0077$ ) for the LST and 4.21 ( $P=0.0077$ ) using the ERT (Tables 1 and 2). DV was therefore more sensitive to instability than fluoroscopic parameters.

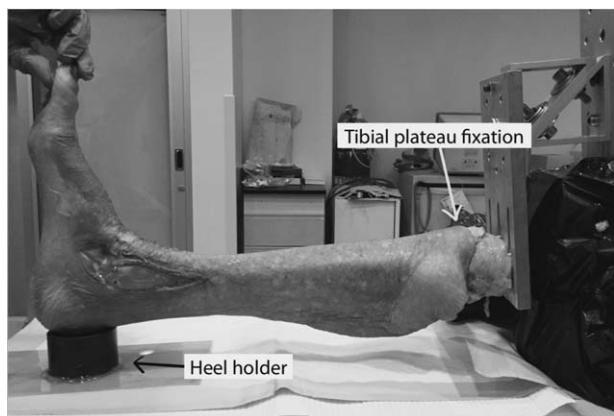


Figure 1. Representation of the experimental setup.

**Table 1****Mean diastasis using MCS, TFCS, and DV with incremental ligament section using external rotation stress.**

Ligament section	MCS, mm		TFCS, mm		DV, mm	
	Mean and SD	P value*	Mean and SD	P value*	Mean and SD	P value*
Intact	0.33 ± 1.18	–	0.66 ± 1.99	–	1.01 ± 0.60	–
AITFL	0.35 ± 1.06	.7670	1.02 ± 1.64	0.2603	<b>1.64 ± 0.68</b>	<b>0.0077</b>
AITFL+IOM	0.62 ± 1.26	.3742	1.28 ± 1.62	0.2603	<b>3.19 ± 0.78</b>	<b>0.0077</b>
AITFL+IOM+PITFL	0.85 ± 1.24	.2135	2.01 ± 2.01	0.1097	<b>4.21 ± 1.38</b>	<b>0.0077</b>

\* P values shown represent diastasis difference from the intact ankle. Significant p value are bold.

#### 4. Discussion

Our study confirms the hypothesis that DV is more sensitive than fluoroscopy in detecting syndesmosis instability. DV could reliably identify syndesmotic instability associated with a 2-ligaments injury, which is the threshold chosen in this study to cause instability.

Currently, stress radiographs of the mortise are considered the standard tool for intraoperative diagnosis of syndesmosis instability.<sup>[10]</sup> These are obtained using either external rotation or lateral fibular stress to produce tibiofibular diastasis. However, multiple issues exist with these modalities, with several studies showing a lack of sensitivity and reproducibility.<sup>[22,23]</sup> Asymmetry in the MCS is most commonly used as a means of detecting syndesmosis injury on standard mortise fluoroscopic imaging. Clinical studies have shown the incidence of syndesmotic instability in ankle fractures to be between 17% and 39%<sup>[22,23]</sup> when using MCS widening as a diagnostic criterion. However, these studies generally did not assess the integrity of the deltoid ligament. In a cadaveric experiment, Jiang et al showed that isolated deltoid injury significantly increases MCS and is therefore not specific to syndesmosis injury.<sup>[5]</sup> In the present study, we chose to keep the deltoid ligament intact. Our results, in agreement with those found by Jiang et al, demonstrate that MCS does not vary significantly in isolated syndesmotic injuries and therefore should not be used to evaluate syndesmotic instability.

Fluoroscopic assessment of the TFCS is also commonly used on intraoperative fluoroscopy to evaluate syndesmotic integrity. A biomechanical study by Ogilvie-Harris et al<sup>[24]</sup> demonstrated that the proportion of tibiofibular stability provided by each ligament was 35%, 22%, and 43% for the AITFL, IOM, and PITFL, respectively. A combination of any 2 ligaments' rupture would therefore lead to a loss of >50% of stabilization, which explains how even incomplete injuries can lead to instability. In this study, when using the TFCS, instability was detected only in the presence of complete syndesmotic disruption, regardless of which stress test was used. Miller et al<sup>[8]</sup> were able to show that DV of

the syndesmosis decreased malreduction significantly. Our results confirm that DV is superior to currently used methods for intraoperative diagnosis of syndesmotic instability. DV allowed detection of both 2 and 3 ligament injuries.

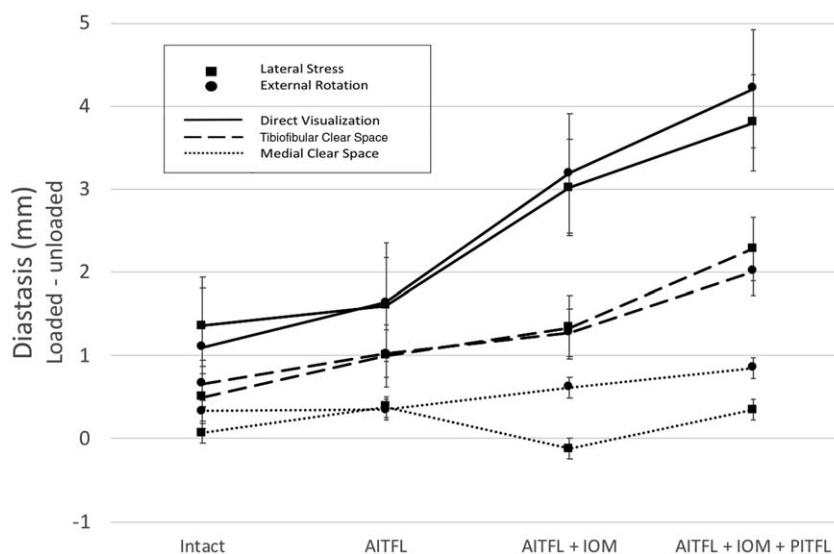
It is also important to note that in a clinical setting, fluoroscopic measurements are usually estimated. Subtle asymmetry can be dismissed as normal (i.e., a 1.34 mm TFCS widening produced by a 2-ligament syndesmotic rupture), potentially resulting in under treatment. DV allows for precise measurements, which should detect even subtle syndesmotic diastasis, that can be performed intraoperatively by measuring the distance between 2 set points with a sterile ruler. Whether small amounts of diastasis warrant surgical treatment has not yet been proven; however, having a precise measurement is surely a requirement in order to further evaluate this problem. Visualization of the anterior syndesmosis can be achieved with minor dissection and limited disruption to soft tissues. Sharp elevation (electrocautery should be avoided) along the anterior border of the fibula will expose the insertion of the AITFL. When this ligament is torn, continuing dissection to 1 mm medial of the tibial incisura will allow for complete anterior syndesmotic visualization, without significant disruption to the blood supply.

Another potential explanation for fluoroscopic inaccuracies in syndesmotic measurement is the inability to quantify multiplanar instability. Recent studies have shown that posterior translation of the fibula may be of more importance than lateral translation.<sup>[1]</sup> In one cadaveric study, Xenos et al reported that sagittal displacement of the fibula was more closely correlated to actual displacement under DV than coronal displacement.<sup>[2]</sup> In their attempt to validate external rotation stress for syndesmosis instability, Beumer et al<sup>[18]</sup> found that posterior displacement of the fibula evaluated with radiostereometric analysis (RSA) was 2 to 3 times smaller than that found with conventional lateral radiographs. This difference was attributed to rotation and to the fact that displacements relative to the anterior and posterior sides were unequal. They concluded that conventional lateral radiographs were unreliable to evaluate posterior displacement. In our

**Table 2****Mean diastasis using MCS, TFCS, and DV with incremental ligament section using lateral stress.**

Ligament section	MCS, mm		TFCS, mm		DV, mm	
	Mean and SD	P value*	Mean and SD	P value*	Mean and SD	P value*
Intact	0.07 ± 0.75	–	0.50 ± 1.64	–	1.36 ± 0.69	–
AITFL	0.38 ± 1.12	.5146	1.00 ± 1.38	.3139	1.60 ± 0.89	.3139
AITFL+IOM	–0.12 ± 1.11	.5939	<b>1.34 ± 1.18</b>	<b>.0381</b>	<b>3.02 ± 1.43</b>	<b>.0077</b>
AITFL+IOM+PITFL	0.35 ± 1.00	.1730	<b>2.28 ± 1.40</b>	<b>.0208</b>	<b>3.80 ± 1.05</b>	<b>.0077</b>

\* P values shown represent diastasis difference from the intact ankle. Significant p value are bold.



**Figure 2.** Comparison of tibiofibular diastasis with DV and radiographic measurement of tibiofibular clear space and medial clear space as seen on a mortise radiograph with both external rotation and lateral stress tests.

cohort, observed displacement was approximately twice as large as radiographic displacement as it represented a combination of coronal, sagittal, and rotatory displacements. Ultimately, an intraoperative computed tomography scan would be ideal to evaluate reduction, but these are not readily available, generate additional radiation exposure, and can increase operative time.<sup>[24–27]</sup>

Several limitations exist with this study, which were inherent to its design. Our sample size was small which underpowers our results. However, our sample size corresponds to that of several other biomechanical studies pertaining to the syndesmosis.<sup>[4,5,11,18,24]</sup> Measurements for DV were taken during stress testing and thus could not be blinded. They were also collected by a single surgeon. This prevents us from being able to make any conclusion regarding the reproducibility of the test. However, measurements were collected in a systematic fashion using precise instruments to minimize the observation bias. Although specimens were immobilized during stress testing, it is possible that these forces caused some rotational variations on AP radiographs. Although the effect is likely minor, it is possible that this may have affected MCS and TFCS values. Despite the fact that multiple studies have advocated using lateral x-rays to evaluate sagittal fibular displacement,<sup>[2,11]</sup> we chose not to because they can be greatly affected by rotation.<sup>[18]</sup>

## 5. Conclusions

In conclusion, DV is more sensitive to syndesmotom instability than fluoroscopy, especially for incomplete injuries. Our findings confirmed that current fluoroscopic evaluation techniques when performed with intraoperative stress testing are suboptimal for diagnosing some syndesmosis injuries. Future studies might include the development of direct measurements by calipers that, when combined with DV, will allow for optimal treatment of these injuries.

## 6. Conflict of interest statement

Dominique M Rouleau is a consultant for Bioventus and Wright. Stéphane Leduc is a consultant for Stryker. The institution (Hôpital du Sacré-Coeur de Montréal) of all of the authors has received funding for research and educational purposes from: Arthrex, Conmed, Depuy, Linvatec, Smith & Nephew, Stryker, Synthes, Tornier, Wright, Zimmer.

## Acknowledgments

The authors wish to thank Kathleen Beaumont for providing manuscript review assistance.

## References

1. Ebraheim NA, Lu J, Yang H, et al. Radiographic and CT evaluation of tibiofibular syndesmotom diastasis: a cadaver study. *Foot Ankle Int.* 1997;18:693–698.
2. Xenos JS, Hopkinson WJ, Mulligan ME, et al. The tibiofibular syndesmosis. Evaluation of the ligamentous structures, methods of fixation, and radiographic assessment. *J Bone Joint Surg Am.* 1995;77:847–856.
3. Gill SL, Behman A, Cochrane LA, et al. The use and efficacy of intraoperative stress tests in supination-external rotation IV ankle fracture fixation. *Surgeon.* 2015;13:9–14.
4. Stoffel K, Wysocki D, Baddour E, et al. Comparison of two intraoperative assessment methods for injuries to the ankle syndesmosis. A cadaveric study. *J Bone Joint Surg Am.* 2009;91:2646–2652.
5. Jiang KN, Schulz BM, Tsui YL, et al. Comparison of radiographic stress tests for syndesmotom instability of supination-external rotation ankle fractures: a cadaveric study. *J Orthop Trauma.* 2014;28:e123–e127.
6. Matuszewski PE, Dombroski D, Lawrence JT, et al. Prospective intraoperative syndesmotom evaluation during ankle fracture fixation: stress external rotation versus lateral fibular stress. *J Orthop Trauma.* 2015;29:e157–e160.
7. Cherney SM, Spraggs-Hughes AG, McAndrew CM, et al. Incisura morphology as a risk factor for syndesmotom malreduction. *Foot Ankle Int.* 2016;37:748–754.
8. Miller AN, Carroll EA, Parker RJ, et al. Direct visualization for syndesmotom stabilization of ankle fractures. *Foot Ankle Int.* 2009;30:419–426.

9. Summers HD, Sinclair MK, Stover MD. A reliable method for intraoperative evaluation of syndesmotom reduction. *J Orthop Trauma*. 2013;27:196–200.
10. Jenkinson RJ, Sanders DW, Macleod MD, et al. Intraoperative diagnosis of syndesmosis injuries in external rotation ankle fractures. *J Orthop Trauma*. 2005;19:604–609.
11. Candal-Couto JJ, Burrow D, Bromage S, et al. Instability of the tibiofibular syndesmosis: have we been pulling in the wrong direction? *Injury*. 2004;35:814–818.
12. Joy G, Patzakis MJ, Harvey JPJr. Precise evaluation of the reduction of severe ankle fractures. *J Bone Joint Surg Am*. 1974;56:979–993.
13. Weening B, Bhandari M. Predictors of functional outcome following transsyndesmotom screw fixation of ankle fractures. *J Orthop Trauma*. 2005;19:102–108.
14. Lauge-Hansen N. Fractures of the ankle III. Genetic roentgenologic diagnosis of fractures of the ankle. *Am J Roentgenol Radium Ther Nuclear Med*. 1954;71:45.
15. Takao M, Ochi M, Naito K, et al. Arthroscopic diagnosis of tibiofibular syndesmosis disruption. *Arthroscopy*. 2001;17:836–843.
16. Takao M, Ochi M, Oae K, et al. Diagnosis of a tear of the tibiofibular syndesmosis. The role of arthroscopy of the ankle. *J Bone Joint Surg Br*. 2003;85:324–329.
17. Lui TH, Ip K, Chow HT. Comparison of radiologic and arthroscopic diagnoses of distal tibiofibular syndesmosis disruption in acute ankle fracture. *Arthroscopy*. 2005;21:1370.
18. Beumer A, Valstar ER, Garling EH, et al. External rotation stress imaging in syndesmotom injuries of the ankle: comparison of lateral radiography and radiostereometry in a cadaveric model. *Acta Orthop Scand*. 2003;74:201–205.
19. Chissell HR, Jones J. The influence of a diastasis screw on the outcome of Weber type-C ankle fractures. *J Bone Joint Surg Br*. 1995;77:435–438.
20. Pakarinen H, Flinkkilä T, Ohtonen P, et al. Intraoperative assessment of the stability of the distal tibiofibular joint in supination-external rotation injuries of the ankle: sensitivity, specificity, and reliability of two clinical tests. *J Bone Joint Surg Am*. 2011;93:2057–2061.
21. Lindsjo U, Danckwardt-Lilliestrom G, Sahlstedt B. Measurement of the motion range in the loaded ankle. *Clin Orthop Relat Res*. 1985;68–71.
22. Stark E, Tornetta PIII, Creevy WR. Syndesmotom instability in Weber B ankle fractures: a clinical evaluation. *J Orthop Trauma*. 2007;21:643–646.
23. Pakarinen HJ, Flinkkilä TE, Ohtonen PP, et al. Syndesmotom fixation in supination-external rotation ankle fractures: a prospective randomized study. *Foot Ankle Int*. 2011;32:1103–1109.
24. Ogilvie-Harris DJ, Reed SC, Hedman TP. Disruption of the ankle syndesmosis: biomechanical study of the ligamentous restraints. *Arthroscopy*. 1994;10:558–560.
25. Nault ML, Hébert-Davies J, Laflamme GY, et al. CT scan assessment of the syndesmosis: a new reproducible method. *J Orthop Trauma*. 2013;27:638–641.
26. Knops SP, Kohn MA, Hansen EN, et al. Rotational malreduction of the syndesmosis: reliability and accuracy of computed tomography measurement methods. *Foot Ankle Int*. 2013;34:1403–1410.
27. Elgafy H, Semaan HB, Blessinger B, et al. Computed tomography of normal distal tibiofibular syndesmosis. *Skeletal Radiol*. 2010;39:559–564.