

OPEN

Picosecond Infrared Laser (PIRL) Application in Stapes Surgery—First Experience in Human Temporal Bones

*Hannes Petersen, *Alexandra Gliese, *Yannick Stober, †Stephanie Maier, †Nils-Owe Hansen, †Sebastian Kruber, ‡Dennis Eggert, *Miklós Tóth, ||Tobias Gosau, ¶Hartmut Schlüter, §Klaus Püschel, ||Udo Schumacher, †Robert John Dwayne Miller, *Adrian Münscher, and #Carsten Dalchow

*Department of Otorhinolaryngology, Head & Neck Surgery and Oncology, University Medical Center Hamburg-Eppendorf; †Max Planck Institute for the Structure and Dynamics of Matter; ‡Heinrich-Pette-Institute, Leibniz Institute of Experimental Virology; §Department of Legal Medicine; ||Department of Anatomy and Experimental Morphology; ¶Department of Clinical Chemistry, University Medical Center Hamburg-Eppendorf, Hamburg; and #Department of Otorhinolaryngology, Klinikum Frankfurt Höchst, Frankfurt, Germany

Objective: Using a contact-free laser technique for stapedotomy reduces the risk of mechanical damage of the stapes footplate. However, the risk of inner ear dysfunction due to thermal, acoustic, or direct damage has still not been solved. The objective of this study was to describe the first experiences in footplate perforation in cadaver tissue performed by the novel Picosecond-Infrared-Laser (PIRL), allowing a tissue preserving ablation.

Patients and Intervention: Three human cadaver stapes were perforated using a fiber-coupled PIRL. The results were compared with footplate perforations performed with clinically applied Er:YAG laser. Therefore, two different laser energies for the Er:YAG laser (30 and 60 mJ) were used for footplate perforation of three human cadaver stapes each.

Main Outcome Measure: Comparisons were made using histology and environmental scanning electron microscopy (ESEM) analysis.

Results: The perforations performed by the PIRL (total energy: 640–1070 mJ) revealed a precise cutting edge with an intact trabecular bone structure and no considerable signs of coagulation. Using the Er:YAG-Laser with a pulse energy of 30 mJ (total energy: 450–600 mJ), a perforation only in the center of the ablation zone was possible, whereas with a pulse energy of 60 mJ (total energy: of 195–260 mJ) the whole ablation zone was perforated. For both energies, the cutting edge appeared irregular with trabecular structure of the bone only be conjecturable and signs of superficial carbonization.

Conclusion: The microscopic results following stapes footplate perforation suggest a superiority of the PIRL in comparison to the Er:YAG laser regarding the precision and tissue preserving ablation. **Key Words:** Laser surgery—Otosclerosis—Stapedotomy—Stapes surgery.

Otol Neurotol 39:e224–e230, 2018.

Address correspondence and reprint requests to Hannes Petersen, M.D., Department of Otorhinolaryngology, Head & Neck Surgery and Oncology, University Medical Center Hamburg-Eppendorf, Martinistr. 52, D-20246 Hamburg, Germany; E-mail: petersenhannes@icloud.com

H.P. and A.G. have contributed equally to this work and share the first authorship.

A.M. and C.D. do so concerning last authorship.

Funding: This study is part of the SUREPIRL project funded by an advanced grant from the European Research Council (ERC-AdG-2011–291630).

R.J.D.M. is cofounder of AttoDyne Inc (manufacturer of the PIRL system) and is the author of a patent related to the mechanism of PIRL laser ablation. All other authors declare no conflicts of interest. There has been no financial relationship with any sponsoring organization.

This is an open access article distributed under the terms of the Creative Commons Attribution-Non Commercial-No Derivatives License 4.0 (CCBY-NC-ND), where it is permissible to download and share the work provided it is properly cited. The work cannot be changed in any way or used commercially without permission from the journal.

DOI: 10.1097/MAO.0000000000001753

Since the stapedotomy was first described in the early 1970s, the technique has become a standard surgery for otosclerosis (1,2). Today incus stapedotomy by Fisch (3) is generally accepted as the standard operative procedure with less surgical trauma and fewer postoperative complications. However, over the years the surgical technique has improved. In addition to a wide range of stapes prostheses, different footplate fenestration methods have evolved with the aim to simplify the surgical procedure, reduce the duration of operation, and primarily decrease the intraoperative and postoperative complications.

Conventional techniques for footplate fenestration could be described as direct-contact methods, traditionally done by mechanical perforators or drills. Because of mechanical and acoustic trauma, there is a risk of footplate mobilization and inner ear damage resulting in

insufficient postoperative results, sensorineural hearing loss, tinnitus, or vertigo.

For this reason Perkins (4) described in 1980 the first use of laser technology to perform a precise footplate fenestration in a non-contact method with no risk of mechanical trauma. Since then, various laser techniques with different characteristics have been implemented for otologic surgery. In the past, several studies have demonstrated a superiority of laser stapedotomy compared with conventional techniques with less sensorineural hearing loss and vertigo (5–7). Therefore, many authors prefer laser above conventional methods for footplate fenestration in stapedotomy.

Today, argon, KTP, CO₂, and Er:YAG lasers are clinically used in stapes surgery. Each laser has its characteristic with its specific advantages and disadvantages, which are discussed in several experimental and clinical reports (8).

However, the risk of inner ear dysfunction due to thermal effects, acoustic shock, pressure fluctuation of the perilymph, and laser penetration with damage to the neuro-endothelium have not been completely resolved (9–13).

Due to a low absorption of energy in water both the argon and KTP laser have a high penetration depth within the perilymph and subsequently a theoretical risk of inner ear damage by a direct impact of laser energy (14,15). However, in the past several studies have demonstrated good postoperative results with no significant inner ear damage (16–18). Hence both, the argon and the KTP laser are widely used lasers for stapedotomy.

The CO₂ laser does not have a high penetration depth into the perilymph, but heat is produced during CO₂-laser ablation with a risk of thermal injury to inner ear structures (19).

The Er:YAG laser targets the peak absorption of water around 3 μm. Tissue with high water content can be ablated precisely with no or minimal thermal effect to the inner ear (10). Several clinical studies have demonstrated the feasibility and efficiency of the Er:YAG laser in stapes surgery (20). However, at the same time, the Er:YAG laser produces acoustic shock waves causing explosive ablation of bone and generates a shockwave through the inner ear, which can potentially harm inner ear function (10,21).

Recently the research group of R.J.D.M. demonstrated a method to convert matter of a liquid or solid aggregate phase directly into a gaseous aggregate phase by using an innovative Mid-IR picosecond laser (22). The complete confinement of the deposited energy inside the ablation volume is ensured by a physical process denoted as desorption by impulsive vibrational excitation (DIVE). No significant amount of energy is transferred to the surrounding tissue, neither in thermal form nor by acoustic shockwaves or by ionizing radiation. During DIVE ablation, an ultrafast laser pulse is used to selectively excite the strongly absorbing vibrational O-H stretching modes of water molecules located in the tissue on a time scale faster than their thermalization time. Using the picosecond infrared laser (PIRL) system that emits 400 ps pulses at 1 kHz repetition rate and 3 μm

wavelength, the water molecules inside the irradiated tissue are converted into the gas phase on a picosecond time scale. The entire ablation process takes place before nucleation and cavitation effects within the ablation zone can occur. In addition, the effective frequency of any thermally excited acoustic modes is in the GHz range, which are attenuated within micron propagation distances such that all the laser energy is confined to the region of interest with the minimum energy required to drive the ensuing ablation and material removal (23–25).

Initial applications of the novel PIRL-scalpel have shown a reduction of collateral damage zones in both soft and densely calcified tissue (26,27). Due to the mentioned characteristics the PIRL has great potential for advancing techniques and outcomes in otologic surgery.

This article describes for the first time the use of the PIRL in stapes surgery to perform footplate perforation on human cadaver tissue using conventional histology and environmental scanning electron microscopy. In addition, comparisons between PIRL and Er:YAG laser footplate perforation were conducted.

MATERIALS AND METHODS

This study was approved by the local ethics committee (Licence-No. PV4236, ‘‘Ethical Commission of the Medical Association Hamburg’’). Nine human stapes were investigated to determine the feasibility of different laser application techniques for laser-stapedotomy, the microscopic and histologic quality of the perforation, and the reproducibility of the perforation effect.

Laser Settings

A prototype picosecond infrared laser (PIRL-III-3000, Atto-dyne Inc, Toronto, Canada) and commercial Er:YAG Laser (MEY-1-A EX-2, J Morita Mfg Corp, Kyoto, Japan) were used for footplate perforation. The PIRL and Er:YAG Laser had pulse widths of 400 ps and 300 μs, respectively, both emitting approximately Gaussian shaped beams at 2.94 μm (Er:YAG) and 3000 ± 90 nm (PIRL).

The PIRL output has been coupled on to a sapphire multi-mode fiber (Photran, LLC, Poway, CA) with a 250 μm fiber core diameter and a length of approximately 1 m. The average laser pulse energy of the fiber output was 0.330 mJ 1 kHz repetition rate. For 1 second of laser application that was used in this study as described below, the integrated energy thus amounts to 330 mJ. Sapphire fibers are very suitable for medical applications, because Sapphire fibers are not only autoclavable, biologically inert, but also have a very high damage threshold in the infrared region (28). In preparation of the experiment the end faces of the sapphire fibers were polished with diamond fiber polishing films with a grid size of 1 μm.

The Er:YAG Laser output was coupled to hand piece with a 600 μm diameter glass fiber tip (C800F, J Morita Corp; Kyoto, Japan). For the footplate perforation two different pulse energies were set up with a pulse frequency of 1 Hz in both adjustments. Thereby in one group the average pulse energy was 30 mJ and in the other group the used energy was 60 mJ, corresponding to a fluence of 10 and 22 J/cm². The deposited energy per second for the Er:YAG laser applications amounted to 30 and 60 mJ, respectively. The pulse energies were measured before every surgical procedure for 60 seconds with the energy meter (Energy

Max Sensor J-25MB-LE, Coherent, Santa Clara, CA) for the PIRL and the energy meter (Energy Max Sensor J-50MB-IR, Coherent, Santa Clara, CA) for the Er:YAG.

Surgical Procedure

In total nine human cadaver temporal bones were prepared and stored in 4% formalin. On each temporal bone the stapes suprastructures, the tendon of the stapedius muscle as well as the footplate were prepared to ensure a clear view to the anterior part of the footplate.

Appropriate to the two different lasers and the above-mentioned laser set ups, the temporal bones were divided into three groups. Thereby, three perforations were performed with the PIRL fiber. The remaining six preparations were used for stapedotomy with the two different Er:YAG laser set ups. In the group E1 the perforation was set with an average pulse energy of 30 mJ on three stapes footplates and in group E2 with 60 mJ on another three stapes footplates.

For all methods mentioned above, the duration of laser application was defined as 1 second and controlled by a time switch. The amount of required seconds/pulses to perform a footplate perforation was documented in each case. Thereby the surgical procedure was completed when the perforation diameter reached the beam and fiber diameter, respectively, or when no changes of the perforation diameter could be observed after repeated laser application (maximum of two repetitions).

Analysis of Tissue Effects

Following laser ablation and isolation of the stapes, tissues were kept in 10% phosphate buffered saline at 4 °C for 24 hours. Topographical unstained ESEM images were then obtained with a Phillips XL30 (FEI, Hillsboro, OR) system using a solid state backscattered electron (BSE) detector at a water vapor pressure of 1.5 Torr, spot size of 5, and an acceleration voltage of 20 kV. The DISS5 digital image scanning system (Point Electronic, Halle, Germany) was used for image acquisition. The perforation was photo-documented at different magnifications. The dimension and shape of the perforation, the quality of the tissue ultra-structure, presence of carbonization, and presence of microfractures were recorded.

Following ESEM all stapes were decalcified for histological assessment. For decalcification each sample was prepared in 10% ethylenediaminetetraacetic acid (EDTA) for 24 hours and subsequent in 70% propanol for 12 hours. The decalcified samples were then embedded in paraffin, cut into 4 µm sections, and stained with hematoxylin and eosin (H.E.). Histological examination was conducted using a Zeiss AxioPlan 2 Microscope System (Carl Zeiss Microscopy GmbH, Jena, Germany). Images

of the perforation margins were captured using a Zeiss AxioCam MRc 5 and Axiophot 2 (Carl Zeiss Microscopy GmbH, Jena, Germany). For histological interpretation, the destruction zone, and here predominantly laser coagulation effects and tissue integrity on the cellular level, were microscopically evaluated. In addition, the shape of the perforation margin was described.

RESULTS

Tissue Effects After Fenestration With PIRL Fiber

Respectively 2, 3, and 3 seconds (PF-1–3) were needed for footplate perforation in the three cases in Table 1. This corresponds to a total energy of 646, 1071, and 927 mJ, respectively.

The ESEM images of the PIRL fiber ablation confirmed the aforementioned impressions (Fig. 1). The perforations had a smooth round shape with a diameter of 330, 330, and 200 µm, respectively. The edges were straight and precise. The immediate surrounding area of the perforations showed a slightly loosened mucosa. Damage to the bone was not observed. At the cut surface, an intact trabecular bone structure without considerable signs of coagulation of the compacta or the spongiosa was visible, showing that PIRL did not coagulate, nor extensively disrupt tissues.

HE staining of the footplate perforations revealed a clean and unruffled cut edge with no significant damage to the surrounding tissue (Fig. 1). There were no signs of carbonization.

Tissue Effects After Fenestration With Er:YAG Laser 30 mJ

Using the Er:YAG 600 µm glass fiber and applying 30 mJ per pulse, 15 pulses were needed for footplate perforation in two cases (Table 1). In one case, 20 pulses of 30 mJ per pulse were necessary. This corresponds to a total energy of 600, 450, and 450 mJ, respectively.

On the ESEM images the trabecular structure of the bone is visible. The images further revealed that the compacta at the cutting edge was vaporized irregularly so that the spongiosa was ablated at different levels giving an irregular appearance of the cut surface (Fig. 2). Thereby, the diameters of the total ablation zone were 890, 610, and 680 µm, respectively. However, the actual perforations had diameters of 450, 260, and 450 µm, respectively.

TABLE 1. Applied laser systems and parameters

Instrument	ID	Pulse Energy (mJ)	Pulse Duration (µs)	Frequency (Hz)	Amount of Pulses	Fluence (J/cm ²)	Total Energy (mJ)
PIRL (250 µm)	PF-1	0.323	0.0004	1,000	2,000	0.7	646
	PF-2	0.357	0.0004	1,000	3,000	0.7	1,071
	PF-3	0.309	0.0004	1,000	3,000	0.6	927
Er:YAG (600 µm)	Er30–1	30	300	1	20	10	600
	Er30–2	30	300	1	15	10	450
	Er30–3	30	300	1	15	10	450
Er:YAG (600 µm)	Er60–1	60	300	1	3	22	195
	Er60–2	60	300	1	3	22	195
	Er60–3	60	300	1	4	22	260

PIRL indicates Picosecond-Infrared-Laser.

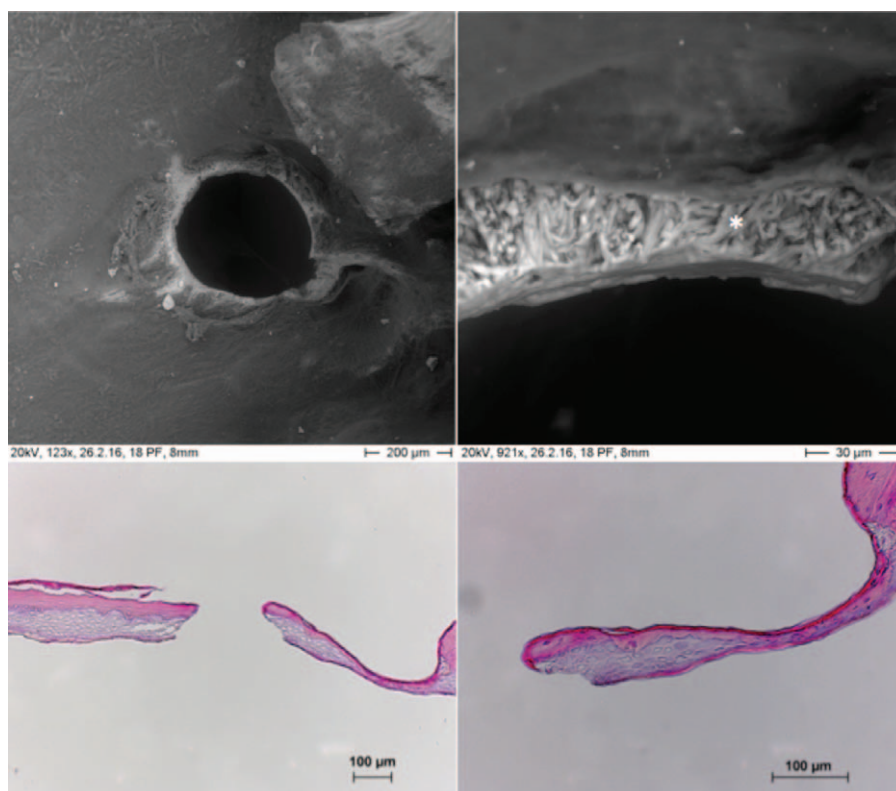


FIG. 1. ESEM image and HE staining of a stapes footplate perforation produced by PIRL: precise ablation edge with no significant damage to surrounding tissue. Compacta and spongiosa of the stapes had remained intact and are clearly visible (*asterisk*). ESEM indicates environmental scanning electron microscopy.

Under the light microscope, the perforation margins were clean and unruffled, but the edges became thinner toward the center of the holes (Fig. 2). Mild but no significant carbonization formations were seen.

Tissue Effects After Fenestration With Er:YAG Laser 60 mJ

Applying 60 mJ per pulse, three pulses for footplate perforation were needed in two cases and four pulses in one case (Table 1). This corresponds to a total energy of 195, 195, and 260 mJ, respectively.

The ESEM images showed rough edges resulting in irregular perforation margins (Fig. 3). The perforations had a diameter of around 600, 650, and 480 μm , respectively.

HE staining showed lacerated and irregular perforation margins (Fig. 3). Superficial carbonization was visible at the edges.

DISCUSSION

This study describes the first experiences in footplate perforation in cadaver tissue performed by PIRL. The results were compared with footplate perforations performed with clinically applied Er:YAG laser.

The pulse energy for Er:YAG laser used for stapedotomy ranges from 10 to 450 mJ in the literature (20,29).

The upper limit of pulse energy differs between authors. A pulse energy of 60 mJ has been described by Lippert et al. (30) as the optimal energy for footplate perforation. Another set of experiments showed that a single Er:YAG laser shot should not exceed 35 mJ and the total energy should not exceed 400 mJ to avoid inner ear damage (31,32).

According to the literature we used and analyzed a pulse energy for the Er:YAG laser of 30 and 60 mJ to perform a footplate perforation with the Er:YAG laser (10,30,31).

The footplate perforation performed by 30 mJ pulse energy, in all three cases, led to an incomplete and imprecise perforation with perforation-diameters of 260 and 450 μm in comparison to the diameter of the used fiber (600 μm). A total amount of 15 to 20 pulses was needed. The total amount of energy added up to 450 and 600 mJ.

The results of the microscopy of the Er:YAG samples presume that the laser energy was not evenly distributed over the acting surface. The energy to the periphery did not seem to be sufficient, it rather damaged the tissue instead of ablating it.

Although 30 mJ equates the recommended pulse energy by Szyfter et al. (31) and Hausler et al. (10), results of the perforation were unsatisfactory. In addition, the total energy in all three samples was beyond the

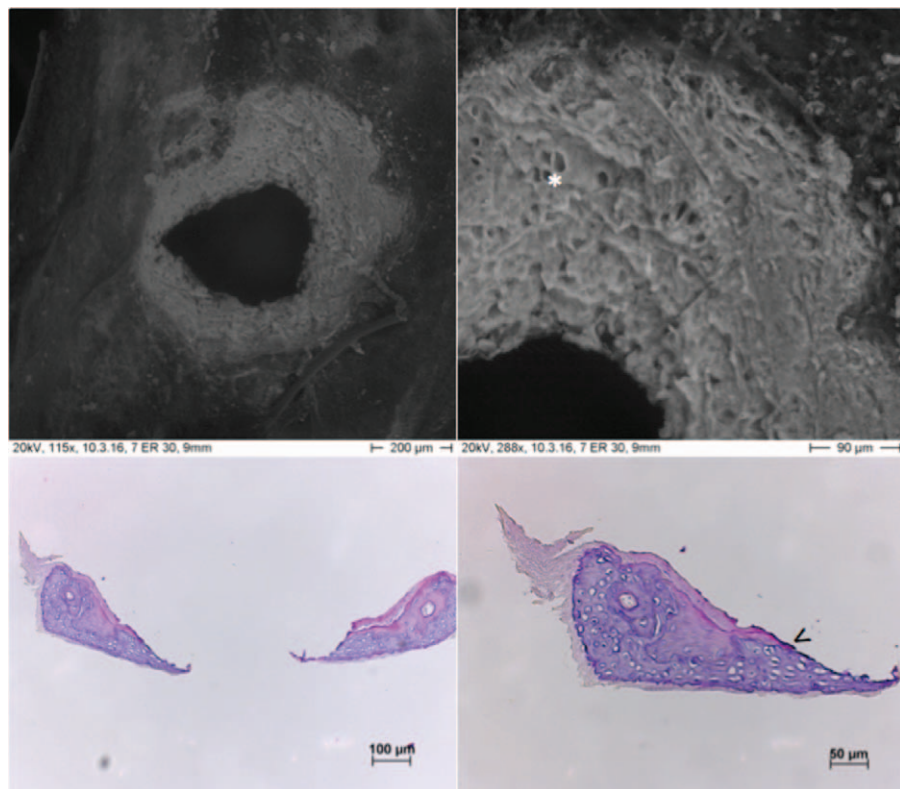


FIG. 2. ESEM image and HE staining of a stapes footplate perforation produced by an Er:YAG laser (puls energy: 30 mJ): imprecise ablation edge with a disproportion between the ablation zone and perforation. The structure of the trabecular bone is conjecturable. The lacunae are clearly visible (*asterisk*). In the histology there are mild signs of superficial carbonization (*arrow head*). ESEM indicates environmental scanning electron microscopy.

recommended total energy of 400 mJ to avoid inner ear damage (31,32). Hence in this study, we cannot conclude that the risk of inner ear damage could be reduced by using 30 mJ pulses.

The footplate perforation performed by 60 mJ pulse energy led to complete perforations and an adequate size of 480 to 650 μm . Additionally, not more than three to four pulses were needed and the total amount of energy did not exceed the recommended 400 mJ (31). The results of the microscopy reveal that the energy was sufficient to perforate the footplate in areas almost covering the complete fiber tip—tissue interaction area. However, the light microscopy as well as ESEM shows disordered edges and superficial carbonization as a sign of tissue traumatization.

Although 60 mJ has been proven by Lippert et al. (30) as the optimal energy for footplate perforation, there is evidence that a fluence of 10 to 17 J/cm² produces pressure waves within the inner ear between 140 and 160 dB leading to transitory acoustic traumatization (10).

The equivalent fluence for 60 mJ was 22 J/cm² in this study (Table 1). Hence both, the microscopic findings, as well as the relatively too high fluence, leads to the conclusion that a pulse energy of 60 mJ by Er:YAG laser is inappropriate for stapes surgery.

The hypothesis in the use of PIRL in stapedotomy is that due to the high absorption by water and ultrafast ablation completely confines the laser energy such that there is minimal energy penetration into the inner ear with minimal traumatization by direct impact of laser energy. The PIRL is similar to the Er:YAG laser in terms of absorption length and penetration depth, but significantly different in terms of ablation plume dynamics. Therefore, with PIRL, no damage due to tissue transported shock waves is expected and damage due to air transported shockwaves is also expected to be negligible because the involved energy densities are low compared with literature values for other laser ablation experiments.

In addition, ex vivo soft tissue incisions made with PIRL have demonstrated nearly complete absence of thermal injury compared with CO₂ laser incisions (33,34), which explains our finding that the surrounding structures were unaltered after PIRL application. Infrared thermography has shown that ablation of cortical bone using the PIRL generates significantly less heat than Er:YAG laser ablation. The surface temperature rises with PIRL was 2 °C compared with 13 °C with Er:YAG laser (35).

Our findings are further reinforced by observation in other tissues: wound healing studies have shown that the

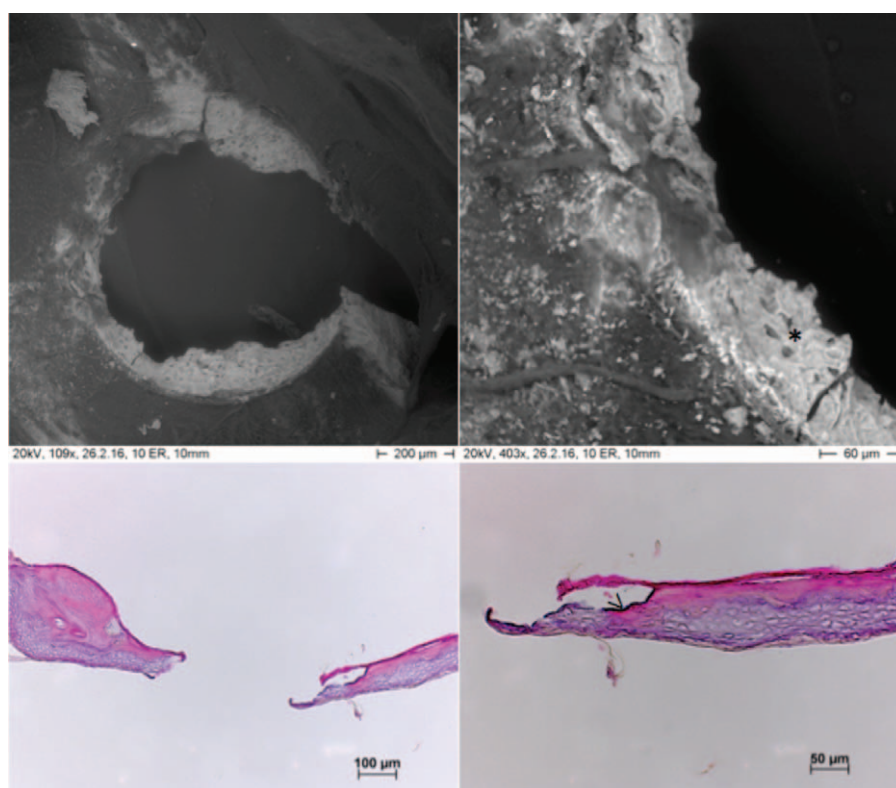


FIG. 3. ESEM image and HE staining of a stapes footplate perforation produced by an Er:YAG laser (puls energy: 60 mJ): irregular ablation edge with lacunae of the trabecular bone visible (*asterisk*). Histologically the perforation edge appears lacerated with superficial carbonization (*arrow heads*). ESEM indicates environmental scanning electron microscopy.

wounds created by the PIRL showed a significantly less scar formation in the skin as compared with those created using the Er:YAG laser, electrocautery, or scalpel (26,36).

Footplate perforation with the PIRL laser required a higher total energy than with Er:YAG laser in this study. Due to the above mentioned physical characteristics of the PIRL and especially the low per pulse energy, no detrimental effects—like accumulation of damage linearly dependent on total energy—connected to this are to be expected however.

The higher integrated energy used in case of the PIRL application cases drives ablation and vaporization and does not lead to collateral damage via energy loss to surrounding tissue. In contrast, with lower total energies in case of the Er:YAG application cases, detrimental effects that become more pronounced with increased energies are found.

The diameter of the fiber used for the PIRL ablation was only 250 μm and the maximal produced fenestration-diameter only 330 μm . Given that the shaft of a stapes prosthesis has at least 400 μm , further development is necessary to evaluate the required fiber characteristics. Sapphire fibers up to a diameter of 500 μm are available for further experiments, and pulse energies between 1 and 2 mJ are required to achieve fluences in the range of 0.5 to 1 J/cm^2 comparable to the fluences used in the PIRL

experiments. With a new laser design envisioned that makes use of a straight forward approach to directly amplify 3 μm laser radiation, pulse energies in the range of 1 to 2 mJ are within reach and the necessary fenestration-diameter for the stapes prosthesis could be achieved.

CONCLUSION

This study for the first time describes the use of the PIRL for stapedotomy in human cadaver tissue. The results of examinations using electron microscopy and histological examinations with the light microscope suggest a clear superiority of the PIRL in comparison to the Er:YAG laser regarding the procedure's outcomes. From the present study, considering the characteristics of the PIRL in connection with the available literature data, we conclude that this novel laser system could potentially be the solution to previous problems found with laser stapedotomy. However, further studies are necessary to directly prove the nontraumatic character of the PIRL laser ablation to the inner ear structures.

REFERENCES

1. Shea JJ Jr. The teflon piston operation for otosclerosis. *Laryngoscope* 1963;73:508–9.
2. Häusler R. General history of stapedectomy. *Adv Otorhinolaryngol* 2007;65:1–5.

3. Fisch U. *Tympanoplasty, Mastoideotomy, and Stapes Surgery*. Stuttgart: Georg Thieme; 1994.
4. Perkins RC. Laser stapedotomy for otosclerosis. *Laryngoscope* 1980;90:228–41.
5. Garin P, Van Prooyen-Keyser S, Jamart J. Hearing outcome following laser-assisted stapes surgery. *J Otolaryngol* 2002;31:31–4.
6. Fang L, Lin H, Zhang TY, et al. Laser versus non-laser stapedotomy in otosclerosis: a systematic review and meta-analysis. *Auris Nasus Larynx* 2014;41:337–42.
7. Motta G, Moschillo L. Functional results in stapedotomy with and without CO₂ laser. *ORL J Otorhinolaryngol Relat Spec* 2002;64:307–10.
8. Frenz M. Physical characteristics of various lasers used in stapes surgery. *Adv Otorhinolaryngol* 2007;65:237–49.
9. Arnoldner C, Schwab B, Lenarz T. Clinical results after stapedotomy: a comparison between the erbium: Yttrium-Aluminum-Garnet Laser and the conventional technique. *Otol Neurotol* 2006;27:458–65.
10. Häusler R, Schar PJ, Pratisto H, et al. Advantages and dangers of erbium laser application in stapedotomy. *Acta Otolaryngol* 1999;119:207–13.
11. Jovanovic S, Schönfeld U, Fischer R, et al. Thermic effects in the “vestibule” during laser stapedotomy with pulsed laser systems. *Lasers Surg Med* 1998;23:7–17.
12. Kiefer J, Tillein J, Ye Q, et al. Application of carbon dioxide and erbium:yttrium-aluminum-garnet lasers in inner ear surgery: an experimental study. *Otol Neurotol* 2004;25:400–9.
13. Pratisto H, Frenz M, Ith M, et al. Temperature and pressure effects during erbium laser stapedotomy. *Lasers Surg Med* 1996;18:100–8.
14. Lesinski SG. Lasers for otosclerosis—which one if any and why. *Lasers Surg Med* 1990;10:448–57.
15. Lesinski SG, Palmer A. Lasers for otosclerosis: CO₂ vs. Argon and KTP-532. *Laryngoscope* 1989;99 (Suppl):1–8.
16. Timoshenko AP, Oletski A, Prades JM, et al. A comparison of the hearing results of KTP and Erbium YAG laser stapedotomy. *Acta Otolaryngol* 2009;129:217–9.
17. Buchman CA, Fucci MJ, Roberson JB Jr, et al. Comparison of argon and CO₂ laser stapedotomy in primary otosclerosis surgery. *Am J Otolaryngol* 2000;21:227–30.
18. Stucken EZ, Brown KD, Selesnick SH. The use of KTP laser in revision stapedectomy. *Otol Neurotol* 2012;33:1297–9.
19. Li ZZ, Reinisch L, Van de Merwe WP. Bone ablation with Er:YAG and CO₂ laser: study of thermal and acoustic effects. *Lasers Surg Med* 1992;12:79–85.
20. Szyfter W, Mielcarek-Kuchta D, Mitkiewska-Leszniwska D, et al. Comparison between 2 laser systems, Er-Yag and CO₂, in stapes surgery. *Otol Neurotol* 2013;34:29–35.
21. Kamalski DMA, Wegner I, Tange RA, et al. Outcomes of different laser types in laser-assisted stapedotomy: a systematic review. *Otol Neurotol* 2014;35:1046–51.
22. Siwick BJ, Dwyer JR, Jordan RE, et al. An atomic-level view of melting using femtosecond electron diffraction. *Science* 2003;302:1382–5.
23. Franjic K. *Studies of Laser Ablation of Liquid Water Under Conditions of Impulsive Heat Deposition Through Vibrational Excitations (IHDVE)*. Department of Physics, University of Toronto; 2010.
24. Franjic K, Miller D. Vibrationally excited ultrafast thermodynamic phase transitions at the water/air interface. *Phys Chem Chem Phys* 2010;12:5225–39.
25. Franjic K, Cowan ML, Kraemer D, et al. Laser selective cutting of biological tissues by impulsive heat deposition through ultrafast vibrational excitations. *Opt Express* 2009;17:22937–59.
26. Petersen H, Tavakoli F, Kruber S, et al. Comparative study of wound healing in rat skin following incision with a novel picosecond infrared laser (PIRL) and different surgical modalities. *Lasers Surg Med* 2016;48:385–91.
27. Jowett N, Wollmer W, Reimer R, et al. Bone ablation without thermal or acoustic mechanical injury via a novel picosecond infrared laser (PIRL). *Otolaryngol Head Neck Surg* 2014;150:385–93.
28. Waynant RW, Ediger MN, Fink M. Infrared optical fibers for surgical applications. *J Laser Appl* 1990;2:45–9.
29. Keck T, Wiebe M, Rettinger G, et al. Safety of the Erbium:Yttrium-Aluminum-garnet laser in stapes surgery in otosclerosis. *Otol Neurotol* 2002;23:21–4.
30. Lippert BM, Gottschlich S, Kulkens C, et al. Experimental and clinical results of Er:YAG laser stapedotomy. *Lasers Surg Med* 2001;28:11–7.
31. Szyfter W, Mielcarek-Kuchta D, Miętkiewska-Leszniwska D, et al. Long-term results of the Er-Yag laser used in stapes surgery. *Eur Arch Otorhinolaryngol* 2015;272:61–75.
32. Parrilla C, Galli J, Rita Fetoni A, et al. Erbium: yttrium-aluminum-garnet laser stapedotomy—a safe technique. *Otolaryngol Head Neck Surg* 2008;138:507–12.
33. Bottcher A, Clauditz TS, Knecht R, et al. A novel tool in laryngeal surgery: preliminary results of the picosecond infrared laser. *Laryngoscope* 2013;123:2770–5.
34. Hess M, Hildebrandt MD, Muller F, et al. Picosecond infrared laser (PIRL): an ideal phonomicrosurgical laser? *Eur Arch Otorhinolaryngol* 2013;270:2927–37.
35. Jowett N, Wöllmer W, Mlynarek AM, et al. Heat generation during ablation of porcine skin with erbium:YAG laser vs a novel picosecond infrared laser. *JAMA Otolaryngol Head Neck Surg* 2013;139:828–33.
36. Amini-Nik S, Kraemer D, Cowan ML, et al. Ultrafast mid-IR laser scalpel: protein signals of the fundamental limits to minimally invasive surgery. *PLoS ONE* 2010;5:e13053.