

CASE REPORT

Management of dermatofibrosarcoma protuberans of the face using lower trapezius musculocutaneous pedicle flap reconstruction: a case report

Wahid Terro^{1,2,3,*}, Nizar Hamadeh⁴, and Miray Terro⁵

¹Oral & Maxillofacial Surgery Division, Dental School, Tutor Beirut Arab University (BAU), Beirut, Lebanon,

²Dept. Oral & Maxillofacial Surgery, Dental School, Chief of Clinic Lebanese University (LU), Beirut, Lebanon,

³Cardiff University of Wales, College of Medicine, London, UK, ⁴ENT (Head and Neck), Maxillofacial and Plastic Esthetic, Paris, France, and ⁵Implantology (Cambridge Academy, UK), Dental School, Beirut Arab University (BAU), Beirut, Lebanon

*Correspondence address. Elena Maxillofacial Surgery Clinic Ashrafiya, Sodeco Score Area, Sama Beirut Tower, 10th Floor, Beirut, Lebanon, Tel: +961-1-303742 (Clinic), +961-1-429779 (Clinic), +961-3-231862 (Mobile); Fax: +961-1-303742, +961-1-429779; E-mail: vratchesurgeon@hotmail.com

Abstract

Dermatofibrosarcoma protuberans (DFSP) is a rare neoplasm which represents <0.1% of all tumors but it is considered the most common skin sarcoma. It is a slow-growing tumor that arises from the dermis and invades deeper tissues. The precise origin of DFSP is not well known. It is most frequently seen on the trunk, extremities, and head and neck. The standard treatment of the localized huge DFSP consists of a wide local surgical resection with recommended surgical margins of 2–3 cm. Local recurrence after incomplete excision is common. We present a case of 35-year-old man with enormous bulky mass on the face. Upon histological examination, the diagnosis of DFSP was made, and the patient underwent en bloc wide local excision of the mass followed by the use of Trapezius musculocutaneous pedicle flap reconstruction. On 32 months follow-up, no recurrence has been reported.

INTRODUCTION

Dermatofibrosarcoma protuberans (DFSP) is a very rare neoplasm of the dermis layer of the skin and is classified as a cutaneous soft tissue sarcoma [1]. The etiology of DFSP is not well known [2]. Scars caused by dermal burns, surgery or vaccination might increase the risk for developing DFSP [3]. DFSP tends to grow gradually and may initially present as a painless, skin-colored plaque with probable reddish brown or blue discoloration [2]. At later stages, it can increase in size and become protuberant [3, 4]. It usually appears in adults (25–50 years), but

has been diagnosed in people of all ages and afflicts both sexes nearly equally [5].

DFSPs are mainly found on the trunk and the proximal extremities and at low percentage in the head and neck region [6].

Noteworthy, DFSP is often mistaken for other skin conditions such as lipomas, epidermal cysts and keloids in its early stages and for pyogenic granuloma and kaposi sarcoma in its later stages [7]. Tests and procedures used to diagnose DFSP comprise of clinical examination (incl. size and mobility), imaging tests (MRI to evaluate the tumor extent within the

Received: February 1, 2018. Accepted: May 3, 2018

Published by Oxford University Press and JSCR Publishing Ltd. All rights reserved. © The Author(s) 2018.

This is an Open Access article distributed under the terms of the Creative Commons Attribution Non-Commercial License (<http://creativecommons.org/licenses/by-nc/4.0/>), which permits non-commercial re-use, distribution, and reproduction in any medium, provided the original work is properly cited. For commercial re-use, please contact journals.permissions@oup.com

tissues and a CT scan to indicate bone invasion), and biopsy [8, 9]. Histological examination is the only definitive diagnostic method.

Treatment of choice for DFSP is wide local excision with negative margins of 3 cm from the tumor border (including the underlying skin, the subcutaneous tissue and fascia); and includes the periosteum or even a part of the bone in more complex cases [8]. One alternative to surgical resection is Mohs micrographic surgery with maximal conservation of tissue [8, 9]. Distant metastasis, however, is rarely reported [4].

CASE REPORT

A 35-year-old Syrian refugee presented with a large protuberant mass located on his face (Fig. 1). The patient reported an increase in the size of the tumor over the preceding 5 months and no changes following a drained incision of misdiagnosed facial abscess. He denied any recent, fever, night sweats and weight loss.

Upon physical examination, a large, firm, painless, unimodular mass measuring ($10 \times 8 \times 4 \text{ cm}^3$) was found on the left facial skin with non healed incision in the middle of the mass and with no sign of localized redness (Fig. 1). No palpable cervical or axillary lymph nodes were noticed.

Considering a possible diagnosis of a facial tumor, the patient underwent an incisional biopsy specimen. Based on the histological findings, the diagnosis of DFSP was made. MRI of the head and neck was performed showing a vascularized tumor. The patient was informed about the treatment plan which comprised of a surgical excision and reconstructive surgery. Upon approval of the treatment plan, a consent form was obtained. On 16 June 2015, under general anesthesia, en bloc excision of the mass with 3 cm margins was performed and a wound dress was applied. A final pathology review was employed to confirm negative margins (Figs 2 and 3). According to the report, no tumor cells were observed.

Day 14 postoperative, given the size of the resulted defect and inability to adequately rotate local tissue, a lower trapezius musculocutaneous (LTMC) pedicle flap from the back was deployed (Figs 4 and 5). No further adjuvant therapy was required.

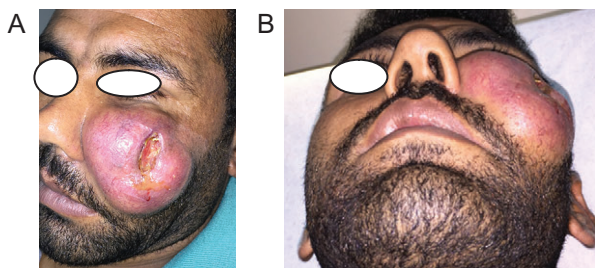


Figure 1: (A and B) A large protuberant mass located at the left side of the face of a 30-year-old Syrian refugee with skin laceration at the middle of the lesion.

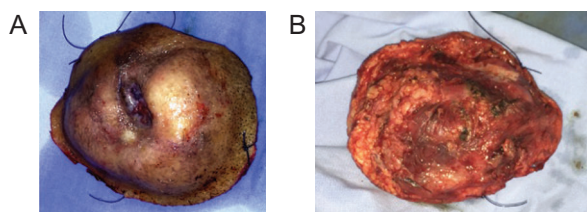


Figure 2: En bloc excision. Macroscopic appearance of the surgical specimen is that of a large tumor ($10 \times 8 \times 4 \text{ cm}^3$). (A) From outside view. (B) From inside view.

Day 42 postoperative, the flap was completely healed and succeeded in covering the defect (Fig. 6). The range of movement of the neck was limited with minimal medial-lateral rotation. A physical therapy and rehabilitation program was prescribed. After 2 months of intensive exercise, the performance of the neck improved.

At 7 weeks, the donor site was completely healed (Fig. 7). At 32 months follow-up, clinical examination showed no signs of recurrence and the patient was actively using his neck.

DISCUSSION

DFSP is a rare malignant dermal tumor that originates from the dermis. The tumor accounts for <0.1% of all malignancies and

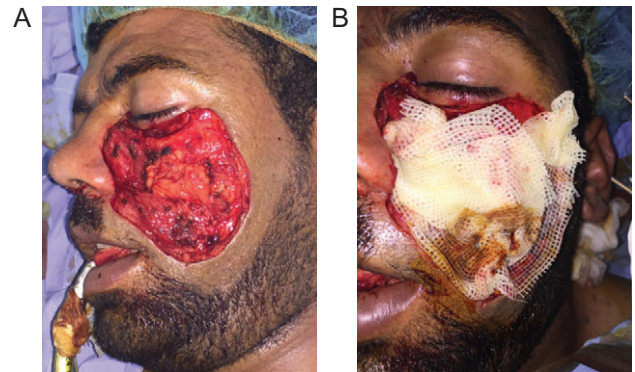


Figure 3: (A) Postoperative defect in the left cheek region. Bone exposure is well noticed. (B) The surgical field with a wound dress (16 June 2015).

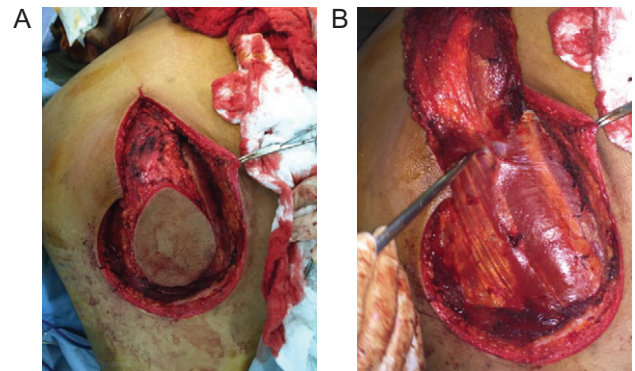


Figure 4: (A) Marking of the LTMC pedicle flap planning on the back. (B) Elevated flap as a distant pedicle flap. (30 June 2015).

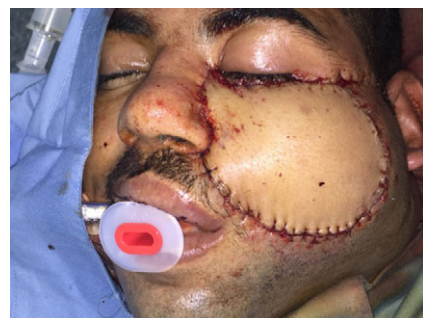

Figure 5: The LTMC pedicle flap was completely covered the postsurgical defect (30 June 2015).

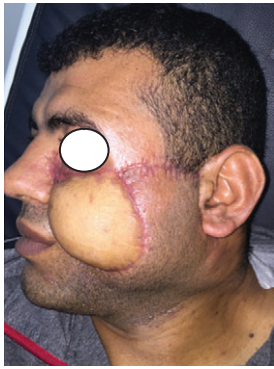

Figure 6: Postoperative view of the well healed LTMC distant pedicle flap. Note the slightly depressed of the left lower eyelid (12 August 2015).

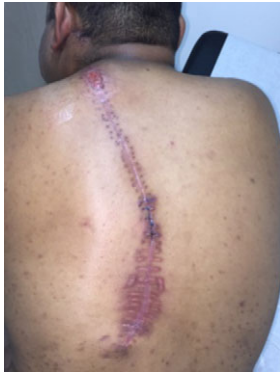

Figure 7: Completely healed state of the donor site with secondary intention for 2 months.

for ~1% of all soft tissue sarcomas. The average tumor size has been reported to be ≤ 5 cm and tumors of 10 cm or more are extremely rare [2, 4].

The conventional treatment of huge DFSP (more than 5 cm) is radical wide local surgical excision—en bloc removal with abolition of 2–3 cm of uninvolved skin including the underlying subcutaneous tissue and fascia, and can extend to involve even muscle tissue if necessary to attain negative intact borders—with a recurrence rate of 8.8% (3). An alternative to extensive surgical resection is Mohs micrographic surgery with a recurrence rate of 1.5% (4, 8 and 9). Other types of treatment include radiation and targeted therapy [8–10]. In this report, the $10 \times 8 \times 4$ cm³-sized tumor was entirely removed via en bloc wide local excision with margins of 3 cm. The excision included some branches of the facial nerve yet avoided the intraoral communication and the underlying bones, namely, the zygomatic bone. No further adjuvant therapy was necessary.

The use of local flaps to cover the resulted extensive post-surgical field was inappropriate. As such, the use of the

extended LTMC pedicle flap for facial reconstruction was the best treatment of choice as it covered up all the area and facilitated wound healing. LTMC pedicle flap's enormous arc of rotation allows its application for the immediate or late reconstruction of massive deformities following resection of tumors of the face. Moreover, it helps avoid major morbidity normally associated with such resections. In our case, histological assessment was the ultimate diagnostic means to confirm the diagnosis of DFSP. MRI was used to reveal the expansion. There was no evidence of recurrence after 32 months.

Wide local en bloc excision with at least 3 cm surgical margins in conjunction with the use of the LTMC pedicle flap is the most suitable surgical method for treating huge DFSP on the face and is highly recommended in similar cases. Long-term follow-up is crucial for detecting future recurrence.

CONFLICT OF INTEREST STATEMENT

None declared.

REFERENCES

1. Eguzo K, Camazine B, Milner D. Giant dermatofibrosarcoma protuberans of the face and scalp: a case report. *Int J Dermatol* 2014;53:767–72.
2. Bhambri S, Desai A, Del Rosso JQ, Mobini N. Dermatofibrosarcoma protuberans: a case report and review of the literature. *J Clin Aesthet Dermatol* 2008;1:34–6.
3. McArthur G. Dermatofibrosarcoma protuberans: recent clinical progress. *Ann Surg Oncol* 2007;14:2876–86.
4. Criscione VD, Weinstock MA. Descriptive epidemiology of dermatofibrosarcoma protuberans in the United States, 1973 to 2002. *J Am Acad Dermatol* 2007;56:968–73.
5. Burkhardt BR, Soule EH, Winkelmann RK, Ivins JC. Dermatofibrosarcoma protuberans. Study of fifty-six cases. *Am J Surg* 1966;111:638–44.
6. Stivala A, Lombardo GA, Pompili G, Tarico MS, Frassetta F, Perrotta RE. Dermatofibrosarcoma protuberans: our experience of 59 cases. *Oncol Lett* 2012;4:1047–55.
7. Bhambri S, Desai A, Del Rosso JQ, Mobini N. Dermatofibrosarcoma protuberans: a case report and review of the literature. *J Clin Aesthet Dermatol* 2008;1:34–6.
8. Khatri VP, Galante JM, Bold RJ, Schneider PD, Ramsamooj R, Goodnight JE Jr. Dermatofibrosarcoma protuberans: reappraisal of wide local excision and impact of inadequate initial treatment. *Ann Surg Oncol* 2003;10:1118–22.
9. Chang CK, Jacobs IA, Salti GI. Outcomes of surgery for dermatofibrosarcoma protuberans. *Eur J Surg Oncol* 2004;30:341–5.
10. Dim-Jamora KC, Perone JB. Management of cutaneous tumors with Mohs micrographic surgery. *Semin Plast Surg* 2008;22:247–56.