

Gallbladder Stones Following Ileal Resection for Gangrenous Intussusceptions: A Follow-up Study

Roland Iheanyichukwu Osuoji, Babajide Olawale Balogun,
Olatunbosun Olabode Olofinlade¹

Departments of Surgery and ¹Radiology, Lagos State University Teaching Hospital, Ikeja, Lagos State, Nigeria

ABSTRACT

Background: Intussusceptions are the most common causes of bowel obstruction in infancy and childhood in this environment they present late, resulting in gangrene of the intussusception consequently resection of the affected bowel and a limited or extended right hemicolectomy (RH) to establish bowel continuity. **Aim:** The aim of the following study is to follow-up these children that had a limited ileal resection for gangrenous intussusceptions and document the formation of stones in their gallbladders. **Materials and Methods:** A total of 14 patients who had limited ileal resection during infancy for gangrenous intussusceptions were matched with sixteen patients who had manual reduction for viable intussusceptions during infancy. Both groups had ultrasound scans of their gallbladders to document the formation of stones in their gallbladders. **Results:** No gallbladder stones were found in both groups, however, one male child that had a resection and a RH for a gangrenous intussusception at the age of 4 months and was seen at an interval of 72 months had a thickened gallbladder on ultrasonography, another child, a female child operated on at the age of 6 months and seen at an interval of 57 months also had a thickened gallbladder on ultrasonography. **Conclusion:** Although no stones were seen, we suggest a prolonged follow-up of these patients with either periodic ultrasonography of the their gallbladders or with the periodic estimation of their serum bile acids.

KEYWORDS: Cholelithiasis, gangrenous childhood intussusceptions, limited ileal resection

Address for correspondence:

Dr. Roland Iheanyichukwu Osuoji,
Lagos State University Teaching Hospital, Ikeja, Lagos State, Nigeria.
E-mail: drosuoji@yahoo.com

Access this article online

Quick Response Code:



Website: www.nigerianjsurg.com

DOI:
10.4103/1117-6806.127101

if the intussusception is gangrenous. We reported our series of intussusceptions in our institution, where we did 35 right hemicolectomies for gangrenous intussusceptions, from a total of 83 patients that presented with intussusceptions in 4½ years, with a resection rate of 42.16%,^[5] while Bode did a total of 96 right hemicolectomies and 23 limited ileal resections in his series from a total of 174 patients that presented with signs and symptoms of intussusceptions, with a resection rate of 68.39%.^[4] It has been reported that extensive ileal resection in necrotizing enterocolitis and Crohn's disease^[7,8] can cause an alteration of the concentration of bile salts in the enterohepatic circulation leading to the possible formation of gallbladder stones. To the best of our knowledge, the literature is scanty on the effect of limited ileal resection from gangrenous intussusception on the formation of gallbladder stones.

This study therefore, is aimed at following up our patients who had ileal resection and a right hemicolectomy (RH) for gangrenous intussusceptions to detect the formation of gallbladder stones.

MATERIALS AND METHODS

The case files of children that were operated on for intussusceptions in the Lagos State University Teaching Hospital, Ikeja, from December 2006 to December 2011 were retrieved from the records department of the hospital and the parents contacted for a follow-up clinic in the pediatric surgical out-patients' either by phone calls or through text messages. This was from August,

INTRODUCTION

Intussusceptions are one of the causes of surgical emergencies in children world-wide.^[1,2] It is the most common cause of bowel obstruction in infants in Nigeria.^[3-5] Contrary to previous studies that stated its prevalence in children above 5 years^[6] We did note in our study and other studies from Nigeria that they present late for treatment in our environment.^[3-5] The consequences of late presentation are increased morbidity and mortality. Early presentation can be managed non-operatively by hydrostatic reduction using barium or air. Operative procedures could be by manual reduction (OR), if the intussusception is viable, or intestinal resection, with an ileo-colic anastomosis, or an intestinal resection with right hemicolectomy (IRRH)

2013 to September, 2013. The reason for the study was explained to the parents and a signed informed consent was obtained from the parents, who also kept a copy. The children were then referred to the radiology department where an abdominal ultrasound examination was performed in both supine and lateral oblique positions. This study was approved by the ethics committee of the institution.

The gall bladder, pancreas and liver were given special attention. The study was performed using either a GE LOGIQ 5 Expert or a Mindray model DP-6600 ultrasound machine with dual probes (3.5 and 7.5 MHz). All participants were scanned by the radiologists after the subjects were fasted for at least 4 h or occasionally in between meals.

Patients were considered to have gallbladder disease only if they had definite gallstones shown on ultrasonography as an echogenic foci with strong posterior acoustic shadowing. The finding of biliary sludge was not accepted as a positive study.

RESULTS

The total number of patients phoned/texted was 57, consisting of 31 control and 26 of the study group. Out of the control group, we phoned 31 parents and only 16 responded, giving a Response rate of 0.52 (52%). Among the study group, we phoned 26, out of which 14 responded. This gave a response rate of 0.54 (54%).

There were 30 responses to phone calls of which 23 were male and 7 were female with a male:female ratio of 3.3:1.

In the control group, we got 16 responses consisting of 11 males and 5 females with a male to female ratio of 2.2:1.

In the study group, there were 14 responses, of which 12 were males and 2 were females and a male:female ratio of 6:1.

The mean age of the control group was 6.2 ± 1.91 months; the mean age was 6 months with minimum of 3 months and maximum age of 9 months. Average interval between operation time and follow-up time for this group was 51.6 ± 18.96 months

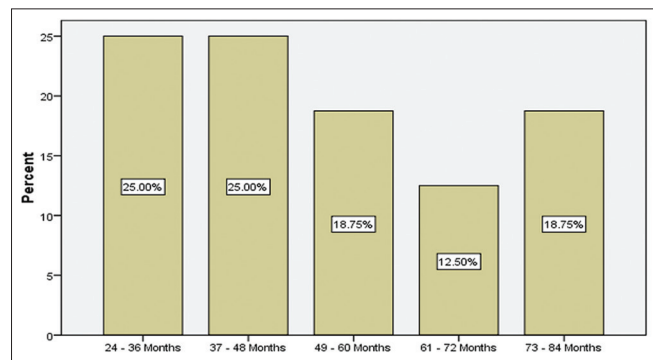


Figure 1: Bar chart of interval between operation and follow-up in operative reduction patients

with the earliest follow-up time being 26 months after operation. For the study group, the mean age of 7.7 ± 3.68 months ranging from 4-18 months was seen. The median age was 7 months. The average follow-up time was 50.07 ± 21.74 months with the earliest follow-up time of 7 months while the latest follow-up of 87 months was recorded [Table 1, Figures 1 and 2].

For OR, 54.5% of the male patients seen were between 3 and 5 months, 36.4% were in age group 6-8 months whereas for IRRH, the dominant age group was 9-11 months with the value of 41.7%. More females were seen in age category 6-8 months (80 0%) for OR, whereas all the female IRRH patients seen were between 3 and 5 months. For OR, no patient was followed up below 24 months while 2 each of male and female were followed-up in between 2 and 3 years. The dominant follow-up period was 37-48 months (3-4 years) for both OR and IRRH and all of them were male patients. The *P* value of 0.779, shows that there was no significant difference between follow-up time for both male and female.

Table 1: Comparison of age, sex and interval between operation and follow-up

	Sex (OR)		Sex (IRRH)	
	Male (%)	Female (%)	Male (%)	Female (%)
Age category				
3-5 months	6 (54.5)	-	2 (16.7)	2 (100.0)
6-8 months	4 (36.4)	4 (80.0)	4 (33.3)	-
9-11 months	1 (9.1)	1 (20.0)	5 (41.7)	-
12 months and above	-	-	1 (8.3)	-
Total	11 (100.0)	5 (100.0)	12 (100.0)	2 (100.0)
Interval between operation and follow-up				
<24 months	-	-	1 (8.3)	-
24-36 months	2 (18.2)	2 (40.0)	2 (16.7)	-
37-48 months	4 (36.4)	-	4 (33.3)	-
49-60 months	1 (9.1)	2 (40.0)	2 (16.7)	-
61-72 months	2 (18.2)	-	1 (8.3)	2 (100.0)
73-84 months	2 (18.2)	1 (20.0)	1 (8.3)	-
85 months and above	-	-	1 (8.3)	-
Total	11 (100.0)	5 (100.0)	12 (100.0)	2 (100.0)

OR=Operative reduction, IRRH=Intestinal resection with right hemicolectomy

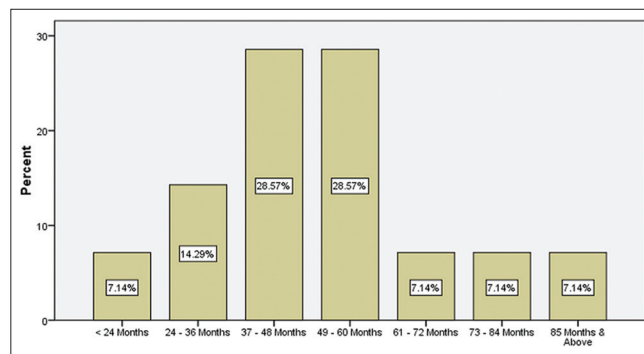


Figure 2: Bar chart of interval between operation and follow-up in limited resection and right hemicolectomy patients

One male child that had a resection with a RH for a gangrenous intussusception at the age of 4 months and seen at an interval of 72 months had a thickened gall bladder on ultrasonography. Another child, a female, operated on at the age of 6 months and seen at an interval of 57 months also had a thickened gallbladder on ultrasonography [Figure 3].

DISCUSSION

Late presentation of intussusceptions leads to gangrene and resection and anastomosis. Often, the gangrenous segment of bowel is resected with the terminal ileum and ileocecal valve and an ileotransverse anastomosis is done to establish bowel continuity. Studies of extensive resection for Crohn's disease and necrotizing enterocolitis showed the development of cholelithiasis.^[7,8] A similar study to ours^[9] which included only 2 patients with gangrenous intussusceptions with ileocecal resection did not find any stones on ultrasonography. To the best of our knowledge, ours is a huge collection and may well form a reference point for further studies in this subregion where these patients present late and have limited ileal resections/limited RH.^[3-5] Two children were found to have thickened gallbladders on ultrasonography, this could be from other causes.

If these children will develop cholelithiasis, they will be mostly cholesterol stones. Cholesterol supersaturation is the main cause of cholesterol stones.^[10] Cholesterol bile supersaturation may be attributable to hypersecretion of cholesterol, hyposecretion of bile acids or a combination of both. An increase in biliary cholesterol output is the most common cause of supersaturation, i.e. from increased synthesis or uptake from endogenous sources.^[11] Adequate bile acid secretion depends in no small measure on the integrity of the enterohepatic circulation and any interference with this mechanism will contribute to bile acid hyposecretion^[12-14]

The pathogenesis of cholelithiasis in children is multifactorial.^[8] In infants it could be due to lithogenic factors such as parenteral alimentation, fasting, dehydration, frusemide treatment, ileal

resection related to necrotizing enterocolitis or neonatal volvulus, biliary tract anomalies and polycythaemia, in combination with the immaturity of both the hepatic excretory function and the enterohepatic circulation.^[8,15,16]

Two children from the study group had thickened gall bladders on ultrasonography, which we think may be due to cholecystitis. This study throws up 2 questions: If stones form, how long after the resection would they form? Secondly, what preventive measures should be undertaken to forestall the formation of these stone? The answer to the first question may be an early and prolonged follow-up of these children.

Hoffmann in its article stated that whenever extensive ileal resection is done, there is malabsorption of bile acids leading to decreased concentration of deoxycholic acid and an increase in the concentration of chenodeoxycholic acid.^[16]

Perhaps the serum levels of these acids might be an indicator of those that may be at risk of developing gallstones from ileal resection from gangrenous intussusceptions, on the long run and who may benefit from dietary and therapeutic manipulation to lower their cholesterol levels if need be. Obviously, one of the limitations of this study is that the length of the resected terminal ileum was not measured, however, majority of intussusceptions occur at the terminal ileum/caecum.^[1] Further studies should be a prolonged follow-up, measurement of the length of ileo-colic resection, pre-operative and periodic estimation of serum cholesterol and bile salts, vitamin B 12, hemoglobin estimation and periodic abdominal ultrasonography. The objective is to investigate the nutritional implications of resecting varying lengths of terminal ileum in the course of treatment of gangrenous intussusceptions.

CONCLUSION

Although we did not find any gallbladder stones in these children who had resection and RH for gangrenous intussusceptions, the need for a long-term follow-up of these patients cannot be overemphasized.

REFERENCES

1. Ein SH, Daneman A. Intussusception. In: Coran AG, Fonkalsrud EW, Grosfeld JL, O'Neil JA, editors. *Pediatric Surgery*. 6th ed. Philadelphia: Mosby Elsevier; 2006. p. 1313-41.
2. Doody DP, Foglia RP. Intussusception. In: Oldham KT, Colombani PM, Foglia RP, editors. *Principles and Practice of Pediatric Surgery*. Philadelphia: Lippincott Williams and Wilkins; 2005. p. 1297.
3. Osifo OD, Evbuomwan I, Osime OC, Mene AO. Paediatric intussusception in Benin City, Nigeria. *Afr J Pediatr Surg* 2007; 4:12-5.
4. Bode CO. Presentation and management outcome of childhood intussusception in Lagos: A prospective study. *Afr J Paediatr Surg* 2008;5:24-8.
5. Osujji RI, Idika OC, Abolarinwa AA, Williams MO, Bankole MA. Intussusception in infancy and childhood in Lagos, Nigeria: A follow-up study. *J Med Res Pract* 2012;1:10-3.

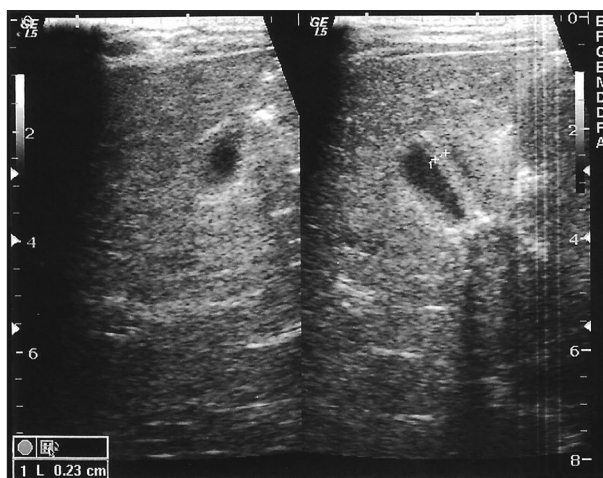


Figure 3: Sonogram, showing thickening of the gallbladders in patients that had ileal resections (limited resection and right hemicolectomy)

6. Ravitch MM. Intussusception. In: Welch KJ, Randolph JG, Ravitch MM, O'Neil JA Jr, Rowe ML, editors. *Pediatric Surgery*. 4th ed. Chicago: Year Book; 1986. p. 868.
7. Hill GL, Mair WS, Goligher JC. Gallstones after ileostomy and ileal resection. *Gut* 1975;16:932-6.
8. Rouma BS, Meler DE. Cholelithiasis (Gallstones). In: Ameh EA, Bickler SW, Lakhoo K, Nwomeh BC, Poenaru D, editors. *Paediatric Surgery: A Comprehensive Text for Africa*. Seattle: Global HELP Organization Publishers; 2012. p. 487.
9. Iwanaka T, Hashizume K, Kawarasaki H, Tanaka K, Kanamori Y, Utsuki T, *et al.* Ileocecal resection in neonates and infants: A follow-up study. *J Pediatr Surg* 1993;28:110-2.
10. Venneman NG, van Erpecum KJ. Pathogenesis of gallstones. *Gastroenterol Clin North Am* 2010;39:171-83, vii.
11. Zessurun J, Albores-Saavedra J. Gallbladder and extra hepatic biliary ducts. In: Damjanov I, Linder J, editors. *Anderson's Pathology*. 10th ed. St. Louis, Baltimore, Carlsbond, Napels, New York, Philadelphia, Portland, London: Mosby; 1990. p. 1864.
12. Bowen JC, Brenner HI, Ferrante WA, Maule WF. Gallstone disease. Pathophysiology, epidemiology, natural history, and treatment options. *Med Clin North Am* 1992;76:1143-57.
13. Everson GT. Gallbladder function in gallstone disease. *Gastroenterol Clin North Am* 1991;20:85-110.
14. Guyton AC, Hall JE. Secretory functions of the alimentary tract. In: Guyton AC, Hall JE, editors. *Textbook of Medical Physiology*. 9th ed. Philadelphia, London, Toronto, Montreal, Sydney, Tokyo: WB Saunders Company; 1996. p. 829.
15. Aldini R, Roda A, Festi D, Sama C, Mazzella G, Bazzoli F, *et al.* Bile acid malabsorption and bile acid diarrhea in intestinal resection. *Dig Dis Sci* 1982;27:495-502.
16. Hofmann AF. Bile acid malabsorption caused by ileal resection. *Arch Intern Med* 1972;130:597-605.

How to cite this article: Osuoji RI, Balogun BO, Olofinlade OO. Gallbladder stones following ileal resection for gangrenous intussusceptions: A follow-up study. *Niger J Surg* 2014;20:19-22.

Source of Support: Nil, **Conflicts of Interest:** None declared.

New features on the journal's website

Optimized content for mobile and hand-held devices

HTML pages have been optimized of mobile and other hand-held devices (such as iPad, Kindle, iPod) for faster browsing speed.

Click on [**Mobile Full text**] from Table of Contents page.

This is simple HTML version for faster download on mobiles (if viewed on desktop, it will be automatically redirected to full HTML version)

E-Pub for hand-held devices

EPUB is an open e-book standard recommended by The International Digital Publishing Forum which is designed for reflowable content i.e. the text display can be optimized for a particular display device.


Click on [**EPub**] from Table of Contents page.

There are various e-Pub readers such as for Windows: Digital Editions, OS X: Calibre/Bookworm, iPhone/iPod Touch/iPad: Stanza, and Linux: Calibre/Bookworm.

E-Book for desktop

One can also see the entire issue as printed here in a 'flip book' version on desktops.

Links are available from Current Issue as well as Archives pages.

Click on  View as eBook