

Received: 2018.06.17
Accepted: 2018.08.30
Published: 2018.11.09

e-ISSN 1941-5923
© Am J Case Rep, 2018; 19: 1338-1341
DOI: 10.12659/AJCR.911694

Living Donor Liver Transplant as Rescue Surgery for a Patient with Hepatocellular Carcinoma Who Underwent Associating Liver Partition and Portal Vein Ligation for Staged Hepatectomy (ALPPS)

Authors' Contribution:
Study Design A
Data Collection B
Statistical Analysis C
Data Interpretation D
Manuscript Preparation E
Literature Search F
Funds Collection G

ABCDEF G 1,2 **Eduardo de Souza Martins Fernandes**
ABDF G 1 **Felipe Pedreira Tavares de Mello**
ABFG 1 **Ronaldo Oliveira Andrade**
ABFG 1 **Camila Liberato Girao**
ABFG 1 **Leandro Savattonne Pimentel**
ABFG 1 **Camilla Cesar**
ABG 1 **Claudia Cristina Sousa**
ABG 1 **Anderson Brito-Azevedo**
ABG 1 **Samanta Teixeira Basto**
ABCDEF G 3 **Orlando Jorge Martins Torres**

1 Department of Gastrointestinal and Liver Transplant Surgery, Rio de Janeiro Adventista Hospital, Rio de Janeiro, RJ, Brazil
2 Department of Surgery, Faculty of Medicine, Federal University of Rio de Janeiro, Rio de Janeiro, RJ, Brazil
3 Department of Gastrointestinal and Liver Transplant Surgery, University Hospital, Federal University of Maranhão, São Luis, MA, Brazil

Corresponding Author: Eduardo de Souza Martins Fernandes, e-mail: esmfernandes@hotmail.com
Conflict of interest: None declared

Patient: Male, 49
Final Diagnosis: Hepatocellular carcinoma
Symptoms: Abdominal pain
Medication: —
Clinical Procedure: Liver transplant
Specialty: Transplantology

Objective: Unusual clinical course





Background: The associating liver partition and portal vein ligation for staged hepatectomy (ALPPS) is an important tool to induce fast liver hypertrophy. The degree of hepatic fibrosis/cirrhosis in patients with HCC negatively impacts their health, and the risk of liver failure is always present. In these cases, liver transplantation may be necessary as a rescue procedure. We present the case of a patient with HCC who underwent ALPPS and developed liver failure. A living donor liver transplant was performed as a rescue procedure.

Case Report: A 49-year-old man with chronic hepatitis B without cirrhosis underwent computed tomography, which revealed an expansive lesion in the right lobe of his liver that was diagnosed as hepatocellular carcinoma. Liver resection was indicated and liver cirrhosis was observed with high portal pressure after transection. The treatment strategy was switched from right hepatectomy to ALPPS. The patient developed severe liver dysfunction and liver transplantation was indicated. His postoperative course was uneventful and 3 months after the procedure the patient was without complications.

Conclusions: Living donor liver transplantation may be necessary as a rescue procedure for patients who underwent ALPPS and develop liver dysfunction.

MeSH Keywords: Hepatectomy • Liver Cirrhosis, Alcoholic • Liver Failure, Acute • Liver Transplantation

Full-text PDF: <https://www.amjcaserep.com/abstract/index/idArt/911694>

 1288   4  12



Background

Complete tumor resection is the only chance for long-term survival in patients with liver metastasis or primary hepatic tumors. Multiple strategies have emerged to avoid liver dysfunction after major liver resection, such as portal vein embolization (PVE), portal vein ligation (PVL), two-stage hepatectomy, and the associating liver partition and portal vein ligation for staged hepatectomy (ALPPS) [1,2].

This new procedure was developed in Regensburg, Germany and is called liver bi-partition. Recently, the acronym ALPPS was proposed by Clavien and Santibanes for associating liver partition and portal vein ligation for staged hepatectomy [1–3].

The initially reported high morbidity and mortality rates of this procedure led to an intense debate about the safety of this novel technique and its modifications. The strict selection of patients is important to perform ALPPS with low or even no mortality. ALPPS has been described for hepatocellular carcinoma (HCC) but the degree of hepatic fibrosis/cirrhosis in patients with HCC negatively impacts future liver remnant growth, and the risk of liver failure is always present. In these cases, liver transplantation could be necessary as a rescue procedure [3–5].

In this report, we present the case of a patient with HCC who underwent ALPPS and who developed liver failure and underwent living donor liver transplant as a rescue procedure.

Case Report

A 49-year-old man with chronic hepatitis B without cirrhosis was diagnosed 1 year ago and was taking Entecavir. Computed tomography revealed an expansive lesion in the right lobe of the liver (9.3×8.6 cm), which was diagnosed as hepatocellular carcinoma. The lesion was restricted and no constitutional symptoms or weight loss were observed during this period. Alpha-fetoprotein on admission was 3.17. After confirmed resectability and preoperative evaluation, surgical resection was indicated.

During the laparotomy, the portal venous pressure was measured using a cannula introduced into the mesenteric vein toward the point where the portal vein diameter was at a maximum and the cannula was connected to a pressure transducer. Liver cirrhosis was observed and the portal pressure was 9 mmHg. After ligation of the right portal vein, the portal pressure increased to 12 mmHg. Hepatic transection was performed in the Cantlie line with the hepatic artery opened and a new portal pressure measurement of 19 mmHg was observed. The strategy was switched from right hepatectomy to ALPPS (Figure 1). A catheter was left in the inferior mesenteric

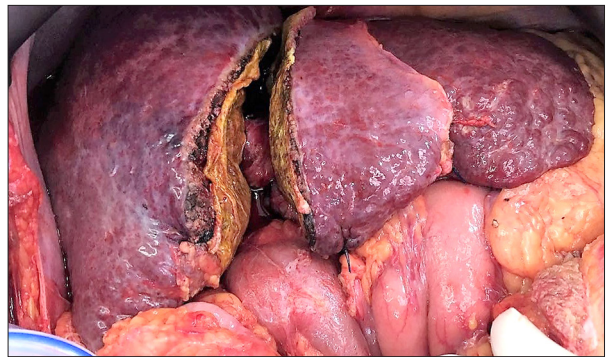


Figure 1. ALPPS for hepatocellular carcinoma.

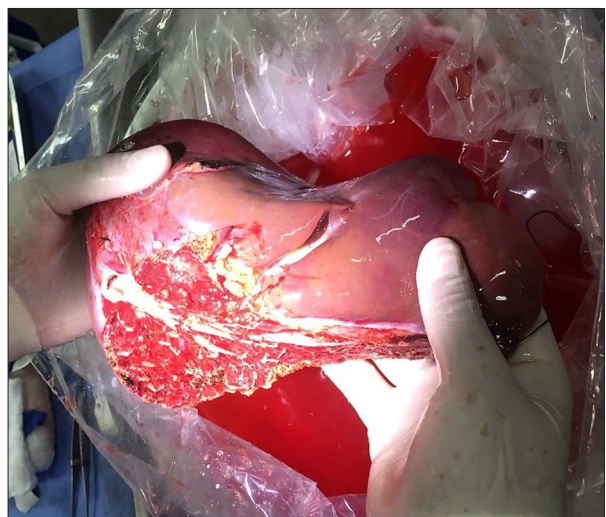


Figure 2. Right lobe for living donor liver transplant.

vein for portal pressure measurement. The histopathology examination of the specimen confirmed a 9.5×8.5 cm hepatocellular carcinoma.

The patient developed severe liver dysfunction and liver transplantation was indicated. As the tumor was beyond the Milan criteria, living donor liver transplantation was suggested. The donor was his brother, a 37-year-old man who was 1.83 meters tall and weighed 88 kg. After careful preoperative evaluation, the patient underwent liver transplantation with a live donor (right lobe shown in Figure 2). Right hepatectomy was performed including the middle hepatic vein (Figure 3) and the volumetric evaluation was 1.024 cm³.

The total ischemia time was 1 h, and the warm ischemia time was 40 min. Anastomosis of the right and middle hepatic vein graft and V8 was performed on the right hepatic vein (Figure 4). Anastomosis of the bile duct was performed with the right hepatic duct.

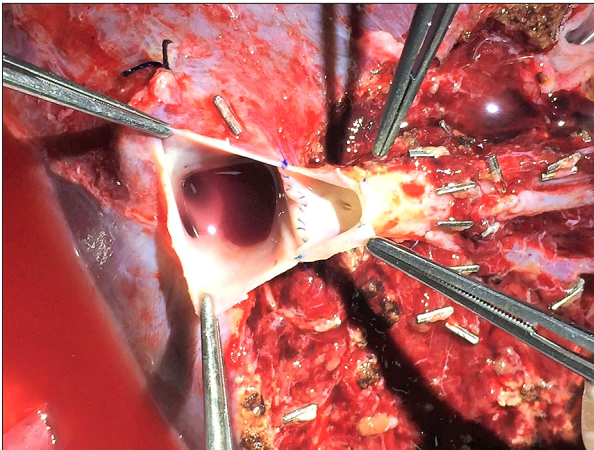


Figure 3. Back-table with right lobe including the middle hepatic vein.

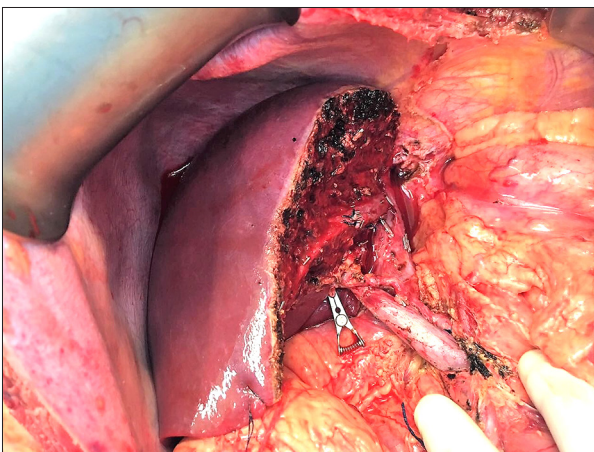


Figure 4. Final aspect of living donor liver transplant.

The postoperative course was uneventful, and the length of hospital stay after the liver transplant was 7 days. Three months after the procedure, the patient was well and without complications. The donor was evaluated 4 weeks after right hepatectomy and was well.

Discussion

ALPPS is a promising procedure for primarily unresectable liver tumors with insufficient future liver remnant (FLR). ALPPS has mainly been performed for colorectal liver metastases and selected cases of hepatocellular carcinoma, as rapid FLR growth in a shorter interval has been observed. However, these advantages may not extend to patients with hepatocellular carcinoma. This patient had concomitant hepatic fibrosis and limited FLR growth. After ALPPS, rapid hypertrophy has been observed with restoration of the liver function 2 weeks after resection. This regenerative quality is not observed in some patients with hepatocellular carcinoma and liver fibrosis [3,5–8].

Approximately 75% of the mortalities after ALPPS were related to liver insufficiency, even when the hypertrophy was considered satisfactory after volumetric analysis. Olthof et al., in a multicenter study, demonstrated that the increase in liver function as measured by hepatobiliary scintigraphy after stage 1 ALPPS is less than the increase measured by volumetric evaluation. The hypertrophy observed in ALPPS does not necessarily lead to a proportional increase in liver function when evaluated by hepatobiliary scintigraphy. The authors described a liver as functionally immature when compared to hepatocytes that underwent portal vein embolization. They concluded that volumetric evaluation of the liver overestimated liver function, and hepatobiliary scintigraphy performed better in assessing liver function [8–10].

ALPPS in patients with hepatocellular carcinoma is indicated in cases of failed portal vein embolization when two-stage hepatectomy is not possible due to portal vein branch invasion, and for substantial tumors with small future liver remnant where the classical two-stage hepatectomy cannot be applied. This procedure should be considered only in a highly selected patient population, and the major concern is the adequacy of future liver remnant growth. The degree of hepatic fibrosis in patients with HCC negatively impacts FLR growth. Some authors suggest that the use of vibration-controlled elastography or magnetic resonance elastography as an initial evaluation tool in patients with hepatocellular carcinoma should be considered for ALPPS. Chia et al. observed that the median FLR growth in patients who underwent ALPPS stage 1 was significantly lower in those with hepatocellular carcinoma BCLC stage B. These patients presented histological evidence of hepatic fibrosis [8–11].

In the present report, the portal venous pressure was measured using a cannula introduced into the mesenteric vein toward the point where the portal vein diameter was at the maximum and connected to a pressure transducer. When the portal venous pressure increases to greater than 11–13 mmHg, complications of portal hypertension have been observed. Portal venous pressure may affect liver regeneration after partial hepatectomy or ALPPS, leading to postoperative liver failure [8,10–12].

Risk factors associated with posthepatectomy liver failure and related to the quality of liver parenchyma are cirrhosis, cholestasis, fibrosis, steatosis, and chemotherapy-related hepatotoxicity. Resection of up to 50% of the hepatic parenchyma can be safely performed in some patients with cirrhosis without liver dysfunction or portal hypertension. In advanced cirrhosis, even minor resections can result in liver failure [5,9,11,12].

When the final volume of the liver is too small to meet metabolic demands, the liver loses this ability, compromising the synthetic function with poor bile production, coagulopathy, and

cholestasis. The minimal volume of future liver remnant is dependent on the underlying liver disease and liver function. The incidence of posthepatectomy liver failure can increase up to 20% in patients with a cirrhotic liver [10–12].

Living donor liver transplantation for HCC has been performed with low surgical mortality. This procedure as a rescue liver transplant has been indicated for tumor recurrence or deteriorated liver function. In patients beyond the Milan criteria, deceased donor liver transplantation is not allowed, and the limitation of organ supplies remains the main issue. In patients with large tumors beyond the Milan criteria, surgical resection or ALPPS is the first choice for those with preserved liver function. This procedure can be followed by living donor liver transplant if necessary, with similar long-term survival and comparable surgical complications [8–12]. In the present

report, a living donor liver transplant was indicated due to postoperative liver failure.

Conclusions

ALPPS for hepatocellular carcinoma should be considered only in highly selected patients. The degree of hepatic fibrosis in patients with HCC negatively affects FLR growth. Living donor liver transplantation may be necessary as a rescue procedure.

Conflict of interest

None.

References:

1. de Santibanes E, Clavien PA: Playing Play-Doh to prevent postoperative liver failure: The "ALPPS" approach. *Ann Surg*, 2012; 255: 415–17
2. Schnitzbauer AA, Lang SA, Goessmann H et al: Right portal vein ligation combined with *in situ* splitting induces rapid left lateral liver lobe hypertrophy enabling 2-staged extended right hepatic resection in small-for-size settings. *Ann Surg*, 2012; 255: 405–14
3. Torres OJ, Fernandes ES, Oliveira CV et al: Associating liver partition and portal vein ligation for staged hepatectomy (ALPPS): The Brazilian experience. *Arq Bras Cir Dig*, 2013; 26: 40–43
4. Hernandez-Alejandro R, Bertens KA, Pineda-Solis K, Croome KP: Can we improve the morbidity and mortality associated with the associating liver partition with portal vein ligation for staged hepatectomy (ALPPS) procedure in the management of colorectal liver metastases? *Surgery*, 2015; 157: 194–201
5. Schadde E, Aridles V, Robles-Campos R et al: Early survival and safety of ALPPS: First report of the international ALPPS registry. *Ann Surg*, 2014; 260: 829–38
6. Torres OJM, Vasques RR, Silva THS et al: The ALPPS procedure for hepatocellular carcinoma larger than 10 centimeters. *Int J Sur Case Rep*, 2016; 26: 113–17
7. Torres OJM, Fernandes ESM, Herman P: ALPPS: past, present and future. *ABCD Arq Bras Cir Dig*, 2015; 28: 155–56
8. Vennarecci G, Laurenzi A, Levi Sandri GB et al: The ALPPS procedure for hepatocellular carcinoma. *Eur J Surg Oncol*, 2014; 40: 982–88
9. Chan ACY, Chok K, Dai JWC, Lo CM: Impact of split completeness on future liver remnant hypertrophy in associating liver partition and portal vein ligation for staged hepatectomy (ALPPS) in hepatocellular carcinoma: Complete-ALPPS versus partial-ALPPS. *Surgery*, 2017; 161: 357–64
10. Chia DK, Yeo Z, Loh SEK et al: ALPPS for hepatocellular carcinoma is associated with decreased liver remnant growth. *J Gastrointest Surg*, 2018; 22(6): 973–80
11. Serenari M, Cescon M, Cucchetti A, Pinna AD: Liver function impairment in liver transplantation and after extended hepatectomy. *World J Gastroenterol*, 2013; 19: 7922–29
12. Olthof PB, Tomassini F, Huespe PE et al: Hepatobiliary scintigraphy to evaluate liver function in associating liver partition and portal vein ligation for staged hepatectomy: Liver volume overestimates liver function. *Surgery*, 2017; 162(4): 775–83