

Laparoscopic Harvest of the Rectus Abdominis for Perineal Reconstruction

Nneamaka Agochukwu, MD*
Alisha Bonaroti, MD*
Sandra Beck, MD†
James Liau, MD*

Summary: The rectus abdominis is a workhorse flap for perineal reconstruction, in particular after abdominoperineal resection (APR). Laparoscopic and robotic techniques for abdominoperineal surgery are becoming more common. The open harvest of the rectus abdominis negates the advantages of these minimally invasive approaches. (Sentence relating to advantages of laparoscopic rectus deleted here.) We present our early experience with laparoscopic harvest of the rectus muscle for perineal reconstruction. Three laparoscopic unilateral rectus abdominis muscle harvests were performed for perineal reconstruction following minimally invasive colorectal and urological procedures. The 2 patients who underwent APR also had planned external perineal skin reconstruction with local flaps. (Sentence deleted here to shorten abstract.) All rectus muscle harvests were performed laparoscopically. Two were for perineal reconstruction following laparoscopic APR, and 1 was for anterior vaginal wall reconstruction. This was done with 4 ports positioned on the contralateral abdomen. The average laparoscopic harvest time was 60–90 minutes. The rectus muscle remained viable in all cases. One patient developed partial necrosis of a posterior thigh fasciocutaneous flap after cancer recurrence. There were no pelvic abscesses, or abdominal wall hernias. Laparoscopic harvest of the rectus appears to be a cost-effective, reliable, and reproducible procedure for perineal with minimal donor-site morbidity. Larger clinical studies are needed to further establish the efficacy and advantages of the laparoscopic rectus for perineal reconstruction. (*Plast Reconstr Surg Glob Open* 2017;5:e1581; doi: 10.1097/GOX.0000000000001581; Published online 13 November 2017.)

INTRODUCTION

The traditional complication rate of abdominoperineal resection (APR) without soft-tissue coverage can be high as 25–60%.^{1–3} In 2007, a landmark study performed by Butler et al.⁴ demonstrated that the use of the vertical rectus abdominis myocutaneous (VRAM) flap led to a drastic reduction in the complication rate of perineal abscess, major wound dehiscence, and pelvic fluid collections after APR. This robust, versatile flap has become the workhorse of perineal reconstruction. As minimally invasive techniques for APR have become more prevalent, the traditional open harvest of a VRAM is losing its appeal, as it defeats the purpose and advantages of a laparoscopic or

robotic APR. Also, the skin paddle complication rate of a VRAM can be high depending on the ratio between the patient's pelvic inlet and thickness of the adipocutaneous portion of the VRAM.

The earliest reports of endoscopic harvest of the rectus describe a technically difficult and lengthy dissection and violation of the anterior sheath.^{5–7} The first report of an anterior sheath sparing laparoscopic harvest of the rectus abdominis was in 2000, where it was harvested as a free flap for a heel wound.⁸ Reports for its utility in perineal reconstruction are scarce, with its use in perineal reconstruction first reported in a cadaver model in 2015.⁹ Its use in perineal reconstruction has been reported in only 2 articles to date.^{10,11} Advantages of the laparoscopic harvest include reduced incisional morbidity, sparing of the anterior rectus sheath, utilization of the same port sites and laparoscopic instruments, enhanced recovery, decreased

From the *Division of Plastic Surgery, Department of Surgery, University of Kentucky, Lexington, Ky.; and †Division of General Surgery, Department of Surgery, University of Kentucky, Lexington, Ky.

Received for publication August 2, 2017; accepted September 29, 2017.

Copyright © 2017 The Authors. Published by Wolters Kluwer Health, Inc. on behalf of The American Society of Plastic Surgeons. This is an open-access article distributed under the terms of the Creative Commons Attribution-Non Commercial-No Derivatives License 4.0 (CCBY-NC-ND), where it is permissible to download and share the work provided it is properly cited. The work cannot be changed in any way or used commercially without permission from the journal.

DOI: 10.1097/GOX.0000000000001581

Disclosure: The authors have no financial interest to declare in relation to the content of this article. The Article Processing Charge was paid for by the authors.

Supplemental digital content is available for this article. Clickable URL citations appear in the text.

postoperative pain, superior aesthetics, ability for simultaneous harvest in certain cases, and decreased postoperative pain.¹¹

We present our experience with laparoscopic harvest of the rectus abdominis muscle for perineal reconstruction with the goal of expanding the literature on the utility of minimally invasive harvest of the rectus abdominis in perineal reconstruction.

METHODS

Three laparoscopic harvests of the rectus abdominis muscle were performed at a single institution by a single plastic surgeon (J.L.) and colorectal surgeon (S.B.). See Table 1 for patient descriptions and indications.

Technique

Port Placement

All ports were placed in the contralateral abdominal wall. A 10-mm port was placed over the left abdominal wall in the subxiphoid region following the use of a Veress needle for peritoneal access and insufflation. Three, 5-mm ports were placed in a W-configuration allowing optimal angles for dissection and visualization (Fig. 1).

Rectus Abdominis Harvest

Supplemental Digital Contents 1 and 2 demonstrate the intraperitoneal laparoscopic harvest after APR, and for vaginal wall reconstruction, respectively (see video, Supplemental Digital Content 1, <http://links.lww.com/PRSGO/A610>; see video, Supplemental Digital Content 2, which displays the laparoscopic rectus harvest for vaginal wall reconstruction on patient 3, <http://links.lww.com/PRSGO/A611>).

We incise the posterior sheath longitudinally and identify the rectus muscle. Similar to an open approach, we then transect the superior rectus muscle and then dissect the rectus off the anterior sheath. The deep inferior epi-

gastric pedicle is visualized and protected during the dissection.

The harvest was performed at the same time as the urological procedure in 1 patient, and following the APR in the APR patients. In the urologic patient, the urologists gained exposure transvaginally, and the rectus muscle was pulled through the transvaginal space. It was sutured superiorly to support the bladder neck over the anterior vaginal wall defect using 3-0 Vicryl sutures (Fig. 2). We harvested posterior fascia above the arcuate line to provide the urologists with fascia to perform a pubovaginal sling for concomitant stress incontinence. In the patients undergoing laparoscopic APR, we secured the rectus to the pelvic opening after external perineal extirpation in the prone position. The rectus muscle was sutured with 3-0 Vicryl over the perineal defect (Fig. 3). In the APR patients, the soft-tissue perineal defect was closed with local tissue flaps (Table 1; see figure, Supplemental Digital Content 3, which displays patient 1, shown after bilateral gluteal fasciocutaneous advancement flaps, <http://links.lww.com/PRSGO/A612>).

RESULTS

The average harvest time was 60–90 minutes. One patient had partial necrosis of 1 of the posterior thigh fasciocutaneous flaps after cancer recurrence, requiring debridement and delayed closure. The rectus muscle remained viable and intact in all cases. There were no other complications, and no patients developed abdominal wall bulges.

DISCUSSION

The advent and refinement of minimally invasive techniques in surgery has been 1 of the greater paradigm shifts in surgery and are increasingly finding a role in plastic surgery.^{12–22} As colorectal surgeons begin to perform more APRs laparoscopically, it is imperative

Table 1. Patient Characteristics/Demographics

Patient No.	1	2	3
Age (y)	34	50	20
BMI (kg/m ²)	30.4	25.7	38.7
Diagnosis	Anal squamous cell carcinoma	Anal squamous cell carcinoma	Anterior vaginal wall defect, stress urinary incontinence
Indication	Perineal defect after APR	Perineal defect after APR	Anterior vaginal wall defect with bladder neck prolapse
Procedure	Laparoscopic APR, laparoscopic harvest of rectus, bilateral gluteal V-Y fasciocutaneous advancement flaps	Laparoscopic APR with partial excision of vaginal wall, laparoscopic harvest of rectus, bilateral posterior thigh flaps	Transvaginal repair of bladder prolapse with pubovaginal sling, laparoscopic harvest of rectus
Complications	None	Unilateral posterior thigh flap necrosis following cancer recurrence	None
Surgery date	5/12/16	1/12/16	5/9/17
Length of stay	12 d	24 d	5 d
Length of follow-up	13 mo	17 mo	1 mo
Comorbidities	HIV	HTN	PCOS
Prior XRT	Yes	Yes	No
Prior chemo	Yes	Yes	No
Prior abdominal surgery	Yes (diverting colostomy)	Yes (appendectomy, cholecystectomy, bilateral tubal ligation, colostomy)	No

HTN, hypertension; PCOS, polycystic ovarian syndrome.

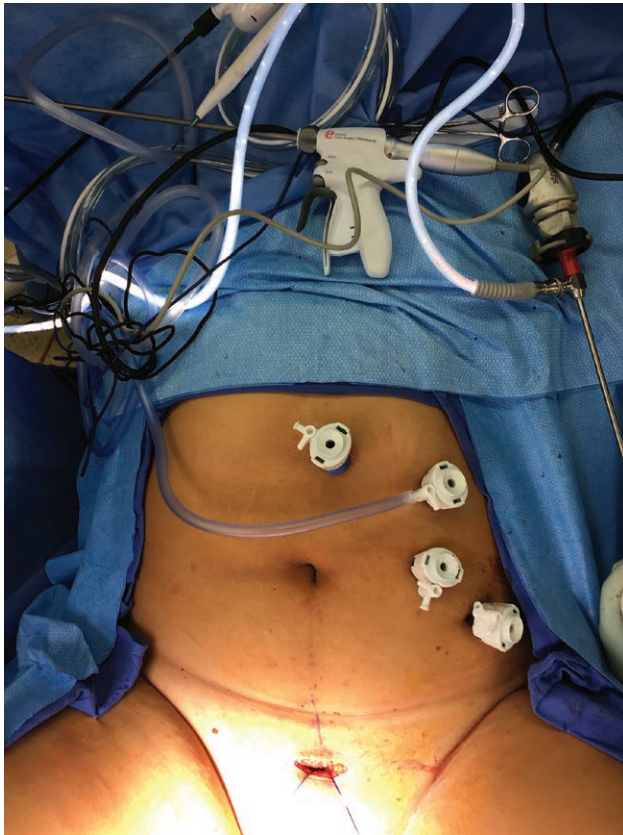
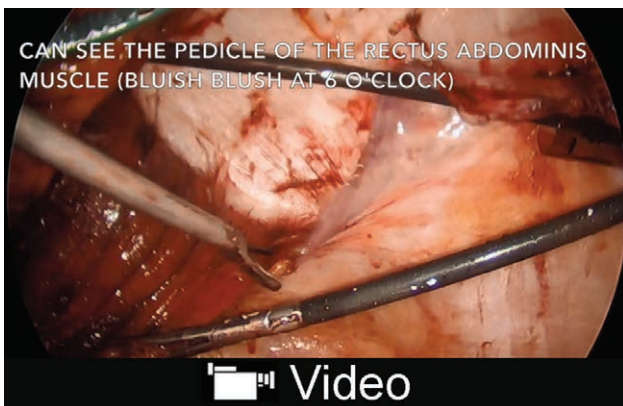


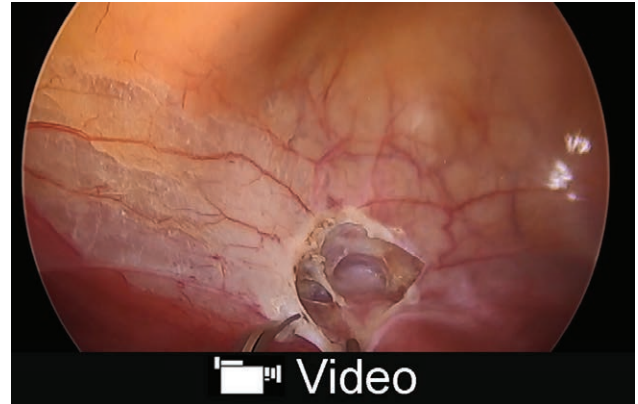
Fig. 1. Image demonstrating laparoscopic port setup on patient 3.

that we, the reconstructive surgeons, have the ability to shift our paradigm and adopt new techniques “to decrease morbidity and enhance patient recovery from these complex surgeries.”

Benefits of the laparoscopic harvest include use of the same laparoscopic equipment, ability to simultaneously harvest muscle in the case of concomitant urologic/gynecologic procedures, and low donor-site morbidity. Additionally, in cases of external wound breakdown or necrosis, the rectus muscle is not compromised due to the fact that



Video Graphic 1. See video, Supplemental Digital Content 4, which displays the laparoscopic rectus harvest after laparoscopic APR on patient 1. This video is available in the “Related Video” section of PRSGlobalOpen.com or at <http://links.lww.com/PRSGO/A610>.



Video Graphic 2. See video, Supplemental Digital Content 5, which displays the laparoscopic rectus harvest for vaginal wall reconstruction on patient 3. This video is available in the “Related Video” section of PRSGlobalOpen.com or at <http://links.lww.com/PRSGO/A611>.

it is a separate entity. In the patient who developed necrosis of the posterior thigh flaps, the rectus remained viable.

APRs yield complex defects that are fairly hostile environments for reconstruction due to irradiation, patient habitus, and the inherent difficulty with perineal wound care. Using muscle and skin distant to the surrounding tissue, such as a VRAM, is an excellent solution in certain cases. However, VRAMs have a significant adipocutaneous component in obese patients. Passing the thicker adipocutaneous flap through the pelvis increases tension on the skin, jeopardizing its viability. Furthermore, complex and delicate reconstruction of the vaginal vault is next to impossible with a thick adipocutaneous paddle. Muscle can be easily contoured to a vaginal defect and allowed to mucosalize with time (see figure, Supplemental Digital Content 4, which displays patient 3, shown 1-month postoperatively with mucosalization of rectus muscle over anterior vaginal wall defect, <http://links.lww.com/PRSGO/A613>; see figure, Supplemental Digital Content 5, which displays patient 3, healed abdominal port sites, <http://links.lww.com/PRSGO/A614>).

This is preferable to a skin paddle that requires significant maintenance hygiene due to the constant epithelial shedding. Another significant advantage of the laparoscopic harvest is the sparing of the anterior rectus sheath. In our study, similar to prior reports of minimally invasive harvest of the rectus, no patients had mesh reinforcement of the abdominal wall, and none developed abdominal wall bulges. Additional minimally invasive options for reconstruction of the perineum following APR include a laparoscopic harvest of the omentum (although this may not reach for deep pelvic defects) and a laparoscopic harvest of the gracilis.

Disadvantages of these minimally invasive approaches include the technical challenge, as laparoscopic surgery lacks tactile feedback for the surgeon who is used to open surgery. An additional cutaneous flap may be needed in addition to the rectus, in APR cases. It should be noted, however, in the 2 reports of the use of the laparoscopic rectus in perineal reconstruction, no additional flap was used.^{10,11}

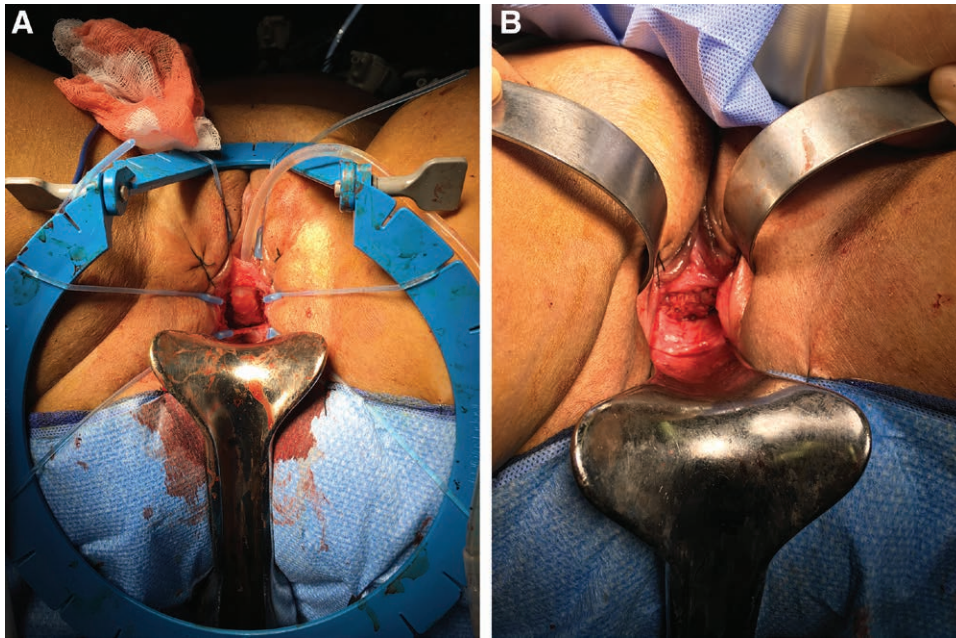


Fig. 2. A, Anterior vaginal wall defect before repair. B, Anterior vaginal wall defect after repair and rectus muscle inset.

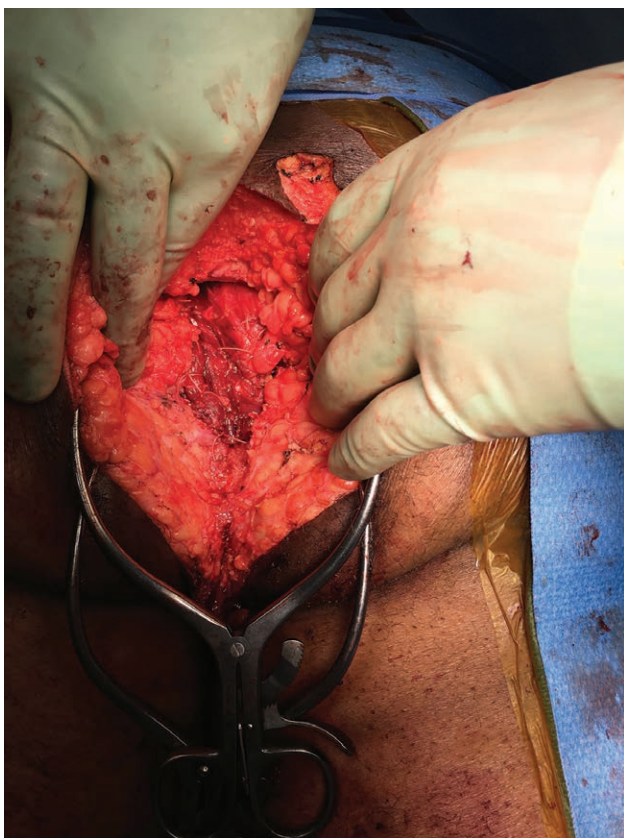


Fig. 3. Rectus muscle in situ over perineal defect after inset on patient 1.

CONCLUSIONS

In this preliminary study, we have shown that the laparoscopic harvest of the rectus abdominis appears to be a feasible, reproducible technique that decreases the mor-

bidity associated with the traditional harvest of this versatile flap in perineal reconstruction. Minimally invasive techniques are finding a new home in plastic surgery and represent a new paradigm shift in the modern day practice our specialty. With the current focus on enhanced recovery after surgery, minimally invasive techniques are playing an increasingly significant role in other surgical specialties, and we as reconstructive surgeons, need to follow suit. More and larger clinical studies, including randomized control trials, are needed to further validate and establish this technique and its efficacy for perineal reconstruction.

James Y. Liau, MD

Division of Plastic Surgery, Department of Surgery
University of Kentucky
740 S. Limestone, Suite K448
Lexington, KY 40536
E-mail: jyliu0@uky.edu

REFERENCES

1. Yeh KA, Hoffman JP, Kusiak JE, et al. Reconstruction with myocutaneous flaps following resection of locally recurrent rectal cancer. *Am Surg.* 1995;61:581–589.
2. Shibata D, Hyland W, Busse P, et al. Immediate reconstruction of the perineal wound with gracilis muscle flaps following abdominoperineal resection and intraoperative radiation therapy for recurrent carcinoma of the rectum. *Ann Surg Oncol.* 1999;6:33–37.
3. Khoo AK, Skibber JM, Nabawi AS, et al. Indications for immediate tissue transfer for soft tissue reconstruction in visceral pelvic surgery. *Surgery.* 2001;130:463–469.
4. Butler CE, Gündeslioglu AO, Rodriguez-Bigas MA. Outcomes of immediate vertical rectus abdominis myocutaneous flap reconstruction for irradiated abdominoperineal resection defects. *J Am Coll Surg.* 2008;206:694–703.
5. Bass LS, Karp NS, Benacquista T, et al. Endoscopic harvest of the rectus abdominis free flap: balloon dissection in the fascial plane. *Ann Plast Surg.* 1995;34:274–279; discussion 279.

6. Friedlander LD, Sundin J. Minimally invasive harvesting of rectus abdominis myofascial flap in the cadaver and porcine models. *Plast Reconstr Surg*. 1996;97:207–211.
7. Venkataramakrishnan V, Southern SJ. Endoscopic rectus harvest: a simplified sheath-saving technique. *Ann Plast Surg*. 1997;39:573–577.
8. Greensmith A, Januszkiewicz J, Poole G. Rectus abdominis muscle free flap harvest by laparoscopic sheath-sparing technique. *Plast Reconstr Surg*. 2000;105:1438–1441.
9. Johnston DB, McBrearty A, Armstrong A. Laparoscopic mobilization of a rectus abdominis myofascial flap for the prevention of perineal hernia post-abdominoperineal resection of the rectum: a feasibility study? *Surg Innov*. 2015;22:656.
10. Winters BR, Mann GN, Louie O, et al. Robotic total pelvic exenteration with laparoscopic rectus flap: initial experience. *Case Rep Surg*. 2015;2015:835425.
11. Pang JH, Patel SA, King SA, et al. Reduced-port approach to laparoscopic flap harvest (RALFH): an anterior sheath sparing rectus abdominis flap. *J Plast Reconstr Aesthet Surg*. 2017;70:710–712.
12. Pedersen J, Song DH, Selber JC. Robotic, intraperitoneal harvest of the rectus abdominis muscle. *Plast Reconstr Surg*. 2014;134:1057–1063.
13. Ibrahim AE, Sarhane KA, Pederson JC, et al. Robotic harvest of the rectus abdominis muscle: principles and clinical applications. *Semin Plast Surg*. 2014;28:26–31.
14. Ibrahim AE, Sarhane KA, Selber JC. New frontiers in robotic-assisted microsurgical reconstruction. *Clin Plast Surg*. 2017;44:415–423.
15. Selber JC. Can I make robotic surgery make sense in my practice? *Plast Reconstr Surg*. 2017;139:781e–792e.
16. Van Buskirk ER, Rehnke RD, Montgomery RL, et al. Endoscopic harvest of the latissimus dorsi muscle using the balloon dissection technique. *Plast Reconstr Surg*. 1997;99:899–903; discussion 904.
17. Karp NS, Bass LS, Kasabian AK, et al. Balloon assisted endoscopic harvest of the latissimus dorsi muscle. *Plast Reconstr Surg*. 1997;100:1161–1167.
18. Fine NA, Orgill DP, Pribaz JJ. Early clinical experience in endoscopic-assisted muscle flap harvest. *Ann Plast Surg*. 1994;33:465–469; discussion 469.
19. Doi K, Hattori Y, Soo-Heong T, et al. Endoscopic harvesting of the gracilis muscle for reinnervated free-muscle transfer. *Plast Reconstr Surg*. 1997;100:1817–1823.
20. Ramakrishnan V, Southern S, Hart NB, et al. Endoscopically assisted gracilis harvest for use as a free and pedicled flap. *Br J Plast Surg*. 1998;51:580–583.
21. Onishi K, Maruyama Y, Yataka M. Endoscopic harvest of the tensor fasciae latae muscle flap. *Br J Plast Surg*. 1997;50:58–60.
22. Kamei Y, Torii S, Hasegawa T, et al. Endoscopic omental harvest. *Plast Reconstr Surg*. 1998;102:2450–2453.