

Original research

# Combined external and endonasal approach to fronto-ethmoidal mucocele involving the orbit

Bijan Beigi<sup>a,b,\*</sup>, Deepak Vayalambrone<sup>a</sup>, Mohsen Bahmani Kashkouli<sup>b</sup>, Peter Prinsley<sup>c</sup>, Jan Saada<sup>d</sup>

<sup>a</sup> Department of Ophthalmology, Norfolk & Norwich University Hospital NHS Trust, United Kingdom

<sup>b</sup> Eye Research Center, Rassoul Akram Hospital, Iran University of Medical Sciences, Iran

<sup>c</sup> ENT Department, Norfolk & Norwich University Hospital NHS Trust, United Kingdom

<sup>d</sup> Radiology Department, Norfolk & Norwich University Hospital NHS Trust, United Kingdom

Received 26 October 2015; revised 26 January 2016; accepted 26 January 2016

Available online 7 March 2016

## Abstract

**Purpose:** To present a technique to improve the surgical treatment of frontal sinus mucocele and its recurrence.

**Methods:** Nine procedures performed on eight patients by a team of ENT and Ophthalmic orbital surgeons. Data collected included patient demographics, surgical details, pathological findings and complications. The surgical technique involved an external approach via the upper eyelid skin crease combined with an internal approach with a rigid 4 mm endoscope described below. Following evacuation of the mucocele the sinus was anastomosed to nasal cavity with insertion of silicon stent. All patients had preoperative and postoperative CT scans of the orbit and paranasal sinuses.

**Result:** There were nine operations on eight patients (six males, two female patients, mean age of 57.25; range, 15–71). Two patients had inverted papillomas. All patients presented with non-axial proptosis and diplopia. The mean follow up period was 38.7 months (range 11–99). The only intraoperative complication noted was a cerebrospinal fluid (CSF) leak in a patient with a post traumatic mucocele. Post-operative complications included lid scarring in 2 patients. One of the patients had a fistula overlying the affected sinus at presentation. Both patients underwent dermis fat grafting as a second stage procedure and responded well. One patient presented with asymptomatic superior oblique weakness that could be attributed to trauma to the superior oblique intra operatively. There was no case of recurrence of mucocele in our series. One of the inverted papillomas had an early recurrence (within 6 months) that required repeat surgery.

**Conclusion:** Fronto nasal anastomosis restores the anatomy and reduces the chance of recurrence in our experience. The final cosmetic result is excellent and the patient's satisfaction is high.

Copyright © 2016, Iranian Society of Ophthalmology. Production and hosting by Elsevier B.V. This is an open access article under the CC BY-NC-ND license (<http://creativecommons.org/licenses/by-nc-nd/4.0/>).

## Introduction

Treatment of the frontal sinus pathology has proved surgically challenging and a number of approaches have been

reported over the years.<sup>1</sup> In general terms external approaches give a wide exposure but may be complicated by scars and cutaneous nerve damage whereas endonasal endoscopic approaches are limited by the extent to which lateral and supra orbital extensions of the sinus may be accessed.

A combined approach to pathology of the frontal sinus has been used over the last 10 years in Norwich. The advantages of the combined endoscopic and open approach are apparent and the several problems encountered if a single approach is used are avoided. The technique has evolved enabling

Conflicts of interest: None.

\* Corresponding author. Department of Ophthalmology, Norfolk & Norwich University Hospital, Norwich NR4 7UY, United Kingdom. Tel.: +44 1603 288372; fax: +44 1603 288261.

E-mail address: [bb@mrbeigi.com](mailto:bb@mrbeigi.com) (B. Beigi).

Peer review under responsibility of the Iranian Society of Ophthalmology.

<http://dx.doi.org/10.1016/j.joco.2016.01.007>

2452-2325/ Copyright © 2016, Iranian Society of Ophthalmology. Production and hosting by Elsevier B.V. This is an open access article under the CC BY-NC-ND license (<http://creativecommons.org/licenses/by-nc-nd/4.0/>).

treatment of a number of different pathologic problems requiring a safe and wide exposure.

## Methods

This is a retrospective review of nine procedures performed on eight patients by a team of ENT and Ophthalmic orbital surgeons. Data collected included patient demographics, surgical details, pathological findings and complications. All the procedures were performed under a general anaesthetic. The surgical technique involved an external approach via the upper eyelid skin crease combined with an internal approach with a rigid 4 mm endoscope described below. All patients had pre-operative and postoperative CT scans of the orbit and paranasal sinuses.

### External dissection

An upper eyelid skin crease incision extending towards the medial and lateral orbital rim is made. The anterior lamella of the upper eyelid is elevated by blunt dissection of the orbicularis oculi muscle off the orbital septum towards the orbital rim to expose the arcus marginalis, extending medially towards the trochlea and laterally to the lacrimal fossa. A periosteal incision is made parallel to the orbital rim. The supraorbital and supratrochlear neurovascular bundles are clearly identified and retracted out of the surgical field with a squint hook, thus ensuring their preservation. The periosteal incision is extended towards the base of the nose and if necessary towards the rim of the medial wall. The periorbitum is then elevated exposing any pathological defect in the orbital roof. The floor of the frontal sinus is opened to give excellent exposure of the sinus all aspects. There is sometimes a defect at this level to lead to the sinus. The frontal sinus is inspected with the endoscope through the same route to visualise the lateral extent of the sinus if necessary. The frontal sinus ostium is easily identifiable from within the sinus and probed. The frontonasal probing will follow after endonasal surgery with endoscopic guidance.

### Endonasal dissection

The nasal cavity is prepared with 4% topical cocaine/1 in 5000 adrenaline solution on nasal sponges. Standard endoscopic dissection of the frontal recess is performed with uncinectomy and resection of the hard bone in the “Axilla” of the middle turbinate attachment after elevation of a small mucosal flap. A limited resection of anterior ethmoidal cells then exposes the region of the lower end of the fronto-nasal duct. Its precise location may be difficult to identify from below especially if there has been previous surgery but a probe passed from above is easily seen within the nose at this point. An opening large enough to accommodate the stent is then created.

### Stenting

A single or double lumen stent is prepared by passing a 5/0 prolene suture through its upper portion. The stent is threaded

into the frontal sinus through the external opening and then guided through the ostium into the nasal cavity (Fig. 2). The prolene suture attached to the upper portion of the stent is directed through orbital rim periosteum towards the superior aspect of the eyebrow skin and secured over a plastic bolster on skin surface. This will ensure that the stent remains in place as long as necessary. The final appearance is shown in Fig. 2. The periorbitum is then closed with 5/0 vicryl suture. The skin wound is repaired with 6/0 nylon suture. The stent is removed 3 months later by release of the bolster and retrieved from inside the nose.

All the patients were followed up at 1 week, 3 months and 1 year after surgery with further follow up decided on the basis of clinical need. All patients had pre and post operative CT scans with the latter scan performed after removal of the stent in all cases.

## Results

There were nine operations on eight patients (One patient had bilateral pathology, Figs. 1–5). There were six male and two female patients with a mean age of 57.25 (range 15–71). Two patients had inverted papillomas. All patients presented with non-axial proptosis and diplopia in up gaze.

The demographics and clinical features of the eight patients are shown in Table 1. The mean follow up period was 38.7 months (range 11–99). The only intraoperative complication noted was a CSF leak in a patient with a post traumatic mucocele. This resulted from damage to the dural plug which had closed a defect in the posterior table arising from the original injury. A fat graft was used to close the defect during the surgery.

Post-operative complications included lid scarring in two patients. One of the patients had a fistula overlying the affected sinus at presentation. The second patient had inflammatory upper lid changes preoperatively. Both patients underwent dermis fat grafting as a second stage procedure and responded well. Fig. 1 shows a patient who presented with left frontal mucoceles prior to surgery. It was operated on successfully (Fig. 2). The right eye developed the same problem (Fig. 3). This was treated with the same technique (Fig. 4).

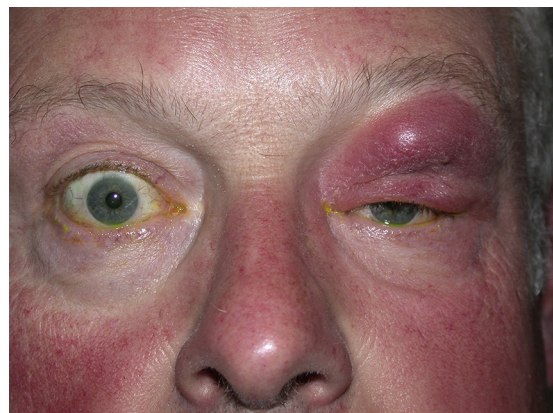

Fig. 1. Pre-operative photo of left mucocele with orbital roof abscess.

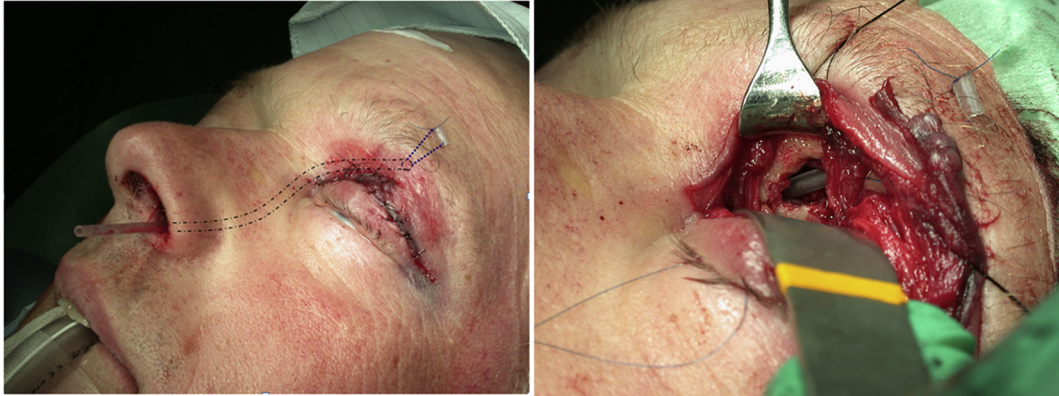


Fig. 2. Intra-operative view of the surgery. Fronto-nasal stent is highlighted.

This patient had surgery for postoperative lid scarring and retraction on the left side with an excellent cosmetic result. One patient presented with asymptomatic superior oblique weakness that could be attributed to trauma to the superior oblique intra-operatively. One patient had forehead anaesthesia resulting from an injury to the head sustained following a fall of a ladder 15 years prior to presentation.

There was no case of recurrence of mucocele in our series. One case with inverted papillomas had an early recurrence (within 6 months) that required repeat surgery with the adjunctive use of Mitomycin-C. At his 12 month follow up,

after his second operation, there was no recurrence. Case 7 had four previous conventional sinus surgeries prior to referral, but responded well to this procedure (Figs. 6 and 7).

The final cosmetic result was excellent in all cases and the patients were satisfied with their appearance.

#### Discussion

The Lynch incision has been the standard external approach employed by surgeons to access frontal mucocele.<sup>2</sup> However, it has the disadvantage of poor cosmesis caused by a depression over the forehead due to removal of the anterior wall of the frontal sinus and a visible skin scar. Persistent post-operative pain and neuralgia has been noted in 6% of cases.<sup>3</sup>

Bicoronal osteoplastic flaps are time consuming and can be complicated by scalp numbness, hair loss and frontalis palsy. In a series of bicoronal osteoplastic flaps reported by Weber et al a recurrence rate of 6.8% was noted during a follow up ranging from 1 to 12 years.<sup>4</sup> Complications included numbness (8.5%), persistent pain (3.4%) and poor cosmesis reported by the patient (5.1%).

Endoscopic procedures have become popular in the surgical management of frontal sinus mucoceles. The Draft 3 or modified Lothrop procedure is the most extensive and involves

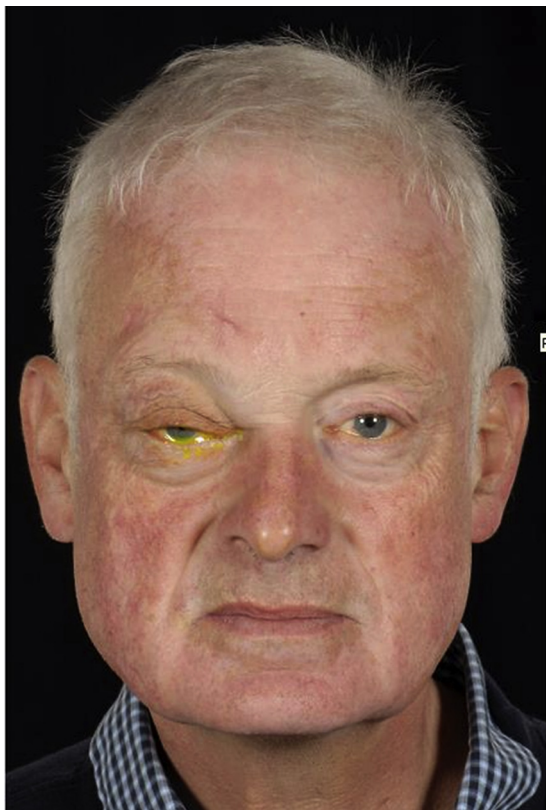


Fig. 3. Same patient after developing a right frontal mucocele. This is the appearance after surgery on the left mucocele and before surgery on the right mucocele.

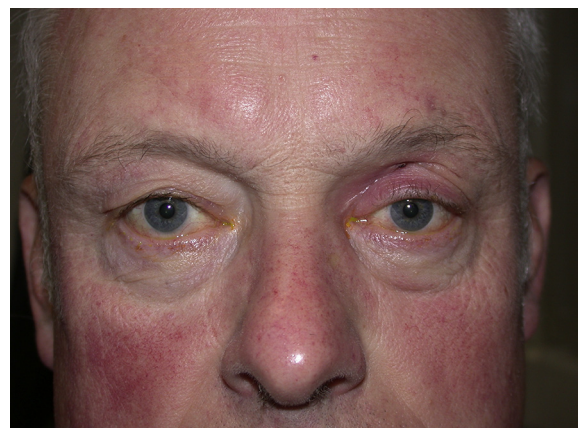

Fig. 4. Post operative result following bilateral frontonasal anastomosis. Left upper eyelid fat atrophy was dealt with fat graft later.

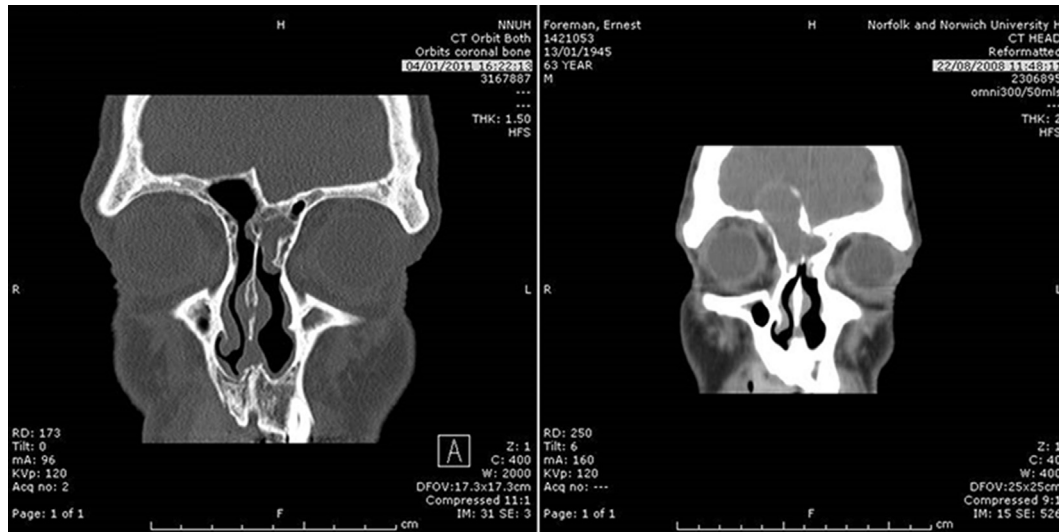

Fig. 5. Shows left: preoperative and Right: postoperative appearances (of bilateral mucocoeles) of the same patient.

Table 1  
The demographics and clinical features of the 8 patients.

Patient no.	Age	Sex	Eye	Aetiology	Clinical features	Complications	Follow up (months)
1	64	M	L	Mucocele	Proptosis, Preseptal cellulitis	Lid scarring	75
1	64	M	R	Mucocele	Proptosis	Nil	75
2	55	F	R	Mucocele	Proptosis, fistula	Lid scarring	99
3	71	M	L	Inverted papilloma	Recurrent mucocele following 4 endoscopic procedures	Nil	13
4	53	F	L	Mucocele	Proptosis	Nil	12
5	15	M	R	Mucocele	Proptosis	Nil	11
6	51	M	R	Mucocele following trauma 15 years prior	Proptosis	CSF leak, numbness in V1	61
7	37	M	R	Mucocele	Proptosis	Nil	21
8	54	M	L	Inverted papilloma	Proptosis	Needed a second procedure to treat residual papilloma.	18

M: male, F: female, L: left, R: right.

removal of the inferior portion of the interfrontal septum, the superior part of the nasal septum, and the frontal sinus floor to the orbit laterally with sparing of the lamina papyracea and posterior walls of the frontal sinus. In a series of 97 patients with frontal mucoceles 23% required revision surgery.<sup>5</sup> A review article by Scott et al reported a CSF leak rate of 6–11% with this procedure.<sup>6</sup>

A transcaruncular-transconjunctival approach avoiding skin incisions has been recently reported.<sup>7</sup> In this series of 11 cases with mean follow up of 12 months, there were no failures and the only complication noted was transient vertical diplopia due to damage to the superior oblique muscle. There is however some concern about possible long term failure as this approach involves removal of part of the lamina papyracea and restenosis could occur due to a collapse of the orbital contents into the defect.<sup>8</sup> The cosmetic result with this procedure is likely to be better than the other non-endoscopic-external approach procedures. Furthermore, surgical decompression of the lateral frontal sinus can be difficult compared to the described procedure.

Our procedure involved a skin crease approach with sparing of the supraorbital bundle, providing good access to the sinus. We found the endoscopic reestablishment of the ostium and the placing of the stent particularly useful in establishing a functioning ostium which we feel is the key to prevention of mucocele recurrences.

The only intraoperative complication noted in our series was a CSF leak. This complication occurred in a patient with a traumatic mucocele. This resulted from a significant head injury resulting from a fall off a ladder 15 years prior to presenting with the mucocele. The leak resolved without any sequelae.

Another complication that was noted was a vertical deviation secondary to superior oblique weakness possibly resulting from injury to the muscle in the region of the trochlea during surgery. The deviation was not noted prior to surgery, was stable when last seen and the patient reported no symptoms.

2 patients had lid scarring leading to retraction of the upper eyelid and required further surgery. It was interesting to note that these were the only patients in this series to have pre-

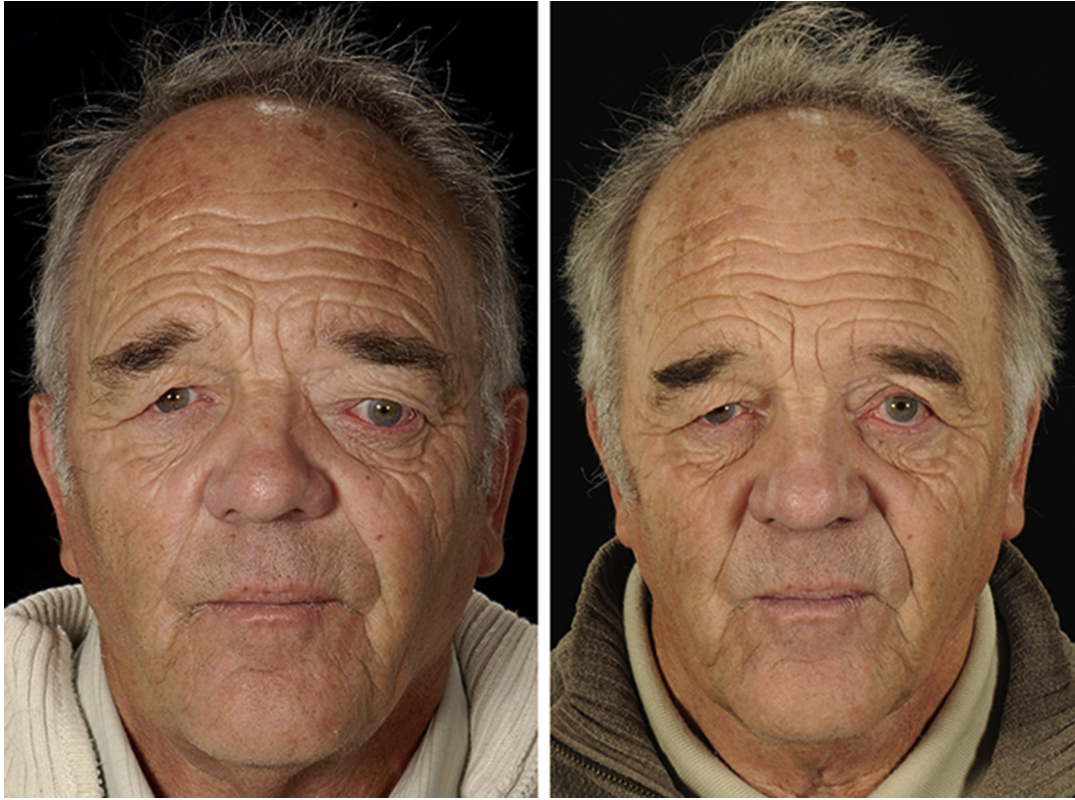

Fig. 6. Left: preoperative and Right: postoperative photo of a left inverted papilloma with recurrent frontal mucocele. Note the left eye hypoglobus prior to the surgery.

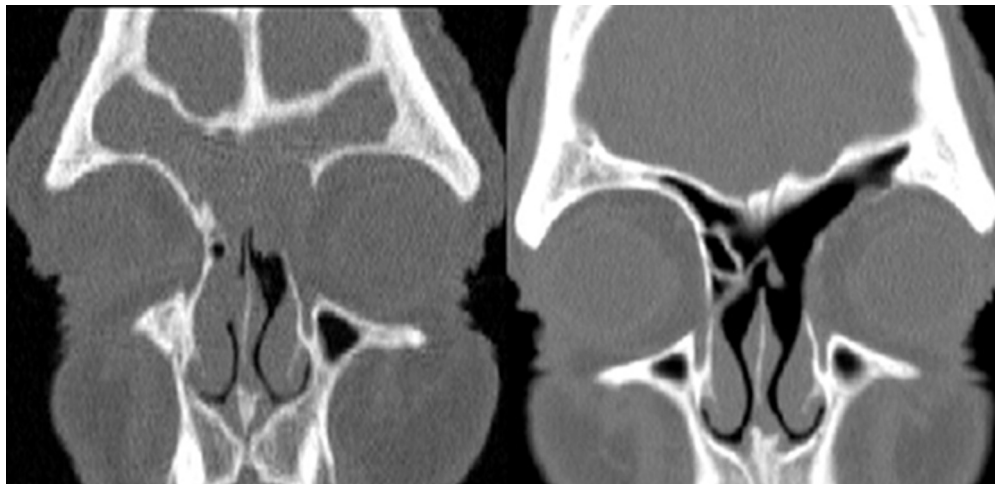

Fig. 7. Left: pre-operative and Right: post-operative scan after removal of inverted papilloma of patient in Fig. 6.

operative upper lid inflammatory changes indicating a breach in the floor of the frontal sinus and periosteum preoperatively. Both patients achieved an excellent cosmetic result (Figs. 4 and 5).

Our series included two patients with inverted transitional cell papillomas. One of the patients had 4 conventional procedures to treat multiple recurrences before he underwent the procedure described here and is recurrence free for over a year following surgery. The second patient had a recurrence

requiring repeat surgery with the adjunctive use of Mitomycin-C and was disease free when last seen. Inverted papillomas are known to recur following conventional sinus surgery. Mirza et al while reporting on their own series of 65 cases of inverted papillomas over 20 years also performed a met analysis and report a failure rate between 12.8% for endoscopic procedures and 34.2% for limited resections.<sup>9</sup>

In summary we report that the combined internal/external approach with the use of a transnasal stent provides a viable and

effective alternative for managing frontal mucocele and other frontal sinus pathology. This approach is now the preferred technique for management of inverted papillomas in our institution.

## References

1. Saldana M, Wearne M, Beigi B, Petrarca R. Inverted papillomas of the nasal and paranasal sinuses that involve the ocular/adnexal region. *Orbit*. 2013 Dec;32:366–369.
2. Lynch RC. The technique of a radical frontal sinus operation which has given me the best results. *Laryngoscope*. 1921;31:1–5.
3. Rice Dale H, Schaefer Steven D. *Endoscopic Paranasal Sinus Surgery*. 3rd ed. Lippincott Williams and Wilkins; 2004:219 [Chapter 12].
4. Weber R, Draf W, Keerl R, et al. Osteoplastic frontal sinus surgery with fat obliteration: technique and long-term results using magnetic resonance imaging in 82 operations. *Laryngoscope*. 2000 Jun;110:1037–1044.
5. Shirazi MA, Silver AL, Stankiewicz JA. Surgical outcomes following the endoscopic modified Lothrop procedure. *Laryngoscope*. 2007 May;117:765–769.
6. Scott NA, Wormald P, Close D, Gallagher R, Anthony A, Maddern GJ. Endoscopic modified Lothrop procedure for the treatment of chronic frontal sinusitis: a systematic review. *Otolaryngol Head Neck Surg*. 2003 Oct;129:427–438.
7. Lai PC, Liao SL, Jou JR, Hou PK. Transcaruncular approach for the management of frontoethmoid mucoceles. *Br J Ophthalmol*. 2003 Jun;87:699–703.
8. Khong JJ, Wormald P, Selva D. Transcaruncular approach for the management of frontoethmoidal mucoceles: a comment. *Br J Ophthalmol*. 2004 May;88:725. Comment on: *Br J Ophthalmol*. 2003 Jun;87(6):699–703.
9. Mirza S, Bradley PJ, Acharya A, Stacey M, Jones NS. J Sinonasal inverted papillomas: recurrence, and synchronous and metachronous malignancy. *Laryngolotol*. 2007 Sep;121:857–864.