

Early Resolution of Convergence Spasms Following the Addition of Antipsychotic Medications

Hyo Jin Hyun¹, Un Sun Chung², Bo Young Chun¹

¹Department of Ophthalmology, Kyungpook National University School of Medicine, Daegu, Korea

²Department of Psychiatry, Kyungpook National University School of Medicine, Daegu, Korea

We report a case of early resolution of convergence spasms following the addition of antipsychotic medications and present it as a possible alternative to the conventional treatment for convergence spasms. The cessation of atropinization of the eyes and the use of reading glasses was achieved after only 2 months following the initiation of antipsychotic medications for childhood emotional disorder.

Key Words: Antidepressants, Anxiolytics, Atropinization, Childhood emotional disorder, Convergence spasm

The triad of symptoms used to diagnose convergence spasms consists of intermittent episodes of sustained maximal convergence, accommodative spasm, and constriction of the pupils [1]. The etiology of convergence spasms is usually functional [1,2]. Unless an organic cause can be found, the treatment of convergence spasms consists of prolonged atropinization of the eyes and the prescription of plus lenses for reading glasses. This treatment may have to be applied for as long as one year [1].

We report a case of early resolution of convergence spasms following the addition of antipsychotic medications. These results were attained not only after the initiation of antipsychotic medications in the patient, but also following simultaneous medication of her mother's depression, which was the primary cause of the patient's emotional instability.

Case Report

A 7-year-old female presented complaining of intermittent diplopia and blurred vision for 2 months. The patient reported that her visual symptoms were most severe during the daytime. Her best corrected visual acuity was 20/100 in each

eye. The results of an ocular motility examination were normal. During an ocular alignment examination, she was found to be orthophoric at distance (Fig. 1). However, variable degrees (10 to 30 prism diopters [PD]) of esodeviation and miotic pupils were evident only at near fixation (Fig. 2). Her esodeviation did not change with the addition of +3.0 diopters (D) lenses. Autorefractometry was performed and -10 D of high myopia was found in each eye. However, cycloplegic refraction revealed that both eyes were nearly emmetropic (+0.5 D). The patient also complained of frequent headaches and abdominal pain; the results of all physical and neurological examinations were normal, including a brain magnetic resonance imaging with contrast. The patient was diagnosed with convergence spasms and was referred to the psychiatry department for her somatic complaints. Plus lenses (+1.5 D) for reading were prescribed for atropinization of her eyes.

One month after prescribing atropine eyedrops and reading glasses, the patient's best corrected visual acuity increased to 20/20. She was orthophoric at distance but still esotropic at near fixation without glasses. She continued to complain of intermittent diplopia, but the frequency and duration were decreased. However, the patient's mother did not bring her daughter to the psychiatric department; the patient was again referred to the Department of Psychiatry.

During a mental status examination at the Department of Psychiatry, the patient was noted to be hyperactive, impulsive, and irritable. Her mother appeared very depressed and her attitude toward her daughter was very cold. The patient was given a psychiatric diagnosis of childhood emotional disorder owing to an emotionally unavailable mother suffering from major depressive disorder. The psychiatrist

Received: November 23, 2009 Accepted: March 15, 2010

Corresponding Author: Bo Young Chun, MD, Department of Ophthalmology, Kyungpook National University School of Medicine, Dongin-dong 2-ga, Jung-gu, Daegu 700-422, Korea. Tel: 82-53-420-5818, Fax: 82-53-426-6552, E-mail: byjun424@hotmail.com

* This paper was presented as a poster at the 97th Annual Meeting of the Korean Ophthalmological Society, April 6, 2007, Busan, Korea.

© 2011 The Korean Ophthalmological Society

This is an Open Access article distributed under the terms of the Creative Commons Attribution Non-Commercial License (<http://creativecommons.org/licenses/by-nc/3.0/>) which permits unrestricted non-commercial use, distribution, and reproduction in any medium, provided the original work is properly cited.

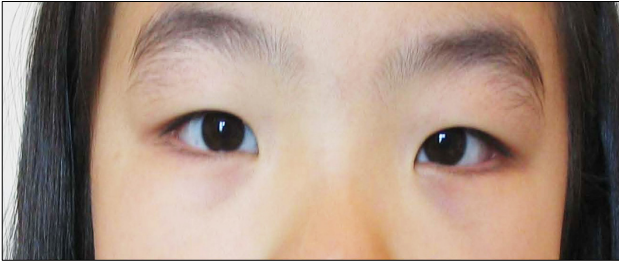

Fig. 1. The patient was orthophoric at distance.

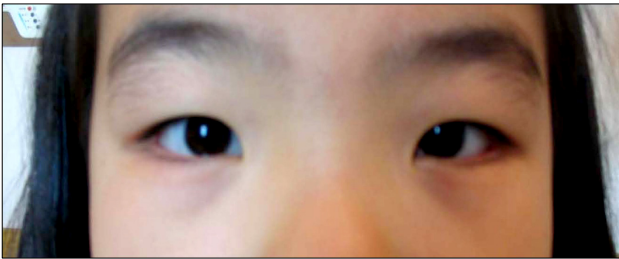

Fig. 2. The patient demonstrated esotropia of 15 to 20 prism diopters at near fixation. At this time, her pupils were constricted and autorefractometry performed immediately after near fixation revealed -10.0 diopters of pseudomyopia.

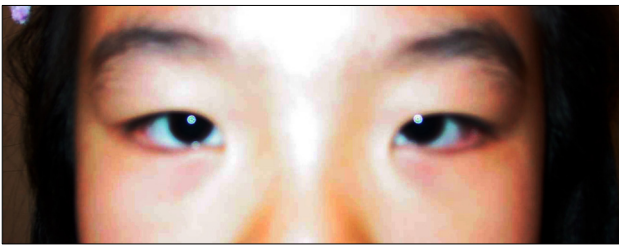


Fig. 3. The patient's esodeviation at near fixation resolved only one month after initiation of the antipsychotic medications. The patient's visual acuity was 20/20 without glasses and her refraction was nearly emmetropic (+ 0.5 diopters).

prescribed Sertraline[®] 25 mg p.o. (antidepressants, selective serotonin reuptake inhibitor [SSRI]) and Diazepam[®] 2 mg p.o. (anxiolytics, benzodiazepine) for the patient. Additionally, Escitalopram[®] 10 mg p.o. (antidepressants, SSRI) was prescribed for the patient's mother.

One month after initiation of the antipsychotic medications, the patient's esodeviation at near fixation was resolved and all somatic complaints had ceased (Fig. 3). The patient's visual acuity was 20/20 without glasses and her refraction was nearly emmetropic (+0.5 D). As such, successful cessation of the atropinization of the patient's eyes was achieved after only 2 months. After the patient and her mother finished 6 months of the antipsychotic medication regimen, no symptoms were evident of either convergence spasms or any other somatic disorders.

Discussion

The course of therapy for convergence spasms depends on

the etiology. Most convergence spasm cases are caused by a functional disorder, such as hysteria or neurosis. If an emotional etiology is suspected, psychological counseling is in order. Emotional instability may result in a variety of ocular manifestations besides convergence spasms, such as blurred vision, monocular diplopia, tunnel vision, blepharospasm, and nystagmus [3,4]. Emotional instability should be considered as a possible cause when patients present with these symptoms. If no signs of emotional problems are present, a thorough neurological work-up is recommended. There are several organic causes of convergence spasms, including encephalitis, tabes, labyrinthine fistulas, Arnold Chiari malformation, posterior fossa neurofibroma, trauma, and pituitary adenoma [3,4].

Some authors have reported positive outcomes from supportive psychotherapy and amytal interviews [5,6]. However, the conventional therapy for convergence spasms consists of atropinization of the eyes and the prescription of plus lenses for near vision [1]. It often takes several months to a year for ocular symptoms to dissipate [1]. It is useful to produce cycloplegia in an attempt to break the cycle of sustained maximal convergence and accommodative spasm. However, prolonged atropinization of the eyes can give rise to side effects. Dilated pupils can lead to photophobia and blurred vision with near fixation and the wearing of reading glasses can cause discomfort. Other adverse events may include allergic conjunctivitis and, rarely, fever and aggravation of asthma [7].

In the present case, the successful cessation of the atropinization of the patient's eyes was achieved only one month after the patient and her mother initiated antipsychotic medications. Of course, antidepressants and anxiolytics may result in side effects. Sertraline[®] may cause behavioral activation, nausea, and diarrhea [8]. These events may occur early in treatment with a high dose (>100 mg) of the drug or following the addition of drugs that inhibit the metabolism of SSRIs [8]. In addition, some patients also experience ataxia (<2%) and dizziness (<1%) with benzodiazepines [9]. However, most benzodiazepines, especially low potency benzodiazepines like diazepam, are generally well tolerated [9]. The low dose and low potency of the antipsychotic medications given to the present patient did not elicit any of these side effects.

We report a case of early resolution of convergence spasms after the addition of antipsychotic medications. Additional treatment for childhood emotional disorder, which was the indirect cause of the patient's convergence spasms, reduced the required duration of atropinization of the eyes from one year to 2 months. We recommend active referral and collaboration with psychiatrists when treating patients whose disease may be functional in origin. This course of action may reduce the duration of symptoms in certain patients.

Conflict of Interest

No potential conflict of interest relevant to this article was reported.

References

1. Von Noorden GK, Campos EC. *Binocular vision and ocular motility: theory and management of strabismus*. 6th ed. St. Louis: Mosby; 2002. p. 504-5.
2. Walsh FB, Hoyt WF. *Clinical neuro-ophthalmology*. 3rd ed. Baltimore: Williams and Wilkins; 1969. p. 230.
3. Rutstein RP, Galkin KA. Convergence spasm: two case reports. *J Am Optom Assoc* 1984;55:495-8.
4. Sarkies NJ, Sanders MD. Convergence spasm. *Trans Ophthalmol Soc U K* 1985;104(Pt 7):782-6.
5. Suzuki A, Mochizuki H, Kajiyama Y, et al. A case of convergence spasm in hysteria improved with a brief psychiatric assessment. *No To Shinkei* 2001;53:1141-4.
6. Schwartze GM, McHenry LC Jr, Proctor RC. Convergence spasm: treatment by amytal interview. A case report. *J Clin Neuroophthalmol* 1983;3:123-5.
7. Ventura MT, Di Corato R, Di Leo E, et al. Eyedrop-induced allergy: clinical evaluation and diagnostic protocol. *Immunopharmacol Immunotoxicol* 2003;25:529-38.
8. Lewis M. *Child and adolescent psychiatry: a comprehensive textbook*. 3rd ed. London: Lippincott Williams & Wilkins; 2002. p. 965.
9. Sadock BJ, Kaplan HI, Sadock VA. *Kaplan & Sadock's synopsis of psychiatry: behavioral sciences/clinical psychiatry*. 10th ed. Philadelphia: Lippincott Williams & Wilkins; 2007. p. 1018-22.