



Published in final edited form as:

Neurol India. 2020 ; 68(12 Suppl 2): S137–S140. doi:10.4103/0028-3886.287684.

The Roadmap to Pituitary in COVID-19 Crisis

Manjul Tripathi¹, Rajesh Chhabra², Pinaki Dutta³, Liza Das³, Sandeep Mohindra², Satyvati Mohindra⁴, Sonikpreet Aulakh⁵

¹Department of Neurosurgery, Gamma Knife Radiosurgery, Postgraduate Institute of Medical Education and Research, Chandigarh, India

²Department of Neurosurgery, Office, Nehru Hospital, 5th Floor, Postgraduate Institute of Medical Education and Reserach, Chandigarh, India

³Department of Endocrinology, Postgraduate Institute of Medical Education and Reserach, Chandigarh, India

⁴Department of ENT, Neurosurgery Office, Nehru Hospital, 5th Floor, Postgraduate Institute of Medical Education and Reserach, Chandigarh, India

⁵West Virginia University, Translational Neuro-Oncology, West Virginia Cancer Institute, 64 Medical Center Drive, PO Box 9162, Morgantown, WV, USA

“Those of us fighting the brain tumor beasts are a band of brothers and sisters. None of us wants to be on this journey, but we are, and so we fight, side by side, helping each other with love, information, and support.....”

-Dr. Michael Gabriel

The COVID-19 crisis has provoked a sense of insecurity among skull base surgeons. All surgeries en route nasal cavity, paranasal air sinuses, or upper airway are deemed especially dangerous due to a high risk of viral load and potential for aerosol generation during endonasal instrumentation.^[1] In fact, one of the first cases of nosocomial spread of SARS-CoV-2 was in a patient operated endoscopically for a pituitary adenoma in the neurosurgery department of Wuhan Hospital, the original epicentre of the current pandemic.^[2] The recent reports of higher morbidity and mortality among endoscopic skull base surgeons and otorhinolaryngologists are highly alarming.^[3] As far as neurosurgery is concerned, surgeries in the sellar region are the second most common surgeries to be performed after parenchymal glial cell tumors. The unique geographic position of sellar pathologies brings the optic apparatus and hypothalamic pituitary axis at high risk of permanent neurological and endocrinological injuries demanding expedited surgery, despite the ongoing SARS-CoV-2 scare.

This is an open access journal, and articles are distributed under the terms of the Creative Commons Attribution-NonCommercial-ShareAlike 4.0 License, which allows others to remix, tweak, and build upon the work non-commercially, as long as appropriate credit is given and the new creations are licensed under the identical terms. **For reprints contact:**reprints@medknow.com

Address for correspondence: Dr. Manjul Tripathi, Department of Neurosurgery, Neurosurgery Office, Nehru Hospital, 5th Floor, Postgraduate Institute of Medical Education and Reserach, Chandigarh - 160 012, India. drmanjultripathi@gmail.com.

There is an intrinsically high viral load of coronavirus in the nasal cavity compared to the pharynx and throat. The endonasal and anterior skull base surgeries are aerosol-generating procedures (AGPs) due to aggressive disruption of virus-containing mucosa. Endonasal surgeries further remain at higher risk than conventional surgeries due to prolonged duration of exposure as well as disruption of the surrounding paranasal sinuses. Once the viral particles become aerosolized, they remain active in the air for more than 3 hours. The risk of viral shedding is significantly high in the active phase of the infection.^[1-4]

In the early wake of the crisis, most of the leading centers throughout the world have arrested their pituitary and endoscopic skull base surgeries in view of the general concern. Many professional bodies including our 'Neurological Society of India' and 'Neurosurgery Society of Australia' have recommended: "serious consideration be given to avoid a transsphenoidal approach due to extremely high viral transmission risk".^[5,6] Now, we are in a state of dilemma where we would need a balanced approach to mitigate the transmission of SARS-CoV-2 while ensuring timely and standard care to the patients. It is a time for "risk mitigation approach" for patients to optimize patient outcomes, continue resection for emergency indications like pituitary apoplexy and compromised vision, initiate appropriate medical management with monitoring for deterioration or adverse effects by virtual consults; all while safeguarding the health professionals.^[6]

Tailored Neurosurgical Care during COVID Crisis

The management of pituitary adenoma is a tiresome journey for the patient, and it cannot be prolonged indefinitely in view of the COVID-19 crisis. We have to accept the fact that COVID-19 is going to stay for longer than our earlier perception. Hence, patient management needs to be tailored not refused. The endoscopic endonasal approach is now a standard treatment for pituitary adenoma. The treatment need not be changed in view of the ongoing pandemic and we need to gradually return to our usual practice though with caution.

The onus lies on proper and increased testing facilities for these patients. We need better testing facilities which are easily available, reliable, faster, and patient-friendly. Ensuring testing for all these patients will help to reduce the collateral damage, discrimination, overall cost of the treatment, morbidity, and mortality profile, while building confidence in the treating team and ensuring the safety of all.^[7] The COVID-19 fear is real. However, COVID-19 negative patients need not suffer in this pandemic. A COVID-19 negative patient should receive standard timely care with endoscopic approaches.

Wherever possible, we should postpone surgery for COVID-19 positive patients until they become COVID-19 negative. For a COVID-19 patient, the COVID status needs to be addressed first followed by neurosurgical ailment [Figure 1]. The published literature has highlighted the high risk of periprocedure mortality and morbidity in COVID-19 positive patients.^[7] COVID-19 suspected or patients with unknown status should be considered COVID-19 positive until proven otherwise, to safeguard the resources. They should receive surgical intervention only in an utmost emergency. There is an ongoing confusion over the exact mechanisms of virus transmission, degree of aerosolization, amount of viral load

exposure, and lack of data on appropriate personal protective equipment (PPE) in endonasal AGPs. We advocate precautions for preoperative, intraoperative and postoperative phases [Figure 2]. A COVID-19 positive status of the patient puts a huge burden on the healthcare resources. Therefore, every COVID-19 positive patient in need of emergency surgery should be referred to COVID designated hospital only to mitigate spread among other health care workers (HCWs).

Endocrine Management and Emergency Surgical Indications during the COVID-19 Pandemic

Though slow-growing requiring elective surgery, adenomas with visual disturbances, and/or apoplexy are a medical emergency which mandates emergency management. One absolute surgical indication is pituitary apoplexy with progressive visual deterioration. Isolated radiologic diagnosis of apoplexy or apoplexy with minimal clinical features such as restriction of extraocular movements or no/minimal but static visual deficit does not warrant surgery. Diagnosis of these situations may be difficult without the of all required investigations. Clinical clues including acute-onset headache, visual acuity or field disturbances, diplopia, ptosis, epistaxis or seizures (undiagnosed adrenal insufficiency or hypothyroidism) can be used to diagnose adenomas with emergency indications. A management algorithm keeping in mind the dynamicity of the disease has been proposed [Figure 3].

Should We Advocate Alternative Approaches

In some compelling indications like rapid visual deterioration, especially in adenomas with suprasellar component, transcranial surgery is an alternative approach if there is not enough time to wait for the COVID-19 investigation [Figure 3]. We should avoid nasal packing or pledges, as they need to be removed in the postoperative period inducing cough/sneeze. The surgeon may also consider microscopic trans-sphenoidal surgery with submucosal approach and sellar exploration with no drill technique,^[8] though there is no compelling evidence if submucosal approach is safer than endoscopic approaches.

Managing the Operation Room

Informal, UK and US advisories have advocated the use of powered, air purifying respirators (PAPRs) for all operating room staff during the conduct of high-risk AGPs.^[1,2] They have suggested that N95 and eye protection may not be suffice for AGPs. The entire surgical and ICU teams should don PAPRs during surgery. We should avoid aerosol generating steps such as the use of high-speed drills and debridors; rather use rongeurs, debridors, and punches which are non-thermal procedures. Usage of topical anaesthetics prior to intubation can reduce cough and consequently aerosolization. Similarly, observation for a couple of hours in the OR post extubation can be helpful by reducing risk to unprepared healthcare workers in case of emergency re-intubation. Furthermore, due to the neurotropism of the virus, dural handling during the surgery should be minimised. Survival of SARS-CoV-2 on various types of surfaces, leading to fomite transmission is a real challenge to be addressed. Endoscopes and other surgical instruments can be disinfected by agents containing 70% ethanol, 0.1%

sodium hypochlorite or 0.5% hydrogen peroxide. Non-disposable equipment should be double-bagged in red biohazard bags for transport for centralized cleaning. Disposable equipment should be discarded.^[1,2]

The Vision for the Future

COVID-19 crisis is an evolving and dynamic crisis. We are routinely getting new evidence and insights for its pathogenesis and neurological manifestations. Till now, we have no measures to cure the viral disease and caution is the only proven way to safeguard the health care workers (HCWs). The published reports have highlighted the high risk of complications secondary to the COVID-19 status of the patients. The patients with sellar pathologies frequently suffer from some endocrinological disturbances predominantly hypocortisolemia. It precipitates poor immune response and makes such a patient at higher risk of infection. The patient should be explained the reasons and outcomes of the delayed treatment vis-a-vis surgery in the pandemic. Further, virtual consults or usage of telemedicine facilities for non-emergency follow-up of patients can be effective in ensuring social shielding which may be especially important for patients with immunosuppression like Cushing's disease (CD) or diabetes secondary to CD or acromegaly. Radiation treatment, especially Gamma knife radiosurgery (GKRS), should not be delayed as it needs limited resources and can be performed as a day care procedure without challenging logistic constraints. Routine radiation therapy, including intensity modulated radiation therapy (IMRT), needs longer time and may be delayed in view of logistic constraints. We need a systemic worldwide audit of the patients operated in the COVID-19 pandemic, outcome of the patients delayed due to crisis and actual efficacy of our efforts in risk mitigation strategy.

The Empathy

Management of a pituitary disorder demands a multimodal, multidisciplinary care which includes long hours of investigations, clinical evaluations, discussions with endocrinologists, neurosurgeons, ophthalmologists, and sometimes psychiatrists. It is equally important to inform the patient if the treatment is being postponed. Such an information should be detailed, properly explained, but in an empathetic tone – otherwise, tire ongoing crisis may get severely compounded affecting the mental health. We need to reassure diem of the chosen approach. Virtual connections are the means to ease the anxiety and timely information would prove to be of great help.

Conclusion

These recommendations do not advocate that surgeries should be done as a normal procedure during pandemic. In the selected cohort of the patients, endoscopic surgeries can be performed taking due consideration of COVID-19 assessment and safety parameters. In case of no compelling indications for emergency surgery, medical management can be effectively employed with close surveillance for efficacy and adverse effects.^[9] In the long run, we need psychologically safe health care workers and a dedicated multidisciplinary team to improve patient outcomes in proportion to the risk, and country-specific resources.

References

1. Lo YT, Teo NXY, Ang BT. Endonasal neurosurgery during COVID-19 pandemic: The Singapore perspective. *J Neurosurg* 2020;17:1–3.
2. Zhu W, Huang X, Zhao H, Jiang X. A COVID-19 patient who underwent endonasal endoscopic pituitary adenoma resection: A case report. *Neurosurgery* 2020;nyaa147. doi: 10.1093/neuros/nyaa147. Online ahead of print.
3. Patel ZM, Fernandez-Miranda J, Hwang PH, Nayak JV, Dodd R, Sajjadi H, et al. Letter: Precautions for endoscopic transnasal skull base surgery during the COVID-19 pandemic. *Neurosurgery* 2020;nyaa125. doi: 10.1093/neuros/nyaa125. Online ahead of print.
4. Kolas A, Tysome J, Donnelly N, Sharma R, Klotsas EG, Budohoski K, et al. A safe approach to surgery for pituitary and skull base lesions during the COVID-19 pandemic. *Acta Neurochir (Wien)* 2020:1–3. doi: 10.1007/s00701-020-04396-5. Online ahead of print.
5. Mitchell RA, King JAJ, Goldschlager T, Wang YY. Impact of COVID-19 on pituitary surgery. *ANZ J Surg* 2020. doi: 10.1111/ans.15959. Online ahead of print.
6. Gupta P, Muthukumar N, Rajshekhar V, Tripathi M, Thomas S, Gupta SK, et al. Neurosurgery and neurology practices during the Novel COVID-19 pandemic: A consensus statement from India. *Neurol India* 2020;68:246–54. [PubMed: 32414996]
7. Nahshon C, Bitterman A, Haddad R, Hazzan D, Lavie O. Hazardous postoperative outcomes of unexpected COVID-19 infected patients: A call for global consideration of sampling all asymptomatic patients before surgical treatment. *World J Surg* 2020;1–5. doi: 10.1007/s00268-020-05575-2. Online ahead of print.
8. Jenkins A Letter: Transmission of COVID-19 During Neurosurgical Procedures-Some Thoughts From the United Kingdom. *Neurosurgery* 2020;nyaa126. doi: 10.1093/neuros/nyaa126. Online ahead of print.
9. Gupta P, Muthukumar N, Rajshekhar V, Tripathi M, Thomas S, Gupta SK, et al. Neurosurgery and Neurology Practices during the Novel COVID-19 Pandemic: A Consensus Statement from India. *Neurol India* 2020;68:246–54. [PubMed: 32414996]

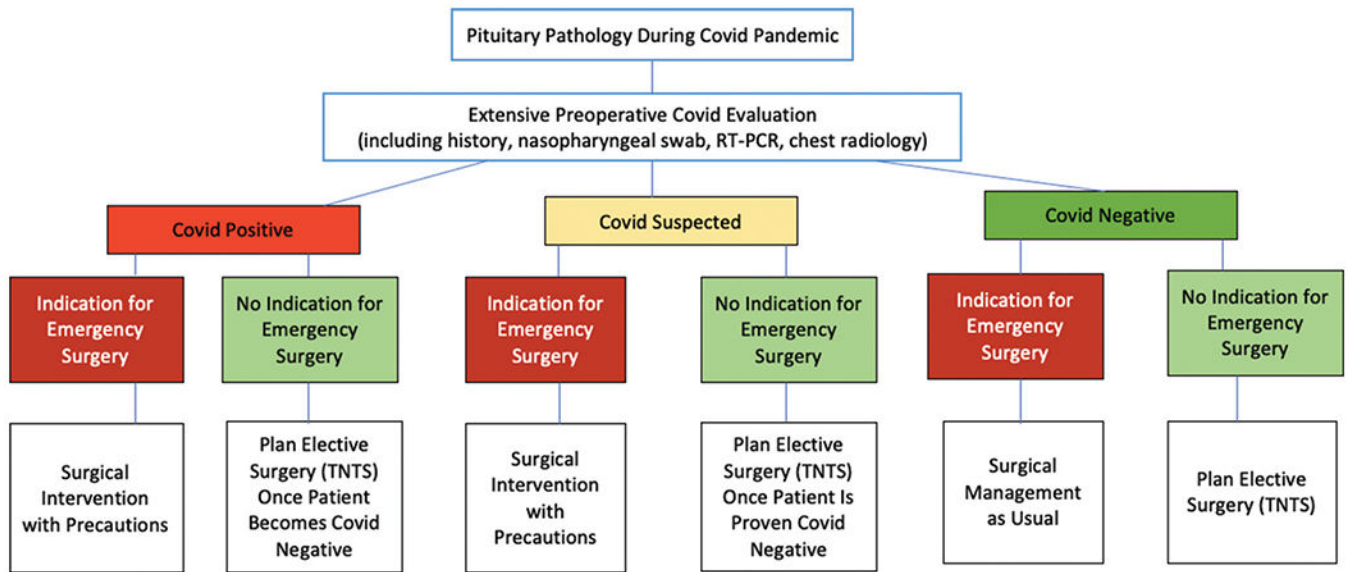


Figure 1: Risk mitigation strategy for sellar pathologies during COVID-19 pandemic (COVID-19, corona virus 19; TNTS, transnasal transsphenoidal surgery)

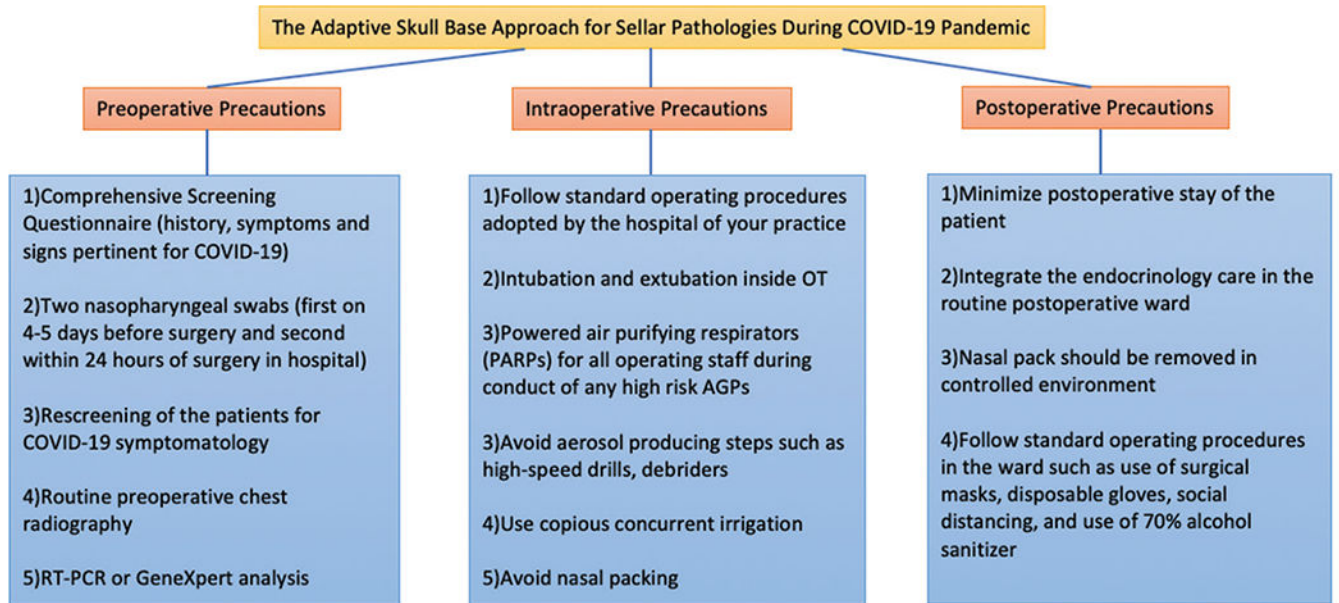


Figure 2:
The Adaptive skull base approach for sellar pathologies during COVID-19 pandemic (AGP, aerosol generating procedures; COVID-19, corona virus 19; RTPCR, reverse transcriptase polymerase chain reaction)

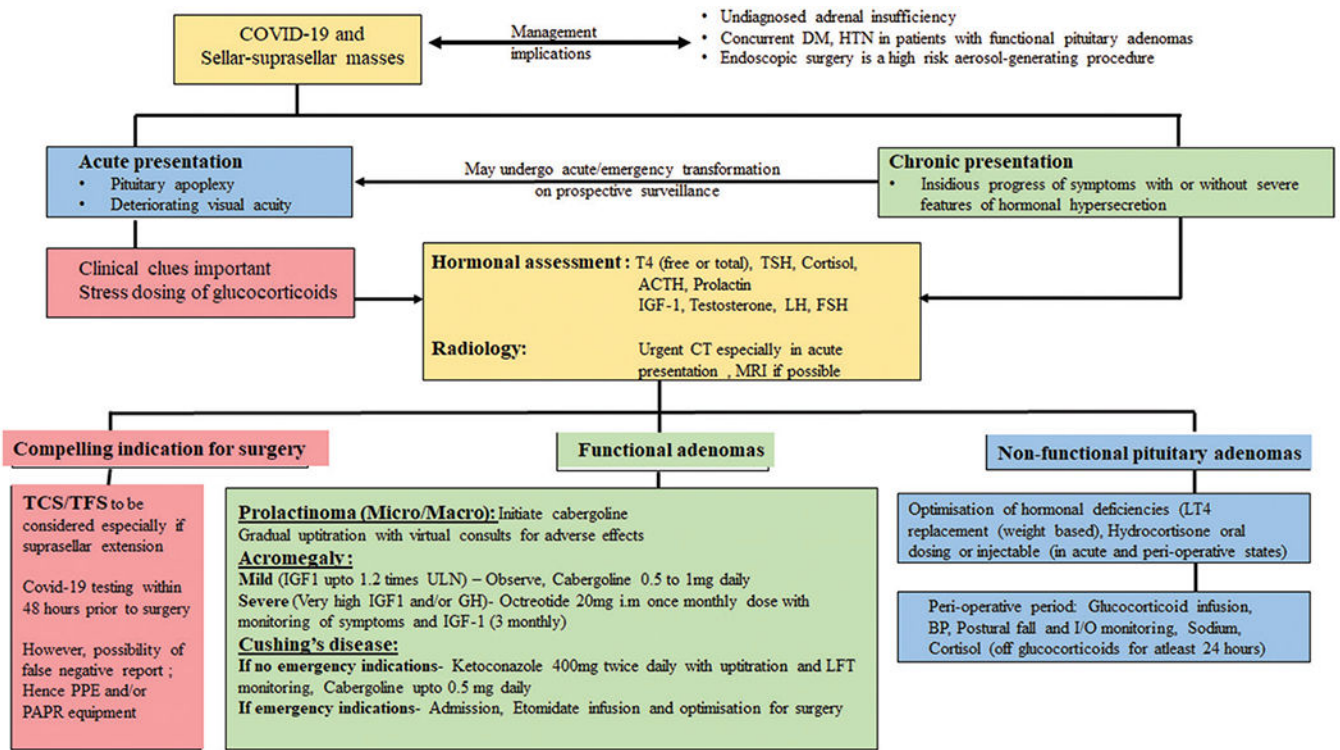


Figure 3: Proposed algorithm for remodelling of endocrinological management of pituitary adenomas during the COVID crisis (ACTH- Adrenocorticotrophic hormone; BP- Blood pressure; CT- Computerised tomography; DM- Diabetes mellitus; FSH- Follicle stimulating hormone; HTN- Hypertension; I/O- Input/output IGF-1- Insulin like growth factor-1; LT4- Levothyroxine; LFT- Liver function test; LH- Luteinising hormone; MRI- Magnetic resonance imaging; PAPR- Powered air-purifying respirator; PPE- Personal protective equipment; T4- Tetraiodothyronine; TSH- Thyroid stimulating hormone; TCS- Transcranial surgery; TFS- Trans-frontal surgery; ULN- Upper limit of normal;)