

[CASE REPORT]

Ischemic Stroke Due to Spontaneous Dissection of the Brachiocephalic to the Common Carotid Artery with a Fatal Course after Expansion to the Ascending Aorta

Kazumasa Oura, Mitsunobu Sato, Mao Yamaguchi Oura, Ryo Itabashi and Tetsuya Maeda

Abstract:

Spontaneous dissection of the brachiocephalic artery is rare, and there is insufficient evidence for optimal treatment. We herein report a case of ischemic stroke due to spontaneous dissection of the brachiocephalic to the right common carotid artery. The patient was treated medically but died suddenly 18 days after the onset because of aortic dissection. Although almost all reported cases of spontaneous dissection of the brachiocephalic artery have had good outcomes with medical management, it is important to note that sudden development of aortic dissection might occur, even without initial findings suggestive of this condition.

Key words: brachiocephalic artery dissection, aortic dissection, stroke

(Intern Med 61: 2483-2487, 2022)

(DOI: 10.2169/internalmedicine.8931-21)

Introduction

Spontaneous dissection of a cervical artery is rare, with an incidence of approximately 3 per 100,000 people per year; however, this condition is one of the most common causes of juvenile stroke, accounting for 10-25% of all cases (1, 2). Notably, cases with spontaneous brachiocephalic artery dissection are even less frequently reported (3-7).

We herein report a case of spontaneous dissection of the brachiocephalic and the right common carotid artery (CCA) with sudden chest pain and transient left paresthesia.

Case Report

A 56-year-old man was admitted to our department 150 minutes after the onset of sudden chest pain and transient left paresthesia. He had untreated hypertension and no recent history of trauma and had smoked for 36 years. Furthermore, his brother had a history of aortic dissection.

Upon admission, his neurological findings were normal, and chest pain and paresthesia had resolved. His blood pressure measurement was 94/57 mmHg without a marked dif-

ference between the right and left sides. His pulse rate was 47 beats/min, and his body temperature was 36.9°C. He was 169 cm tall and weighed 51 kg, and there were no skin or skeletal abnormalities.

Electrocardiography showed no abnormalities, and contrast-enhanced computed tomography (CT) of the neck and chest revealed acute dissection involving the origin of the brachiocephalic artery (Fig. 1A) that extended into the right CCA (Fig. 1B). There were no findings suggestive of aortic dissection in the ascending aorta (Fig. 1C) or aortic arch (Fig. 1D). On carotid ultrasonography, the false lumen communicated with the true lumen at the immediately proximal segment of the internal carotid artery (ICA) (Fig. 2A, B). Blood chemistry test results showed elevated brain natriuretic peptide (88.8 ng/L), and no other abnormalities, including D-dimer concentrations, were observed. Diffusion-weighted imaging showed acute infarcts in the right frontal lobe (Fig. 3A), and magnetic resonance angiography showed no abnormalities in the intracranial arteries (Fig. 3B).

He was treated with oral aspirin. His blood pressure was maintained at approximately 90/60 mmHg without antihypertensive treatment, and the pulse rate was approximately 40 beats/min. Contrast-enhanced CT obtained six days after

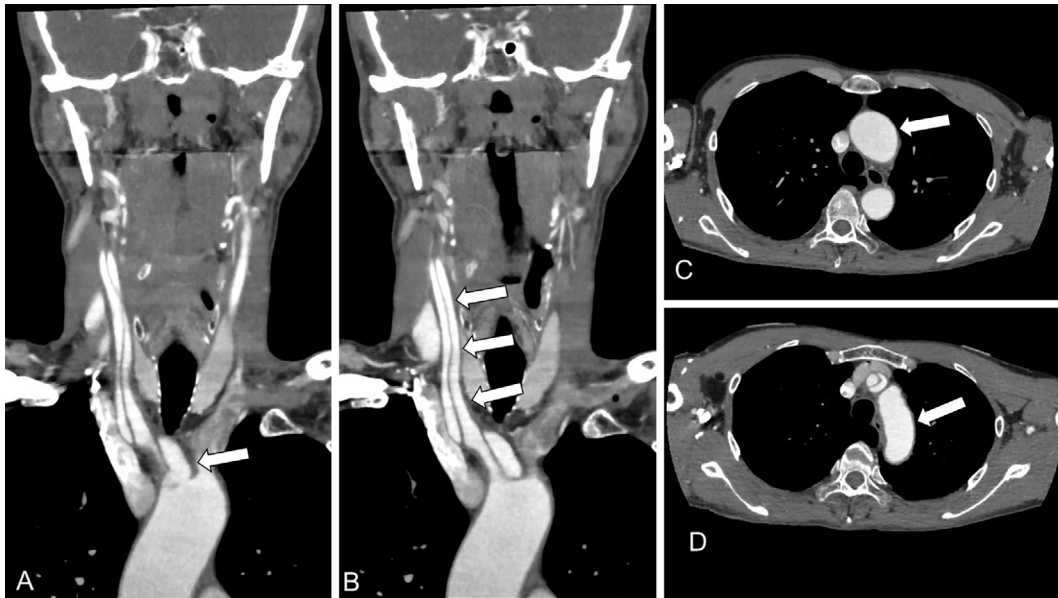


Figure 1. Initial contrast-enhanced CT of the neck and chest. Coronal images showing arterial dissection extending from the brachiocephalic artery (A, arrow) to the right CCA (B, arrows). The true lumen (B, arrows) is seen in the arterial dissection. Axial images showing no findings suggestive of aortic dissection in the ascending aorta (C, arrow) or aortic arch (D, arrow). CT: computed tomography, CCA: common carotid artery

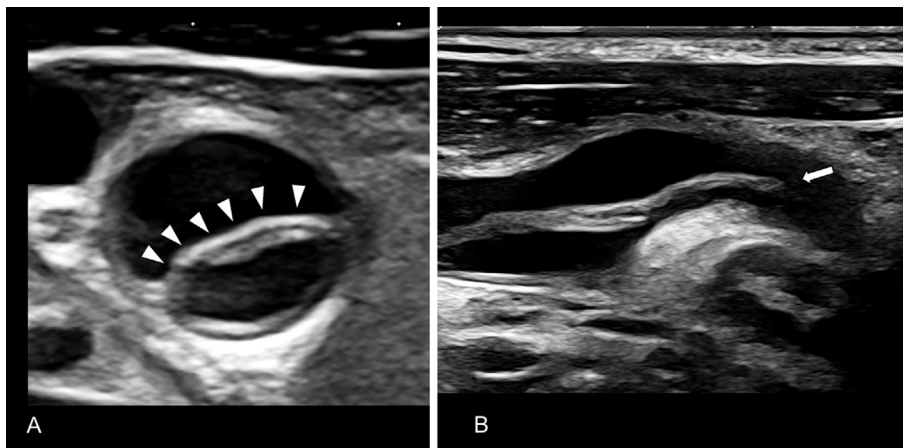


Figure 2. Carotid ultrasonography of the right CCA to the extracranial ICA. A) Axial B mode image showing an intimal flap in the right CCA (arrowheads). B) Longitudinal B mode image showing the false lumen communicating with the true lumen at the immediately proximal segment of the internal carotid artery (arrow). CCA: common carotid artery, ICA: internal carotid artery

the stroke onset showed slight enlargement of the false lumen in the brachiocephalic artery and the right CCA; however, we decided not to perform surgical treatment based on the asymptomatic course and the carotid ultrasonography findings suggesting a sufficient anterograde blood flow in the ICA. Contrast-enhanced CT obtained 15 days after the stroke onset showed no change in the dissection. Eighteen days after the stroke onset, he suddenly complained of chest pain, which was followed by pulseless electrical activity five minutes later. Although we performed immediate cardiopulmonary resuscitation measures, including tracheal intubation and pericardiocentesis for cardiac tamponade, which was

suggested by transthoracic echocardiography, the patient did not recover and died 90 minutes after the sudden chest pain.

Whole-body CT obtained after death showed extended arterial dissection not only at the brachiocephalic artery but also from the ascending aorta to the descending aorta just before the celiac artery, as well as massive pericardial effusion (Fig. 4).

Discussion

The cause of spontaneous cervical artery dissection has not been definitively elucidated, and it is speculated to be

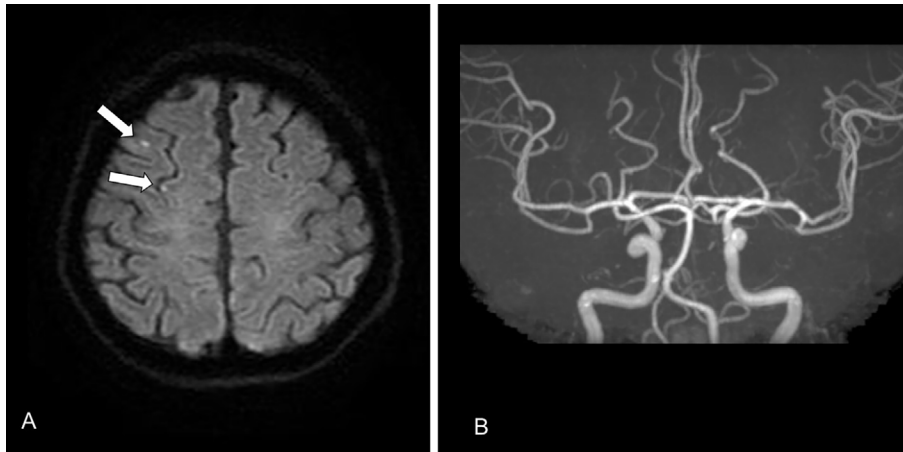


Figure 3. Brain MRI and MRA findings on admission. A) Diffusion-weighted images showing acute cerebral infarcts scattered in the right frontal lobe (arrows). B) MRA did not show occlusion or stenosis of the major cerebral arteries. MRI: magnetic resonance imaging, MRA: magnetic resonance angiography

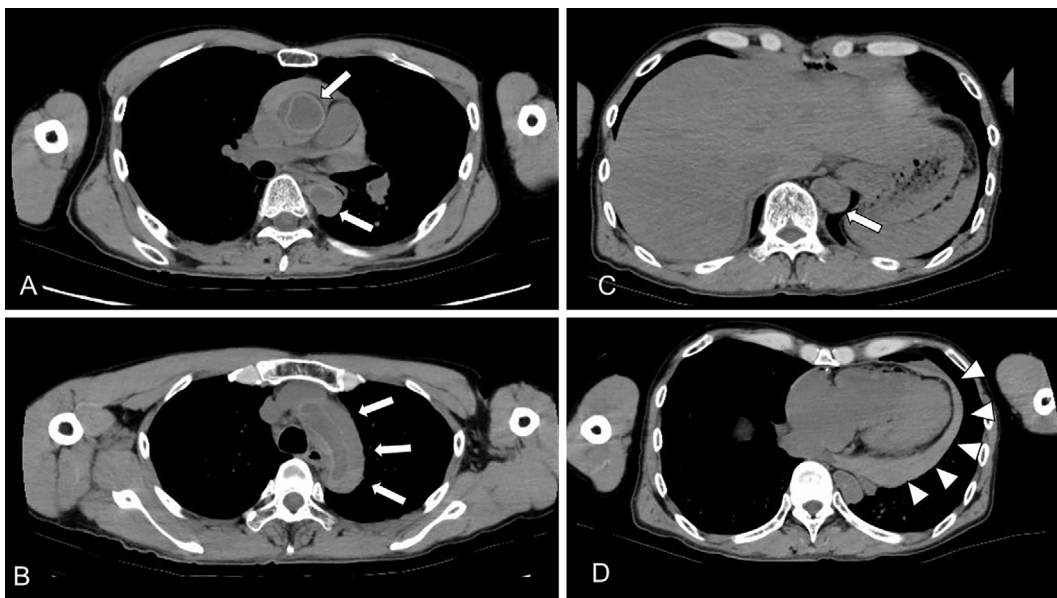


Figure 4. Whole-body CT after death. A-D) Consecutive axial non-contrast CT whole-body images showing extended arterial dissection not only at the brachiocephalic artery but also from the ascending aorta to the descending aorta just before the celiac artery (arrows). Massive pericardial effusion is also visible (arrowheads). CT: computed tomography

multifactorial, involving genetic predisposition, environmental factors, such as trivial trauma, and infections (2). As in the present case, low blood pressure and bradycardia can be caused by carotid sinus syndrome owing to carotid artery dissection (8). It is presumed that ischemic stroke or transient ischemic attack (TIA) is caused by embolism from the dissected arteries (9). Although several randomized controlled trials have been performed to determine the optimal antithrombotic treatment for patients with ischemic stroke or TIA due to carotid artery dissection, there is no consensus concerning whether antiplatelet treatment or anticoagulation is suitable.

In the Cervical Artery Dissection in Stroke Study

(CADISS) trial, there was no significant difference in outcomes between anticoagulation and antiplatelet treatment in 250 patients with cervical artery dissection (10). The TREAT-CAD trial, which was designed to address the non-inferiority of aspirin, failed to prove the non-inferiority of antiplatelet treatment with aspirin to the warfarin group in 194 patients with symptomatic cervical artery dissection (11).

The characteristic point of this case was that arterial dissection had extended not only to the CCA but also to the brachiocephalic artery. The details of five previously reported similar cases and the present case are summarized in Table. All patients were men, and except for a case of rup-

Table. Summary of Previous Reports of Spontaneous Dissection of the Brachiocephalic Artery.

Case No.	Reference	Age	Sex	Location of dissection	Neurological symptoms	Treatment	Outcome
1	(6)	61	Male	Brachiocephalic artery (ruptured)	None	Surgery	Developed type A aortic dissection and underwent reoperation
2	(7)	67	Male	Brachiocephalic artery	Left hemiparesis and dysarthria	rt-PA (for stroke), anti-hypertensive treatment	Fluctuation of symptoms followed by worsening
3	(4)	41	Male	Brachiocephalic artery and right CCA	Ataxia, slurred speech, and left facial weakness	Heparin	No additional event
4	(3)	68	Male	Brachiocephalic artery, right CCA, and right subclavian artery	None	Anti-hypertensive treatment, aspirin, and warfarin	No additional event at 6 months
5	(5)	50	Male	Brachiocephalic artery and right subclavian artery	None	Anti-hypertensive treatment and aspirin	No additional event 1 year later
6	The present case	56	Male	Brachiocephalic artery and right CCA	Transient left paresthesia	Aspirin	Developed acute type A aortic dissection and died

rt-PA: recombinant tissue plasminogen activator, CCA: common carotid artery

ruptured dissection that was initially treated surgically (case No. 1) (6), all cases were treated medically (case No. 2-5) (3-5, 7). Case No. 1 required surgical repair of the aortic arch because of subsequent aortic dissection two weeks after initial surgical replacement of the brachiocephalic artery (6). In comparison, the present case was also treated medically with aspirin; however, he developed aortic dissection with a fatal outcome. Although surgical treatment is standard for aortic dissection involving the ascending aorta (12), there were no clinical or radiological findings suggestive of aortic dissection except for transient chest pain at the onset, in the present case. Therefore, we had insufficient time to surgically repair the aortic arch because of the rapid course of the aortic dissection.

Because of the small number of reported cases, there is no consensus concerning the treatment of brachiocephalic artery dissection not involving the ascending aorta (3, 5). Karmy-Jones et al. reported that patients with traumatic dissection of the brachiocephalic artery were able to be managed medically, but patients with a pseudoaneurysm should be treated surgically because of the risk of vessel rupture (13). In addition, some reports have recommended surgical treatment even in patients with asymptomatic aneurysms, not because of arterial dissection but because of the presumed high risk of vessel rupture (14).

It might be difficult to predict progression to aortic dissection in patients with spontaneous dissection of the brachiocephalic artery. In the literature, we were unable to find any marked differences, including in radiological findings, between the cases with and without aortic dissection. To our knowledge, the only report of aortic dissection after idiopathic brachial artery dissection was published by Munakata et al. (6). In their case, aortic dissection occurred two weeks after surgery for a ruptured brachiocephalic ar-

tery (6). Although it is well known that Marfan's syndrome and bicuspid aortic valve are risk factors for aortic dissection (15), our patient had no skeletal abnormalities suggestive of Marfan's syndrome, and the aortic valve was tricuspid. However, he had untreated hypertension and a family history of aortic dissection. It has been reported that 15-30% of patients with aortic aneurysms or dissection have a family history of these conditions (16). Even after excluding individuals with Marfan syndrome or bicuspid aortic valve, a family history of aortic dissection has been shown to be associated with an increased risk of aortic dissection (17). Furthermore, smoking is also a risk factor for aortic dissection (18), and our patient was a current smoker. These risk factors for aortic dissection might be related to subsequent aortic dissection in patients with spontaneous brachiocephalic artery dissection. The common risk factors of brachiocephalic artery dissection and aortic dissection are unclear at present. However, this patient developed aortic dissection, suggesting the possibility of a common vascular vulnerability. The further accumulation of cases is warranted to establish the optimal indications for surgery for spontaneous brachiocephalic artery dissection.

Conclusion

In conclusion, we encountered a case of spontaneous dissection of the brachiocephalic to the right CCA followed by sudden fatal aortic dissection. It is important to note that the sudden development of aortic dissection might occur in cases of spontaneous dissection of the brachiocephalic artery, without initial findings suggestive of aortic dissection.

The authors state that they have no Conflict of Interest (COI).

Acknowledgment

We thank Jane Charbonneau, DVM, for editing a draft of this manuscript.

References

- Lee VH, Brown RD Jr, Mandrekar JN, Mokri B. Incidence and outcome of cervical artery dissection: a population-based study. *Neurology* **67**: 1809-1812, 2006.
- Debette S, Leys D. Cervical-artery dissections: predisposing factors, diagnosis, and outcome. *Lancet Neurol* **8**: 668-678, 2009.
- Seese L, Kilic A, Navid F, Gleason TG, Sultan I. Nonoperative management of brachiocephalic artery dissection. *Ann Thorac Surg* **107**: e97-e99, 2019.
- Mani H, Ahluwalia S. Isolated brachiocephalic artery dissection presenting as acute stroke. *BMJ Case Rep* **2015**: bcr2014208815, 2015.
- Sharaf OM, Martin TD, Jeng EI. Management of a spontaneous supra-aortic arterial dissection: a case report. *J Med Case Rep* **15**: 283, 2021.
- Munakata H, Okada K, Tanaka H, Yamashita T, Nakagiri K, Okita Y. Acute dissection of the innominate artery: a case of report. *Gen Thorac Cardiovasc Surg* **56**: 131-133, 2008.
- Sansone T, Baroncelli S, Tozzetti C, Berni A, Torri M. Challenges in management of ischemic stroke secondary to brachiocephalic artery dissection. *Intern Emerg Med* **8**: 181-183, 2013.
- Smith JK, Castillo M. Carotid sinus syndrome secondary to iatrogenic dissection of the carotid artery. *AJNR Am J Neuroradiol* **15**: 193, 1994.
- Engelter ST, Traenka C, Von Hessling A, Lyrer PA. Diagnosis and treatment of cervical artery dissection. *Neurol Clin* **33**: 421-441, 2015.
- Markus HS, Hayter E, Levi C, Feldman A, Venables G, Norris J; The CADISS trial investigators. Antiplatelet treatment compared with anticoagulation treatment for cervical artery dissection (CADISS): a randomised trial. *Lancet Neurol* **14**: 361-367, 2015.
- Engelter ST, Traenka C, Gensicke H, et al. Aspirin versus anticoagulation in cervical artery dissection (TREAT-CAD): an open-label, randomised, non-inferiority trial. *Lancet Neurol* **20**: 341-350, 2021.
- Evangelista A, Isselbacher EM, Bossone E, et al. Insights from the International Registry of Acute Aortic Dissection: a 20-year experience of collaborative clinical research. *Circulation* **137**: 1846-1860, 2018.
- Karmy-Jones R, DuBose R, King S. Traumatic rupture of the innominate artery. *Eur J Cardiothorac Surg* **23**: 782-787, 2003.
- Kieffer E, Chiche L, Koskas F, Bahnini A. Aneurysms of the innominate artery: surgical treatment of 27 patients. *J Vasc Surg* **34**: 222-228, 2001.
- Golledge J, Eagle KA. Acute aortic dissection. *Lancet* **372**: 55-66, 2008.
- Coady MA, Davies RR, Roberts M, et al. Familial patterns of thoracic aortic aneurysms. *Arch Surg* **134**: 361-367, 1999.
- Chen SW, Kuo CF, Huang YT, et al. Association of family history with incidence and outcomes of aortic dissection. *J Am Coll Cardiol* **76** (10): 1181-1192, 2020.
- Landenhed M, Engström G, Gottsäter A, et al. Risk profiles for aortic dissection and ruptured or surgically treated aneurysms: a prospective cohort study. *J Am Heart Assoc* **4**: e001513, 2015.

The Internal Medicine is an Open Access journal distributed under the Creative Commons Attribution-NonCommercial-NoDerivatives 4.0 International License. To view the details of this license, please visit (<https://creativecommons.org/licenses/by-nc-nd/4.0/>).