






# Surgical Techniques to Prevent Nipple-Areola Complex Malposition in Two-Stage Implant-Based Breast Reconstruction

Takako Komiya, MD, PhD<sup>1</sup>  Yosuke Ojima, MD<sup>1</sup>  Takashi Ishikawa, MD, PhD<sup>2</sup>   
Hajime Matsumura, MD, DMSc, FACS<sup>1</sup> 

<sup>1</sup> Department of Plastic and Reconstructive Surgery, Tokyo Medical University, Tokyo, Japan

<sup>2</sup> Department of Breast Surgery, Tokyo Medical University, Tokyo, Japan

Address for correspondence Takako Komiya, MD, PhD, 6-7-1 Nishishinjyuku Shinjyuku-ku, Tokyo 160-0023, Japan (e-mail: takapinsmile@gmail.com).

Arch Plast Surg 2022;49:580–586.

## Abstract

**Background** Appropriate position of the nipple-areolar complex (NAC) is crucial following nipple-sparing mastectomy (NSM). The prevention of NAC malposition in two-stage implant-based breast reconstruction has not been well described, and the efficacy of the techniques has not been evaluated. This study aimed to evaluate the efficacy of our technique to prevent NAC malposition in patients who underwent implant-based breast reconstruction after NSM.

**Methods** Patients who underwent two-stage implant-based breast reconstruction with NSM between January 2012 and December 2019 were included. We used a surgical technique to fix the NAC to the rigid base, assuming a pocket-like appearance, with pectoralis major muscle and lateral adipofascial flap at the time of tissue expander (TE) insertion. Patients were classified into two groups based on the performance of the technique for the prevention of NAC malposition.

**Results** In 35 patients who underwent implant-based breast reconstruction after NSM, the clavicle-to-nipple distance ratio was  $96.0 \pm 5.0\%$  in those who underwent NAC fixation and  $86.1 \pm 11.5\%$  in those who did not undergo NAC fixation.

**Conclusions** Using our technique, NAC malposition could be prevented in two-stage implant-based breast reconstruction. NAC fixation during TE insertion was found to be extremely effective. This procedure successfully prevented NAC malposition without the formation of extra scars.

## Keywords

- ▶ nipple-sparing mastectomy
- ▶ nipple-areolar complex malposition
- ▶ two-stage implant-based breast reconstruction
- ▶ breast reconstruction

## Introduction

Symmetric and anatomical positioning of the nipple-areolar complex (NAC) and a well-balanced breast mound on both sides are the primary goals in nipple-sparing mastectomy (NSM).<sup>1</sup>

NAC position is the most significant factor,<sup>2</sup> and prevention of NAC malposition in NSM provides excellent esthetic outcomes which increase patient satisfaction and improve psychological outcomes.<sup>3</sup> However, nipple malposition after NSM is common

received  
January 4, 2022  
accepted after revision  
June 23, 2022

DOI <https://doi.org/10.1055/s-0042-1756292>.  
ISSN 2234-6163.

© 2022. The Korean Society of Plastic and Reconstructive Surgeons. All rights reserved.

This is an open access article published by Thieme under the terms of the Creative Commons Attribution-NonDerivative-NonCommercial-License, permitting copying and reproduction so long as the original work is given appropriate credit. Contents may not be used for commercial purposes, or adapted, remixed, transformed or built upon. (<https://creativecommons.org/licenses/by-nc-nd/4.0/>)

Thieme Medical Publishers, Inc., 333 Seventh Avenue, 18th Floor, New York, NY 10001, USA

and is sometimes called “high-riding nipple.” Choi et al reported an incidence of 14 to 75% of NAC malposition.<sup>1</sup>

The risk factors and secondary revision of NAC malposition have been reported. Such secondary revision of NAC malposition is a major concern for the patient,<sup>4</sup> because it results in the formation of extra scars on the breast. This extra scar is often observed and is much more visible in Asian women than in Caucasians.<sup>5</sup>

The prevention method of NAC malposition and results of such technique have not yet been reported. We have been trying to prevent NAC malposition during expander insertion to properly fix the NAC to the pectoralis major fascia. Therefore, this study aimed to evaluate the efficacy of this technique in preventing NAC malposition in patients undergoing two-stage implant-based breast reconstruction following NSM.

## Methods

This study was reviewed and approved by the Institutional Review Board (IRB) of the University (IRB no.: T2020-0291), and informed consent was obtained from all patients. All procedures performed in studies involving human participants were in accordance with the ethical standards of the institutional and/or national research committee and with the 1964 Helsinki Declaration and its later amendments or comparable ethical standards.

This retrospective cohort study included data obtained from medical charts and clinical photographs. Patients who underwent two-stage implant-based breast reconstruction with NSM at the Tokyo Medical University Hospital (Tokyo), Tokyo Medical University Hachioji Medical Center (Tokyo), and Tokyo Medical University Ibaraki Medical Center (Ibar-

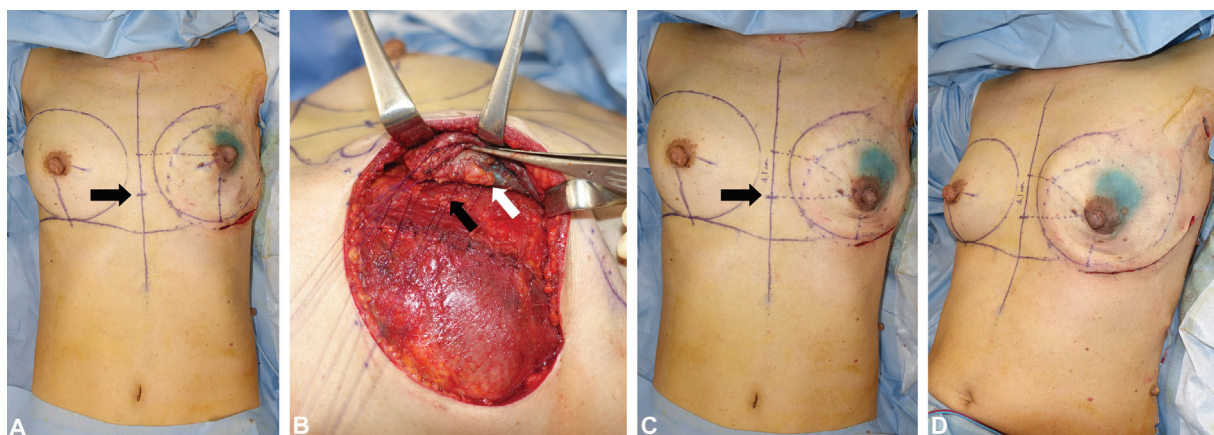
aki) between January 2012 and December 2019 were included. The exclusion criteria were as follows: bilateral cases, NSM after partial mastectomy, periareolar incision, irradiated cases, secondary reconstruction, augmentation on the healthy side, recurrence, a history of surgical site infection (SSI) and other complications, additional resection required, and reconstruction by surgeons other than plastic surgeons.

## Surgical Techniques to Prevent Nipple-Areolar Complex Malposition

A preventive technique of NAC malposition was performed at the time of expander insertion in supine position (→ Fig. 1).

NAC was fixed on the pectoralis major fascia to ensure symmetry while paying attention to the following three steps:

1. Proper NAC position (step 1): before the operation, symmetrical nipple-areola height was marked on the skin over the sternum by drawing across the horizontal line to the unaffected side and chest midline, with the patient in the standing position. Intraoperatively, in the supine position, this mark is the correct position of the NAC height. Fixation is performed in the supine position.
2. The area of the fascia where NAC is sutured should not move easily (step 2): an expander was inserted under the pectoralis major with approximately 10% of the expander volume filled with saline solution. The pectoralis major fascia was preserved if it was permitted oncologically. A pocket was made by suturing the pectoralis major muscle and lateral adipofascial flap. This pocket covered the expander tightly, establishing a rigid base for suture fixation of the NAC.



**Fig. 1** Prevention technique of nipple-areola complex (NAC) malposition during expander insertion in the supine position. NAC was fixed on the pectoralis major fascia to ensure symmetry. (A) Before fixation of NAC in supine position: The symmetrical nipple-areola height was marked on the skin on the sternum by drawing across the horizontal line to the unaffected side and chest midline, with the patient in the standing position (black arrow). This is the proper NAC position in the supine position. As shown in the photograph, the NACs of the right healthy and left postmastectomy sides are both deviated upward compared with the proper NAC position in the standing position. (B) Eight-point fixation of NAC: A rigid base resembling a pocket is created to fix the NAC with the pectoralis major muscle and the lateral adipofascial flap. This pocket wraps the expander, and the expander and muscle are rigidly on the chest wall. Eight periareolar points of the dermal tissue deep to the superficial layer of the superficial fascia (white arrow) were sutured to the fascia of the pectoralis major (black arrow). If there is no fascia, the pectoralis muscles are threaded tightly. These sutures were made to maintain the NAC shape, similar to that of the unaffected side, and prevent distorting the oval shape. (C) After fixation of NAC in supine position: Left affected NAC was fixed at the proper level of NAC position while in the supine position. (D) After fixation of NAC in sitting position: finally, the symmetry was checked in the sitting position.

3. Symmetrical shape of NAC (step 3): The eight periareolar points of the dermal tissue deep to the superficial layer of the superficial fascia were sutured to the pectoralis major fascia with 4-0 PDS II (Ethicon Inc., Somerville, NJ) absorbable thread. These sutures were made to maintain the NAC shape, similar to the unaffected side, and prevent the distortion of the oval shape. Finally, the expander was filled with saline equal to the volume of the removed mammary gland; subsequently, the symmetry was checked in the sitting position.

Patients were classified into the following two groups based on the performance of the prevention technique of NAC malposition: group 1 (which comprised patients in whom the prevention technique was not performed) and group 2 (which comprised patients in whom the prevention technique was performed).

Data regarding the age at initial diagnosis, region of cancer, ptosis, volume of the removed mammary gland, implant volume, and body mass index (BMI; as measured at the time of TE insertion) were obtained.

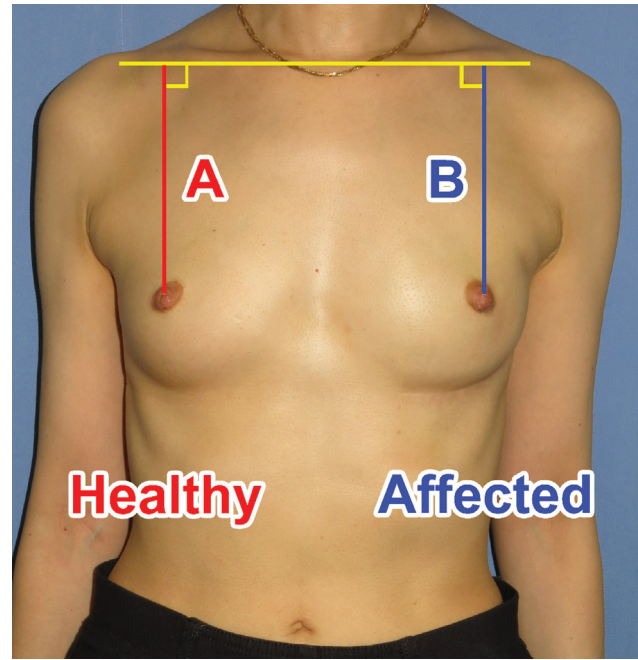
#### Evaluation of Nipple-Areolar Complex Malposition Using Clavicle-to-Nipple Distance Ratio

A 6-month postoperative standing frontal view was evaluated. Six months after implant replacement, frontal view photographs were taken in the standing position. First, a horizontal line was drawn at the top of the clavicle. Subsequently, a perpendicular line to the previous line was drawn through the nipple on each side. The length of the perpendicular line from the clavicle to the nipple was measured on the photograph. The malposition rate was calculated as the ratio of the clavicle-to-nipple distance on the reconstructed side compared with that on the healthy side. The clavicle-to-nipple distance ratio was defined as the ratio of the distance on the affected side to that on the healthy side (b/a; %); this ratio was compared between the two groups (►Fig. 2).

Statistical analyses, including Mann-Whitney and Chi-square tests, were performed using IBM SPSS Statistics (International Business Machines Corporation, New York, NY). A  $p$ -value of  $<0.05$  was considered statistically significant. Allergan Natrelle 133 Tissue Expander and Allergan Natrelle 410 Breast Implant (Allergan, NJ), which had an anatomical shape, were used in all cases.

## Results

Overall, 78 patients who underwent two-stage expander and implant-based breast reconstruction after NSM in the study period were included. The exclusion criteria were as follows: bilateral cases ( $n = 6$ ); NSM after partial mastectomy ( $n = 6$ ); periareolar incision ( $n = 7$ ); secondary reconstruction ( $n = 2$ ); corrected ptosis augmentation on the healthy side ( $n = 2$ ); recurrence ( $n = 1$ ); SSI ( $n = 2$ ); additional resection due to pathological examination ( $n = 1$ ); operated by non-plastic surgeons ( $n = 9$ ); and radiation therapy ( $n = 7$ ). Subsequently, 35 patients/breasts were included. All patients were operated by the first author.



**Fig. 2** Evaluation of nipple-areolar complex (NAC) malposition after a postoperative period of 6 months (frontal view). First, a horizontal line was drawn at the top of the clavicle. Subsequently, perpendicular to that line, a line was drawn through the nipple on each side. The length of the perpendicular line from the level of the upper end of the clavicle to the nipple on the photograph was measured. The malposition rate—defined as the ratio of the distance on the affected side to that on the healthy side (B/A; %)—was compared between the groups.

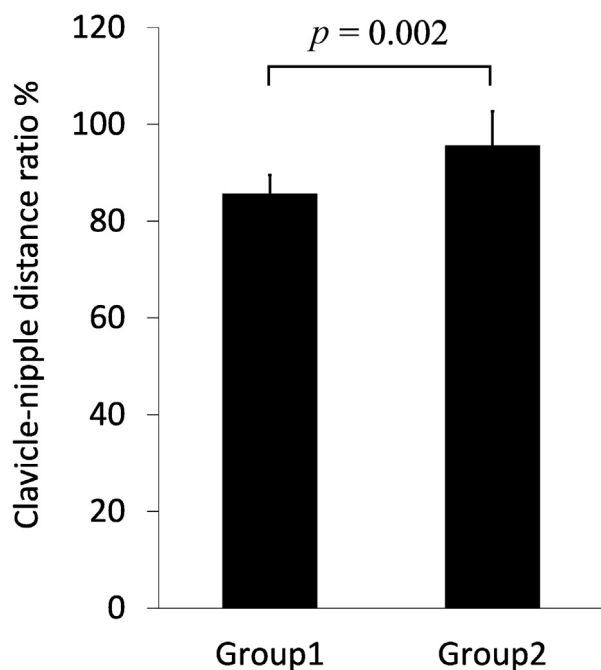
The clavicle-to-nipple distance ratios (mean  $\pm$  standard deviation) at 6 months after implant insertion in groups 1 and 2 were  $86.1 \pm 11.5$  and  $96.0 \pm 5.0\%$ , respectively (►Fig. 3). There was a significant difference in the nipple height malposition ratio between groups 1 and 2 ( $p = 0.003$ ). Demonstrative case photographs are presented in ►Fig. 4.

The changes over time in group 1, the NAC fixation group, are shown in ►Fig. 5. Immediately after TE insertion, edema around the areola was severe; however, it improves over time. Six months after silicone breast implant (SBI) replacement surgery, the patient's appearance was good.

The number of patients in groups 1 and 2 was 10 and 25, respectively. The demographic data of the patients are presented in ►Table 1. All patient background factors were not significantly different between the groups. The data regarding the volume of the removed mammary glands were missing in 5 of the 35 patients; the other data were collected in all 35 patients.

## Discussion

NAC deviation worsens esthetic outcomes and reduces patient's satisfaction,<sup>6</sup> and secondary NAC revision surgery leaves new scarring on the breast.<sup>7</sup> We were motivated to conduct this study because we believed that it was crucial to prevent NAC deviation during the immediate two-stage breast reconstruction, since there have been no studies that have investigated the effects of surgical techniques to prevent NAC deviation.



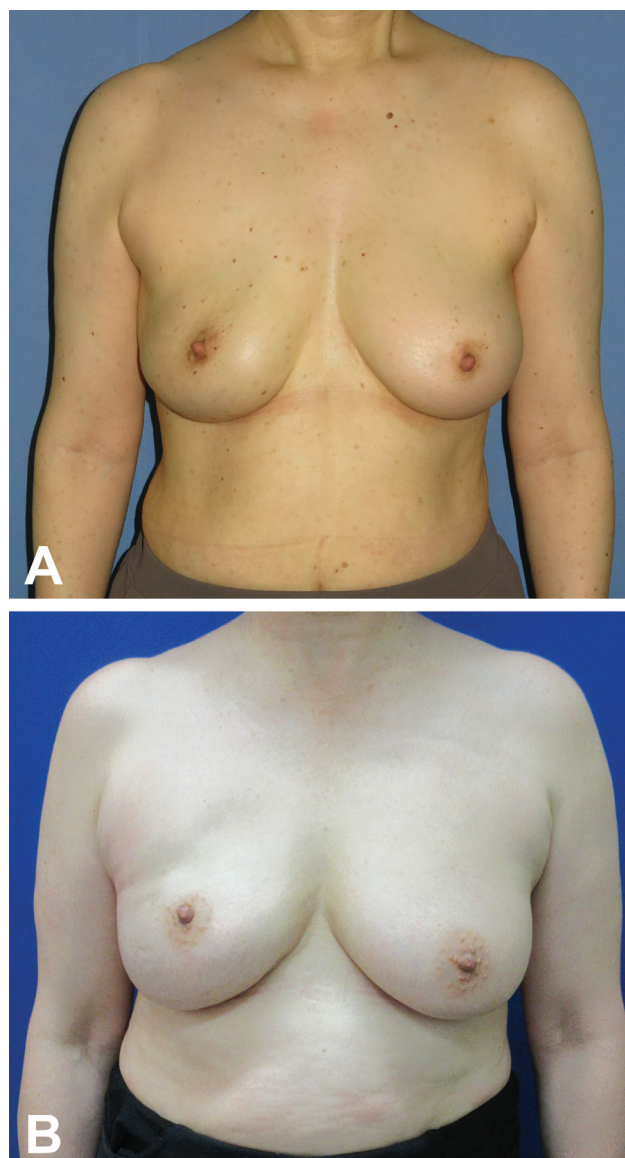
**Fig. 3** There was a significant difference in nipple height malposition ratio (clavicle-to-nipple distance ratio) between groups 1 and 2 after 6 months of implant insertion ( $p = 0.003$ ).

The study results revealed that fixing the NAC on the pectoralis major fascia at the time of TE insertion is effective. This procedure intraoperatively prevents NAC malposition, and this technique has favorable effects in two-stage implant-based breast reconstruction.

When NAC malposition occurs following NSM, even if the symmetry of the breast mound is good, malposition extremely reduces patient satisfaction.<sup>6</sup> Additional revision surgery to correct NAC malposition would result in the formation of new scars in addition to the existing scar,<sup>7</sup> especially in Asians in whom mammary scars often are more visible.<sup>5</sup> Based on these findings, we believe that NAC malposition should be prevented rather than corrected. Therefore, we believe in preventing NAC malposition at mound reconstruction intraoperatively rather than correcting it later with additional revision surgery. This might reasonably be less burdensome, both emotionally and physically, for the patient and would not result in the formation of extra scars.

Takayanagi stated that the goal of NSM is symmetry, including for the NAC.<sup>5</sup> The frequency of malposition of NAC has been reported to be 75% by Wagner et al,<sup>8</sup> 14 to 75% by Choi et al,<sup>1</sup> and 41.9% by Swanson.<sup>9</sup> The degree as vertical distance ratio has been reported to be 88% by Mori et al.<sup>10</sup> A few studies have analyzed the causes of NAC malposition and postoperative corrections.<sup>1,7</sup>

The risk factors for malposition include periareolar mastectomy incision with lateral extension, older age, wider preoperative width of breast base, a history of radiation, longer preoperative sternal notch-to-nipple distance,<sup>7</sup> verti-

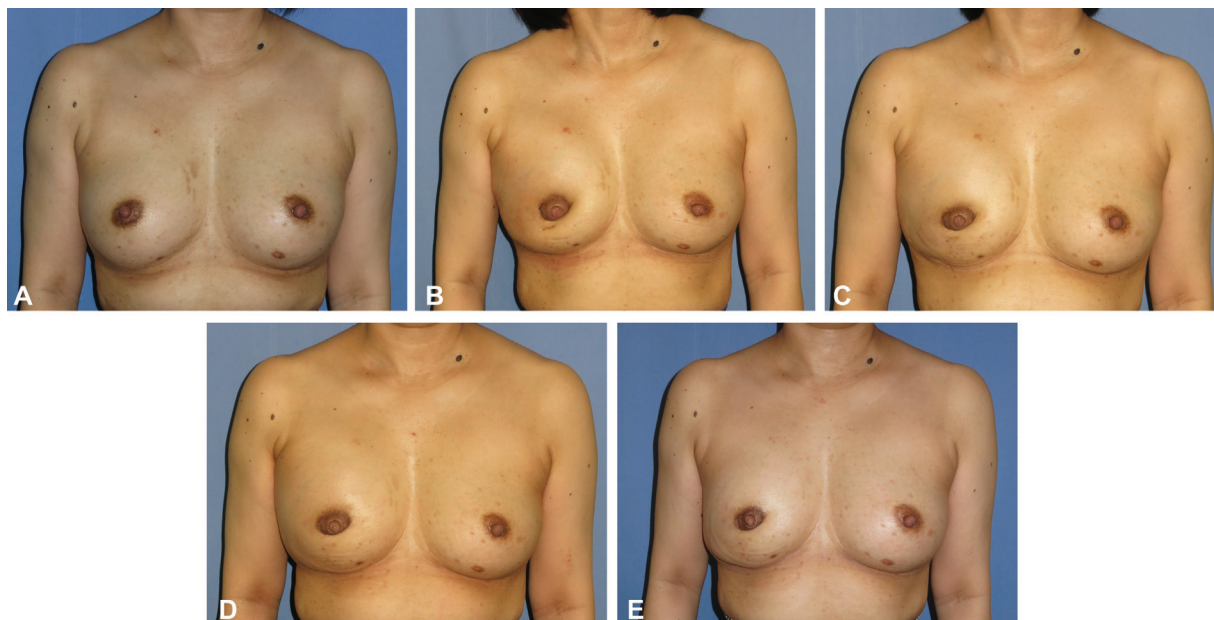


**Fig. 4** Demonstrative case photographs are shown. Patients were classified into two groups according to the performance of the prevention technique of nipple-areola complex (NAC) malposition at the time of tissue expander (TE) insertion. (A) Group 1: With NAC position correction at TE insertion (right breast was reconstructed). (B) Group 2: Without NAC position correction at TE insertion (right breast was reconstructed).

cal radical mastectomy incisions,<sup>1</sup> ptotic, and large resection tissue weight.<sup>10</sup>

Secondary revision techniques for NAC include free nipple grafting,<sup>4</sup> subdermal pedicle flap reconstruction,<sup>5</sup> crescentic excision,<sup>1</sup> capsule modification,<sup>1</sup> Z-plasty technique,<sup>11</sup> U-plasty,<sup>12</sup> transposition technique,<sup>13</sup> and crescent periareolar skin excision.<sup>1</sup>

In comparison with these reports, the nipple malposition rate calculated as the clavicle-to-nipple distance ratio on the affected side to that on the healthy side (the affected/healthy [b/a] ratio [%]) in group 1 without preventive technique was 86.1%, which is close to the rate of 88% reported in the literature as vertical distance ratio by Mori et al.<sup>10</sup> In contrast, the nipple malposition ratio was 96.0% in group



**Fig. 5** The temporal changes in group 2. (A) Preoperation, 48 years of age. BMI, 22.6 kg/m<sup>2</sup>. (B) One month after TE insertion at right breast. The volume of the removed mammary gland was 221 mL. MX 400 TE was inserted. NAC was 4.2 cm pulled down and corrected. Edema around the nipple was severe. (C) Three months after TE insertion. Edema improved over time. (D) Six months after TE insertion. (E) Six months after the implant replacement. LF 270 implant was replaced, and the patient's appearance is good.

2, wherein the preventive technique of NAC fixation was performed at TE insertion. The nipple malposition ratio was significantly higher ( $p = 0.003$ ) in group 2 than in group 1, thus suggesting that NAC fixation at the time of TE insertion may have significantly prevented NAC malposition. Moreover, no studies have precisely described the prevention methods and their effectiveness. Thus, the present study results can be considered valuable.

This study had a retrospective design; hence, the number of patients in each group differed. However, no significant differences were noted in the patient background factors between the two groups.

Regarding the fixation of NAC during TE insertion, our meticulous technique had satisfactory outcomes. The appropriate fixed position of the NAC was determined based on the reference point of the healthy nipple height marked on the sternum in the standing position, since the point on the

midline of the chest did not shift in supine position intraoperatively. In the supine position, the healthy NAC moves upward. In contrast, Flessas et al reported that the appropriate NAC position was determined by comparing it with the healthy lateral nipple position in the seated position intraoperatively.<sup>14</sup> However, in obese patients, the accurate NAC position may not be determined because the abdomen compresses the breast upward. Even in patients with breast ptosis, it is difficult to obtain adequate ptosis while seated on the operation table. In contrast, the point marked on the midline of the sternum is less likely to move and is more accurate. If the preoperative NAC position and breast size are asymmetrical, the reconstruction can be considered to have matched the healthy side.

A rigid base resembling a pocket was created to fix the NAC with the pectoralis major muscle and the lateral adipofascial flap. The dissected area under the pectoralis major

**Table 1** Patients' characteristics

Patients' demographics		Group 1	Group 2	<i>p</i> -Value
<i>n</i>		10	25	
Age (y)		46.6 ± 10.4	46.12 ± 7.3	0.815
Ptosis	Non	7	23	0.128
	Glandular/pseud	3	2	
Removed mammary gland (mL)		269.3 ± 149.0	171.8 ± 60.8	0.104
Tissue expander volume (mL)		410.5 ± 133.5	312.4 ± 88.1	0.053
Implant volume (mL)		273.0 ± 100.9	217.0 ± 60.7	0.186
Waiting period until implant insertion (day)		276.7 ± 53.2	286.5 ± 49.4	0.622
Body mass index (%)		22.8 ± 2.2	21.1 ± 2.5	0.054

muscle should match the base area of the TE to create a tight space. We used the superficial fascia at the margin of the areola as the suture site on the skin flap. The pectoralis major fascia, which serves as the site of anchoring NAC, should be rigid and tight. If there is no fascia, the pectoral muscles are tightly threaded. This pocket wraps the expander, and the expander and muscle are rigidly on the chest wall. Without this pocket, the NAC can easily move and be pulled by the skin flap which can result in poor fixation.

We measured the contralateral NAC diameter to evaluate the symmetry and size and subsequently fixated eight points of the areola margin to the pectoralis major fascia using 4–0 PDS II (Ethicon Inc.). With this approach, a natural oval-shaped nipple with minimal strain can be created. The time required to perform this procedure was approximately 15 minutes; Flessas et al reported fixing the subpapillary tissue to the pectoralis major with two to three sutures using 3–0 Vicryl with the serratus anterior overlying the implant.<sup>14</sup> In our experience, the nipple shape was deformed into an inverted triangle at only one subnipple suturing and a square shape due to four sutures; therefore, we sutured the nipple in eight locations to reproduce a proper nipple contour. The method of fixing NAC not only corrects the NAC position but also consciously fixes the NAC shape. This concept has not been described previously.

A limitation of this study was that only patients with pseudoptosis and glandular ptosis, according to Regnault's classification, were included, whereas other major ptosis cases are excluded. The other major ptosis cases were either indicated for autologous tissue reconstruction or NAC repositioning surgery after implant insertion in case of implant-based breast reconstruction. Similarly, Mori et al reported that small and nonptotic breasts showed relatively acceptable symmetry, whereas large or ptotic breasts tend to develop NAC deviation. In a large or ptotic breast, NSM and expander-implant reconstruction should be performed, considering additional surgery. Doren et al showed that there were anatomical criteria for the indication of NSM, and free nipple grafting was selected for the excluded cases.<sup>15</sup> Small et al reported a low rate of NAC malposition of 13.8% with a stricter patient selection.<sup>7</sup> Choi et al described that patients underwent reduction or mastopexy of the healthy breast at 1 to 3 months before mastectomy, and consequently, none of them underwent NAC repositioning after mastectomy.<sup>1</sup> Better results can be achieved by evaluating the patient's breast shape.

Prevention of NAC malposition was possible using our technique "NAC fixation at TE insertion" in two-stage implant-based breast reconstruction, following NSM without major ptosis. Additionally, NAC fixation at TE insertion was found to be extremely effective.

#### Ethical Approval

This retrospective single-center chart review was approved by the Institutional Review Board (IRB) of the Tokyo Medical University, Tokyo, Japan (IRB no.: T2020–0291), and performed in accordance with the principles of

the Declaration of Helsinki. Written informed consent was obtained.

#### Authors' Contributions

T.K.: conceptualization, data curation, and preparing the original draft. Y.O.: data curation. T.I.: project administration. H.M.: project administration and writing, reviewing, and editing manuscript.

#### Note

This article was presented at the 9th congress of the Japan Oncoplastic Breast Surgery Society on September 16, 2021, in Tokyo, Japan.

#### Conflict of Interest

None declared.

#### Acknowledgments

We are grateful to Dr. Tatsuya Isomura, Division of Clinical Research Consultation of Institute of Medical Science, Tokyo Medical University, Tokyo, Japan, for helpful discussions about the statistical analysis.

#### References

- Choi M, Frey JD, Salibian AA, Karp NS. Nipple-areola complex malposition in nipple-sparing mastectomy: a review of risk factors and corrective techniques from greater than 1000 reconstructions. *Plast Reconstr Surg* 2017;140(02):247e–257e
- Djohan R, Gage E, Gatherwright J, et al. Patient satisfaction following nipple-sparing mastectomy and immediate breast reconstruction: an 8-year outcome study. *Plast Reconstr Surg* 2010;125(03):818–829
- Metcalfe KA, Cil TD, Semple JL, et al. Long-term psychosocial functioning in women with bilateral prophylactic mastectomy: does preservation of the nipple-areolar complex make a difference? *Ann Surg Oncol* 2015;22(10):3324–3330
- Rietjens M, De Lorenzi F, Andrea M, et al. Free nipple graft technique to correct nipple and areola malposition after breast procedures. *Plast Reconstr Surg Glob Open* 2013;1(08):e69
- Takayanagi S. Transposition of the malpositioned nipple-areola complex in breast reconstruction with implants. *Aesthetic Plast Surg* 2010;34(01):52–58
- Jabor MA, Shayani P, Collins DR Jr., Karas T, Cohen BE. Nipple-areola reconstruction: satisfaction and clinical determinants. *Plast Reconstr Surg* 2002;110(02):457–463, discussion 464–465
- Small K, Kelly KM, Swistel A, Dent BL, Taylor EM, Talmor M. Surgical treatment of nipple malposition in nipple-sparing mastectomy device-based reconstruction. *Plast Reconstr Surg* 2014;133(05):1053–1062
- Wagner JL, Fearmonti R, Hunt KK, et al. Prospective evaluation of the nipple-areola complex sparing mastectomy for risk reduction and for early-stage breast cancer. *Ann Surg Oncol* 2012;19(04):1137–1144
- Swanson E. Correction of postoperative nipple/areola malposition without nipple grafting. *Plast Reconstr Surg Glob Open* 2014;2(03):e117
- Mori H, Uemura N, Okazaki M, Nakagawa T, Sato T. Nipple malposition after nipple-sparing mastectomy and expander-implant reconstruction. *Breast Cancer* 2016;23(05):740–744
- Frenkiel BA, Pacifico MD, Ritz M, Southwick G. A solution to the high-riding nipple-areola complex. *Aesthetic Plast Surg* 2010;34(04):525–527

- 12 Mohmand H, Naasan A. Double U-plasty for correction of geometric malposition of the nipple-areola complex. *Plast Reconstr Surg* 2002;109(06):2019–2022
- 13 Taneda H, Sakai S. Transposition technique for correction of a malpositioned nipple-areola complex after reconstruction following a nipple-sparing mastectomy: a case report. *Ann Plast Surg* 2011;67(06):579–582
- 14 Flessas I, Michalopoulos NV, Zografos GC. Nipple malposition following nipple-sparing mastectomy. How can we prevent it? *Breast J* 2016;22(01):131–132
- 15 Doren EL, Van Eldik Kuykendall L, Lopez JJ, Laronga C, Smith PD. Free nipple grafting: an alternative for patients ineligible for nipple-sparing mastectomy? *Ann Plast Surg* 2014;72(06):S112–S115