



## Case Report

## Colorectal intussusception with rectal prolapse related to cecal lipoma in adult: A rare case report and review of the literature

Nor Abdi Yasin<sup>a,\*</sup>, Abdirahman Ahmed Mohamud<sup>a</sup>, Ersin Acet<sup>a</sup>, Ilkay Guler<sup>b</sup>, Abdulkamil Abdullahi Adani<sup>a</sup>

<sup>a</sup> Mogadishu Somalia Turkish Training and Research Hospital, Mogadishu, Somalia

<sup>b</sup> General Directorate Of Public Hospitals, Ministry of the Health of the Republic of Turkiye, Ankara, Turkiye

## ARTICLE INFO

## Keywords:

Intussusception  
Cecal Lipoma  
Adult  
Rectal prolapse

## ABSTRACT

Colonic intussusception due to lipoma is extremely rare. Very few cases were reported in the literature of cecal lipoma leading to the intussusception of the whole proximal colon till the rectum. We report a rare case of a 39-year-old female patient with cecal lipoma causing colo-colonic intussusception involving the entire length of the proximal colon and the overall mass prolapsed into the pelvis that could be palpated in rectal examination. The case presented with a giant mass with clinical manifestations of obstruction. An extended right hemicolectomy and end ileostomy were performed due to intestinal dilation and intra-abdominal contamination. To the best of our knowledge, this is the second case of cecal lipoma leading to intussusception of the whole proximal colon till to the rectum reported in the relevant literature. Whenever a colonic mass results in intussusception, the incidence of malignancy is slightly higher (60%), so a proper oncological resection should be performed if the pathology is not known preoperatively.

## 1. Introduction

Intussusception, invagination of an intestinal segment into the distal portion, is a rare condition among the adult population (1% of bowel obstructions). Nonetheless, it can lead to bowel obstruction, bowel necrosis, sepsis, and death without proper treatment. Unlike children, it is usually caused by an organic reason like benign or malignant tumors, adhesions, and inflammations [1]. Colo-colonic type of intussusception is even rarer, probably because of the ascending and descending colon stability due to anatomical attachments to the retroperitoneum [2].

Cecal lipomas are rare benign tumors (seen 0.2%–4.4% in large autopsy series), and cecal lipoma incidence is only 19% among them. They are generally asymptomatic but may cause crampy abdominal pain, constipation, nausea, vomiting, and other mechanical bowel obstruction symptoms, especially when larger than 4 cm [3].

As far as we know, few cases were reported in the literature of cecal lipoma leading to the assumption of the whole proximal colon till the rectum. We report a cecal lipoma causing colo-colonic intussusception involving the entire length of the proximal colon and the overall mass prolapsed into the pelvis that could be palpated in rectal examination.

## 2. Case presentation

A 39-year-old female patient was admitted to our hospital with diffuse abdominal pain for the last two weeks. The pain was associated with nausea, vomiting, and absolute obstipation for the last three days. She had a history of a painless palpable mass in the right lower quadrant of the abdomen. However, all the other reviews of systems were negative. The patient had no previous history of gastrointestinal symptoms or pathologies, and she denied any history of hemorrhoids or prolapse. She had never undergone a colonoscopy. She had no previous comorbidities or prior abdominal surgeries in her medical or surgical history.

On the initial physical examination, the patient had a palpable, firm abdominal mass on the left side. The mass was partially prolapsed into the pelvis and could be palpated during a digital rectal examination, mimicking rectal prolapse. Her blood pressure, heart rate, and body temperature were 90/50 mmHg, 110 bpm, and 37.8 °C, respectively. There were no signs of acute peritonitis, perforation, or ischemia.

Her laboratory results were in the normal range except for a leukocyte count of 17.23/mm<sup>3</sup> and a C-reactive protein (CRP) level of 47.1 mg/L. Since the patient was hypotensive and dehydrated, we started rehydration with intravenous fluids. The patient was kept 'nil per os,'

\* Corresponding author. Tel.: +90 00252615732173.

E-mail address: [dalnurshe68@gmail.com](mailto:dalnurshe68@gmail.com) (N.A. Yasin).

<https://doi.org/10.1016/j.amsu.2022.104707>

Received 8 August 2022; Received in revised form 8 September 2022; Accepted 10 September 2022

Available online 28 September 2022

2049-0801/© 2022 Published by Elsevier Ltd on behalf of IJS Publishing Group Ltd. This is an open access article under the CC BY license (<http://creativecommons.org/licenses/by/4.0/>).

and a nasogastric tube was placed for decompression. An abdominal computed tomography (CT) scan with oral and intravenous contrast was performed. This imaging study showed dilated ileal segments with intussusception of the terminal ileum, cecum, ascending colon, and transverse colon through descending and sigmoid colon down to the rectum. Also, an intramural oval mass (11 × 10 cm) was detected (Fig. 1A, 1B and 1C). Since the mass was irreducible by rectal examination, we did not perform a colonoscopy. After initial resuscitation, an abdominal exploration was performed. This exploration revealed distended small bowel segments and intussusception of the cecum, ascending colon, and part of the transverse colon until the rectum. The intussusception was reduced, and some segments of the proximal colon appeared ischemic and edematous (Fig. 2).

There were micro-perforations and intra-operative abdominal contamination. Furthermore, there was a mass in the cecum with unknown pathological features. So, the patient underwent extended right hemicolectomy and end ileostomy (Fig. 3,4). The postoperative period was uneventful, and the patient was discharged five days after the surgery. The histopathological examination of the specimen revealed a cecal intramural lipoma and colonic ischemia. Four months postoperatively, the patient was returned to the hospital for a second procedure for ileostomy closure. For a 3-year follow-up for the patient, there was no recurrence of the condition.

This work has been reported in line with the SCARE 2020 criteria [4].

### 3. Discussion

Intussusception was first reported in 1674 by Barbet and further reported in detail in 1789 by John Hunter [1,3]. This condition is the telescoping of a proximal segment of the bowel known as intussusceptum into the distal segment of the GI tract, called intussusciens. In adults, intussusception represents a rare cause of bowel obstruction, estimated at 1–5% of all bowel obstructions [5]. The first operation was performed by Sir Jonathan Hutchinson, who operated on a child with intussusception in 1871 [5].

Although generally, Gastrointestinal lipoma is rare, even colonic lipoma is rarer, and the incidence of colonic lipoma is reported a range between 0.035% and 0.4% [6]. Colonic lipoma is prevalent in late middle-aged women between 50 and 60 years of age and the ascending and transverse colon at 38% and 22%, respectively [7]. We present a case of colorectal intussusception and prolapse in the rectum due to cecal lipoma. Less than five cases were reported in the literature related to entire ileorectal intussusception. Apposition of ascending colon to the retroperitoneum and exteriorization with failure of ascending zygosis that did not stop the intussusception was observed in these cases. Similar to our case, Bensardi et al. presented a patient with entire ileorectal

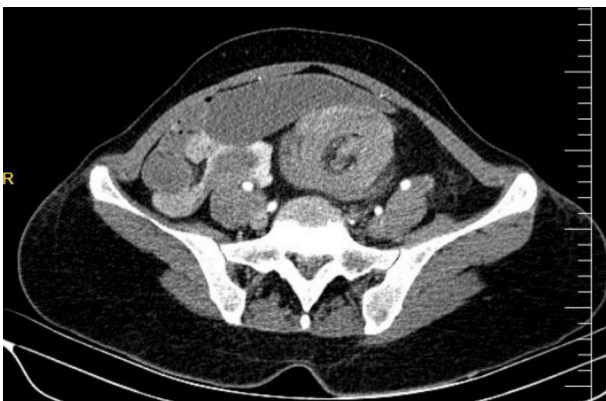

Fig. 1. (A) Axial CT scan shows left mid abdominal colocolic intussusception as a target-like mass.

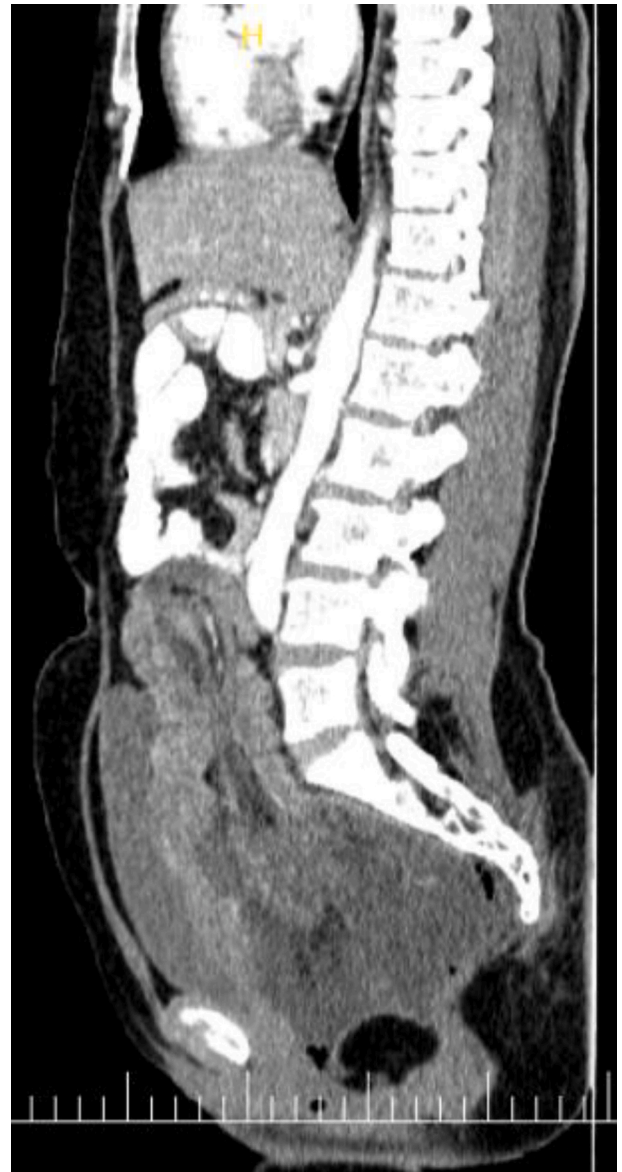

Fig. 1. B Axial CT scan shows a round mass of fat density representing lipoma within the lumen of the rectum.

intussusception due to cecal lipoma [8]. Robertson et al. reported a cecal tumor that chronically impacted the rectum and the leading point was cecal adenocarcinoma [9]. Ongom et al. reported a case of anal protrusion of ileocolic intussusception with no identifiable leading point, bowel laxity, and no hepatocolic or splenocolic ligaments [10]. These patients underwent right hemicolectomy and primary ileocolic anastomosis; however, our patient had an extended right hemicolectomy and ileostomy due to intestinal dilation and intra-operative abdominal contamination.

Acute intestinal intussusception is more likely if it is over 2 cm [7]. Cecal lipoma is challenging to diagnose preoperatively due to nonspecific clinical symptoms, and tumors less than 2cm are asymptomatic. Tumors 4cm or bigger are symptomatic, and the most common symptom is intermittent pain, which can lead to a late diagnosis. Vomiting and bleeding are frequent, while hematochezia and lipoma tissue prolapse are occasionally seen [11,12]. The present cases presented with a giant mass with clinical manifestations of obstruction.

Nowadays, several diagnostic tools are available. Preoperatively, 32%–50% of colonic lipomas are found. Colonoscopy is reliable for biopsy and diagnosing typical lipomas but not valuable for atypical

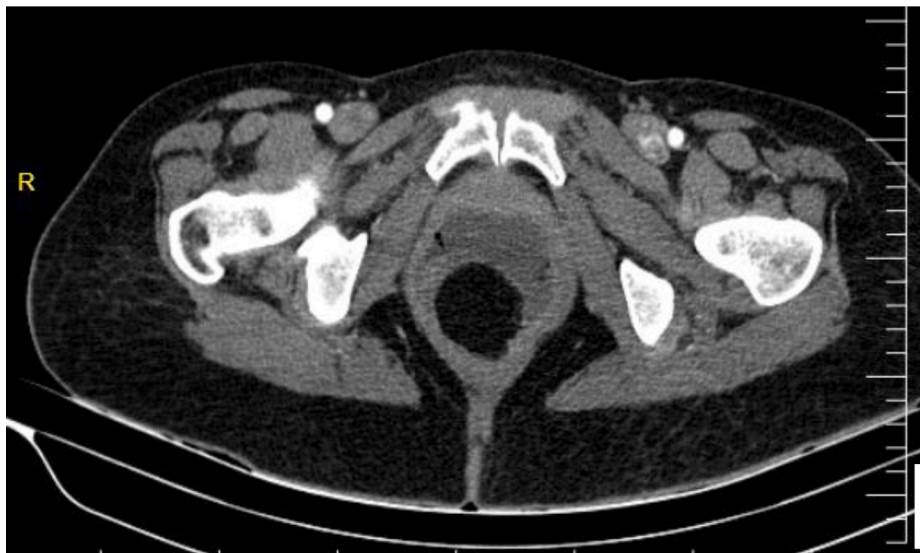

Fig. 1. C Sagittal CT scan shows very large colocolic intussusception as a bowel-in-bowel sign with an intussuscepted lipoma in the rectum.

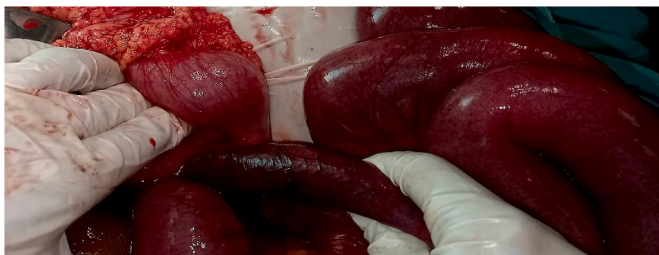

Figure 2. terminal ileum and the right colon intussuscepted in the left colon.

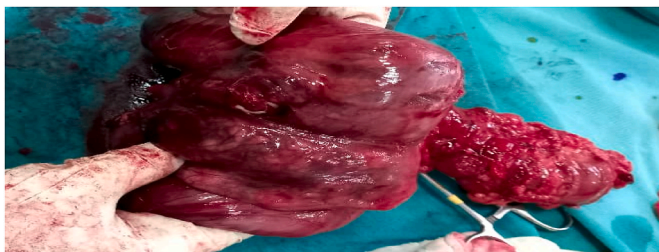

Figure 3. After reduction of the cecal mass.

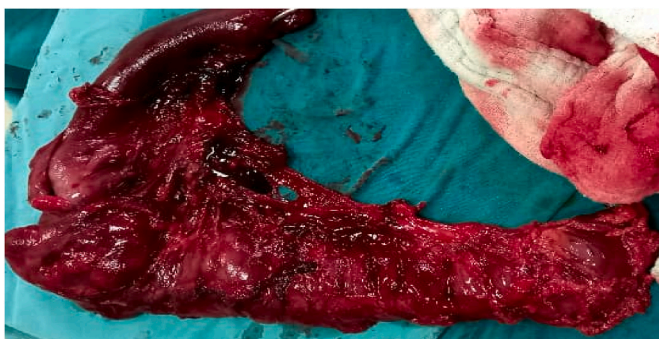


Figure 4. After resection The bowel was edematous and ischemia.

lesions. Endoscopic and surgical excisions can treat colonic lipomas  $\leq 2\text{cm}$  [13]. Abdominal x-rays can show intestinal blockage with dilatation and ileus. On barium enema, colonic lipomas appear as smooth, spherical lumps (due to fat). Size and shape variations show a “squeeze sign” [14]. Ultrasonography is used to evaluate suspected intussusception; despite being cheap, readily available, and operator-dependent, it lacks meaningful pictures and interpretation in patients with ileus or obstruction due to abdominal gas. USG displays the “target and doughnut sign” and the “pseudokidney sign” in transverse and longitudinal views, respectively. The diagnostic accuracy of USG is 86.6% in palpable and 78.5% in non-palpable abdominal mass [12]. Unfortunately, Our patients had giant lipomas that caused colorectal intussusception in the rectum, which cannot be conducted by colonoscopy, and a CT scan was our primary diagnosis. CT imaging is the radiological modality of choice in diagnosing colonic lipoma and offers a sensitivity of 71%–87% and a specificity of up to 100%. Lipoma is characterized by fat-equivalent density, a near oval form, and smooth edges. However, it is relatively easy to detect intussusception as a lesion exhibiting the usual appearance known as the “target sign” or “sign of donut.” Lipomas that are intussusceptible may have a diverse appearance that reflects the degree of infarction and fat necrosis.

Furthermore, if a sufficiently large lesion is present, CT can determine whether a lesion is composed of adipose tissue, with values ranging from 40 to 120 Hounsfield units (HU). If an oval shape accompanies it, the suspicion of a lipomatous lesion is high. However, special care must be used in making the diagnosis because 60–65% of instances of large intestine intussusception are caused by malignant tumors [15,16].

Although there are many surgical techniques for colonic lipoma benign tumors, large symptomatic lipomas are best treated surgically, especially if malignancy cannot be ruled out [17]. The best treatment was surgical resection for our patient with a giant cecal lipoma and bowel obstruction and no preoperative diagnosis to exclude malignancy. Endoscopic management is possible for colonic lipoma  $<2.0\text{cm}$  in diameter but not for lesions  $>2.0\text{cm}$  due to associated complications [15].

Whenever a colonic mass results in intussusception, the incidence of malignancy is slightly higher (60%), so a proper oncological resection should be performed if the pathology is not known preoperatively [3].

#### 4. Conclusion

To the best of our knowledge, this is the second case of cecal lipoma leading to intussusception of the whole proximal colon till to the rectum

reported in the relevant literature. Whenever a colonic mass results in intussusception, the incidence of malignancy is slightly higher (60%), so a proper oncological resection should be performed if the pathology is not known preoperatively.

#### Declaration of competing interest

The authors declare no conflict of interest and this study received no funding support.

#### Consent

Written informed consent was obtained from the patient for publication of this case report and accompanying images. A copy of the written consent is available for review by the Editor-in-Chief of this journal on request.

#### Provenance and peer review

Not commissioned, externally peer reviewed.

#### Ethical approval

The ethics approval form was waived from the ethics committee of Mogadishu Somali Turkey, Recep Tayyip Erdogan Training and Research Hospital.

#### Please state any sources of funding for your research

We declare that we have no funding source.

#### Author contribution

All authors have equal contribution regarding the designing, drafting and preparation of the case. All authors read and approved the final manuscript.

#### Please state any conflicts of interest

We declare that we have no conflict/competing interests.

#### Registration of research studies

1. Name of the registry: Not applicable.
2. Unique Identifying number or registration ID: Not applicable.
3. Hyperlink to your specific registration (must be publicly accessible and will be checked): Not applicable.
- 4.

#### Guarantor

As Corresponding Author, I confirm that the manuscript has been

read and approved by all named authors.

#### Consent

Informed consent was obtained from the patient.

#### References

- [1] Brill A, Lopez RA. Intussusception in Adults. InStatPearls [Internet] 2021 Aug 11. StatPearls Publishing.
- [2] M. Allawati, T. Logman, M.T. Al Qubtan, Colonic lipoma as a leading cause of intussusception resulting in bowel obstruction, *Cureus* 13 (9) (2021 Sep 24), e18261, <https://doi.org/10.7759/cureus.18261>. PMID: 34C712536; PMCID: PMC8542912.
- [3] T. Casiraghi, A. Masetto, M. Beltramo, M. Garland, C. Di Bella, Intestinal obstruction caused by ileocolic and colocolic intussusception in an adult patient with cecal lipoma, *Case Rep Surg* 2016 (2016), 3519606, <https://doi.org/10.1155/2016/3519606>. Epub 2016 Dec 4. PMID: 28044120; PMCID: PMC5164886.
- [4] R.A. Agha, T. Franchi, C. Sohrabi, G. Mathew, for the SCARE Group, The SCARE 2020 guideline: updating consensus surgical Case Report (SCARE) guidelines, *Int. J. Surg.* 84 (2020) 226–230.
- [5] A. Marinis, A. Yiallourou, L. Samanides, N. Dafnios, G. Anastasopoulos, I. Vassiliou, T. Theodosopoulos, Intussusception of the bowel in adults: a review, *World J. Gastroenterol.* WJG 15 (4) (2009 Jan 1) 407.
- [6] Panagiotis Katsinelos, Grigoris Chatzimavroudis, Christos Zavos, Ioannis Pilpilidis, Georgia Lazaraki, Basilis Papaziogas, George Paroutoglou, Jannis Kountouras, Dimitris Paikos.
- [7] T. Casiraghi, A. Masetto, M. Beltramo, M. Girlando, C. Di Bella, Intestinal obstruction caused by ileocolic and colocolic intussusception in an adult patient with cecal lipoma, *Case Reports in Surgery* (2016 Dec 4) 2016.
- [8] Bensardi F, Hamrerras I, El Bakouri A, El Hattabi K, Fadil A. Ileo-colo-rectal Intussusception Secondary of Cecal Lipoma Simulating Strangulated Rectal Prolapse.
- [9] C.G. Robertson, S.L. Due, K. Shimokawa, M. Yeow, Caecal tumor biopsy with a rigid sigmoidoscope–Ileorectal intussusception, *International Journal of Surgery Case Reports* 12 (2015 Jan 1) 1–3.
- [10] P.A. Ongom, R.L. Lukande, J. Jombwe, Anal protrusion of an ileo-colic intussusception in an adult with persistent ascending and descending mesocolons: a case report, *BMC Res. Notes* 6 (1) (2013 Dec) 1–5.
- [11] Salari AA, Taghipour S, Pourmazar A. ADULT INTUSSUSCEPTION DUE TO A COLONIC LIPOMA (CASE REPORT).
- [12] M. Shramana, K. Vibha, K.D. Kajal, G. Parul, K. Nita, Lipomatous polyp presenting with intestinal intussusception in adults: report of four cases, *Gastroenterol. Res.* 3 (5) (2010) 229–231.
- [13] N. Cin, C. Tavusbay, H. Kar, E. Durak, Y. Peker, F. Tatar, H. Bağ, A. Er, E. Tarcan, M. Hacıyanlı, Colonic lipomas: report of sixteen cases and review of the literature, *Acta Med. Mediterr.* 32 (2016 Jan 1) 399.
- [14] S. Singhal, A. Singhal, P.K. Arora, R. Tugnait, B. Tiwari, P. Malik, A.S. Dhuria, V. Varghese, M.D. Bharali, S. Chandrakant, V. Panwar, Adult ileo-ileo-caecal intussusception: case report and literature review, *Case Reports in Surgery* (2012 Oct) 2012.
- [15] F.E. Álvarez-Bautista, P. Moctezuma-Velázquez, J.C. Cisneros-Correa, J.L. Aguilar-Frasco, A. Vélez-Valle, O. Vergara-Fernández, N. Salgado-Nesme, Colonic lipomas an uncommon cause of intussusception in adult patients: report of three cases and literature review, *Cirugía y cirujanos.* 89 (2021) 9–12.
- [16] D. Karaosmanoglu, O. Temizoz, M. Karcaaltincaba, D. Akata, Sonographic findings of colonic lipoma causing intussusception, *J. Ultrasound Med.* 26 (2007) 1621–1623.
- [17] D. Crocetti, P. Sapienza, A.V. Sterpetti, A. Paliotta, A. De Gori, G. Pedulla, G. De Toma, Surgery for symptomatic colon lipoma: a systematic review of the literature, *Anticancer Res.* 34 (11) (2014 Nov 1) 6271–6276.