




# A Rare Case of Disseminated Peritoneal Leiomyomatosis: A Case Report

Michael Chirayath<sup>1</sup>  Twinkle T. Titus<sup>1</sup> Loana Mariyam Sebastian<sup>1</sup> Soumya Cicilet<sup>1</sup>

<sup>1</sup>Department of Radiodiagnosis, St John's Medical College and Hospital, Bangalore, Karnataka, India

Address for correspondence Michael Chirayath, MD, St John's Medical College and Hospital, Bangalore 560034, Karnataka, India (e-mail: michaelchirayath@gmail.com).

Indian J Radiol Imaging 2024;34:765–769.

## Abstract

Disseminated peritoneal leiomyomatosis is a benign condition characterized by multiple extrauterine leiomyomas in various locations such as the peritoneum, mesentery, abdominal wall, and pelvis. This is typically observed following laparoscopic myomectomy and is an extremely rare disease, with only a limited number of cases reported thus far. It primarily affects women in their reproductive age group and is believed to be associated with ovarian secretions. Leiomyomas are monoclonal smooth muscle tumors with characteristics similar to muscle on computed tomography/magnetic resonance imaging. The presence of multiple nodules dispersed throughout the peritoneal cavity may resemble malignancy. There is no conventional treatment guideline, and the approach depends on the patient's age, symptoms, fertility requirements, and previous treatment. The treatment modalities can be surgical, hormonal, or combined. The presented case involves a 40-year-old woman who developed disseminated peritoneal leiomyomatosis after undergoing laparoscopic myomectomy.

## Keywords

- fibroid
- leiomyomas
- leiomyomatosis

## Case Report

A 40-year-old female patient presented with complaints of pain abdomen and diffuse abdominal distension noticed over the last 6 months, which were also associated with occasional dragging sensations in the abdomen and a significant weight loss of 15 kg. On physical examination, multiple nontender nodular masses were appreciable in the right iliac fossa and lumbar quadrants. She had a history of laparoscopic myomectomy for intrauterine fibroid.

## Imaging Findings

Ultrasonography of the abdomen and pelvis revealed multiple intraperitoneal well-defined solid hypoechoic lesions with internal vascularity causing compression of

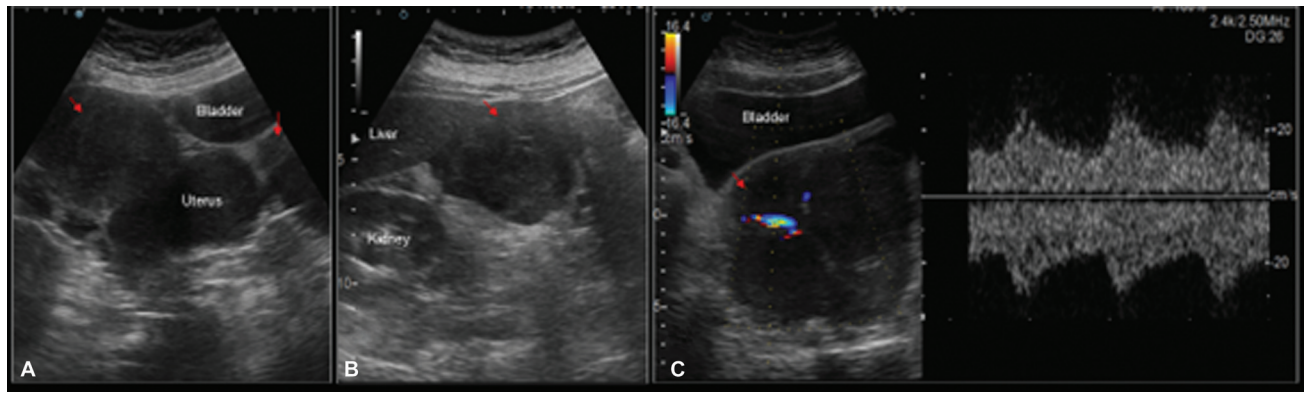
adjacent organs. Multiple serosal and intramural hypoechoic fibroids were also observed. Computed tomography (CT) confirmed disseminated peritoneal leiomyomatosis (DPL), with multiple soft tissue attenuation masses throughout the mesentery and similar masses in the small intestine and sigmoid mesentery. Similar masses were present in the bilateral colic gutter region, retroperitoneum, abdominal wall, and pelvis. The largest mass in the pelvis was noted to cause compression of the bladder, uterus, and ovaries.

Considering the disseminated nature of the condition, she was treated surgically and underwent debulking of the pelvic masses along with a hysterectomy, bilateral salpingoopherectomy, and omentectomy. The patient's postoperative course was uneventful, and histopathology revealed a benign smooth muscle tumor.

article published online  
March 23, 2024

DOI <https://doi.org/10.1055/s-0044-1780524>.  
ISSN 0971-3026.

© 2024. Indian Radiological Association. All rights reserved.  
This is an open access article published by Thieme under the terms of the Creative Commons Attribution-NonDerivative-NonCommercial-License, permitting copying and reproduction so long as the original work is given appropriate credit. Contents may not be used for commercial purposes, or adapted, remixed, transformed or built upon. (<https://creativecommons.org/licenses/by-nc-nd/4.0/>)  
Thieme Medical and Scientific Publishers Pvt. Ltd., A-12, 2nd Floor, Sector 2, Noida-201301 UP, India



**Fig. 1** (A) Multiple oval lobulated iso to hypoechoic masses of varying sizes noted in the pelvis on either side of the uterus. (B) A large lobulated mass in the right hypochondrium situated anterior to the right kidney and abutting the inferior surface of the liver. (C) Color Doppler evaluation for internal vascularity of the mass showed arterial waveform.

**Diagnosis:** Disseminated Peritoneal Leiomyomatosis (→Figs. 1–7).

## Discussion

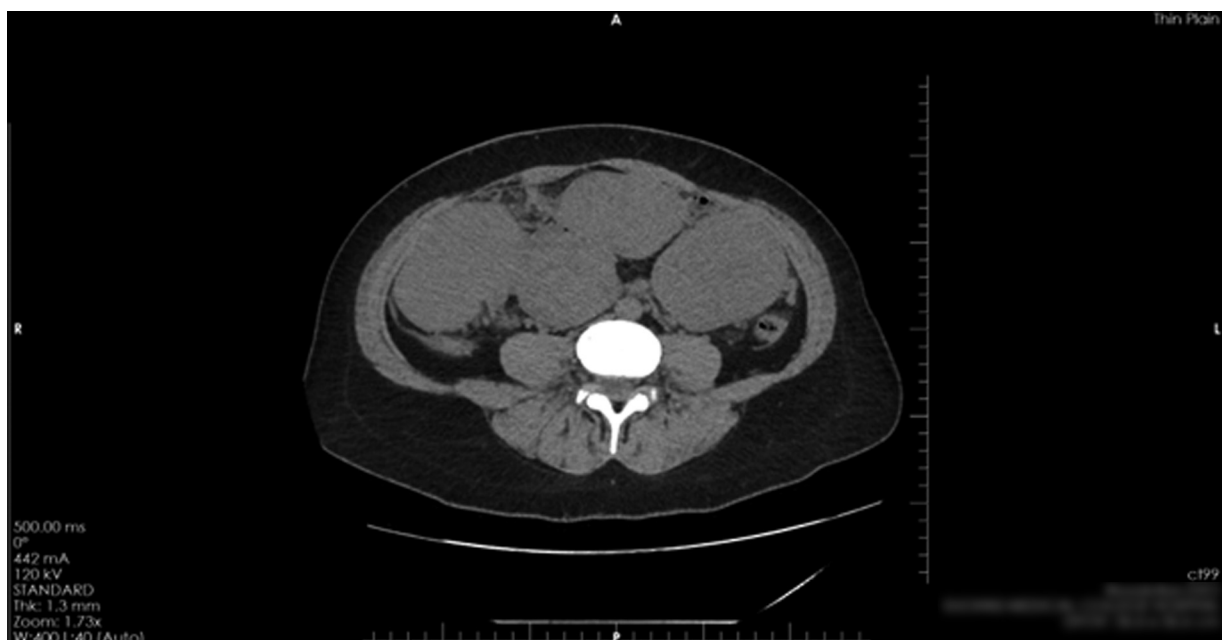DPL is a rare condition characterized by the presence of multiple benign smooth muscle nodules scattered throughout the peritoneal cavity.<sup>1–4</sup> These nodules can vary in size and distribution, and their exact etiology is still not fully understood. The most widely accepted theory is peritoneal seeding of monoclonal smooth cells following laparoscopic morcellation.<sup>3,5,6</sup>

With respect to the clinical presentation, patients with DPL can exhibit a wide range of symptoms. The most common symptoms include abdominal pain, abdominal distension, and pelvic pressure. Due to the nonspecific nature of the symptoms associated with DPL, it is crucial to consider other potential differential diagnoses. Conditions such as endometriosis,

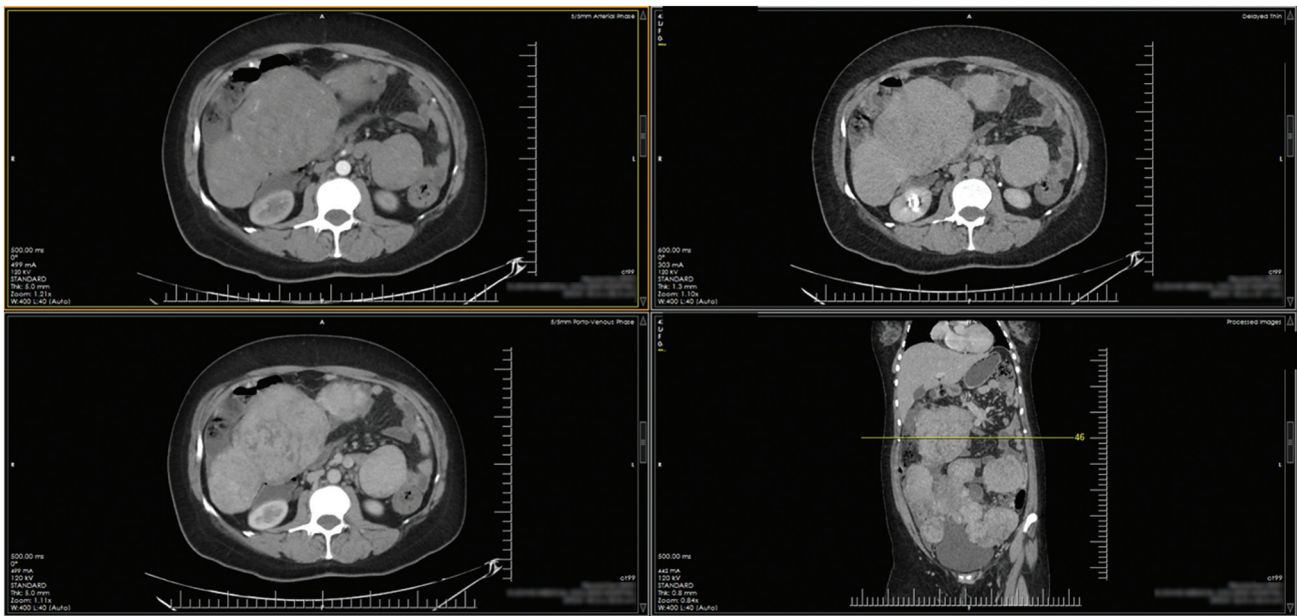
gastrointestinal tumors, disseminated ovarian tumors, and lymphoma are important differential diagnosis.<sup>1,7</sup>

Radiological imaging, including ultrasound sonography, contrast-enhanced CT, and magnetic resonance imaging (MRI), plays a significant role in the diagnosis of DPL. These imaging modalities can help visualize the peritoneal nodules, assess their distribution and size, and guide treatment decisions.

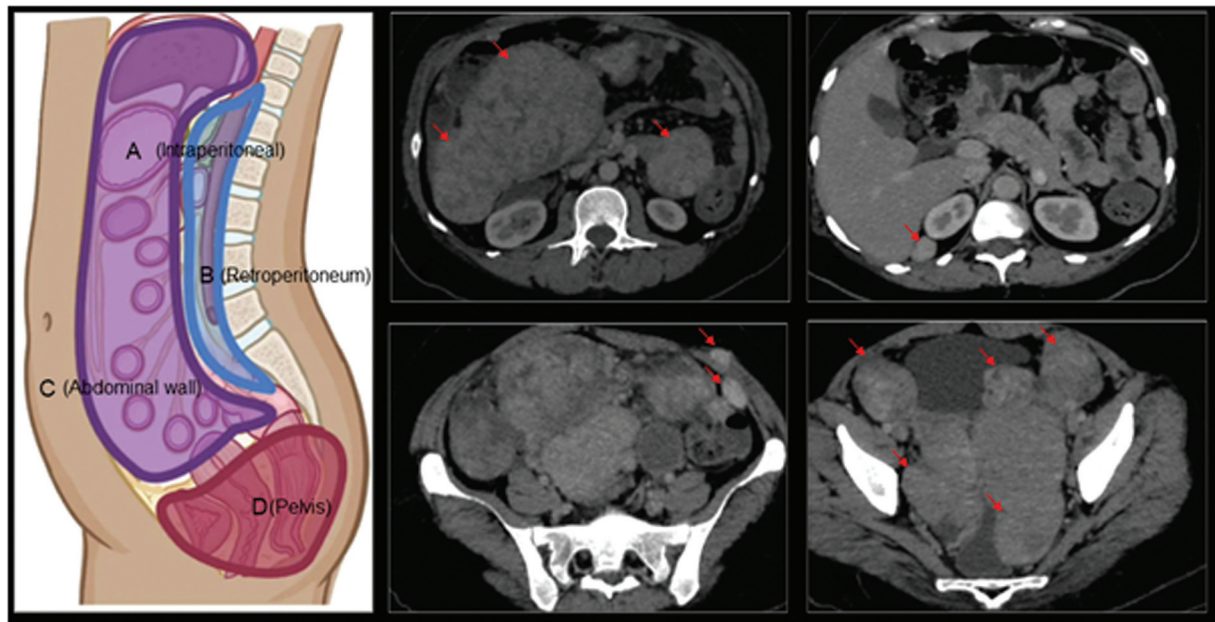
The choice of treatment for DPL depends on various factors, including the patient's symptoms, the extent of the disease, and their desire for fertility preservation. Asymptomatic patients may be managed conservatively with regular monitoring to assess disease progression and symptomatology. Hormonal therapies, such as gonadotropin-releasing hormone<sup>8</sup> agonists or aromatic inhibitors,<sup>9</sup> can be utilized to reduce the size of the nodules before surgical intervention. Surgical options for DPL range from debulking procedures involving removal of a portion of the nodules to complete



**Fig. 2** Noncontrast image showing multiple lobulated heterogeneous masses in the intraperitoneal space.



**Fig. 3** Contrast-enhanced computed tomographic images showing multiple lobulated heterogeneous enhancing masses in the mesentery, peritoneum, retroperitoneum, abdominal wall, and pelvis of varying size with most of the larger masses having a central area of decreased enhancement.



**Fig. 4** Contrast-enhanced images in venous phase showing heterogeneously enhancing masses disseminated in different regions in abdomen.

excision of all visible nodules.<sup>10</sup> In cases where fertility preservation is not a concern, total abdominal hysterectomy with bilateral salpingo-oophorectomy may be considered as a definitive treatment.<sup>10</sup>

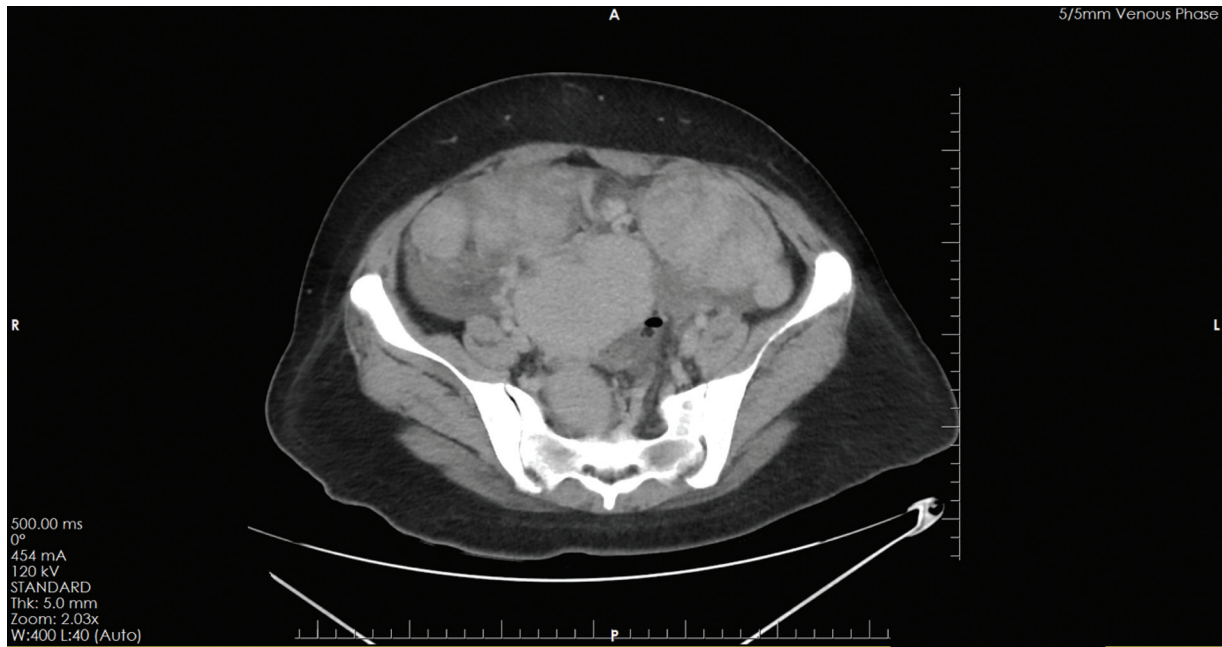
While DPL is typically considered a benign condition, rare cases of malignant transformation have been reported.<sup>11</sup> Recurrence of symptoms and the need for further interventions can occur in DPL, particularly due to the presence of microscopic residual nodules that may not have been completely removed during surgery.<sup>12</sup> Long-term follow-up and regular monitoring are crucial to detect any recurrence or progression of the disease.

Hence, reporting a case of DPL is essential for expanding medical knowledge, improving awareness, and optimizing patient care. This contributes to the understanding of this rare condition, facilitates early diagnosis, and guides clinicians in choosing the most effective treatment strategies.

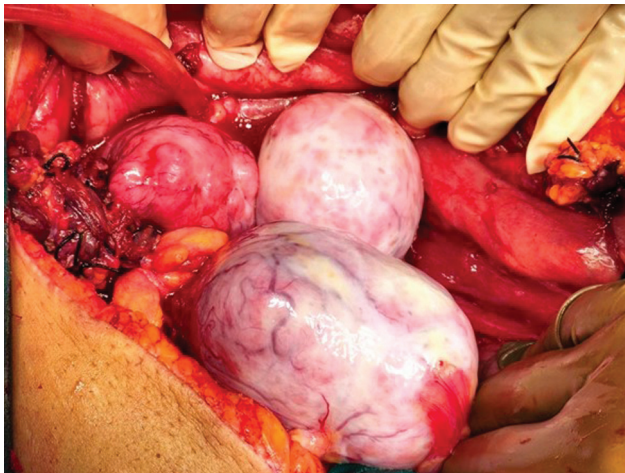
## Conclusion

DPL is a rare condition with atypical symptoms, posing multitude of management challenges. Recognition of this diagnosis is crucial in patients with a history of uterine

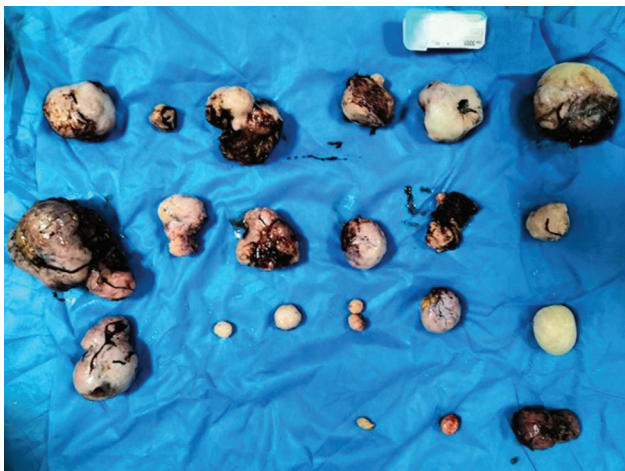



**Fig. 5** Multiple varying sizes heterogeneously enhancing lobulated masses disseminated throughout pelvic region causing significant mass effect.



**Fig. 6** Intraoperative image showing a large extrauterine intraperitoneal fibroid with its pedicle ligated.



**Fig. 7** Intraoperative picture showing multiple resected fibroids.

fibroids and unusual clinical features like umbilical swelling, weight loss, and abdominal discomfort. Timely diagnosis using ultrasound sonography, CT and MRI scans, followed by appropriate surgical intervention, can lead to positive outcomes. Further research is required to understand the underlying mechanisms and establish optimal treatment strategies for DPL.

#### Conflict of Interest

None declared.

#### References

- 1 Hiremath SB, Benjamin G, Gautam AA, Panicker S, Rajan A. Disseminated peritoneal leiomyomatosis: a rare cause of enigmatic peritoneal masses. *BJR Case Rep* 2016;2(03): 20150252
- 2 Hsieh YC, Kuo PY, Chiang YC. Leiomyomatosis peritonealis disseminata in laparoscopic port site and abdomino-pelvic cavity: a case report. *Radiol Case Rep* 2021;17(02):293–297
- 3 Larraín D, Rabischong B, Khoo CK, Botchorishvili R, Canis M, Mage G. “Iatrogenic” parasitic myomas: unusual late complication of laparoscopic morcellation procedures. *J Minim Invasive Gynecol* 2010;17(06):719–724
- 4 Willson JR, Peale AR. Multiple peritoneal leiomyomas associated with a granulosa-cell tumor of the ovary presented at a meeting of the Philadelphia Obstetrical Society, Jan. 3, 1952. *Am J Obstet Gynecol* 1952;64(01):204–208
- 5 Ye Z, Chen L. Leiomyomatosis peritonealis disseminata with low-grade malignant change: a case report. *Medicine (Baltimore)* 2022;101(36):e30528
- 6 Van der Meulen JF, Pijnenborg JM, Boomsma CM, Verberg MF, Geomini PM, Bongers MY. Parasitic myoma after laparoscopic morcellation: a systematic review of the literature. *BJOG* 2016; 123(01):69–75
- 7 Gebresellassie HW. Leiomyomatosis peritonealis disseminata in postmenopausal women: a case report with review of literature. *Int Med Case Rep J* 2016;9:309–312

- 8 Hales HA, Peterson CM, Jones KP, Quinn JD. Leiomyomatosis peritonealis disseminata treated with a gonadotropin-releasing hormone agonist. A case report. *Am J Obstet Gynecol* 1992;167(02):515–516
- 9 Takeda T, Masuhara K, Kamiura S. Successful management of a leiomyomatosis peritonealis disseminata with an aromatase inhibitor. *Obstet Gynecol* 2008;112(2 Pt 2):491–493
- 10 Chen X, Liu H, Shi H, Fan Q, Sun D, Lang J. Leiomyomatosis peritonealis disseminata following laparoscopic surgery with uncontained morcellation: 13 cases from one institution. *Front Surg* 2021;8:788749
- 11 Raspagliesi F, Quattrone P, Grosso G, Cobellis L, Di Re E. Malignant degeneration in leiomyomatosis peritonealis disseminata. *Gynecol Oncol* 1996;61(02):272–274
- 12 Quaranta M, Mehra G, Nath R, Culora G, Sayasneh A. A rare case of refractory disseminated leiomyomatosis peritonealis complicated by cauda equina compression. *Eur J Obstet Gynecol Reprod Biol* 2018;229:205–207