



The management of failed cubital tunnel decompression

Abdus S. Burahee
Andrew D. Sanders
Dominic M. Power

- Cubital tunnel decompression is a commonly performed operation with a much higher failure rate than carpal tunnel release.
- Failed cubital tunnel release generally occurs due to an inadequate decompression in the primary procedure, new symptoms due to an iatrogenic cause, or development of new areas of nerve irritation.
- Our preferred technique for failed release is revision circumferential neurolysis with medial epicondylectomy, as this eliminates strain, removes the risk of subluxation, and avoids the creation of secondary compression points.
- Adjuvant techniques including supercharging end-to-side nerve transfer and nerve wrapping show promise in improving the results of revision surgery.
- Limited quality research exists in this subject, compounded by the lack of consensus on diagnostic criteria, classification, and outcome assessment.

Keywords: compression neuropathy; failed cubital tunnel syndrome; ulnar nerve

Cite this article: *EFORT Open Rev* 2021;6:735-742.
DOI: 10.1302/2058-5241.6.200135

Introduction

Cubital tunnel syndrome (CuTS) is the second most common compression neuropathy and affects the ulnar nerve at the elbow. Surgery is to be considered when conservative options have failed, when there is poor symptom control or symptom progression with motor weakness. There are different surgical procedures in common usage, with in situ decompression being the predominant intervention in simple cases with a low risk of complications. When there is nerve subluxation, surgical options include medial epicondylectomy or a formal anterior transposition procedure, either subcutaneous or submuscular. These procedures have higher rates of complications. Dellon correlated the success of surgery with the severity

of nerve compression with unsatisfactory results in 10% of moderate compression and 20% to 35% for severe compression cases.¹ Failure of cubital tunnel decompression surgery can be defined clinically by persistence of symptoms for three months after surgery or recurrence of symptoms within six months of surgical treatment, either of which can be accompanied by new symptoms.² Persisting symptoms may be due to an incorrect diagnosis, inadequate release or failure to improve the condition of a significantly compromised nerve. Recurrent symptoms are often the result of perineural scar formation with impaired nerve glide; however, neo-subluxation is also implicated. New neurological symptoms may represent an intraoperative nerve injury or damage to cutaneous nerves. The risk of scar formation can be reduced with careful surgical technique, minimal nerve handling, meticulous haemostasis and early rehabilitation. The potentially preventable causes of failure are from poor decision making and technical errors that render the nerve susceptible to subluxation or neo-compression. There is no consensus on the management of cubital tunnel, and the aim of this article is to provide a guide to management based on our clinical experience of treating failed surgery.

Cubital tunnel syndrome

The ulnar nerve (UN) supplies motor function to the flexor carpi ulnaris (FCU), the two ulnar flexor digitorum profundus (FDP) tendons, the palmar and dorsal interossei, the two ulnar lumbricals, the abductor digiti minimi (AbDM), the hypothenar muscles, the adductor pollicis (AdP) and sensation to the volar and dorsal aspects of the ulnar side of the hand and to the small finger and the ulnar aspect of the ring finger. Cubital tunnel results in pain, altered feeling, numbness, weakness of grip and key pinch, and loss of fine digital movements. Surgery is indicated in mild cases with persistence of symptoms despite activity modification and in moderate and severe cases with sensory loss and motor weakness or paralysis. Surgery is effective

in improving pain and resolving paraesthesia independent of compression severity; however, numbness and motor recovery are less predictable, with surgery aimed primarily at preventing progression. Functional improvements are more variable, perhaps reflecting the complexity of UN function and individual variations in hand use. CuTS has an incidence of 25 per 100,000 in men and 19 per 100,000 in women in the UK.³ The surgical intervention rate per new diagnosis has increased from 31% to 67% from 2000 to 2011 and it was estimated in 2015 that there would be over 9000 surgical procedures in 2020.⁴ Despite the high volumes of surgical procedures, there are few high-quality comparative trials and little consensus regarding the optimal management of this condition.⁵ A Cochrane Review, updated in 2016, which identified seven randomized controlled trials (RCTs) comparing different surgical methods with no significant difference in outcome found, however, that endoscopic release led to higher rates of haematoma and transposition was associated with more wound infections.⁶ An estimated 25% of cases will have recurrence of symptoms,⁷ which suggests that there could be several thousand patients each year in the UK who may require a revision procedure. Risk factors for failure include younger age at presentation, greater static two-point discrimination and history of diabetes.⁸

Failed cubital tunnel decompression

Failure following any surgical procedure is defined as not achieving the primary objective, which in the case of CuTS, is the resolution of pain, paraesthesia, numbness and possibly weakness. Failure from a patient's perspective may be the absence of a return to normal function. Severe CuTS involves motor weakness or paralysis and it is not realistic to expect a return to normal. As such, the role of the clinician, to classify the disease severity, provide a prognosis and guide the patient's expectations, is key to patient satisfaction. Objective measurements of sensation and motor strength form the basis of surgeon-derived measures of outcome; however, patient-reported outcomes, pain and procedural satisfaction provide the most useful measures of surgery success. New symptoms that develop due to nerve injury, scarring or subluxation must also be reported and used to determine failure. A review reported failure rate for primary cubital tunnel surgery between 2.4% and 17%, with the lowest rate of complications in simple decompression cases, and transposition or medial epicondylectomy associated with higher rates, perhaps reflecting a more complex presentation with subluxation or severe compression and the complexity of the procedure.⁹

Failure in CuTS can be broadly defined as persistence of, recurrence of or development of new symptoms. Each of these will be discussed in detail.

Persistent symptoms

CuTS is the result of compression and traction affecting the UN as it passes posterior to the elbow joint. Persistent symptoms may reflect incomplete decompression, failure to address a nerve subluxation, moderate or severe compression where the expectation is prevention of deterioration rather than complete resolution or another alternative or synchronous diagnosis such as Guyon's canal compression,¹⁰ thoracic outlet syndrome or lower cervical radiculopathy which may resemble the clinical presentation.¹¹ There may be multiple sites of compression in one limb.¹² Incomplete decompression accounts for up to 20% of failed cubital tunnel cases.¹³ In a series of 100 revision cases, the fascial septum between the FCU and the pronator teres in the distal tunnel was suggested as the most common site of persistent compression.¹⁴

Recurrent symptoms

Interval improvement or resolution of symptoms followed by a further deterioration is often associated with scar formation at the site of surgery impeding nerve glide and resulting in recurrent compression. Primary transposition procedures are prone to interval failure if neo-compression sites are not anticipated and there are technical errors or omissions in the first operation. Transposition may create a tether point at the arcade of Struthers. The nerve may rest against the distal insertion of the intermuscular septum to the medial epicondylar ridge, or may be tethered by the motor branch to the ulnar head of the FCU at the distal extent of the transposition. Creating a neo-instability with tenting of the nerve around the medial epicondyle was also implicated in recurrent symptoms.¹⁴ Intraoperative recognition of a potentially unstable nerve at the primary operation may be treated with transposition. If the nerve is unstable in the new position, surgeons may create a fascial sling from the common flexor origin to try and prevent the nerve moving back to the retrocondylar groove. This may scar and create a tether point with temporary symptom relief and then a subsequent recurrence and deterioration. Scar tether may follow complications of the primary surgery including bleeding, haematoma formation and infection. Failure of the initial procedure, both for simple decompression and anterior transposition, was deemed to be due to perineural fibrosis in 14/22 patients.¹⁵ Similar findings were reported in all nine patients with failed CuTS who underwent anterior submuscular transposition as primary surgery.¹⁶

New symptoms

Failure to recognize an unstable UN may result in a new onset of UN subluxation and a painful neuritis where the nerve is irritated as it moves abnormally against the medial epicondyle during elbow flexion. This may produce

recurrent or persistent cubital tunnel symptoms with an additional painful clicking sensation on deep elbow flexion. Injury to the main UN is rare, however, the medial antebrachial cutaneous nerve (MABCN) may be damaged during the surgical approach creating a painful neuroma at the site of injury with numbness in the medial forearm, a painful scar and, on occasion, severe allodynia. The posterior branch of the MABCN is the most vulnerable and lies within 40 mm of the medial epicondyle in approximately 60% of cases.¹⁷

Assessment of failed cubital tunnel surgery

The clinician must take a detailed history to determine the timing of onset and severity of symptoms including any interval improvement following surgery. Alternative diagnoses must be excluded. A history of medial elbow pain radiating to the medial arm and hand with altered sensation confined to the ulnar side of the hand, weakness of grip and loss of fine motor control is suggestive of an ulnar compression neuropathy in the region of the elbow. The forearm and hand must be observed for muscle wasting. Loss of thenar, hypothenar and interosseous muscle bulk with sensation loss confined to the ulnar hand and forearm may suggest a diagnosis of neurogenic thoracic outlet syndrome. Altered sensation in the median and UN distribution may imply a concomitant carpal tunnel syndrome. MABCN loss after a primary cubital tunnel decompression may be associated with injury to the small nerve branches during the original operation.

Onset of symptoms with elbow flexion for one minute is a useful provocative test for CuTS. The UN should be palpated and abnormal movement in the sagittal plane suggesting subluxation should be determined for both active and passive elbow movements. An overdeveloped medial head of triceps may dislocate over the medial epicondyle, producing a symptomatic snapping sensation which is commonly misdiagnosed. Spinner et al described a double snapping sensation with the nerve subluxing at 90 degrees and the triceps dislocating at 110 degrees of elbow flexion.¹⁸ Tinel's sign is elicited by tapping over the course of the UN from the fingers in a proximal direction. Points of irritation with reproduction of paraesthesia should be marked. Common compression sites include the FCU, the retrocondylar groove, the medial intermuscular septum and the region of the arcade of Struthers. The resisted small finger flexion test is a useful way of determining extrinsic motor weakness affecting the FDP. The examiner's index finger should not be able to extend the flexed Distal Interphalangeal Joint (DIPJ) of the small finger of the subject under test if the motor strength is normal. Strength of the interossei and the adductor

pollicis should be tested with a Froment's test and digit adduction. AbDM strength is determined by resisted small finger abduction. The UN should also be examined at the level of Guyon's canal to exclude a concomitant distal compression.

The scar should be carefully examined to determine local tenderness or a Tinel's sign radiating only to the medial forearm skin, suggestive of a neuroma in the MABCN territory. Tether pain of the UN during passive elbow extension is a rare finding but may be correlated with nerve tether due to perineural scar.

Review of previous records

The original diagnosis must be reviewed. Access to copies of outpatient correspondence, operation notes, anaesthesia records, therapy records, imaging studies and neurophysiology tests are valuable. Pain management should be evaluated and a pain diary can be helpful. The baseline compression severity can be ascertained as well as interval deterioration.

Imaging studies

There is interest in using ultrasound imaging of the UN to localize compression. As a dynamic study, ultrasound is useful to determine points of tether. Magnetic resonance imaging (MRI) neurography shows promise in determining local inflammation, oedema and intraneural scar. We do not use imaging studies in the assessment of primary or failed CuTS unless there is severe localized Tinel's sign at another point that could suggest an intrinsic nerve tumour accounting for unusual UN symptoms without signs at the elbow level.

Neurophysiology studies

Neurophysiology studies measure the function within the UN. Nerve conduction velocities may be slowed across points of compression or scar. A loss of amplitude in the MABCN cutaneous territory compared to the contralateral limb can indicate potential injury of these nerve branches. A reduction in amplitude of the compound muscle action potential suggests axonal loss when associated with muscle wasting. Electromyography of the target ulnar innervated muscles will demonstrate reduced amplitude of the compound muscle action potential (CMAP) as well as fibrillation and positive sharp waves (PSW) from muscle denervation due to axonopathy. Neurophysiology studies can exclude other sites of compression, an underlying neuropathy and radiculopathy. Review of the original neurophysiology, interval studies demonstrating improvement or deterioration and contemporary studies are valuable in assessing the possible cause of failure and planning revision surgery.

Revision cubital tunnel surgery

The patient should be counselled regarding the planned surgery, the different treatment options and any adjunctive procedures that may be required. The points of maximum Tinel's irritation should be marked prior to anaesthesia. Revision surgery should be performed under general anaesthetic or a regional brachial plexus block with a proximal fascial block to cover the intercostobrachial nerve, terminal medial brachial cutaneous nerve branches and the MABCN. This adjunctive block improves high arm tourniquet tolerance. Full limb preparation to the axilla, followed by application of a sterile pneumatic tourniquet is our preferred technique.

The original incision site is extended proximally and distally to allow exposure of the UN in tissues that are not scarred from the previous surgery. Cutaneous nerve branches must be identified and any neuromas mobilized in preparation for definitive treatment. Dissecting in a proximal to distal direction along the UN during neurolysis avoids damage to side branches. A surgical sloop can be placed around the proximal nerve and used to lift and to mobilize the nerve, providing controlled tension on the tissues to be dissected without undue handling of the nerve. The motor branches to the FCU must be identified and protected. The elbow should be cycled through a full range of motion to determine any deep tether points prior to completing a circumferential neurolysis. The distal dissection should extend between the two heads of the FCU and any constricting fascial bands must be released. Proximally the nerve should be traced to the medial intermuscular septum hiatus, and release of the arcade of Struthers is usually necessary. A large crossing vein is usually identified between 5 and 7 cm proximal to the medial epicondyle. Where possible, feeding vascular pedicles should be preserved along with the longitudinal vessels in the paraneurium. We recommend that in revision cases a circumferential neurolysis is completed along the whole course of the UN across the elbow.

Some surgeons prefer to undertake a transposition in revision cases in an attempt to detension the nerve, eliminate subluxation, and, if sensitive, relocate it to a deeper submuscular plane. Our experience with the management of failed cubital tunnel cases is that transposition surgery can be associated with neo-compression sites and distortion of the nerve creating scar tether and movement-associated pain. For this reason, our preference is to perform an in situ decompression and medial epicondylectomy.

A medial epicondylectomy eliminates strain acting across the nerve, removes the risk of subluxation and aligns the nerve without creating secondary compression points. The common flexor origin is elevated off the medial epicondyle sufficiently to ensure the entire prominence is exposed distally, without disturbing the medial collateral ligament.

A triangular section of the distal medial intermuscular septum (MIS) is removed, creating a free passage for the nerve in the more anterior plane. The osteotomy is performed in an oblique plane with the exit point at the previous insertion of the MIS. Care should be taken to ensure that there is no residual constriction or distortion of the nerve at the arcade of Struthers or distally at the FCU. We have not experienced any elbow instability utilizing this technique. If the nerve is heavily scarred, the addition of a nerve wrap is advantageous as it creates a gliding layer around the nerve which revascularizes and creates a neo-paraneurium.

Cutaneous neuromas must be resected and then proximally relocated to a plane deep to the UN in the distal arm. Proximal nerve stumps can be capped to prevent tether in scar; however, the evidence to support this approach is currently limited. Centro-central anastomosis may be performed for two adjacent branches with microsurgical neurorrhaphy and then a controlled proximal crush of each branch, creating a loop of nerve for axonal regeneration. Targeted muscle reinnervation to the brachialis or the medial head of the triceps can be utilized in exceptional circumstances.

The wound is closed with an absorbable suture, an occlusive dressing and then a bulky bandage. Cast or splint immobilization is not necessary. The dressings are reduced after five days and gentle range of motion exercises commenced. Heavy lifting should be avoided for six weeks.

Figures 1-6 illustrate the intra-operative approach and findings in revision cubital tunnel surgery.

Adjunctive distal nerve transfer

Cases with severe intrinsic wasting are unlikely to have return of useful intrinsic function following release of longstanding compression of the UN at the cubital tunnel. A nerve transfer of the terminal anterior interosseous nerve

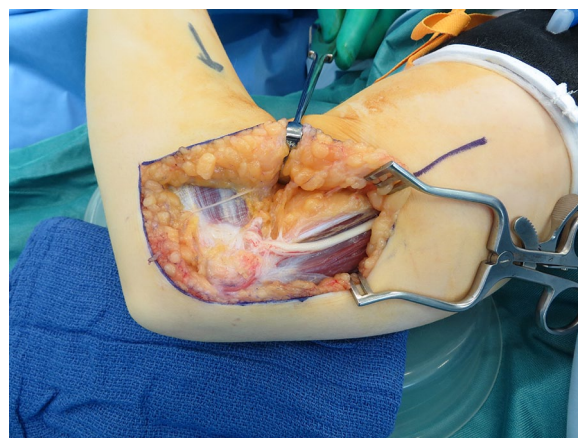


Fig. 1 Ulnar nerve tethered in scar tissue following previous subcutaneous anterior transposition.

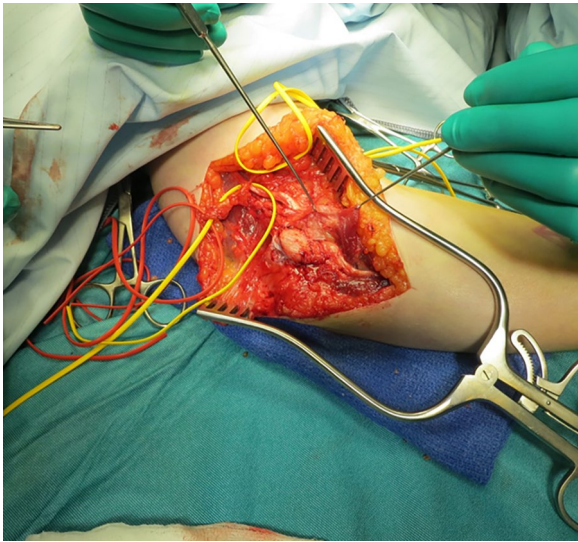


Fig. 2 Previous submuscular transposition with new compression points.

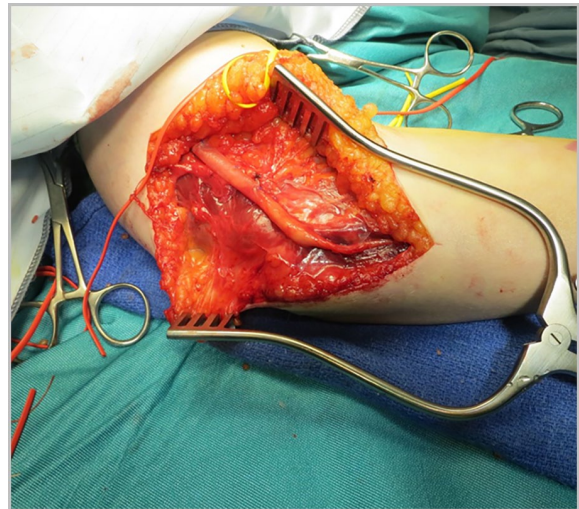


Fig. 4 Ulnar nerve following medial epicondylectomy and wrapping.

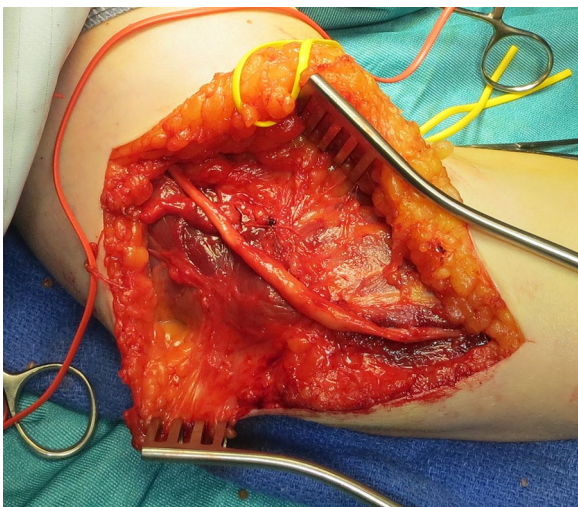


Fig. 3 Decompressed ulnar nerve following medial epicondylectomy and repair of common flexor origin.

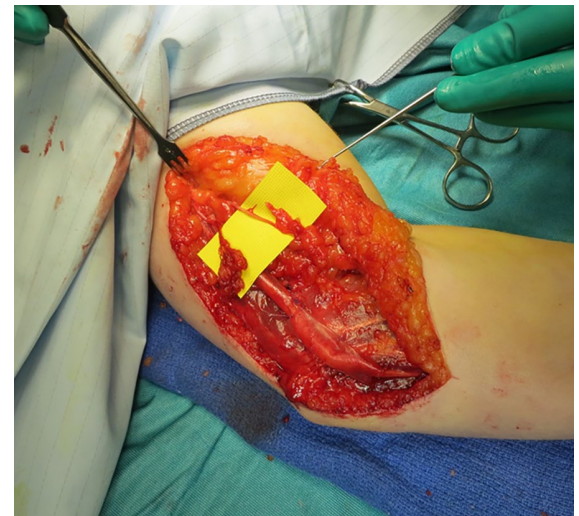

Fig. 5 Iatrogenic medial antebrachial cutaneous nerve neuromas secondary to primary cubital tunnel decompression.

to pronator quadratus to the fascicle groups of the deep UN in the distal forearm performed as either supercharging end-to-side (SETS) or a hemi-end-to-end may confer some benefit by providing the distal nerve with a pool of healthy motor axons to repopulate empty endoneurial tubes.^{19,20} Successful SETS has been reported in cases with active denervation on electromyography.²¹

Outcomes

The uncertainty surrounding management of CuTS is compounded by the lack of consensus on diagnostic criteria, classification, and outcome measures. A review of reported outcome measures following CuTS identified

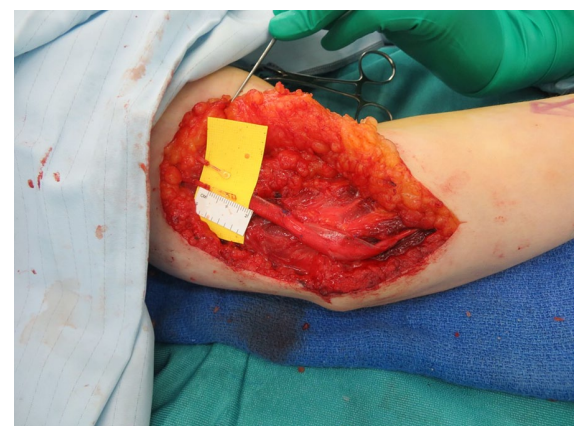

Fig. 6 Medial antebrachial cutaneous nerve neuromas treated with excision and capping.

101 studies which used 45 unique outcomes and 31 post-operative outcome measures.²² The Patient-Rated Ulna Nerve Evaluation (PRUNE) score was the only validated diagnosis-specific tool, but was only reported in 3% of included studies. This results in meta-analysis being of limited benefit due to the heterogeneity of reported data.²³

Patients do show improvement following revision cubital tunnel surgery, in particular in relation to pain,²⁴ however, outcomes are generally worse than for primary surgery with a higher frequency of residual symptoms, higher PRUNE score and an improvement in McGowan grade in 25% compared to 64% of primary surgery procedures.²⁵ The importance of long-term follow-up was highlighted in a recent series where improvements in intrinsic motor power after SETS transfer were seen up to 18 months after surgery.²⁶

Discussion

Although simple decompression is the most common primary procedure used in the management of CuTS,²⁷ in revision cases for failed cubital tunnel decompression it may not deal with UN strain or subluxation. A systematic review reported just 3% of patients having in situ decompression as a revision procedure, with subcutaneous transposition being the most common operation for a primary failed procedure (33%).²⁸

Subcutaneous transposition has been identified as imparting a greater surgical morbidity than decompression alone.²⁹ With neo-compression points as common sites of failure,³⁰ it highlights the importance of ensuring that all fascial structures are addressed.³¹ This should include excising a triangular piece of medial intermuscular septum from its insertion to the humerus proximal to the epicondyle and any fascial layers between the flexor/pronator muscles in a submuscular transposition. A good or excellent result was reported in 75% of patients who underwent subcutaneous transposition after a previous failed procedure, regardless of primary technique.³² Worse outcomes are seen with increasing age and number of previous surgeries.

Submuscular transposition remains one of the most commonly utilized techniques for management of recurrent CuTS (75% of cases)²⁸ despite the lack of good evidence to support this approach. When submuscular transposition was utilized following failed subcutaneous transposition, most had partial relief of pain with a satisfaction rate of 78%.³³

Medial epicondylectomy (ME) aims to address both the compressive forces and tension on the nerve during elbow flexion, with one study showing a recurrence rate of only 10%.³⁴ Findings in re-exploration following either simple decompression or anterior transposition frequently found

the nerve to be sitting directly over the medial epicondyle.³⁰ Described as a total epicondylectomy by King et al in 1959,³⁵ the technique has been modified to a partial excision in order to minimize the risk of instability of the elbow joint. The evidence for ME in recurrent CuTS is limited. A systematic review of ME for primary treatment only identified six comparative studies, two showing no difference when compared with transposition, three reporting superior outcomes, and one study which found similar results to simple decompression.³⁶ A recent survey of UK surgeons found that only 2% preferred ME for a primary procedure, with clinical experience identified as one of the most popular rationales for choosing an alternative method.³⁷ There is a learning curve and a perception of high complication rate that limits the wider adoption of this technique.

The effectiveness and safety of wrapping a scarred nerve is emerging. The ideal barrier should incite minimal reaction, facilitate nutrient diffusion, avoid scar-induced ischaemia, promote nerve gliding, have no donor site morbidity and an acceptable cost.³⁸ Autologous adipofascial flaps provide healthy and vascular tissues to resurface scarred nerves helping to improve nerve glide. Anatomical location, donor morbidity and technical demands limit their wider utility. Collagen, bioresorbable polymers, amniotic membranes and autologous veins are alternative wrapping methods. An early report of layered porcine submucosal extracellular matrix collagen wrap demonstrated improved pain and function in 12 revision cubital tunnel decompressions.³⁹ The wider utility of these collagen wraps in managing the scarred nerve continues to develop.⁴⁰ Autologous vein wrapping has demonstrated efficacy, albeit at a donor site cost.^{41,42}

The use of the SETS nerve transfer from the terminal motor branch of the anterior interosseous nerve to the distal UN motor fascicles has increased in popularity, despite the paucity of high-quality evidence to support its use. The adoption of this technique is likely a consequence of the well-recognized poor motor recovery following decompression of the severe and longstanding cubital tunnel compression neuropathy.^{43,44} The largest cohort of SETS for cubital tunnel neuropathy to date has shown improved intrinsic function to Medical Research Council (MRC) grade ≥ 3 in 33 of 42 patients, with three patients having no recovery of function. There was no threshold of CMAP amplitude below which the technique was unsuccessful; however, active fibrillation is reported as a prerequisite, reflecting the superior results in less chronic lesions.²¹ Further reports on the efficacy of SETS continue to emerge. Significant clinical and electrodiagnostic improvement was demonstrated in a recent series of 30 cases with severe CuTS (20 patients had MRC grade 1 or less, with severely reduced CMAPs). Over three-quarters noted partial or complete resolution of clawing,

73% regained MRC grade 3 or higher, and 47% achieved at least MRC grade 4.²⁶ Head et al found significant improvement in intrinsic motor power in a review of 17 patients following SETS transfer; however, they identified greater recovery of the first dorsal interosseous muscle compared to the adductor digiti minimi.⁴⁵

An algorithm to refine the indications for SETS transfer in CuTS has recently been published. It suggests performing this procedure when the following criteria have been met: (1) Slowed conduction velocity across the elbow; (2) Intrinsic weakness; (3) Decreased CMAP amplitude at wrist; (4) Ulnar motor nerve Electromyography (EMG): Fibrillations +/- PSW present; (5) Normal pronator quadratus EMG.⁴⁶

Conclusion

Cubital tunnel decompression surgery has a lower success rate than carpal tunnel release, perhaps reflecting the different functions of the ulnar and median nerves, the more proximal location of the compression, the more complex characteristics of compression, strain and subluxation in the syndrome and the varied approach to management. Revision surgery is generally less successful than primary decompression and the technique employed should address all contributing factors. The experience of our group in revision cubital tunnel surgery favours circumferential neurolysis and ME. The technique decompresses the nerve, improves nerve glide, relieves tension, eradicates subluxation and restores nerve alignment. Adjunctive nerve wrapping and distal SETS nerve transfer have limited evidence to support their use and remain controversial.

AUTHOR INFORMATION

The Peripheral Nerve Injury Service, University Hospitals Birmingham NHS Foundation Trust, Birmingham, UK.

Correspondence should be sent to: Abdus Burahee, HaPeN Office, 4th Floor, Institute of Translational Medicine, Birmingham, B15 2WB, UK.
Email: Abdus.burahee@nhs.net

ICMJE CONFLICT OF INTEREST STATEMENT

DMP reports receipt of faculty fees for lecturing and for leading workshops in peripheral nerve injury (including the use of the Axoguard for scarred nerves) from Axogen Inc., relating to the published work. The other authors declare no conflicts of interest.

FUNDING STATEMENT

No benefits in any form have been received or will be received from a commercial party related directly or indirectly to the subject of this article.

SOCIAL MEDIA

Twitter: @dominicpower1 @buraheebdus

LinkedIn: <http://www.linkedin.com/in/abdusburahee>

OPEN ACCESS

© 2021 The author(s)

This article is distributed under the terms of the Creative Commons Attribution-Non Commercial 4.0 International (CC BY-NC 4.0) licence (<https://creativecommons.org/licenses/by-nc/4.0/>) which permits non-commercial use, reproduction and distribution of the work without further permission provided the original work is attributed.

REFERENCES

- Dellon AL.** Review of treatment results for ulnar nerve entrapment at the elbow. *J Hand Surg Am* 1989;14:688–700.
- Low J III, Mackinnon SE.** Management of secondary cubital tunnel syndrome. *Plast Reconstr Surg* 2004;113:e1–e16.
- Latinovic R, Gulliford MC, Hughes RA.** Incidence of common compressive neuropathies in primary care. *J Neurol Neurosurg Psychiatry* 2006;77:263–265.
- Bebington E, Furniss D.** Linear regression analysis of Hospital Episode Statistics predicts a large increase in demand for elective hand surgery in England. *J Plast Reconstr Aesthet Surg* 2015;68:243–251.
- Staples JR, Calfee R.** Cubital tunnel syndrome: current concepts. *J Am Acad Orthop Surg* 2017;25:e215–e224.
- Caliandro P, La Torre G, Padua R, Giannini F, Padua L.** Treatment for ulnar neuropathy at the elbow. *Cochrane Database Syst Rev* 2016;11:CD006839.
- Grandizio LC, Maschke S, Evans PJ.** The management of persistent and recurrent cubital tunnel syndrome. *J Hand Surg Am* 2018;43:933–940.
- Izadpanah A, Maldonado AA, Bishop AT, Spinner RJ, Shin AY.** Risk factors for revision cubital tunnel surgery. *J Plast Reconstr Aesthet Surg* 2020;73:959–964.
- Bartels RH, Menovsky T, Van Overbeeke JJ, Verhagen WI.** Surgical management of ulnar nerve compression at the elbow: an analysis of the literature. *J Neurosurg* 1998;89:722e727.
- Kwak KW, Kim MS, Chang CH, Kim SH.** Ulnar nerve compression in Guyon's canal by ganglionic cyst. *J Korean Neurosurg Soc* 2011;49:139–141.
- Upton AR, McComas AJ.** The double crush in nerve entrapment syndromes. *Lancet* 1973;7825:359–362.
- Gabel GT, Amadio PC.** Reoperation for failed decompression of the ulnar nerve in the region of the elbow. *J Bone Joint Surg [Am]* 1990;72-A:213–219.
- Goldfarb CA, Sutter MM, Martens EJ, Manske PR.** Incidence of re-operation and subjective outcome following in situ decompression of the ulnar nerve at the cubital tunnel. *J Hand Surg Eur Vol* 2009;34:379–383.
- Mackinnon SE, Novak CB.** Operative findings in reoperation of patients with cubital tunnel syndrome. *Hand (N Y)* 2007;2:137–143.
- Filippi R, Charalampaki P, Reisch R, Koch D, Grunert P.** Recurrent cubital tunnel syndrome: etiology and treatment. *Minim Invasive Neurosurg* 2001;44:197–201.
- Dagregorio G, Saint-Cast Y.** Simple neurolysis for failed anterior submuscular transposition of the ulnar nerve at the elbow. *Int Orthop* 2004;28:342–346.
- Tanaka SK, Lourie GM.** Anatomic course of the medial antebrachial cutaneous nerve: a cadaveric study with proposed clinical application in failed cubital tunnel release. *J Hand Surg Eur Vol* 2015;40:210–212.
- Spinner RJ, Goldner RD.** Snapping of the medial head of the triceps and recurrent dislocation of the ulnar nerve: anatomical and dynamic factors. *J Bone Joint Surg [Am]* 1998;80-A:239–247.

- 19. Barbour J, Yee A, Kahn LC, Mackinnon SE.** Supercharged end-to-side anterior interosseous to ulnar motor nerve transfer for intrinsic musculature reinnervation. *J Hand Surg Am* 2012;37:2150–2159.
- 20. Power D, Nassimzadeh M, Cavallaro D, Jordaan P, Mikalef P.** Rewiring the upper limb: motor nerve transfer surgery in the reconstruction of paralysis. *J Musculoskelet Surg Res* 2019;3:53–59.
- 21. Dengler J, Dolen U, Patterson JMM, et al.** Supercharge end-to-side anterior interosseous-to-ulnar motor nerve transfer restores intrinsic function in cubital tunnel syndrome. *Plast Reconstr Surg* 2020;146:808–818.
- 22. Gallo L, Gallo M, Murphy J, et al.** Reporting outcomes and outcome measures in cubital tunnel syndrome: a systematic review. *J Hand Surg Am* 2020;45:707–728.e9.
- 23. Macadam SA, Gandhi R, Bezuhly M, Lefavre KA.** Simple decompression versus anterior subcutaneous and submuscular transposition of the ulnar nerve for cubital tunnel syndrome: a meta-analysis. *J Hand Surg Am* 2008;33:1314.e1–12.
- 24. Davidge KM, Ebersole GC, Mackinnon SE.** Pain and function following revision cubital tunnel surgery. *Hand (N Y)* 2019;14:172–178.
- 25. Aleem AW, Krogue JD, Calfee RP.** Outcomes of revision surgery for cubital tunnel syndrome. *J Hand Surg Am* 2014;39:2141–2149.
- 26. Doherty CD, Miller TA, Larocerie-Salgado J, Byers BA, Ross DC.** Reverse end-to-side anterior interosseous nerve-to-ulnar motor transfer for severe ulnar neuropathy. *Plast Reconstr Surg* 2020;146:306e–313e.
- 27. Chung KC.** Treatment of ulnar nerve compression at the elbow. *J Hand Surg Am* 2008;33:1625–1627.
- 28. Kholinne E, Alsharidah MM, Almutair O, et al.** Revision surgery for refractory cubital tunnel syndrome: a systematic review. *Orthop Traumatol Surg Res* 2019;105:867–876.
- 29. Staples R, London DA, Dardas AZ, Goldfarb CA, Calfee RP.** Comparative morbidity of cubital tunnel surgeries: a prospective cohort study. *J Hand Surg Am* 2018;43:207–213.
- 30. Mackinnon SE, Novak CB.** Operative findings in reoperation of patients with cubital tunnel syndrome. *Hand (N Y)* 2007;2:137–143.
- 31. Tang P, Hoellwarth JS, Chauhan A.** Recurrent cubital tunnel syndrome: a critical analysis review. *JBJS Rev* 2016;4:01874474–201603000–00007.
- 32. Caputo AE, Watson HK.** Subcutaneous anterior transposition of the ulnar nerve for failed decompression of cubital tunnel syndrome. *J Hand Surg Am* 2000;25:544–551.
- 33. Vogel RB, Nossaman BC, Rayan GM.** Revision anterior submuscular transposition of the ulnar nerve for failed subcutaneous transposition. *Br J Plast Surg* 2004;57:311–316.
- 34. Schnabl SM, Kisslinger F, Schramm A, et al.** Subjective outcome, neurophysiological investigations, postoperative complications and recurrence rate of partial medial epicondylectomy in cubital tunnel syndrome. *Arch Orthop Trauma Surg* 2011;131:1027–1033.
- 35. King T, Morgan FP.** Late results of removing the medial humeral epicondyle for traumatic ulnar neuritis. *J Bone Joint Surg [Br]* 1959;41-B:51–55.
- 36. O'Grady EE, Vanat Q, Power DM, Tan S.** A systematic review of medial epicondylectomy as a surgical treatment for cubital tunnel syndrome. *J Hand Surg Eur Vol* 2017;42:941–945.
- 37. O'Grady E, Power D, Tan S.** Current attitudes regarding surgical treatment of cubital tunnel syndrome in the UK. *J Hand Surg Eur Vol* 2017;42:959–960.
- 38. Dy CJ, Aunins B, Brogan DM.** Barriers to epineural scarring: role in treatment of traumatic nerve injury and chronic compressive neuropathy. *J Hand Surg Am* 2018;43:360–367.
- 39. Papatheodorou LK, Williams BG, Sotereanos DG.** Preliminary results of recurrent cubital tunnel syndrome treated with neurolysis and porcine extracellular matrix nerve wrap. *J Hand Surg Am* 2015;40:987–992.
- 40. Power D, Jordaan PW, Uhiara O.** Management of the scarred nerve using porcine submucosa extracellular matrix nerve wraps. *J Musculoskelet Surg Res* 2019;3:128–133.
- 41. Masear MP, Tullos JR, St Mary E, Mayer RD.** Venous wrapping of nerve to prevent scarring. *J Hand Surg Am* 1990;15A:817–818.
- 42. Mulgrew S, Kanabar GP, Papanastasiou S.** Further evidence for treatment of recalcitrant neuropathy of the upper limb with autologous vein wrapping. *Ann Plast Surg* 2012;69:288–291.
- 43. Domeshek LF, Novak CB, Patterson JMM, et al.** Nerve transfers: a paradigm shift in the reconstructive ladder. *Plast Reconstr Surg Glob Open* 2019;7:e2290.
- 44. Davidge KM, Yee A, Moore AM, Mackinnon SE.** The supercharge end-to-side anterior interosseous-to-ulnar motor nerve transfer for restoring intrinsic function: clinical experience. *Plast Reconstr Surg* 2015;136:344e–352e.
- 45. Head LK, Zhang ZZ, Hicks K, Wolff G, Boyd KU.** Evaluation of intrinsic hand musculature reinnervation following supercharge end-to-side anterior interosseous-to-ulnar motor nerve transfer. *Plast Reconstr Surg* 2020;146:128–132.
- 46. Power HA, Kahn LC, Patterson MM, Yee A, Moore AM, Mackinnon SE.** Refining indications for the supercharge end-to-side anterior interosseous to ulnar motor nerve transfer in cubital tunnel syndrome. *Plast Reconstr Surg* 2020;145:106e–116e.