

# Overexpression of the PPAR- $\gamma$ protein in primary Ta/T1 non-muscle-invasive urothelial carcinoma

SHINICHI TANAKA<sup>1,2</sup>, YASUNORI TOKUHARA<sup>1</sup>, SHO HOSOKAWA<sup>3</sup>, HIROYUKI OHSAKI<sup>4</sup>, TATSUYA MORINISHI<sup>1</sup>, TAMAMI YAMAMOTO<sup>5</sup>, NORIHIRO TERAMOTO<sup>5</sup> and EIICHIRO HIRAKAWA<sup>1</sup>

<sup>1</sup>Laboratory of Pathology, Department of Medical Technology, Kagawa Prefectural University of Health Sciences, Takamatsu, Kagawa 761-0123; <sup>2</sup>Department of Medical Technology, Kawasaki University of Medical Welfare, Kurashiki, Okayama 701-0193; <sup>3</sup>Department of Medical Technology, Ehime Prefectural University of Health Sciences, Iyo, Ehime 791-2101; <sup>4</sup>Laboratory of Pathology, Department of Medical Technology, Kobe University Graduate School of Health Sciences, Kobe, Hyogo 654-0142; <sup>5</sup>Department of Clinical Laboratory, Shikoku Cancer Center, Matsuyama, Ehime 791-0280, Japan

Received June 10, 2021; Accepted October 18, 2021

DOI: 10.3892/mco.2021.2469

**Abstract.** Peroxisome proliferator-activated receptor- $\gamma$  (PPAR- $\gamma$ ) is a well-known nuclear receptor that is activated in the nucleus to regulate several transcription factors. Its expression patterns have been examined in various types of cancer. The present study investigated the expression patterns of PPAR- $\gamma$  in non-muscle-invasive urothelial carcinoma. The expression rates of PPAR- $\gamma$ , p53 and Ki-67 were compared to determine whether PPAR- $\gamma$  may be considered as an immunobiomarker for bladder cancer. The intensity and extent of PPAR- $\gamma$  expression were evaluated in 79 cases of non-muscle-invasive urothelial carcinoma (30 cases of papillary carcinoma low-grade, 30 cases of high-grade and 19 cases of carcinoma *in situ*) and 30 non-malignant cases. The nuclear overexpression of PPAR- $\gamma$  was frequently observed in non-muscle-invasive urothelial carcinoma (63/79 cases) but was rarely detected in non-malignant cases (2/30 cases). The histological proliferation types of non-muscle-invasive urothelial carcinoma revealed that PPAR- $\gamma$  was more frequently overexpressed in papillary carcinoma (54/60 cases) than in carcinoma *in situ* (9/19 cases). Immunohistochemical staining demonstrated that PPAR- $\gamma$  was more useful as an immunobiomarker than p53 or Ki-67 (diagnostic odds ratios; 55.13, 16.82 and 11.13, respectively). In summary, this study demonstrated that the expression patterns of PPAR- $\gamma$  were associated with histological proliferation type and that PPAR- $\gamma$  was expressed

in the nuclei of papillary carcinoma cells. These findings suggested that immunohistochemical staining for PPAR- $\gamma$  may be used to comprehensively detect non-muscle-invasive urothelial carcinoma.

## Introduction

Bladder cancer is the ninth most common cancer worldwide that ranks 13th for mortality rate, and ~430,000 cases of bladder cancer are reported each year (1). Smoking is the highest risk factor for bladder cancer, accounting for 50% of all cases (2). Urothelial carcinoma (UC) is a common histological type of bladder cancer that includes non-muscle-invasive UC (pathological stages Ta, T1 and Tis) and muscle-invasive UC (pathological stages T2 and higher) (3). Treatment guidelines for UC recommend the assessment of muscle invasiveness. Patients with Ta and T1 non-muscle-invasive UC undergo transurethral resection of bladder tumor (TURBT) for diagnostic and therapeutic purposes (4). Bacillus Calmette-Guerin (BCG) therapy is conducted for Tis UC, while a combination of cystectomy, chemoradiotherapy and radiation therapy is used to treat muscle-invasive UC (4). Non-muscle-invasive UC is separated into two distinct categories based on tumor growth as follows: Papillary and flat non-muscle-invasive UC. Furthermore, ~70-75% of primary UC cases are papillary carcinoma, whereas ~1-3% are the pure form of flat carcinoma. Non-muscle-invasive papillary UC can be distinguished as low grade (NMIPUC-L) and high grade (NMIPUC-H) based on architectural and cytological features (3).

Peroxisome proliferator-activated receptors (PPARs) are nuclear hormone receptors that comprise three subtypes: PPAR- $\alpha$ , PPAR- $\gamma$  and PPAR- $\delta$ . The PPAR- $\gamma$  protein has been detected in adipose tissue (5). The relationship between the expression of PPAR- $\gamma$  and colon cancer has attracted increasing attention (6-8). It was demonstrated that PPAR- $\gamma$  induces cell differentiation, arrests cell growth and reduces tumor growth rate in colon cancer. PPAR- $\gamma$  ligands are expected to become promising therapeutic agents for chemoprevention and treatment. However, previous studies on PPAR- $\gamma$  activation using

---

*Correspondence to:* Professor Eiichiro Hirakawa, Laboratory of Pathology, Department of Medical Technology, Kagawa Prefectural University of Health Sciences, 281-1 Hara, Takamatsu, Kagawa 761-0123, Japan  
E-mail: hirakawa@chs.pref.kagawa.jp

**Key words:** peroxisome proliferator-activated receptor- $\gamma$ , non-muscle-invasive urothelial carcinoma, immunohistochemical staining

several agonists have not provided consistent findings, such as the tumor suppressive or oncogenic role of PPAR- $\gamma$ , in a heterogeneous nature in bladder cancer (9,10). Furthermore, limited information is currently available on the expression of PPAR- $\gamma$  in carcinoma *in situ* (CIS), such as flat carcinoma. Therefore, the relationship between PPAR- $\gamma$  expression and the histological proliferation type in UC remains unclear. The present study aimed to investigate the expression of PPAR- $\gamma$  in non-muscle-invasive UC, including CIS, and to compare it with that in normal urinary epithelial cells to clarify whether PPAR- $\gamma$  may be used as an immunobiomarker in urothelial carcinoma.

## Materials and methods

**Subjects.** Tissue samples, including TURBT and biopsy samples, were collected from 30 non-malignant cases and 79 non-muscle-invasive UC cases (NMIPUC-L 30 cases, NMIPUC-H 30 cases, and CIS 19 cases) at the Shikoku Cancer Center between April 2013 and March 2018. Samples from patients with inflammation in the bladder urothelium or those who recovered from UC following TURBT and BCG therapy were included as non-malignant cases. A histological diagnosis was based on the World Health Organization (WHO) classification of specimens stained using hematoxylin and eosin (3). The present study was approved by the Institutional Research Ethics Committee of the Shikoku Cancer Center (Ehime, Japan) and Kagawa Prefectural University of Health Sciences (Kagawa, Japan).

**Immunohistochemical staining.** Formalin-fixed paraffin-embedded tissue samples were cut into 4- $\mu$ m-thick sections. All samples were rehydrated and deparaffinized using EZ buffer (Roche Diagnostics). Antigen masking was removed using pH 8.5 CC1 buffer (Roche Diagnostics) at 95°C for 64 min. All samples were then incubated with H<sub>2</sub>O<sub>2</sub> (Roche Diagnostics) to block endogenous peroxidase activity. Sections were incubated with primary antibody against PPAR- $\gamma$  (mouse monoclonal; Santa Cruz Biotechnology, Inc; cat. no. sc-7273; 1:200) at 36°C for 32 min. The I-VIEW DAB Universal Kit (Roche Diagnostics) was used for the secondary antibody reaction, followed by section staining with diaminobenzidine according to the manufacturer's instructions. Benchmark ULTRA (Roche Diagnostics) was used as an automatic immunostainer for immunohistochemical processes. To demonstrate the diagnostic utility of PPAR- $\gamma$  in non-muscle-invasive UC cases, staining for p53 (mouse monoclonal; Agilent Technologies, Inc.; cat. no. M7001; Ready-to-use) and Ki-67 (mouse monoclonal; Agilent Technologies, Inc.; cat. no. M7240; 1:100) was performed on the same non-muscle-invasive UC and non-malignant samples. The p53 and Ki-67 immunohistochemical protocols were the same as the PPAR- $\gamma$  immunohistochemical protocol. The expression of all immunobiomarkers was observed under a microscope (BX53; Olympus Corporation; magnification, x400) and images were taken using a microscope camera (DS-Fi3; Nikon Corporation). PPAR- $\gamma$ -stained specimens were assessed by four experienced observers as follows: Nuclear-positive type, nuclear and cytoplasmic-positive type, cytoplasmic-positive type and no signal type. In previous

studies (11,12), specimens positive for PPAR- $\gamma$  were evaluated based on the extent and staining intensity of PPAR- $\gamma$  expression. In the present study, the extent of positive staining was classified into six categories as follows: 0 ( $\leq$ 10% staining), 1 (11-25% staining), 2 (26-50% staining), 3 (51-75% staining), 4 (76-90% staining) and 5 ( $\geq$ 91% staining). The PPAR- $\gamma$  staining intensity was classified into four categories as follows: 0 (no signal), 1 (weak), 2 (moderate) and 3 (strong). The extent and intensity for nuclear and cytoplasmic PPAR- $\gamma$  expression were scored. Based on the combinations of the extent and intensity scores of PPAR- $\gamma$  staining in nuclei, a combined score  $\geq$ 4 corresponded to PPAR- $\gamma$  positive, while that  $<$ 4 corresponded to PPAR- $\gamma$  negative. Furthermore, PPAR- $\gamma$  was considered to be negative when PPAR- $\gamma$  was locally expressed in the cytoplasm or was not expressed at all. The expression of p53 was evaluated as an aberrant type when positive cells accounted for  $\geq$ 50% of tumor cells and as a wild type when positive cells accounted for  $<$ 50%. The expression of Ki-67 was determined as high or low based on published cut-offs (20% positive staining) (13,14).

**cBioPortal.** The cBioPortal for Cancer Genomics (<http://www.cbioportal.org>) is an open-access web resource for exploring and analyzing multidimensional cancer genomic data (15). The present study analyzed the genomic data of PPAR- $\gamma$  extracted from The Cancer Genome Atlas (TCGA) datasets of bladder cancer, namely 'TCGA Cell 2017' (412 cases) (16), 'TCGA, Nature 2014' (131 cases) (17) and 'TCGA, PanCancer Atlas' (411 cases) (18-26).

**Statistical analysis.** Univariate analysis was performed using  $\chi^2$  test for categorical data. Statistical analyses were conducted using JMP 15.0 software (SAS Institute, Inc.).  $P < 0.05$  was considered to indicate a statistically significant difference.

## Results

**Expression pattern of PPAR- $\gamma$  in the urinary bladder.** The following PPAR- $\gamma$  expression patterns were observed in the urinary bladder: Nuclear expression (Fig. 1A), nuclear-cytoplasmic expression (Fig. 1B), cytoplasmic expression (Fig. 1C) and no expression (Fig. 1D). The localization of PPAR- $\gamma$  protein was significantly different between non-muscle-invasive UC cases and non-malignant cases ( $P < 0.0001$ ; Table I). PPAR- $\gamma$  was mainly expressed in the nuclei of tumor cells in non-muscle-invasive UC, including NMIPUC-L (Fig. 2A), NMIPUC-H (Fig. 2B) and CIS (Fig. 2C). Conversely, PPAR- $\gamma$  was partly expressed in the cytoplasm of urinary epithelial cells in non-malignant cases (Fig. 2D). Statistical analyses demonstrated that the nuclear overexpression of PPAR- $\gamma$  was significantly higher in non-muscle-invasive UC cases compared with non-malignant cases ( $P < 0.0001$ ; Table II). The PPAR- $\gamma$ -positive expression was significantly lower in CIS cases as flat carcinoma compared with NMIPUC-L and -H as papillary carcinoma ( $P = 0.0002$ ; Table III). In addition, PPAR- $\gamma$  intensity in CIS with PPAR- $\gamma$ -positive tended to be weak (Fig. 3). The PPAR- $\gamma$ -positive expression was associated with the pathological stage ( $P = 0.0003$ ), but not with age, sex or histological grades (Table III).

Table I. Localization of PPAR- $\gamma$  expression in non-muscle-invasive urothelial carcinoma and non-malignant cases.

	Localization of PPAR- $\gamma$ expression				P-value
	Nuclear	Nuclear-cytoplasmic, complex	Cytoplasmic	No signal	
Non-muscle-invasive urothelial carcinoma cases (n=79)	46	32	1	-	<0.0001
Non-malignant cases (n=30)	1	13	15	1	

PPAR- $\gamma$ , peroxisome proliferator-activated receptor- $\gamma$ .

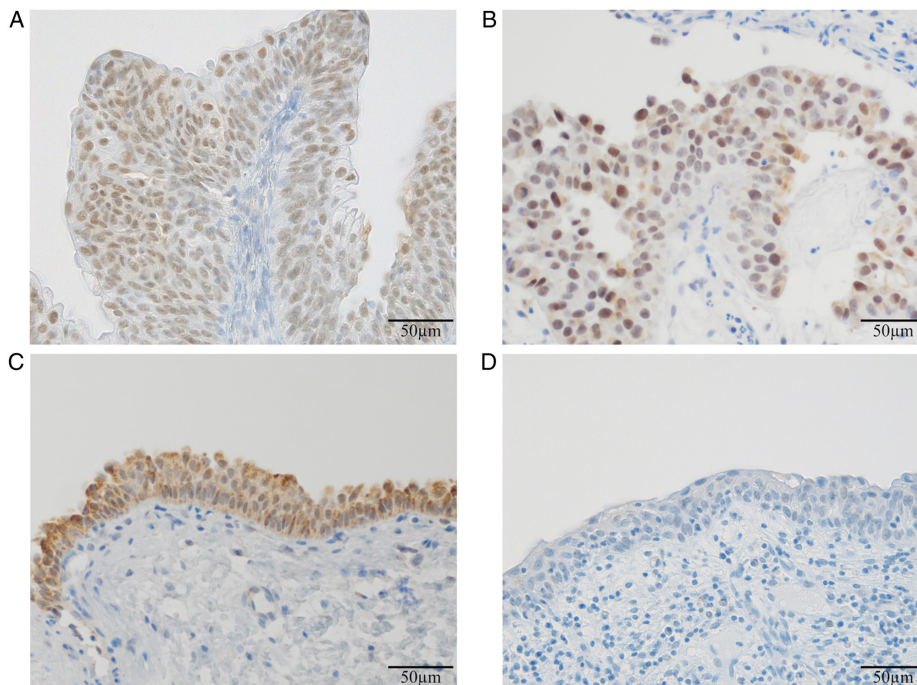


Figure 1. Localization of PPAR- $\gamma$  protein in urinary bladder tissues. (A) Nuclear expression (in non-muscle-invasive papillary urothelial carcinoma, low-grade), (B) nuclear-cytoplasmic complex expression (in non-muscle-invasive papillary urothelial carcinoma, high-grade), (C) cytoplasmic expression (in non-malignant cases) and (D) absence of expression (in non-malignant cases). Magnification, x400. Scale bar, 50  $\mu$ m. PPAR- $\gamma$ , peroxisome proliferator-activated receptor- $\gamma$ .

**Genomic alteration of PPAR- $\gamma$  in bladder cancer.** Using the TCGA datasets of bladder cancer and cBioPortal online tool to analyze PPAR- $\gamma$  gene mutations or copy number alterations, alteration rates were 16.99% (70/412 cases; TCGA, Cell 2017), 16.79% (22/131 cases; TCGA, Nature 2014) and 16.3% (67/411 cases; TCGA, PanCancer Atlas; Fig. 4). In addition, PPAR- $\gamma$  gene amplification accounted for most changes, with amplification rates of 13.59% (56/412 cases; TCGA, Cell 2017), 14.50% (19/131 cases; TCGA, Nature 2014), and 12.65% (52/411 cases; TCGA, PanCancer Atlas; Fig. 4).

**Comparison of PPAR- $\gamma$ , p53 and Ki-67 values as immunobiomarkers for non-muscle-invasive UC.** Fig. 5 shows representative immunohistochemical staining for PPAR- $\gamma$  (Fig. 5A, D, G and J), p53 (Fig. 5B, E, H and K) and Ki-67 (Fig. 5C, F, I and L). Immunohistochemical staining for PPAR- $\gamma$  showed the highest sensitivity (79.7%). The diagnostic odds ratio (DOR) was 55.13 (Table IV). The expression of these immunobiomarkers was significantly higher in non-muscle-invasive UC cases compared with

non-malignant cases. However, the PPAR- $\gamma$ -positive expression did not significantly differ among the histological grades of non-muscle-invasive papillary UC (NMIPUC-L; 86.7%, NMIPUC-H; 93.3%.  $P=0.3980$ ; Table V). Conversely, the aberrant p53 and high Ki-67 expression were significantly lower in NMIPUC-L than in NMIPUC-H. Furthermore, only the PPAR- $\gamma$  positivity clearly distinguished NMIPUC-L from non-malignant cases ( $P<0.0001$ ; Table V). Five out of 19 CIS cases were positive for PPAR- $\gamma$  or had wild-type p53, whereas 17 were positive for PPAR- $\gamma$  or had aberrant p53 (Table VI).

## Discussion

The present study demonstrated that the localization, intensity, extent and genomic alteration of PPAR- $\gamma$  expression significantly differed between non-muscle-invasive UC and non-malignant cases. The expression pattern of PPAR- $\gamma$  in CIS suggested a relationship with the histological proliferative type but not the histological grade. Furthermore, the present study evaluated the usefulness of PPAR- $\gamma$ , p53

Table II. Nuclear expression and cytoplasmic expression of PPAR- $\gamma$  in non-muscle-invasive papillary urothelial carcinoma (low and high-grades), flat carcinoma and non-malignant cases.

	PPAR- $\gamma$ expression					
	Nuclear score			Cytoplasmic score		
	$\geq 4$	$< 4$	P-value	$\geq 4$	$< 4$	P-value
Non-muscle-invasive urothelial carcinoma cases (n=79)	63	16	$< 0.0001$	6	73	0.0007
NMIPUC low-grade and high-grade cases (n=60)	54	6	$< 0.0001$	2	58	$< 0.0001$
Flat carcinoma <sup>a</sup> cases (n=19)	9	10	0.0009	4	15	0.3575
Non-malignant cases (n=30)	2	28		10	20	

<sup>a</sup>Flat carcinoma is carcinoma *in situ*. NMIPUC, non-muscle-invasive papillary urothelial carcinoma; PPAR- $\gamma$ , peroxisome proliferator-activated receptor- $\gamma$ .

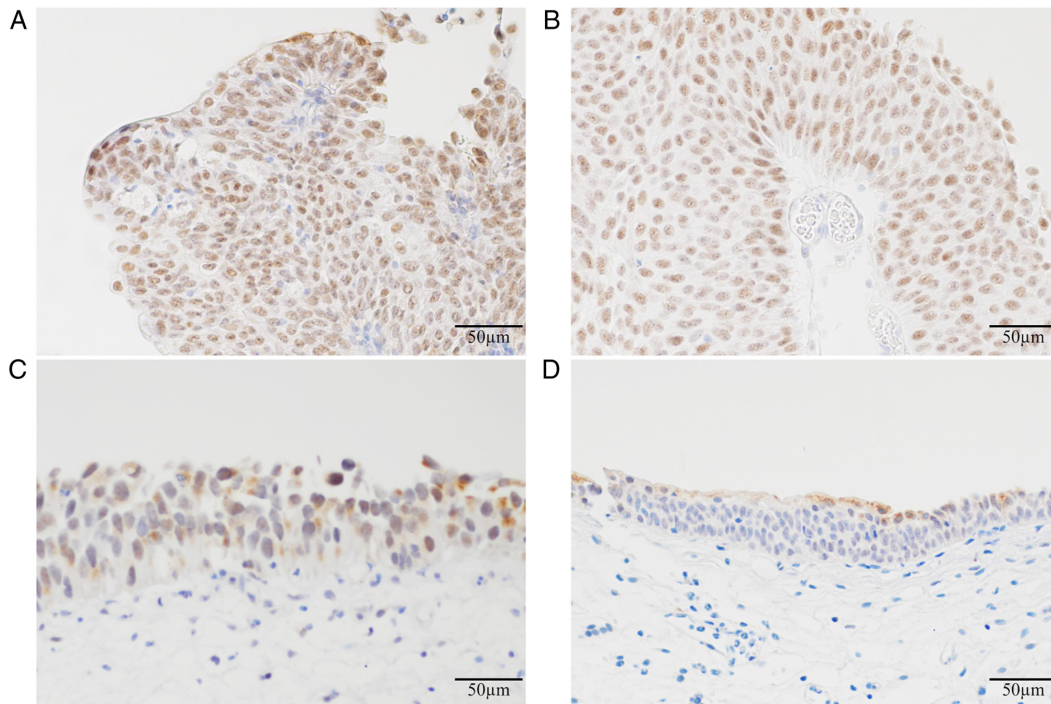


Figure 2. Representative images of the expression of PPAR- $\gamma$  in urinary bladder tissues. (A) Non-muscle-invasive papillary urothelial carcinoma (low-grade), (B) non-muscle-invasive papillary urothelial carcinoma (high-grade), (C) carcinoma *in situ* and (D) non-malignant cases. Magnification, x400. Scale bar, 50  $\mu$ m. PPAR- $\gamma$ , peroxisome proliferator-activated receptor- $\gamma$ .

and Ki-67 as immunobiomarkers. The nuclear expression of PPAR- $\gamma$  was significantly higher in non-muscle-invasive UC compared with non-malignant cases. In addition, PPAR- $\gamma$  was more efficient for the detection of non-muscle-invasive UC than p53 and Ki-67. These results provided evidence for the potential role of PPAR- $\gamma$  as an immunobiomarker in non-muscle-invasive UC.

In the present study, PPAR- $\gamma$  showed different expression patterns in non-muscle-invasive UC and non-malignant cases. We considered PPAR- $\gamma$  protein as being overexpressed in nuclei of urinary bladder tissues with malignant transformation. A previous study reported the nuclear PPAR- $\gamma$  positive staining in colorectal tissues regardless of whether the tissue was malignant or not (27). In ovarian tumors, Zhang *et al* (11)

reported a significant difference in the expression of PPAR- $\gamma$  between the normal epithelium and malignant tumors and demonstrated that PPAR- $\gamma$  was overexpressed in nuclei along with disease progression. In the present study, tumor cells of NMIPUC cases showed moderate cytoplasmic expression and high nuclear expression. The cytoplasmic expression of PPAR- $\gamma$  was inversely associated with nuclear expression, with that in non-malignant cases being significantly higher than that in non-muscle-invasive UC. These results indicated that PPAR- $\gamma$  was overexpressed in nuclei with malignant transformation. These differences in the expression patterns of PPAR- $\gamma$  between normal urinary epithelial cells and tumor cells reflected the malignant transformation. PPAR- $\gamma$  is a nuclear receptor that is activated in the nucleus to regulate

Table III. Association between patient clinicopathological characteristics and the nuclear expression of PPAR- $\gamma$  in non-muscle-invasive urothelial carcinoma.

	Cases no.	PPAR- $\gamma$ expression		P-value
		Positive	Negative	
Mean age $\pm$ standard deviation, years		74.0 $\pm$ 8.11	70.9 $\pm$ 8.33	0.3926
Sex				
Male	63	50	13	0.866
Female	16	13	3	
Histological grade				
Non-muscle-invasive urothelial carcinoma, low-grade	30	26	4	0.2204
Non-muscle-invasive urothelial carcinoma, high-grade <sup>a</sup>	49	37	12	
Histological proliferation type				
Papillary carcinoma <sup>b</sup>	60	54	6	0.0002
Flat carcinoma <sup>c</sup>	19	9	10	
Pathological stage				
Tis	19	9	10	0.0003
Ta	45	41	4	0.619
T1	15	13	2	

<sup>a</sup>High-grade includes the non-muscle-invasive papillary urothelial carcinoma, high-grade (n=30) and carcinoma *in situ* (n=19). <sup>b</sup>Papillary carcinoma includes the non-muscle-invasive papillary urothelial carcinoma, low-grade (n=30) and high-grade (n=30). <sup>c</sup>Flat carcinoma is carcinoma *in situ*. PPAR- $\gamma$ , peroxisome proliferator-activated receptor- $\gamma$ .

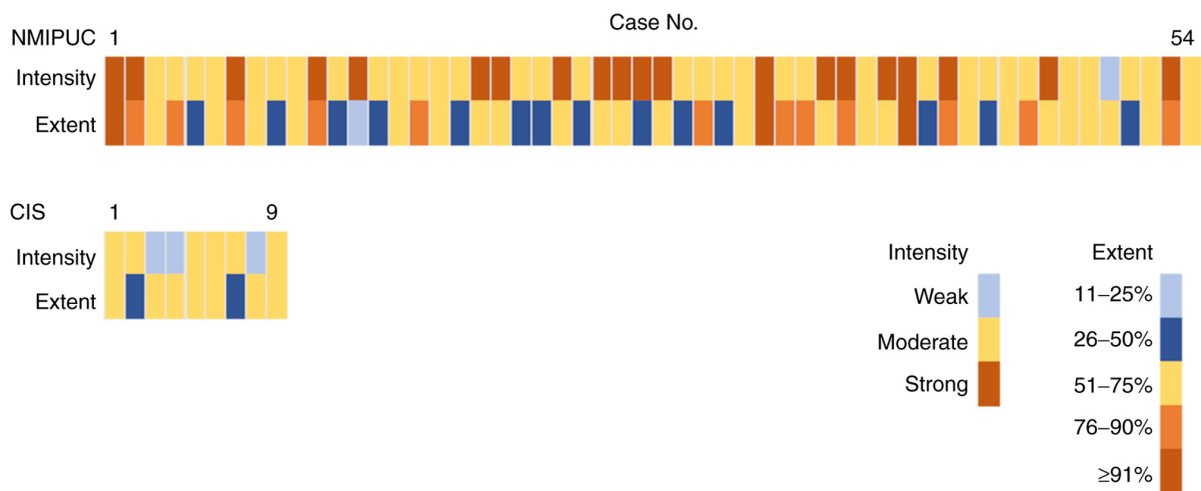

Figure 3. Intensity and extent of PPAR- $\gamma$  immunohistochemical staining in non-muscle-invasive papillary urothelial carcinoma and carcinoma *in situ* with positivity for PPAR- $\gamma$ . NMIPUC, non-muscle-invasive papillary urothelial carcinoma; CIS, carcinoma *in situ*; PPAR- $\gamma$ , peroxisome proliferator-activated receptor- $\gamma$ .

several transcription factors. PPAR- $\gamma$  ligands induce apoptosis in various carcinomas (28,29). In colon cancer, the PPAR- $\gamma$  ligand 15-deoxy- $\Delta$ 12,14-prostaglandin J<sub>2</sub> (15d-PGJ<sub>2</sub>) was shown to inhibit the activity of nuclear factor- $\kappa$ B (NF- $\kappa$ B) and reduce the expression of the Bcl-2 protein, ultimately leading to apoptosis (30-32). Furthermore, 15d-PGJ<sub>2</sub>, which is one of the natural ligands for PPAR- $\gamma$ , can inhibit the growth of neoplastic urothelial cells (33). Bcl-2 and its transcription factor, NF- $\kappa$ B, have been suggested to inhibit tumor proliferation in UC by activating PPAR- $\gamma$ . Previous studies demonstrated that PPAR- $\gamma$  activation can arrest the cell cycle; however, most of the study

materials examined were muscle-invasive UC (9,34). The relationships between the expression of PPAR- $\gamma$ , apoptosis, cell cycle and malignant transformation remain controversial. Further investigation is therefore required to elucidate the PPAR- $\gamma$  pathway in UC.

It is widely known that abnormal gene expression differs with the histological proliferation type in bladder cancer (35,36). According to the results from gene expression analysis using cBioPortal, PPAR- $\gamma$  gene alterations were associated with bladder cancer. However, the histological proliferation type has not yet been examined using a PPAR- $\gamma$

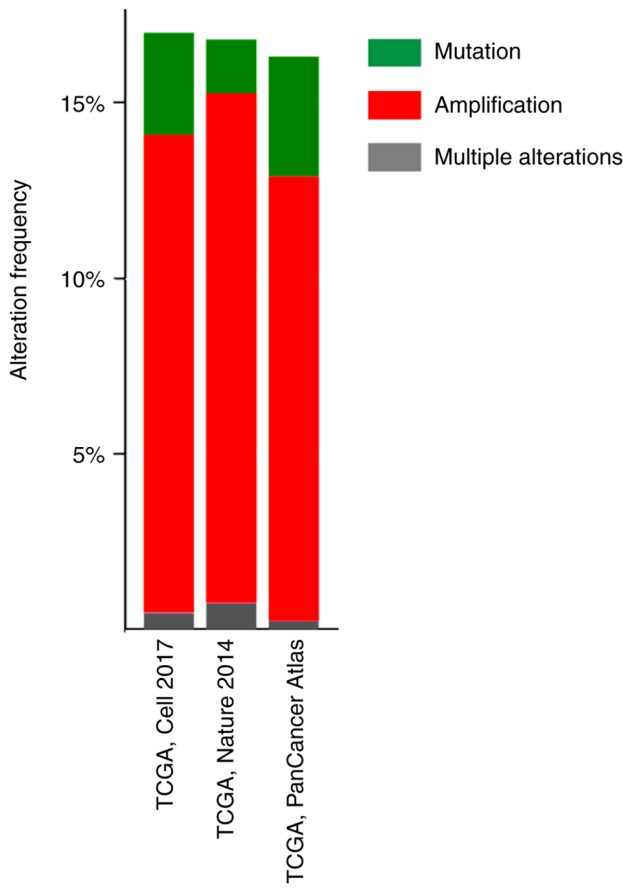


Figure 4. Genetic alteration analysis of peroxisome proliferator-activated receptor- $\gamma$  in patients with bladder cancer using cBioPortal. TCGA, The Cancer Genome Atlas.

expression assay. Regarding the relationship between PPAR- $\gamma$  expression and cancer histological grades, Mylona *et al* (37) and Nakashiro *et al* (33) indicated that the nuclear expression of PPAR- $\gamma$  was inversely correlated with histological grades in UC. However, as presented in Table III, a relationship was not observed between the nuclear overexpression of PPAR- $\gamma$  in non-muscle-invasive UC and histological grades. Histological grades are diagnosed from morphology based on architectural and cytological features. Furthermore, the WHO classification defines low-grade UC as papillary carcinoma, whereas high-grade UC includes papillary, flat and infiltrating types. Since flat carcinoma was not sufficiently examined in previous studies, the relationship between PPAR- $\gamma$  and histological proliferation types was not investigated in detail. The results from the present demonstrated that PPAR- $\gamma$  expression significantly differed among pathological stages. CIS corresponded to Tis pathological stage while papillary carcinoma corresponded to Ta or T1 pathological stages. Therefore, the results from statistical analyses appeared to be dependent on the histological proliferation type and not on the pathological stage. Statistical analyses of PPAR- $\gamma$  expression in Ta and T1 did not reveal any significant differences. Regarding the PPAR- $\gamma$  expression in muscle-invasive UC, a previous study reported that PPAR- $\gamma$  expression levels are lower in muscle-invasive UC cases than in non-muscle-invasive UC cases (37). This finding supports our results showing that PPAR- $\gamma$  expression might be associated with the proliferation type.

Table IV. Comparisons of detection accuracy for PPAR- $\gamma$ , p53 and Ki-67 immunobiomarkers.

	Non-muscle-invasive urothelial carcinoma (n=79) (%)		Non-malignant (n=30) (%)	P-value	Sensitivity, %	Specificity, %	PPV, %	NPV, %	DOR, 95%CI
PPAR- $\gamma$									
Positive, n (%)	63 (79.7)		2 (6.7)	<0.0001	79.7	93.3	96.9	63.6	55.13, 11.866-256.091
Negative, n (%)	16 (20.3)		28 (93.3)						
p53									
Aberrant, n (%)	29 (36.7)		1 (3.3)	0.0005	36.7	96.7	96.7	36.7	16.82, 2.175-130.047
Wild, n (%)	50 (63.3)		29 (96.7)						
Ki-67									
High, n (%)	35 (44.3)		2 (6.7)	0.0002	44.3	93.3	94.6	38.9	11.13, 2.481-49.994
Low, n (%)	44 (55.7)		28 (93.3)						

PPAR- $\gamma$ , peroxisome proliferator-activated receptor- $\gamma$ ; PPV, positive predictive value; NPV, negative predictive value; DOR, diagnostic odds ratio; CI, confidence interval.

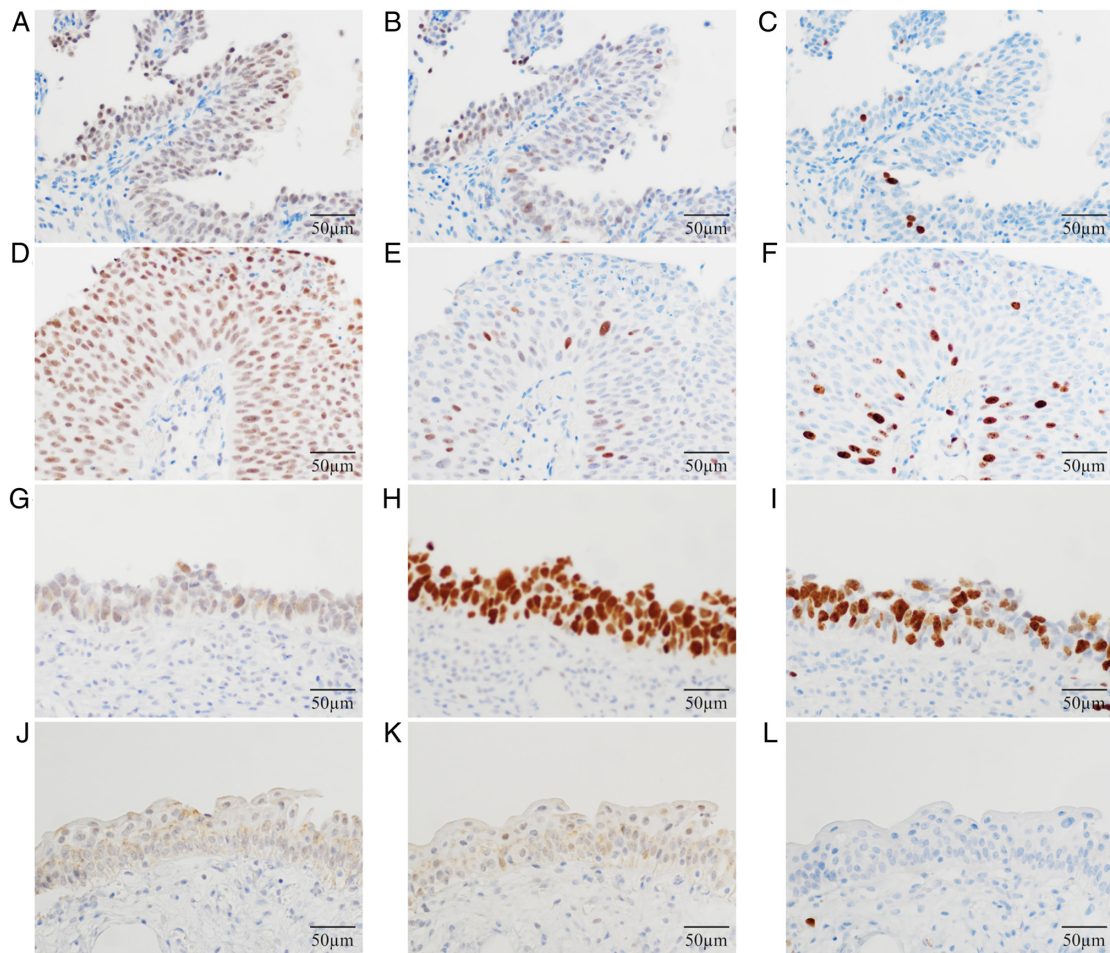


Figure 5. Representative immunohistochemical staining for PPAR- $\gamma$ , p53 and Ki-67. Immunohistochemical staining showing (A) PPAR- $\gamma$ , (B) p53 and (C) Ki-67 in non-muscle-invasive papillary urothelial carcinoma (low-grade), (D) PPAR- $\gamma$ , (E) p53 and (F) Ki-67 in non-muscle-invasive papillary urothelial carcinoma (high-grade), (G) PPAR- $\gamma$ , (H) p53 and (I) Ki-67 in carcinoma *in situ*, and (J) PPAR- $\gamma$ , (K) p53 and (L) Ki-67 in non-malignant cases. Magnification,  $\times 400$ . Scale bar, 50  $\mu\text{m}$ . PPAR- $\gamma$ , peroxisome proliferator-activated receptor- $\gamma$ .

An immunohistochemical method to detect UC has not yet been established. Previous studies reported a relationship between UC and certain immunobiomarkers, such as p53, a tumor suppressor protein, and Ki-67, a cell proliferation marker. However, the sensitivity of p53 as an immunobiomarker was 26-59%, while that of Ki-67 was 16-58% for non-invasive papillary UC, including low and high grades, with the former grade not being detected by these immunobiomarkers (38-42). The sensitivities of p53 and Ki-67 in the present study were consistent with previous findings; however, the sensitivity and DOR of p53 and Ki-67 were dependent on the low frequency of the aberrant type/high expression in NMIPUC-L. Therefore, PPAR- $\gamma$  as an immunobiomarker may be useful for detecting non-muscle-invasive UC despite the histological grade. In the present study, p53 showed the highest sensitivity as an immunobiomarker for CIS (63.2%, 12/19). The aberrant type of p53 has been widely investigated and used as an immunobiomarker to detect CIS (43). Based on the data shown in the present study, we considered CIS to have been comprehensively detected using a combination of PPAR- $\gamma$  and p53 as immunobiomarkers rather than using p53 alone.

A limitation of the present study was that the molecular biological analysis did not include muscle-invasive UC cases or UC cell lines. Therefore, an association was not

observed between UC invasiveness and PPAR- $\gamma$  expression. In addition, we did not obtain clinical data on recurrence because of the limited number of PPAR- $\gamma$ -negative cases in UC presenting with recurrence following TURBT. However, non-muscle-invasive UC frequently relapses, and we speculated that PPAR- $\gamma$  may serve an important role in this process. Although further investigation is required, we herein attempted to clarify the usefulness of PPAR- $\gamma$  as an immunobiomarker in samples from patients with non-muscle-invasive UC.

A routine and less invasive method to detect UC is urinary cytology; however, it has not yet been established as a useful screening method for UC due to its low sensitivity. Meuleman and Delaere (44) reported that the diagnostic findings of urinary cytology were subject to UC differentiation level and infiltrating stage. In cytological samples, difficulties are associated with distinguishing NMIPUC-L from normal urinary epithelial cells based on a morphological diagnosis under a microscope because morphologically, NMIPUC-L negligibly exhibits nuclear atypia and pleomorphism (45,46). According to NCCN Clinical Practice Guidelines in Oncology (4), ~70-75% of primary UC cases are NMIPUC-L or NMIPUC-H. Therefore, NMIPUC-L and NMIPUC-H are frequently encountered in urinary cytology but are not

Table V. Relationships between PPAR- $\gamma$ , p53 and Ki-67 immunohistochemical staining and non-muscle-invasive urothelial carcinoma and non-malignant cases.

	PPAR- $\gamma$ expression		p53 expression		Ki-67 expression		Histological grade, P-value
	Positive (%)	vs. non-malignant, P-value	Aberrant (%)	vs. non-malignant, P-value	High (%)	vs. non-malignant, P-value	
NMIPUC							
Low grade, n=30 (%)	26 (86.7)	<0.0001	5 (16.7)	0.085	4 (13.3)	0.3894	<0.0001
High grade, n=30 (%)	28 (93.3)	<0.0001	12 (40)	0.0006	21 (70)	<0.0001	
CIS, n=19 (%)	9 (47.4)	0.0009	12 (63.2)	<0.0001	10 (52.6)	0.0003	
Non-malignant, n=30 (%)	2 (6.7)		1 (3.3)		2 (6.7)		

PPAR- $\gamma$ , peroxisome proliferator-activated receptor- $\gamma$ ; NMIPUC, non-muscle-invasive papillary urothelial carcinoma; CIS, carcinoma *in situ*.

Table VI. Staining results for each immunobiomarker in carcinoma *in situ* cases.

Case no.	PPAR- $\gamma$ expression	p53 expression	Ki-67 expression
1	-	Aberrant	High
2	-	Aberrant	High
3	Positive	Aberrant	High
4	-	Aberrant	-
5	Positive	Aberrant	High
6	-	Aberrant	High
7	-	Aberrant	High
8	-	-	-
9	Positive	-	-
10	Positive	-	-
11	-	Aberrant	High
12	-	Aberrant	High
13	Positive	Aberrant	-
14	Positive	-	-
15	Positive	Aberrant	High
16	Positive	-	-
17	-	Aberrant	High
18	Positive	-	-
19	-	-	-

PPAR- $\gamma$ , peroxisome proliferator-activated receptor- $\gamma$ .

accurately diagnosed. The results from the present study demonstrated that PPAR- $\gamma$  immunohistochemical staining could detect more cancer cells than other immunobiomarkers for NMIPUC-L and NMIPUC-H. An ancillary diagnostic test using PPAR- $\gamma$  immunocytochemical staining may effectively increase the accuracy of urinary cytology.

In summary, the present study demonstrated that expression patterns of PPAR- $\gamma$  were associated with histological proliferation type and that PPAR- $\gamma$  was expressed in the nuclei of papillary carcinoma cells. Immunohistochemical staining for PPAR- $\gamma$  appeared to be more useful as an immunobiomarker for non-muscle-invasive UC than the other biomarkers examined. Although further investigation is needed, this study suggested that PPAR- $\gamma$  immunobiomarker may be considered as a promising tool for UC early detection.

### Acknowledgements

Not applicable.

### Funding

No funding was received.

### Availability of data and materials

The datasets used during the present study are available from the corresponding author upon reasonable request.



## Authors' contributions

ST, YT and EH designed the study. ST, YT, SH, HO, TM, TY and NT performed the experiments. ST, YT, SH and EH analyzed all data. ST and YT wrote the manuscript. HO, NT and EH confirm the authenticity of all raw data. All authors read and approved the final manuscript.

## Ethics approval and consent to participate

The present study was performed in accordance with the Declaration of Helsinki and was approved by the Ethics Committee of the Shikoku Cancer Center (Ehime, Japan; approval no. 2018-95) and Kagawa Prefectural University of Health Sciences (Kagawa, Japan; approval no. 291). In this retrospective study, the Institutional Review Board previously granted a waiver for written informed consent by publishing information on the study on the Home Page and providing the option to opt-out.

## Patient consent for publication

Not applicable.

## Competing interest

The authors declare that they have no competing interests.

## References

- Antoni S, Ferlay J, Soerjomataram I, Znaor A, Jemal A and Bray F: Bladder cancer incidence and mortality: A global overview and recent trends. *Eur Urol* 71: 96-108, 2017.
- Cumberbatch MG, Rota M, Catto JW and La Vecchia C: The role of tobacco smoke in bladder and kidney carcinogenesis: A comparison of exposures and meta-analysis of incidence and mortality risks. *Eur Urol* 70: 458-466, 2016.
- Humphrey PA, Moch H, Cubilla AL, Ulbright TM and Reuter VE: The 2016 WHO classification of tumours of the urinary system and male genital organs-part B: Prostate and bladder tumours. *Eur Urol* 70: 106-119, 2016.
- Flaig TW, Spiess PE, Agarwal N, Bangs R, Boorjian SA, Buyyounouski MK, Chang S, Downs TM, Efstathiou JA, Friedlander T, *et al*: Bladder cancer, version 3.2020, NCCN clinical practice guidelines in oncology. *J Natl Compr Canc Netw* 18: 329-354, 2020.
- Braissant O, Fougelle F, Scotto C, Dauça M and Wahli W: Differential expression of peroxisome proliferator-activated receptors (PPARs): tissue distribution of PPAR- $\alpha$ , - $\beta$ , and - $\gamma$  in the adult rat. *Endocrinology* 137: 354-366, 1996.
- Sarraf P, Mueller E, Jones D, King FJ, DeAngelo DJ, Partridge JB, Holden SA, Chen LB, Singer S, Fletcher C and Spiegelman BM: Differentiation and reversal of malignant changes in colon cancer through PPAR $\gamma$ . *Nat Med* 4: 1046-1052, 1998.
- Theocharis S, Giaginis C, Parasi A, Margeli A, Kakisis J, Agapitos E and Kouraklis G: Expression of peroxisome proliferator-activated receptor- $\gamma$  in colon cancer: Correlation with histopathological parameters, cell cycle-related molecules, and patients' survival. *Dig Dis Sci* 52: 2305-2311, 2007.
- Tsukahara T, Haniu H and Matsuda Y: PTB-associated splicing factor (PSF) is a PPAR $\gamma$ -binding protein and growth regulator of colon cancer cells. *PLoS One* 8: e58749, 2013.
- Lv S, Wang W, Wang H, Zhu Y and Lei C: PPAR $\gamma$  activation serves as therapeutic strategy against bladder cancer via inhibiting PI3K-Akt signaling pathway. *BMC Cancer* 19: 204, 2019.
- Dong F, Chen L, Wang R, Yang W, Lu T and Zhang Y: 4-nitrophenol exposure in T24 human bladder cancer cells promotes proliferation, motilities, and epithelial-to-mesenchymal transition. *Environ Mol Mutagen* 61: 316-328, 2020.
- Zhang GY, Ahmed N, Riley C, Oliva K, Barker G, Quinn MA and Rice GE: Enhanced expression of peroxisome proliferator-activated receptor gamma in epithelial ovarian carcinoma. *Br J Cancer* 92: 113-119, 2005.
- Armes JE, Trute L, White D, Southey MC, Hammet F, Tesoriero A, Hutchins AM, Dite GS, McCredie MR, Giles GG, *et al*: Distinct molecular pathogenesis of early-onset breast cancers in BRCA1 and BRCA2 mutation carriers: A population-based study. *Cancer Res* 59: 2011-2017, 1999.
- Koyama Y, Morikawa T, Miyakawa J, Miyama Y, Nakagawa T, Homma Y and Fukayama M: Diagnostic utility of Ki-67 immunohistochemistry in small endoscopic biopsies of the ureter and renal pelvis. *Pathol Res Pract* 213: 737-741, 2017.
- Krabbe LM, Bagrodia A, Lotan Y, Gayed BA, Darwish OM, Youssef RF, John G, Harrow B, Jacobs C, Gaitonde M, *et al*: Prospective analysis of Ki-67 as an independent predictor of oncologic outcomes in patients with high grade upper tract urothelial carcinoma. *J Urol* 191: 28-34, 2014.
- Cerami E, Gao J, Dogrusoz U, Gross BE, Sumer SO, Aksoy BA, Jacobsen A, Byrne CJ, Heuer ML, Larsson E, *et al*: The cBio cancer genomics portal: An open platform for exploring multidimensional cancer genomics data. *Cancer Discov* 2: 401-404, 2012.
- Robertson AG, Kim J, Al-Ahmadie H, Bellmunt J, Guo G, Cherniack AD, Hinoue T, Laird PW, Hoadley KA, Akbani R, *et al*: Comprehensive molecular characterization of muscle-invasive bladder cancer. *Cell* 171: 540-556.e25, 2017.
- Cancer Genome Atlas Research Network: Comprehensive molecular characterization of urothelial bladder carcinoma. *Nature* 507: 315-322, 2014.
- Hoadley KA, Yau C, Hinoue T, Wolf DM, Lazar AJ, Drill E, Shen R, Taylor AM, Cherniack AD, Thorsson V, *et al*: Cell-of-origin patterns dominate the molecular classification of 10,000 tumors from 33 types of cancer. *Cell* 173: 291-304, 2018.
- Ellrott K, Bailey MH, Saksena G, Covington KR, Kandath C, Stewart C, Hess J, Ma S, Chiotti KE, McLellan M, *et al*: Scalable open science approach for mutation calling of tumor exomes using multiple genomic pipelines. *Cell Syst* 6: 271-281.e7, 2018.
- Taylor AM, Shih J, Ha G, Gao GF, Zhang X, Berger AC, Schumacher SE, Wang C, Hu H, Liu J, *et al*: Genomic and functional approaches to understanding cancer aneuploidy. *Cancer Cell* 33: 676-689.e3, 2018.
- Liu J, Lichtenberg T, Hoadley KA, Poisson LM, Lazar AJ, Cherniack AD, Kovatich AJ, Benz CC, Levine DA, Lee AV, *et al*: An integrated TCGA Pan-cancer clinical data resource to drive high-quality survival outcome analytics. *Cell* 173: 400-416.e11, 2018.
- Sanchez-Vega F, Mina M, Armenia J, Chatila WK, Luna A, La KC, Dimitriadou S, Liu DL, Kantheti HS, Saghafinia S, *et al*: Oncogenic signaling pathways in the cancer genome atlas. *Cell* 173: 321-337.e10, 2018.
- Gao Q, Liang WW, Foltz SM, Mutharasu G, Jayasinghe RG, Cao S, Liao WW, Reynolds SM, Wyczalkowski MA, Yao L, *et al*: Driver fusions and their implications in the development and treatment of human cancers. *Cell Rep* 23: 227-238.e3, 2018.
- Poore GD, Kopylova E, Zhu Q, Carpenter C, Fraraccio S, Wandro S, Kosciolk T, Janssen S, Metcalf J, Song SJ, *et al*: Microbiome analyses of blood and tissues suggest cancer diagnostic approach. *Nature* 579: 567-574, 2020.
- Ding L, Bailey MH, Porta-Pardo E, Thorsson V, Colaprico A, Bertrand D, Gibbs DL, Weerasinghe A, Huang KL, Tokheim C, *et al*: Perspective on oncogenic processes at the end of the beginning of cancer genomics. *Cell* 173: 305-320.e10, 2018.
- Bonneville R, Krook MA, Kautto EA, Miya J, Wing MR, Chen HZ, Reeser JW, Yu L and Roychowdhury S: Landscape of microsatellite instability across 39 cancer types. *JCO Precis Oncol*: Oct 3, 2017 (Epub ahead of print). doi: 10.1200/PO.17.00073.
- Yun SH, Roh MS, Jeong JS and Park JI: Peroxisome proliferator-activated receptor  $\gamma$  coactivator-1 $\alpha$  is a predictor of lymph node metastasis and poor prognosis in human colorectal cancer. *Ann Diagn Pathol* 33: 11-16, 2018.
- Michael MS, Badr MZ and Badawi AF: Inhibition of cyclooxygenase-2 and activation of peroxisome proliferator-activated receptor- $\gamma$  synergistically induces apoptosis and inhibits growth of human breast cancer cells. *Int J Mol Med* 11: 733-736, 2003.
- Tsubouchi Y, Sano H, Kawahito Y, Mukai S, Yamada R, Kohno M, Inoue K, Hla T and Kondo M: Inhibition of human lung cancer cell growth by the peroxisome proliferator-activated receptor- $\gamma$  agonists through induction of apoptosis. *Biochem Biophys Res Commun* 270: 400-405, 2000.

30. Grimm S, Bauer MK, Baeuerle PA and Schulze-Osthoff K: Bcl-2 down-regulates the activity of transcription factor NF-kappaB induced upon apoptosis. *J Cell Biol* 134: 13-23, 1996.
31. Chen GG, Lee JF, Wang SH, Chan UP, Ip PC and Lau WY: Apoptosis induced by activation of peroxisome-proliferator activated receptor-gamma is associated with Bcl-2 and NF-kappaB in human colon cancer. *Life Sci* 70: 2631-2646, 2002.
32. Catz SD and Johnson JL: Transcriptional regulation of bcl-2 by nuclear factor kappa B and its significance in prostate cancer. *Oncogene* 20: 7342-7351, 2001.
33. Nakashiro KI, Hayashi Y, Kita A, Tamatani T, Chlenski A, Usuda N, Hattori K, Reddy JK and Oyasu R: Role of peroxisome proliferator-activated receptor gamma and its ligands in non-neoplastic and neoplastic human urothelial cells. *Am J Pathol* 159: 591-597, 2001.
34. Wang G, Cao R, Wang Y, Qian G, Dan HC, Jiang W, Ju L, Wu M, Xiao Y and Wang X: Simvastatin induces cell cycle arrest and inhibits proliferation of bladder cancer cells via PPAR $\gamma$  signaling pathway. *Sci Rep* 6: 35783, 2016.
35. Castillo-Martin M, Domingo-Domenech J, Karni-Schmidt O, Matos T and Cordon-Cardo C: Molecular pathways of urothelial development and bladder tumorigenesis. *Urol Oncol* 28: 401-408, 2010.
36. Spruck CH III, Ohneseit PF, Gonzalez-Zulueta M, Esrig D, Miyao N, Tsai YC, Lerner SP, Schmitt C, Yang AS, Cote R, *et al*: Two molecular pathways to transitional cell carcinoma of the bladder. *Cancer Res* 54: 784-788, 1994.
37. Mylona E, Giannopoulou I, Diamantopoulou K, Bakarakos P, Nomikos A, Zervas A and Nakopoulou L: Peroxisome proliferator-activated receptor gamma expression in urothelial carcinomas of the bladder: Association with differentiation, proliferation and clinical outcome. *Eur J Surg Oncol* 35: 197-201, 2009.
38. Kim M, Ro JY, Amin MB, de Peralta-Venturina M, Kwon GY, Park YW and Cho YM: Urothelial eddies in papillary urothelial neoplasms: A distinct morphologic pattern with low risk for progression. *Int J Clin Exp Pathol* 6: 1458-1466, 2013.
39. Shim JW, Cho KS, Choi YD, Park YW, Lee DW, Han WS, Shim SI, Kim HJ and Cho NH: Diagnostic algorithm for papillary urothelial tumors in the urinary bladder. *Virchows Arch* 452: 353-362, 2008.
40. Goussia AC, Papoudou-Bai A, Charchanti A, Kitsoulis P, Kanavaros P, Kalef-Ezra J, Stefanou D and Agnantis NJ: Alterations of p53 and Rb pathways are associated with high proliferation in bladder urothelial carcinomas. *Anticancer Res* 38: 3985-3988, 2018.
41. Quintero A, Alvarez-Kindelan J, Luque RJ, Gonzalez-Campora R, Requena MJ, Montironi R and Lopez-Beltran A: Ki-67 MIB1 labelling index and the prognosis of primary TaT1 urothelial cell carcinoma of the bladder. *J Clin Pathol* 59: 83-88, 2006.
42. Ogata DC, Marcondes CA, Tuon FF, Busato WF Jr, Cavalli G and Czezko LE: Superficial papillary urothelial neoplasms of the bladder (PTA E PT1): Correlation of expression of P53, KI-67 and CK20 with histologic grade, recurrence and tumor progression. *Rev Col Bras Cir* 39: 394-400, 2012 (In English, Portuguese).
43. Sato M, Yanai H, Morito T, Oda W, Shin-no Y, Yamadori I, Tshushima T and Yoshino T: Association between the expression pattern of p16, pRb and p53 and the response to intravesical bacillus Calmette-Guerin therapy in patients with urothelial carcinoma in situ of the urinary bladder. *Pathol Int* 61: 456-460, 2011.
44. Meuleman EJ and Delaere KP: Diagnostic efficacy of the combination of urine cytology, urine analysis and history in the follow-up of bladder carcinoma. *Br J Urol* 62: 150-153, 1988.
45. Wiener HG, Mian C, Haitel A, Pycha A, Schatzl G and Marberger M: Can urine bound diagnostic tests replace cystoscopy in the management of bladder cancer? *J Urol* 159: 1876-1880, 1998.
46. Yamashiro K, Taira K, Nakajima M, Azuma M, Koseki M, Abe T, Suzuki H, Minami K, Harabayashi T and Nagamori S: Voided urine cytology and low-grade urothelial neoplasia of the bladder: Factors that influence the sensitivity. *J Am Soc Cytopathol* 5: 227-234, 2016.



This work is licensed under a Creative Commons Attribution-NonCommercial-NoDerivatives 4.0 International (CC BY-NC-ND 4.0) License.