

Iatrogenic Hepatic Portal Venous Gas in a Patient With Crohn's Disease After Colonoscopy

Ateeq Mubarik, MD¹, Salaah Siddiqui, DO¹, Arshad Muhammad Iqbal, MD¹, Sohaib Khaleel Mohammed, MD², Salman Muddassir, MD¹, Abdulmagid Eddib, MD¹, and Ihab Herraka, MD³

¹Department of Internal Medicine, Oak Hill Hospital, Brooksville, FL

²University of Louisville School of Medicine, Louisville, KY

³Access Healthcare Gastroenterology, Oak Hill Hospital, Brooksville, FL

ABSTRACT

Hepatic portal venous gas is a radiologic sign and is associated with several abdominal disorders. The prognosis and survival of the patient depends on the underlying etiology. Most cases respond to broad-spectrum antibiotics, but some may need surgical intervention. We report a case of hepatic portal venous gas after colonoscopy in a patient with Crohn's disease.

INTRODUCTION

Hepatic portal venous gas (HPVG) is a radiologic sign that indicates the accumulation of gas in the portal vein and its branches. Originally described as a finding seen in infants with necrotizing enterocolitis, HPVG has been associated with several underlying abdominal disorders varying from benign to potentially lethal diseases requiring emergent surgical intervention.^{1,2} We report a case involving one such association of iatrogenic HPVG in a patient with Crohn's disease after a colonoscopy.

CASE REPORT

A 38-year-old woman presented to the hospital with progressive right lower quadrant abdominal pain and diarrhea of 1 month duration. Physical examination revealed normoactive bowel sound and soft abdomen with generalized abdominal tenderness and guarding present in the right lower quadrant of her abdomen. Her vitals and initial laboratory work revealed no abnormalities. Her medical history up until this point was nonsignificant, aside from anxiety.

An emergent computed tomography (CT) abdomen/pelvis with contrast showed phlegmon formation within the deep central portion of the pelvis, suggestive of a perforated appendix vs underlying inflammatory bowel disease. The patient was evaluated by general surgery, and no intervention was done because based on the patient's presentation, there was not a concern for a perforated appendix. A gastroenterologist was consulted, and a colonoscopy was performed, showing sporadic deep and superficial ulcerations, ileal stenosis, ileitis, and diffuse mucosal inflammation. No evidence of fistulization was noted.

After the colonoscopy, the patient was started on empiric antibiotics, ciprofloxacin, and metronidazole. The patient completed a full course of antibiotics and returned to the gastroenterology clinic 2 weeks later, complaining of continued mild abdominal pain and tenderness. A CT enterography obtained to monitor for interval changes after antibiotic treatment showed persistent distal ileitis and new air densities within the hepatic portal venous system (Figure 1). Endoscopic biopsy returned showing chronic active inflammation consistent with the diagnosis of Crohn's disease. Further testing in the form of inflammatory bowel disease serology panel was positive for Crohn's disease. She was then started on adalimumab with a diagnosis at hand. A third CT scan was obtained after improvement of symptoms 90 days later. Subsequent CT revealed clear improvement in the ileal wall thickening and complete resolution of HPVG.

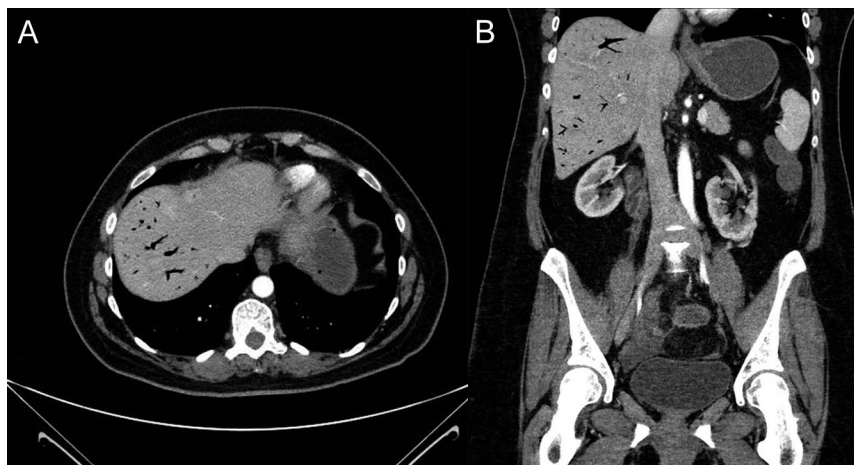


Figure 1. (A) Transverse and (B) coronal computed tomography enterography showing portal venous gas within the liver.

DISCUSSION

HPVG has been described in the literature as gas embolization of the portal venous circulation.³ HPVG is commonly associated with bowel necrosis (72%), ulcerative colitis (8%), intra-abdominal abscess (6%), small bowel obstruction (3%), and gastric ulcers (3%).³ As depicted in the case, we are presenting HPVG as a rare but a well-known complication of Crohn's disease. Approximately 58% of cases of HPVG associated with Crohn's disease are iatrogenic due to colonoscopy, barium enema study, or blunt abdominal trauma.^{4,5}

The exact mechanism of gas appearance in the portal vein is not well understood. The proposed predisposing factors for the accumulation of gas could be the escape of gas produced by organisms in the bowel lumen, abscess, or the presence of gas-forming organisms in the portal venous system.³ HPVG in patients with underlying inflammatory bowel disease can be caused by mucosal damage alone. This loss of mucosal wall integrity can allow gas penetration into the venous portal system.^{6,7}

Several imaging modalities have been used to detect HPVG such as plain abdominal radiography, color Doppler flow imaging, sonography, and CT scan.⁸ On abdominal plain film, a branching radiolucency extending to within 2 cm beneath the liver capsule can be seen. Although HPVG may be diagnosed by conventional radiography, detection is difficult and often easily overlooked.⁹ Color Doppler flow imaging, sonography, and CT scan have been reported to be superior to abdominal radiographs for HPVG. Doppler coupled with sonography is very sensitive for HPVG detection and can be useful as an initial screening examination.^{10,11} On ultrasonography, highly echogenic particles flowing in the portal vein, or in the hepatic parenchyma, are seen.¹² Color Doppler shows hyperechogenic foci moving in the lumen of the portal vein, producing sharp bidirectional spikes superimposed on the normal monophasic portal vein wave pattern. A CT scan has high sensitivity for detection of HPVG and its underlying pathology.^{13,14} On sonography, peripheral gas

lucencies, which branch out and are noted within the last 2 cm beneath the liver capsule. This is a key differentiation from HPVG and pneumobilia, which is centrally located because of the biliary anatomy and the direction of bile flow.^{15,16}

The underlying pathology associated with HPVG is directly related to a patient's survival and prognosis.¹³ The increased use of CT scan and ultrasound allows early detection of such severe illnesses and recognition of an increasing number of benign and non-life-threatening causes of HPVG.^{17,18} HPVG associated with Crohn's disease does not mandate surgical intervention, especially in the absence of peritoneal signs or free intraperitoneal gas.¹⁹ The indication for surgery in HPVG is based on the underlying etiology rather than HPVG per se. Treatment with broad-spectrum antibiotics is sufficient in most cases, whereas abdominal sepsis and intestinal necrosis warrant surgical intervention.²⁰

DISCLOSURES

Author contributions: All authors contributed equally to the manuscript. A. Mubarik is the article guarantor.

Financial disclosure: None to report.

Informed consent was obtained for this case report.

Received February 22, 2019; Accepted May 17, 2019

REFERENCES

1. Wolfe JN, Evans WA. Gas in the portal veins of the liver in infants. A roentgenographic demonstration with post-mortem anatomical correlation. *Am J Roentgenol Radiat Ther Nucl Med.* 1955;74:486-9.
2. Abboud B, El Hachem J, Yazbeck T, Doumit C. Hepatic portal venous gas: Physiopathology, etiology, prognosis and treatment. *World J Gastroenterol.* 2009;15(29):3585-90.
3. Liebman PR, Patten MT, Manny J, Benfield JR, Hechtman HB. Hepatic—Portal venous gas in adults: Etiology, pathophysiology and clinical significance. *Ann Surg.* 1978;187:281-7.
4. Sisk PB. Gas in the portal venous system. *Radiology* 1961;77(1):103-7.
5. Cunningham G, Cameron G, De Cruz P. Hepatic portal venous gas in Crohn's disease. *BMJ Case Rep.* 2014;2014:bcr2014206244.

6. Salyers WJ Jr, Mansour A. Portal venous gas following colonoscopy and small bowel follow-through in a patient with Crohn's disease. *Endoscopy*. 2007;39(Suppl 1):E130.
7. Cerezo Ruiz A, Gómez Camacho F, García Sánchez V, IglesiasFlores E, Gallardo Valverde JM, DE Dios Vega JF. A young woman with Crohn's disease and portal gas. *Gastroenterol Hepatol*. 2008;31:550–1. [Spanish].
8. Ng SS, Yiu RY, Lee JF, Li JC, Leung KL. Portal venous gas and thrombosis in a Chinese patient with fulminant Crohn's colitis: A case report with literature review. *World J Gastroenterol*. 2006;12:5582–6.
9. Gosink BB. Intrahepatic gas: Differential diagnosis. *AJR Am J Roentgenol*. 1981;137:763–7.
10. Chezmar JL, Nelson RC, Bernardino ME. Portal venous gas after hepatic transplantation: Sonographic detection and clinical significance. *AJR Am J Roentgenol*. 1989;153:1203–5.
11. Lee CS, Kuo YC, Peng SM, et al. Sonographic detection of hepatic portal venous gas associated with suppurative cholangitis. *J Clin Ultrasound*. 1993;21:331–4.
12. Pan HB, Huang JS, Yang TL, Liang HL Hepatic portal venous gas in ultrasonogram—benign or noxious. *Ultrasound Med Biol*. 2007;33:1179–83.
13. Monneuse O, Pilleul F, Barth X, et al. Portal venous gas detected on computed tomography in emergency situations: Surgery is still necessary. *World J Surg*. 2007;31:1065–71.
14. Chan SC, Wan YL, Cheung YC, Ng SH, Wong AM, Ng KK. Computed tomography findings in fatal cases of enormous hepatic portal venous gas. *World J Gastroenterol*. 2005;11:2953–5.
15. Yarze JC, Markowitz DM. Distinguishing between hepatic portal vein gas and pneumo(aero)bilia. *Liver Transpl*. 2007;13:1476; author reply 1477.
16. Chirica M, Scatton O. Air in the portal venous system: Radiologic differential diagnosis and etiology-specific treatment. *J Chir (Paris)*. 2006;143:141–7.
17. Sellner F, Sobhian B, Baur M, et al. Intermittent hepatic portal vein gas complicating diverticulitis—a case report and literature review. *Int J Colorectal Dis*. 2007;22:1395–9.
18. Hou SK, Chern CH, How CK, Chen JD, Wang LM, Lee CH. Hepatic portal venous gas: Clinical significance of computed tomography findings. *Am J Emerg Med*. 2004;22:214–8.
19. Ha NR, Lee HL, Lee OY, et al. A case of Crohn's disease presenting with free perforation and portal venous gas. *Korean J Gastroenterol*. 2007;50:319–23.
20. Kesarwani V, Ghelani DR, Graham R. Hepatic portal venous gas: A case report and review of literature. *Indian J Crit Care Med*. 2009;13(2):99–102.

Copyright: © 2019 The Author(s). Published by Wolters Kluwer Health, Inc. on behalf of The American College of Gastroenterology. This is an open-access article distributed under the terms of the Creative Commons Attribution-Non Commercial-No Derivatives License 4.0 (CCBY-NC-ND), where it is permissible to download and share the work provided it is properly cited. The work cannot be changed in any way or used commercially without permission from the journal.