

# Switch from previous major depression comorbid with CLIPPERS to mania-like episode following glucocorticosteroid therapy: a case report

Xiaohua Liu, Yan Wu

**To cite:** Liu X, Wu Y. Switch from previous major depression comorbid with CLIPPERS to mania-like episode following glucocorticosteroid therapy: a case report. *General Psychiatry* 2018;**31**:e000007. doi:10.1136/gpsych-2018-000007

► Prepublication history and additional material for this paper are available online. To view these files, please visit the journal online (<http://dx.doi.org/10.1136/gpsych-2018-000007>).

Received 03 April 2018  
Revised 20 April 2018  
Accepted 30 June 2018

## SUMMARY

Bipolar disorder is associated with high rates of general medical conditions, but few cases of overlap between bipolar disorder and chronic lymphocytic inflammation with pontine perivascular enhancement responsive to steroids (CLIPPERS) have been reported in the current literature. The following is a case of a 29-year-old patient with a previous major depressive episode comorbid with CLIPPERS. Following glucocorticosteroid therapy, the patient switched to mania-like presentation and was diagnosed with bipolar disorder due to another medical condition. So it is strongly suggested that high-dose corticosteroid pulse therapy could easily induce psychiatric disturbances for patients with previous psychiatric symptoms, and there may be potential links between bipolar disorder and CLIPPERS in the area of inflammation.

## INTRODUCTION

Bipolar disorder (BD) is a lifelong and recurrent disease characterised by mood swings which can often result in notable distress and functional impairment.<sup>1</sup> Moreover, patients with BD often suffer from higher and more significant physical morbidity than the general population.<sup>2,3</sup> In particular, several epidemiological studies have documented high rates of autoimmune and inflammatory comorbidities in patients with BD, including multiple sclerosis, rheumatoid arthritis, autoimmune thyroiditis, and so forth.<sup>4-6</sup> Here, we present a case who had a previous major depressive episode and recently suffered from chronic lymphocytic inflammation with pontine perivascular enhancement responsive to steroids (CLIPPERS), which is a novel, definable, rare inflammatory central nervous system (CNS) disease, and switched to a mania-like episode following glucocorticosteroid therapy.

## CASE REPORT

### Ethics review and patient consent

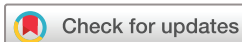This is a retrospective case report, where the patient's medical history, records and images

were reviewed. Ethics committee approval was not necessary as the case fell within the standard of medical care. Informed consent on the diagnostic and therapeutic procedures was given by the patient. Additionally, written consent was obtained from the patient for the purposes of this case publication.

## Case history

Mrs. D is a 29-year-old woman with a previous major depressive episode according to the criteria of the *Diagnostic and Statistical Manual of Mental Disorders, Fourth Edition*,<sup>7</sup> who was seen at a local hospital in June 2012. The patient was administered paroxetine 20 mg (maximum dose 30 mg) daily for 1 year. Then she maintained paroxetine at 10 mg daily.

In January 2016, the patient presented with a 3-week history of subacute dizziness, tetraspasticity, gait ataxia and dysarthria. One week later, she developed dysmasesia, vomiting and difficulty walking that gradually worsened so that she had to lie down in bed all day. The patient was admitted to the neurology unit of a local general hospital with a diagnosis of demyelinating leukoencephalopathy since her brain MRI scan revealed multiple, disseminated hyperintense lesions on T2-weighted images. No positive neurological signs were found but exaggerated tendon reflexes with upper and lower limbs. After 5 days of treatment with gamma globulin, the patient's condition was not significantly improved. Since March 2016, this patient has been staying in the Department of Neurology at Huashan Hospital (Shanghai, China) in pursuit of definite diagnosis and further treatment. Neurological examination on admission revealed a cerebellar syndrome with positive bilateral heel-knee-tibia test and Romberg's sign. Cerebrospinal fluid (CSF) analysis showed protein 793 mg/L, glucose 2.90 mmol/L and chlorine 120 mmol/L, red cells  $1 \times 10^6$ /L, white



© Author(s) (or their employer(s)) 2018. Re-use permitted under CC BY-NC. No commercial re-use. See rights and permissions. Published by BMJ.

Department of Psychiatry, Shanghai Mental Health Center, Shanghai Jiao Tong University School of Medicine, Shanghai, China

### Correspondence to

WuYan; [drwuyan@163.com](mailto:drwuyan@163.com)

cells  $5 \times 10^6/L$ , and Pandy test 1+. The synthesis rate of IgG in the CSF within 24 hours was high which suggested that the blood–brain barrier was slightly damaged, although the IgG band was not significantly different from that in the serum. The antimitochondrial antibody and its subtypes anti-M<sub>2</sub>, anti-M<sub>4</sub> and anti-M<sub>9</sub> were negative. In addition, the antineutrophil cytoplasmic autoantibodies, ds-DNA and autoantibody profile against extractable nuclear antigens were all negative. However, antinuclear antibodies were positive in which the particle type was 1:1000. Serum antibodies against thyroid peroxidase and thyroglobulin were elevated which was 293.70 and 89.60, respectively. MRI scan of the brain showed multiple hyperintense lesions on brainstem, cerebellum, bilateral cerebral hemisphere, basal ganglia and lateral ventricles on T2 and FLAIR images. Moreover, these lesions showed gadolinium contrast enhancement appearing as a typical ‘peppering of pons’. Thereupon, a final diagnosis of CLIPPERS was made. The patient was administered 2 weeks of glucocorticosteroid pulse therapy that started at 500 mg methylprednisolone per day intravenously for three consecutive days and slowly tapered to 120 mg methylprednisolone per day. Subsequently, she was maintained with 0.8 g cyclophosphamide per month intravenously and tapered-off prednisone acetate from 60 mg per day orally. Until now, neurological symptoms had fully remitted.

Meanwhile, the patient was getting overly excited, energetic and lavish on the second day following methylprednisolone treatment. She exhibited symptoms of pressured and rapid speech, inflated self-esteem, decreased need for sleep and increased activities as well for almost 2 weeks. Therefore, the patient visited the Shanghai Mental Health Center and was considered as having BD due to another medical condition in views of previous major depressive episode and recent medication with corticosteroids. Then she was stopped taking paroxetine and replaced it with low-dose anti-psychotics and a mood stabilizer. During the period of mood stabilizer treatment, the patient was transiently depressed and then became stable with 200 mg quetiapine per night plus 1000 mg sodium valproate per day.

## DISCUSSION

To the best of our knowledge, the present case is the first report of a successful diagnosis and treatment for both mood disorder and CLIPPERS. CLIPPERS, first reported by Pittock *and colleagues*,<sup>8</sup> is an inflammatory CNS disorder, prominently involving the brainstem and in particular the pons. Therefore, this disease is considered as a recent addition to the spectrum of brainstem predominant lesions. CLIPPERS is characterised by a combination of clinical symptoms essentially referable to brainstem pathology and a unique MRI appearance. And another distinct feature is clinical and radiological responsiveness to glucocorticosteroid-based immunosuppression. In addition, long-term immunosuppressive therapy seems to be mandatory for sustained improvement since the withdrawal of glucocorticosteroid treatment usually leads to

exacerbation. However, it is well known that corticosteroids are associated with serious physiologic and psychiatric adverse effects. Their neuropsychiatric adverse effects are complex, unpredictable and severe, ranging across most categories including mood lability, anxiety, behavioural disturbances or psychotic features. Generally, the most common adverse effects of short-term therapy are euphoria and hypomania; conversely, long-term therapy tends to induce depressive symptoms.<sup>9</sup> It is most conceivable that high-dose corticosteroid pulse therapy could induce psychiatric disturbances for the patients with previous psychiatric symptoms.

Coincidentally, in the present case, the patient had a history of major depressive episodes and suffered from CLIPPERS afterwards. It originally seemed to be a horse of another colour. Nevertheless, the patient presented with manic-like symptoms following glucocorticosteroid therapy for CLIPPERS. In recent years, several lines of evidence from epidemiological, genetic, post-mortem, preclinical and clinical studies have provided the support that inflammatory reactions and immune modulation play a pivotal role in the pathophysiology of BD. Furthermore, both neuroinflammatory and systemic inflammatory biomarkers which have received continuous attention could be involved in its neuropathogenesis. Thus, the dysfunction of the innate immune system seems to be associated with BD.<sup>10</sup> We are reasonably sure that there may be some potential links between BD and CLIPPERS based on the inflammation hypothesis, besides susceptibility to neuropsychiatric adverse effects of corticosteroids. Clinicians should be cautious with the identification and intervention for medical comorbidities in psychiatric patients.

**Contributors** XL finished the writing of the manuscript. YW provided critical revision for the manuscript. Both authors contributed to and approved the final manuscript.

**Funding** The authors have not declared a specific grant for this research from any funding agency in the public, commercial or not-for-profit sectors.

**Competing interests** None declared.

**Patient consent** Obtained


**Provenance and peer review** Not commissioned; externally peer reviewed.

**Open access** This is an Open Access article distributed in accordance with the Creative Commons Attribution Non Commercial (CC BY-NC 4.0) license, which permits others to distribute, remix, adapt, build upon this work non-commercially, and license their derivative works on different terms, provided the original work is properly cited and the use is non-commercial. See: <http://creativecommons.org/licenses/by-nc/4.0>

## REFERENCES

1. Grande I, Berk M, Birmaher B, *et al*. Bipolar disorder. *Lancet* 2016;387:1561–72.
2. McIntyre RS, Konarski JZ, Soczynska JK, *et al*. Medical comorbidity in bipolar disorder: implications for functional outcomes and health service utilization. *Psychiatr Serv* 2006;57:1140–4.
3. Perugi G, Quaranta G, Belletti S, *et al*. General medical conditions in 347 bipolar disorder patients: clinical correlates of metabolic and autoimmune-allergic diseases. *J Affect Disord* 2015;170:95–103.
4. Hamdani N, Doukhan R, Kurtlucan O, *et al*. Immunity, inflammation, and bipolar disorder: diagnostic and therapeutic implications. *Curr Psychiatry Rep* 2013;15:387.

5. Rosenblat JD, McIntyre RS. Are medical comorbid conditions of bipolar disorder due to immune dysfunction? *Acta Psychiatr Scand* 2015;132:180–91.
6. SayuriYamagata A, Brietzke E, Rosenblat JD, *et al*. Medical comorbidity in bipolar disorder: The link with metabolic-inflammatory systems. *J Affect Disord* 2017;211:99–106.
7. American Psychiatry Association (APA). *Diagnostic and statistical manual of mental disorder: DSM-IV*. 4th edn. Washington DC: American Psychiatric Association, 1994.
8. Pittock SJ, Debruyne J, Krecke KN, *et al*. Chronic lymphocytic inflammation with pontine perivascular enhancement responsive to steroids (CLIPPERS). *Brain* 2010;133:2626–34.
9. Warrington TP, Bostwick JM. Psychiatric adverse effects of corticosteroids. *Mayo Clin Proc* 2006;81:1361–7.
10. Sayana P, Colpo GD, Simões LR, *et al*. A systematic review of evidence for the role of inflammatory biomarkers in bipolar patients. *J Psychiatr Res* 2017;92:160–82.



*Xiaohua Liu is working as an associate chief physician in the Department of Psychiatry at the Shanghai Mental Health Center, Shanghai Jiao Tong University School of Medicine. She graduated and obtained a doctoral degree in Psychiatry and Mental Health from the Shanghai Medical College at Fudan University in 2006. She has been working at the Shanghai Mental Health Center, Shanghai Jiao Tong University School of Medicine since 2006. As a visiting scholar, Dr. Liu studied at the department of Psychiatry of University of California, San Diego from 2012 to 2014. Her research focuses on the molecular biology of psychiatric disorders, especially mood disorders.*