



Original Research Article

Fertility preservation in chemo-radiotherapy for rectal cancer: A combined approach



S. Mariani^a, G. Chiloiro^{a,b}, P. Villa^{a,c}, E. Meldolesi^{a,b,*}, B. Barbaro^{a,d}, A. Di Giorgio^{a,e}, G. Corrado^{a,c}, B. Corvari^{a,b}, M. Giraffa^a, G. Scambia^{a,c}, V. Valentini^{a,b}, M.A. Gambacorta^{a,b}

^a Università Cattolica del Sacro Cuore, Roma, Italy

^b Department of Radiation Oncology, Fondazione Policlinico Universitario Agostino Gemelli IRCCS, Roma, Italy

^c Department of Woman and Child Health and Public Health, Fondazione Policlinico Universitario Agostino Gemelli IRCCS, Roma, Italy

^d Department of Bioimaging and Radiological Sciences, Fondazione Policlinico Universitario Agostino Gemelli IRCCS, Roma, Italy

^e Division of General Surgery, Fondazione Policlinico Universitario Agostino Gemelli IRCCS, Roma, Italy

ARTICLE INFO

Article history:

Received 20 July 2019

Revised 6 September 2019

Accepted 6 September 2019

Available online 12 September 2019

Keywords:

Rectal cancer

Pelvic radiotherapy

Fertility preservation

ABSTRACT

Introduction: Colorectal cancer is a very common form of cancer worldwide, affecting an increasing number of young women. Standard treatment for locally advanced rectal cancer (LARC) can pose a threat to fertility in these patients.

Case presentation: We present the case of a young woman affected by LARC who expressed a desire for child-bearing. The treatment she was proposed, according to guidelines, was neoadjuvant chemo-radiotherapy (CRT) followed by delayed surgery, carrying with it a high risk for amenorrhea. Counselling was performed before the initiation of treatment, with the aim of preserving fertility by the proposal of GnRH agonist administration, ovarian transposition and ovarian tissue cryopreservation, which the patient accepted. Treatment was then successfully completed. The patient presented regular menstrual period from before the surgery.

Discussion: Ovarian tissue is very sensitive to radiations. Transposition of the organ can prevent ovarian insufficiency by placing it outside the radiation field, while ovarian tissue cryopreservation and orthotopic transplantation offers the possibility to restore fertility in the case of organ failure. We performed both of the techniques. GnRH analogs administration allowed to diminish the risk of ovarian cytotoxicity. Radiation treatment plan was optimized in order to minimize the dose to organs at risk (ovary and vagina in particular); position of the uterus, which is quite radiosensitive too, was monitored with daily cone-beam CT (CBCT).

Conclusion: The strategy proposed seemed safe and effective, resulting in radical treatment and persistence of regular menstrual period. Further studies are needed.

© 2019 The Authors. Published by Elsevier B.V. on behalf of European Society for Radiotherapy and Oncology. This is an open access article under the CC BY-NC-ND license (<http://creativecommons.org/licenses/by-nc-nd/4.0/>).

1. Introduction

Colorectal cancer (CRC) is a common form of cancer, with 1.8 million new cases worldwide and almost 500,000 in Europe in 2018 according to the World Health Organization database [1]. It is estimated to be the second most frequent form of cancer among women; approximately one third of the cases are limited to the rectum, and the incidence of rectal cancer in patients aged <40 appears to be increasing [2]. A combined approach including chemo-radiotherapy (CRT) and surgery is the standard of care for most cases of locally advanced rectal cancer (LARC) [3];

radiotherapy and chemotherapy are both responsible of impairment of fecundity and fertility. Currently the availability of methods for fertility preservation, such as surgical transposition of the ovaries and ovarian tissue cryopreservation, together with the advances in radiotherapy with the possibility of delivering ultra-conformal treatments and monitoring target and organs at risk by high quality imaging, make theoretically possible to preserve fertility in women irradiated on the pelvis (Table 1). It is therefore a responsibility of healthcare providers to discuss fertility preservation options with reproductive-aged patients.

2. Case presentation

We present the case of a 24-year-old nulligravida woman who was diagnosed with well differentiated rectal adenocarcinoma

* Corresponding author at: Department of Radiation Oncology, Fondazione Policlinico Universitario Agostino Gemelli IRCCS, Largo Agostino Gemelli, 8, 00168 Roma RM, Italy.

E-mail address: elisa.meldolesi@guest.policlinicogemelli.it (E. Meldolesi).

Table 1

Dose to target and organs at risk.

Structure (name)	Volume (cm ³)	Min dose (Gy)	Max dose (Gy)	Mean dose (Gy)
Anal sphincter	6.8	3.6	55.2	24.5
Left ovary	13.3	0.6	2.1	1.1
Vagina, inferior third	32.5	5.4	54.2	22.1
Uterus	90	18	56.6	41.8
Bladder	136.7	13.4	46.9	33.1
Right femur head	166.2	0.3	41.9	9.3
Left femur head	173.8	0.2	38.5	8.5
Bowel	495.4	1	51.2	19.6
PTV1	329.2	48.9	57.9	55.2
PTV2	554.2	12.7	54.5	44.5

after complaining of rectal bleeding. MRI showed a substenosing tumour of the low-medium rectum extending from 1.5 cm above the ano-rectal junction cranially for 8 cm, with invasion of the mesorectal fascia (MRF) and mesorectal suspect lymph nodes in number <4; TNM stage cT3cN1, MRF+. A total body CT revealed no other localization of disease. The suggested treatment for this case was neoadjuvant long course CRT followed by delayed surgery.

Based on the patient age and her desire for child-bearing, she was early referred to a specialized oncofertility center. The patient underwent transposition of the left ovary and ovarian tissue excision for cryopreservation purposes, both performed laparoscopically during the same procedure; basal serum level of anti-müllerian hormone and antral follicle count were determined before surgery to estimate ovarian reserve. The patient was also given hormonal therapy (GnRH agonist leuporelin, 3 administrations) for ovarian suppression, before and during neoadjuvant

treatment. One month after laparoscopy, CRT treatment started. Radiotherapy was performed by Volumetric Modulated Arc Therapy (VMAT) technique. At the time of prescribing and planning of the radiation treatment, particular attention was given to the transposed ovary, which was contoured as an organ at risk and maintained to a dose below 3 Gy; the uterus and the vagina (inferior third) received a mean dose of 41.8 Gy and 22.1 Gy respectively (Fig. 1). Instructions on bladder filling were administered to the patient and a cone-beam CT (CBCT) scan was performed daily to assess the position of the uterus (Fig. 2).

Neoadjuvant treatment was completed within 5 weeks and 25 fractions of radiotherapy: a total dose of 45 Gy in 1.8 Gy per day was delivered to mesorectum, presacral space and internal iliac nodes; a simultaneous integrated boost, up to a total of 55 Gy in 2.2 Gy per day, was delivered to the tumour and correspondent mesorectum. Concomitant chemotherapy was administered with oral capecitabine (1650 mg/mq/day, every day during radiotherapy).

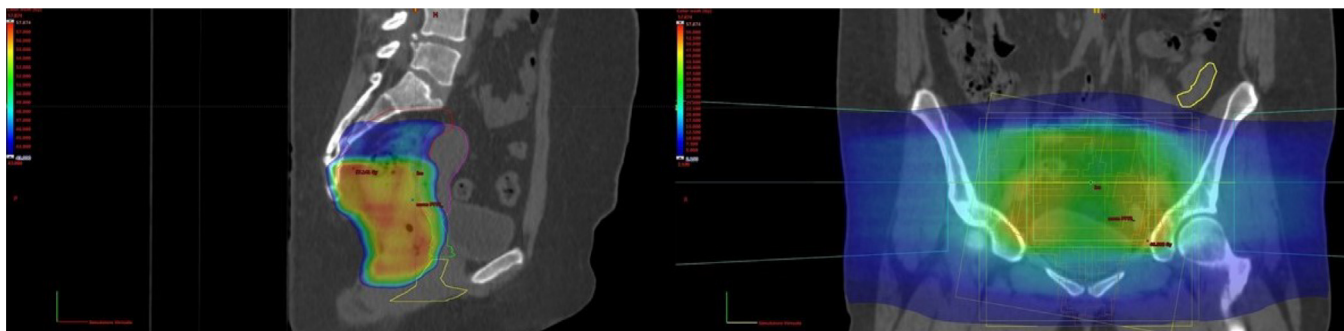


Fig. 1. Dose distribution. On the left, dose distribution to target (red contour); uterus and vagina are respectively represented by purple and yellow contour. On the right, the 2.1 Gy (blue colorwash) laps at the left ovary (yellow contour). (For interpretation of the references to colour in this figure legend, the reader is referred to the web version of this article.)

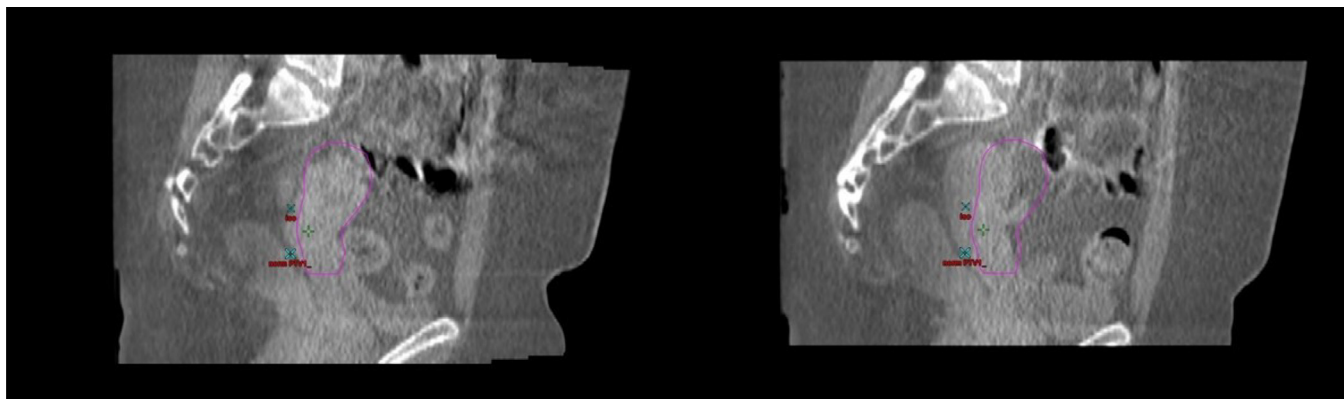


Fig. 2. Cone-beam CT scans taken on two different days during treatment. Purple contour shows position of the uterus at the time of simulation. On the left, the uterus was virtually in the same position as in the simulation day; on the right, position of the uterus was quite different. (For interpretation of the references to colour in this figure legend, the reader is referred to the web version of this article.)

Ten weeks after completion of the neoadjuvant treatment, instrumental restaging by pelvic MRI and clinical re-evaluation were performed and showed good but not complete response to treatment; after two weeks the patient underwent low anterior resection with total mesorectal excision of the rectum. Pathologic assessment revealed ypT2ypN0 residual adenocarcinoma. No adjuvant chemotherapy was administered, as the patient rejected this option.

Four months after surgery, clinical and instrumental evaluation showed no signs of residual or recurrent disease. Menstrual period restarted before surgery and was regularly reported by the patient during all the follow-up time. The estimated age of menopause, based on the dose to the ovary and the patient age at time of treatment, was about 40 years old [4].

3. Discussion

The increase in survival rates for most cancer sites [5], the rise in childbearing age [6] and the yet mentioned tendency towards increasing incidence of cancer among young patients are some of the reasons why fertility preservation is an important issue for cancer patients and health care providers nowadays. It is known that chemotherapy and radiotherapy regimens can lead to infertility. The American Society for Clinical Oncology provides a useful tool by regularly updating its fertility preservation guidelines [7]. Moreover, the advances in radiotherapy treatment planning and delivery such as intensity-modulated radiation therapy (IMRT) and image-guided radiation therapy (IGRT) techniques offer the possibility to administer high doses to a more conformal volume while sparing organs at risk.

Ovarian tissue is very sensitive to radiations; a dose of 2 Gy, which is much lower than the dose delivered in a curative setting, is estimated to kill half of an oocyte population [8]. Ovarian transposition is an option for pelvic irradiation candidate patients, and it proved to preserve ovarian function in the majority of cases [9]. Placing the organ outside the radiation field (e.g. laterally and above the pelvic brim) is considered safe and effective; however, the technique could be unsuccessful due to radiation scatter or remigration of the transposed ovary. In this particular case, we decided to perform oophorectomy together with ovarian tissue cryopreservation. The latter, even if still considered experimental, can restore ovarian activity and was shown to be related to successful pregnancies with rates above 30% after auto-transplantation in a recent prospective study [10]. Small parts of the ovary are excised and frozen in order to be subsequently grafted in an orthotopic site. The procedure can be safely performed laparoscopically. A possible cause of concern when auto-transplanting ovarian tissue is the risk for local recurrence due to reimplantation of neoplastic cells; however, the incidence of ovarian metastases from colorectal cancer is approximately 4%, with no clear evidence supporting routine prophylactic bilateral oophorectomy especially in premenopausal women [11].

Rapidly proliferating cells are easily killed by antineoplastic agents. Cytotoxicity to ovarian tissue and the consequent risk of premature ovarian failure depend on the type and dose of chemotherapeutic agent; data on potential effects of capecitabine on fertility in humans are still lacking, while it was found to impair fertility in animals [12]. Gonadotropin releasing hormone analogs (GnRHa) were found to have a protective role on ovarian function in a recent trial on breast cancer patients [13]; the mechanism of action is probably multifactorial. In addition to other methods, we decided to administer a GnRHa in order to further reduce the likelihood of ovarian insufficiency. Ovarian suppression as a reliable method for fertility preservation is still an open issue indeed.

Radiations, even with doses below 30 Gy [14], can affect fertility by damaging the uterus too, because of its particularly sensitive vessels and musculature. It was demonstrated that large

movements of the uterus can occur during the course of radiotherapy, the most notable being in the superior-inferior and anterior-posterior directions; a technique for limiting organs at risk overdosage should therefore be taken into consideration, especially when using IMRT as in our case [15]. Image guidance by daily CBCT was performed giving us the opportunity for monitoring interfraction motion of the uterus; treatment was considered reproducible every day.

Treatment plan was optimized, with an acceptable reduction of the field superior border in order to keep ovary maximum dose <3 Gy (Dmax 2.1 Gy, Dmean 1.1 Gy); we also aimed at minimizing the dose to the inferior vagina, thus helping to preserve sexual function in a sexually active woman.

4. Conclusions

To our knowledge, this is the first case of such a complex and multidisciplinary approach offered to a young patient undergoing fertility-threatening treatment for cancer. The methods we used to preserve fertility did not require ovarian stimulation for oocyte harvesting and did not compromise the patient prognosis. The patient took an active part in the choice of fertility preservation strategy. Persistence of menstrual period is a surrogate marker for fertility; studies and time are needed to assess effectiveness and safety of the strategy here proposed.

Declaration of Competing Interest

The authors declare that they have no known competing financial interests or personal relationships that could have appeared to influence the work reported in this paper.

References

- [1] Global Cancer Observatory <https://gco.iarc.fr/today/home> last accessed 13/06/19.
- [2] Meyer JE, Narang T, Schnoll-Sussman FH, Pochapin MB, Christos PJ, Sherr DL. Increasing incidence of rectal cancer in patients aged younger than 40 years: an analysis of the surveillance, epidemiology, and end results database. *Cancer* 2010;116(18):4354–9.
- [3] Glynne-Jones R, Wyrwicz L, Tiret E, Brown G, Rödel C, Cervantes A, et al. Rectal cancer: ESMO clinical practice guidelines for diagnosis, treatment and follow-up. *Ann Oncol* 2017;28(suppl. 4):iv22–40.
- [4] Wallace WH, Thomson AB, Saran F, Kelsey TW. Predicting age of ovarian failure after radiation to a field that includes the ovaries. *Int J Radiat Oncol Biol Phys* 2005;62(3):738–44.
- [5] Cronin KA, Lake AJ, Scott S, Sherman RL, Noone AM, Howlander N, et al. Annual report to the nation on the status of cancer, Part I: National cancer statistics. *Cancer* 2018;124(13):2785–800.
- [6] Mathews TJ, Hamilton BE. Mean age of mothers is on the rise: United States, 2000–2014. *NCHS Data Brief* 2016;232:1–8.
- [7] Oktay K, Harvey BE, Partridge AH, Quinn GP, Reinecke J, Taylor HS, et al. Fertility preservation in patients with cancer: ASCO clinical practice guideline update. *J Clin Oncol* 2018;36(19):1994–2001.
- [8] Wallace WH, Thomson AB, Kelsey TW. The radiosensitivity of the human oocyte. *Hum Reprod* 2003;18(1):117–21.
- [9] Bisharah M, Tulandi T. Laparoscopic preservation of ovarian function: an undesired procedure. *Am J Obstet Gynecol* 2003;188(2):367–70.
- [10] Jadoul P, Guilmain A, Squifflet J, Luyckx M, Votino R, Wyns C, et al. Efficacy of ovarian tissue cryopreservation for fertility preservation: lessons learned from 545 cases. *Hum Reprod* 2017;32(5):1046–54.
- [11] Banerjee S, Kapur S, Moran BJ. The role of prophylactic oophorectomy in women undergoing surgery for colorectal cancer. *Colorectal Dis* 2005;7(3):214–7.
- [12] Xeloda: product information https://www.ema.europa.eu/en/documents/product-information/xeloda-epar-product-information_en.pdf.
- [13] Moore HC, Unger JM, Phillips KA, et al. Goserelin for ovarian protection during breast-cancer adjuvant chemotherapy. *N Engl J Med* 2015;372(10):923–32.
- [14] Critchley HO, Wallace WH, Shalet SM, Mamtara H, Higginson J, Anderson DC. Abdominal irradiation in childhood: the potential for pregnancy. *Br J Obstet Gynaecol* 1992;99(5):392–4.
- [15] Jaden R, Pembroke CA, Hanna CL, Palaniappan N, Evans M, Cleves AE, et al. A systematic review of organ motion and image-guided strategies in external beam radiotherapy for cervical cancer. *Clin Oncol (R Coll Radiol)* 2014;26(4):185–96.