

# Prevalence and characteristics of ponticulus posticus and its association with cervicogenic headache and migraine: A lateral cephalometric study

Nasrin Mokhtari<sup>1</sup>, Fereshteh Ashtari<sup>2</sup>, Mehdi Razavi<sup>3,4</sup>, Roshanak Ghaffari<sup>5</sup>

<sup>1</sup>Department of Dentistry, Islamic Azad University, Isfahan (Khorasgan) Branch, Isfahan, Iran, <sup>2</sup>Department of Neurology, School of Medicine, Isfahan University of Medical Sciences, Isfahan, Iran, <sup>3</sup>Department of Internal Medicine, Biionix™ (Bionic Materials, Implants and Interfaces) Cluster, College of Medicine, University of Central Florida, Orlando, Florida, USA, <sup>4</sup>Department of Material Sciences and Engineering, University of Central Florida, Orlando, Florida, USA, <sup>5</sup>Department of Oral and Maxillofacial Radiology, Islamic Azad University, Isfahan (Khorasgan) Branch, Isfahan, Iran

**Background:** Ponticulus posticus (PP) (arcuate foramen) is an abnormal bony bridge in the posterior arch of the atlas, which could possibly cause certain complications such as headache. Our goal was to assess the prevalence and size of PP on lateral cephalometric radiographs and its relationships with cervicogenic headache and migraine. **Materials and Methods:** This cross-sectional study was a descriptive-analytical type and was performed in Isfahan Azad Dental University. Lateral cephalometric radiographs of 150 patients referred to the radiology department were selected to assess the prevalence and size of the anomaly. A checklist was prepared to evaluate cervicogenic headache and migraine among patients. **Results:** Our sample consisted of 97 females and 53 males with an age range between 5 and 56 years. The prevalence of PP was 21.3% (12% complete and 9.3% incomplete), and an insignificant difference was noted between the prevalence of complete and incomplete foramen ( $P > 0.05$ ). The prevalence of foramen was higher in women (59.4%), but it was not significant. The mean width of complete foramen was 6.40 mm, and the mean heights in individuals with complete and incomplete foramen were 4.71 and 4.84 mm, respectively. Among patients with the anomaly, 43.8% had cervicogenic headache and 9.4% had migraine. There was a significant association between the presence of foramen and both types of headaches ( $P < 0.05$ ). However, there was no significant correlation between the shape of anomaly and the presence of cervicogenic headache and migraine ( $P > 0.05$ ). **Conclusion:** Our study showed a high prevalence of PP and its significant association with cervicogenic headache and migraine.

**Key words:** Atlas, headache, lateral cephalometry, ponticulus posticus, Iran

**How to cite this article:** Mokhtari N, Ashtari F, Razavi M, Ghaffari R. Prevalence and characteristics of ponticulus posticus and its association with cervicogenic headache and migraine: A lateral cephalometric study. *J Res Med Sci* 2022;27:61.

## INTRODUCTION

One of the anatomical variations of the atlas is ponticulus posticus (PP), which is a bony bridge in the posterior arch that creates a channel for the passage of the vertebral artery and the root of the C1 nerve. This anomaly can be complete or incomplete, unilateral, or bilateral.<sup>[1]</sup> PP means a small bony bridge in Latin. PP could also result in migraine without aura, cervical pain

syndrome, chronic tension headache, and symptoms of vertebrobasilar insufficiency syndrome, which includes dizziness, impaired vision, impaired speech, dysphagia, diplopia, hearing impairment, balance disorder, tinnitus, and shoulder pain.<sup>[1-3]</sup> The relationship between these effects and PP plays a more important role when the patient's symptoms are relieved through corrective PP surgery.<sup>[4]</sup> Some studies are focused on the effect of PP on screw implantation techniques in the atlas vertebrae because unawareness of this anomaly

This is an open access journal, and articles are distributed under the terms of the Creative Commons Attribution-NonCommercial-ShareAlike 4.0 License, which allows others to remix, tweak, and build upon the work non-commercially, as long as appropriate credit is given and the new creations are licensed under the identical terms.

**For reprints contact:** WKHLRPMedknow\_reprints@wolterskluwer.com

Access this article online	
Quick Response Code:	Website: www.jmsjournal.net
	DOI: 10.4103/jrms.jrms_384_21

**Address for correspondence:** Dr. Roshanak Ghaffari, Department of Oral and Maxillofacial Radiology, Islamic Azad University, Isfahan (Khorasgan) Branch, Isfahan, Iran.  
E-mail: roshanakghaffari@yahoo.com

**Submitted:** 30-Apr-2021; **Revised:** 03-Feb-2022; **Accepted:** 10-May-2022; **Published:** 27-Aug-2022

can lead to a misunderstanding of the large size of the posterior arch, which causes unwanted damage to the vertebral arteries during the surgical procedure. Therefore, accurate determination of the screw entry point based on three-dimensional computerized tomography (CT) before surgery is the most crucial factor to avoid this complication.<sup>[5,6]</sup> Besides, the associations between arcuate foramen and other anomalies such as sagittal skeletal malocclusions, dental malocclusion, impacted canine, sella turcica bridge, and elongated styloid have been recently noted.<sup>[2,7-14]</sup> PP can be detected in lateral cephalometric radiographs which are more suitable for screening than cone-beam computed tomography (CBCT) due to less radiation and more common use by orthodontists.<sup>[1]</sup> Orthodontists who may be the first people to diagnose PP are not responsible for treating and correcting this anomaly. Instead, when the anomaly is observed, that should be recorded, and the patient should be referred to a physician, if necessary.<sup>[15]</sup> Therefore, increasing dentist's knowledge about specific symptoms of headaches associated with this anomaly helps diagnose PP with more accuracy. Furthermore, there are not enough research about prevalence and morphologic characteristics of PP and its association with other anomalies in Iran to the best of our knowledge. This study aimed to determine the frequency and dimensions of arcuate foramen on lateral cephalometric radiographs and related cervicogenic headache and migraine in all of the sample size.

## MATERIALS AND METHODS

This cross-sectional study was performed at the Department of Oral and Maxillofacial Radiology, Faculty of Dentistry, Isfahan Azad University, from November 2019 to September 2020.

Ethical approval for this study was obtained from Islamic Azad University (Isfahan branch) Ethics Committee (Ethical Number: IR.IAU.KHUISF.REC.1398.282/Project Number: 17521239533195139874019).

Using the below formula, 5% confident level ( $\alpha = 0.05$ ), 8% power of the study, and the fact that precision was at least one-fourth of standard deviation (SD) ( $\epsilon = 0.25 \sigma$ ),<sup>[16]</sup> the minimum sample size was achieved 126. Considering an extra 10% to compensate for persons that the researchers were unable to contact, the final sample size was obtained to be 150.

$$n = \left( \frac{(z_{1-\alpha/2} + z_{1-\beta})^2 \times \sigma^2}{\epsilon^2} \right)$$

A total of 160 patients were selected among those who needed lateral cephalometry through a convenience,

nonprobability sampling technique. Moreover, 10 subjects were excluded from the study based on the exclusion criteria that includes occipital bone or mastoid process superimposition, history of cervical vertebrae trauma and surgery, craniofacial syndromes, patients with orofacial clefts, and low-quality lateral cephalometric radiographs.

Radiographs were taken by Vatech (PCH2500-Korea) and were evaluated under the supervision of a maxillofacial radiologist, and the obtained information was classified into three categories: complete PP [Figure 1a], incomplete PP [Figure 1b], and lack of anomaly [Figure 1c].

In the presence of the arcuate foramen, first, the magnification factor was calculated in EasyDent 4 software by selecting the calibration option. The dimensions of the foramen on the lateral cephalometric images were then measured by determining the height and width of the foramen in the case of complete PP and the height of the foramen in the case of incomplete PP.

Similar to a previously published article,<sup>[3]</sup> we used the guidelines of the International Classification of Headache Disorders-3, which provides criteria for classifying cervicogenic and migraine. The history of cervicogenic headache and migraine of all study subjects was evaluated. Headache diagnosis was made only by the neurologist, and then the prevalence of cervicogenic and migraine was assessed. Due to the importance of the exact distinguishment between cervicogenic headache and migraine, CHISG diagnostic criteria were used.<sup>[17,18]</sup>

## Statistics

The Chi-square test and Fisher's exact test were used for assessing the relationship between qualitative variables. The Shapiro-Wilk test indicated that our samples were from a normally distributed population. The independent *t*-test and the Pearson's correlation coefficient were used to analyze quantitative variables. The statistical analyses were performed using SPSS version 22.0 (IBM Corp. Released 2013. IBM SPSS Statistics for Windows, Version 22.0. Armonk, NY, USA: IBM Corp). The level of significance was set at  $P < 0.05$ .

## RESULTS

A total of 150 lateral cephalometric radiographs of 53 male and 97 female patients were examined. The patients were in the age range of 5–56 years with a mean  $\pm$  SD age of  $17.75 \pm 7.66$  years, and the highest frequency was related to patients in the age group of 11–20 years (57.3%) that is the common age range for orthodontic treatment. PP anomaly was observed in 32 patients (21.3%) (40.6% of males and 59.4% of females). There was no significant relationship

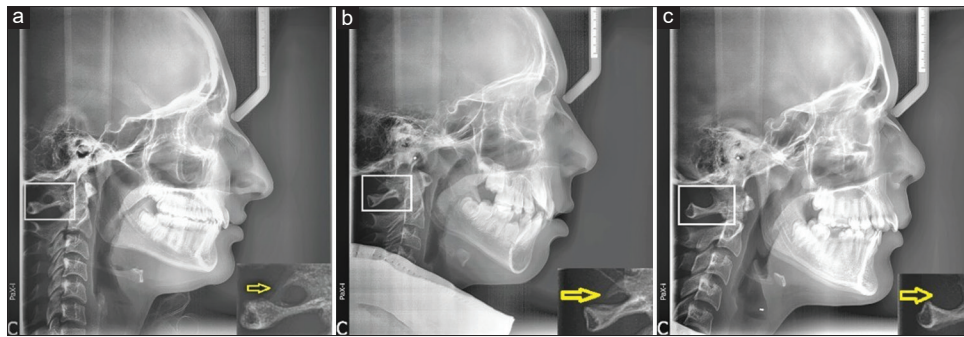


Figure 1: Various morphologic types of Arcuate foramen seen on lateral cephalograms. Yellow arrows show complete (a), incomplete (b) and lack of Ponticulus posticus (c)

between PP anomaly and gender ( $P = 0.480$ ). A total of 14 cases of anomalies (43.8%) had incomplete anomaly type, and 18 cases (56.2%) had a complete anomaly [Table 1]. Although the prevalence of complete and incomplete foramen was higher in women than men, this difference was insignificant ( $P = 0.618$ ). The dimensions of the arcuate foramen (PP) and its distribution according to gender are summarized in Table 2.

We monitored patients with cervicogenic symptoms such as unilaterality with side-locked headache, radiation to the ipsilateral shoulder and arm, attack provocation by digital pressure, Attack provocation by posture and movement and these symptoms followed ICDHD-3 diagnostic criteria:

- A. Any headache fulfilling criterion C
- B. Clinical and/or imaging evidence<sup>1</sup> of a disorder or lesion within the cervical spine or soft tissues of the neck, known to be able to cause headache<sup>2</sup>
- C. Evidence of causation demonstrated by at least two of the following:
  1. Headache has developed in temporal relation to the onset of the cervical disorder or appearance of the lesion
  2. Headache has significantly improved or resolved in parallel with improvement in or resolution of the cervical disorder or lesion
  3. Cervical range of motion is reduced, and headache is made significantly worse by provocative manoeuvres
  4. Headache is abolished following diagnostic blockade of a cervical structure or its nerve supply (3) and migraine symptoms including unilaterality headache with side shifting, Nausea, vomiting, visual change, photophobia, and phonophobia, Pulsating pain quality.

Table 3 demonstrates the correlation between headache and presence of PP. Among patients with PP anomaly, 14 (43.8%) patients had cervicogenic headache and 3 (9.4%) patients with migraine.

Migraine was observed in only 4 (3.4%) patients among patients without PP anomaly. There was a significant association between PP and both types of

Table 1: Frequency distribution of ponticulus posticus by gender and foramen type

Gender	Foramen type		
	Foramen presence, n (%)	Incomplete, n (%)	Complete, n (%)
Male	13 (40.6)	5 (35.7)	8 (44.4)
Female	19 (59.4)	9 (64.3)	10 (55.6)
Total	32 (21.3)	14 (43.8)	18 (56.2)
P	0.480		0.618

Table 2: Comparison of arcuate foramen (ponticulus posticus) dimensions between male and female patients

PP	Dimension	Gender	n	Mean±SD	Statistics	P
Complete	Height	Male	8	5.12±1.21	1.102	0.287
		Female	10	4.38±1.54		
	Width	Male	8	6.48±0.93	0.248	
		Female	10	6.34±1.43		
Incomplete	Height	Male	5	4.73±1.58	-0.255	0.803
		Female	9	4.91±1.11		

PP=Ponticulus posticus; SD=Standard deviation

Table 3: Co-relation between both types of headaches and presence of ponticulus posticus

Headache	PP		Total, n (%)	P
	Absent, n (%)	Present, n (%)		
Without headache	114 (96.6)	15 (46.9)	129 (86.0)	
Migraine	4 (3.4)	3 (9.4)	7 (4.7)	0.048
Cervicogenic headache	0	14 (43.8)	14 (9.3)	0.000
Total	118 (100)	32 (100)	150 (100)	

PP=Ponticulus posticus

headaches ( $P < 0.05$ ). About 42.9% of patients with incomplete arcuate foramen and 44.4% of patients with complete arcuate foramen had cervicogenic headache. Furthermore, the percentage of migraine in patients with complete and incomplete foramen was 11.1% and 7.1%, respectively. The results of the Chi-square test did not show a significant relationship between PP anomaly type and headache in the subjects ( $P = 1.00$ ).

The mean ± SD age of the patients with arcuate foramen was  $20.7 \pm 97.17$  years and  $16.7 \pm 87.58$  years in patients without

PP anomaly. Furthermore, the mean age of the patients with arcuate foramen was significantly higher than those patients with no arcuate foramen ( $P = 0.007$ ). The mean  $\pm$  SD age of the patients with incomplete arcuate foramen was  $21.07 \pm 8.57$  years and  $20.89 \pm 6.13$  years for patients with complete arcuate foramen. The result of the independent *t*-test did not show a significant difference in the mean age of the two groups ( $P = 0.944$ ).

## DISCUSSION

The prevalence of PP was found to be 21.3% in the present study. In the study by Hasani *et al.* on CBCT, the PP prevalence was reported as 20.6%, which is consistent with the results of the current study on lateral cephalometry.<sup>[19]</sup> In the studies by Hoenig and Schoener, the prevalence rates of PP were found to be 21.67% and 22.09%, respectively.<sup>[20,21]</sup> However, Ziabari *et al.* with different sample sizes and inclusion criteria reported a low prevalence of arcuate foramen, i.e., 9.6%.<sup>[6]</sup> Elliott and Tanweer found an average prevalence of PP on radiographs as 16.6%, which could be related to different races and sample sizes.<sup>[22]</sup>

According to a previous study, the prevalence of PP in different ethnic groups was between 5% and 34% in the Western race and between 6.57% and 15.5% in the Asian race.<sup>[19]</sup> However, our study reports a higher prevalence compared to previous studies listed above that had been conducted in the Asian region. Because of a low number of studies found in Iran, further studies in this field are recommended to compare the obtained results with more depth.

The authors of the present study found a prevalence of 12% for complete PP and 9.3% for incomplete PP, but no significant difference was found between the two rates ( $P > 0.05$ ). The prevalence of complete foramen in different studies is between 4.88% and 9.2%, and for the incomplete arcuate foramen, between 2.93% and 60%. The wide range of prevalence for incomplete foramen can be due to the lack of a standard diagnostic criterion.<sup>[23]</sup> In this study, 40.6% of men and 59.4% of women had this anomaly, and the relationship between the anomaly and gender was not statistically significant. This finding is similar to those of previous studies.<sup>[15,19,24-27]</sup> However, in other studies, the prevalence of anomaly has been observed more in men.<sup>[2,28-32]</sup>

In our study, 63.3% of women had incomplete PP, and 55.6% of them had complete PP, and there was not any statistically significant relationship between shape of the anomaly and gender. These results are similar to the results of previous studies.<sup>[15,19,33]</sup> However, in Pekala *et al.*'s study, the prevalence of complete foramen was higher in men, and they observed that the prevalence of incomplete foramen was higher in women.<sup>[34]</sup>

In the present study, the mean  $\pm$  SD width of arcuate foramen was  $6.40 \pm 1.2$  mm, and the mean  $\pm$  SD heights of the foramen in patients with complete and incomplete foramen were  $4.71 \pm 1.41$  and  $4.84 \pm 1.24$  mm, respectively. Furthermore, in the study by Hasani *et al.* on CBCT, the mean width of arcuate foramen was reported to be 6.52 mm, and the mean height of the foramen was 5.95 mm, and this finding is in line with the results of the present study.<sup>[19]</sup> In the study by Mitchell on corpses, the height of the foramen was between 4.9 and 5.7 mm, and the width of the foramen was between 5.9 and 6.7 mm.<sup>[35]</sup> In the study by Unur *et al.*, the mean of superior–inferior dimensions of the foramen was 5.7 mm, and the mean of anterior–posterior dimensions of the foramen was 8.1 mm. These sizes are higher than those in our study.<sup>[36]</sup> Mitchell concluded that the diameter of the anterior–posterior dimensions was significantly more extensive than that of the upper and lower dimensions, which is also in agreement with the results of our study.<sup>[35]</sup>

In the present study, cervicogenic and migraine were observed in 9.3% and 4.7% of all patients, respectively. Among patients with PP anomaly, 43.8% had cervicogenic headache, and 9.4% had migraine, and among patients without PP anomaly, 3.4% had migraine. There was a significant correlation between the presence of foramen and mentioned headaches, but no significant relationship was found between shape of the anomaly (complete or incomplete) and the presence of headaches.

Tambawala *et al.* in India found that the prevalence of cervicogenic headache was 6% in all samples after examining 500 lateral cephalometry and completing a cervicogenic headache diagnosis questionnaire. Moreover, similar to our study, a significant relationship was found in their study between PP and cervicogenic headache. The prevalence of headache in patients with complete arcuate foramen was higher;<sup>[3]</sup> however, we found this insignificant.

In the Pekala *et al.*'s study, a significant relationship was found between the presence of PP and headache. The prevalence of headache was 5.84 in patients with complete arcuate foramen, and it was 19.4 for those with incomplete foramen.<sup>[34]</sup>

In Wight *et al.*'s study, there was a significant association between prevalence of PP and migraine without aura, while this relationship was insignificant for cervicogenic headache and migraine with aura.<sup>[37]</sup> Furthermore, in the studies by Cakmak *et al.* and Ratnaparkhi *et al.*, neck pain and vertigo were significantly more serious in patients with complete PP.<sup>[38,39]</sup> In Sabir *et al.*'s study, the presence of foramen was significantly higher in patients with migraine compared to the control group, which is not consistent with the results of the present study.<sup>[40]</sup>



In the present study, the mean age of subjects was 17.75 years, and the highest frequency was in the age group of 11–24 years. The mean  $\pm$  SD age was  $20 \pm 7.17$  years in patients with arcuate foramen and  $16.87 \pm 7.58$  years in patients without the anomaly. Furthermore, the mean age of the patients with PP was significantly higher than that of those without PP.

Studies on the relationship between age and the highest prevalence of PP anomaly indicate that aging causes the atlas vertebrae ossification.<sup>[41-43]</sup> Bayrakdar *et al.* have considered the age of 49-81 years as the highest age of PP prevalence.<sup>[44]</sup> Geist *et al.* also considered the highest age of prevalence of arcuate foramen after puberty.<sup>[45]</sup> However, some researchers did not find a significant difference between the prevalence of PP and age.<sup>[15,46]</sup> Joshi *et al.* emphasized the effect of genetic causes on the prevalence of this anomaly, but did not report the significance of the prevalence of arcuate foramen anomaly in different age groups.<sup>[23]</sup>

In the present study, the mean  $\pm$  SD age of the patients with incomplete foramen anomaly was  $21.07 \pm 8.57$  years, and in patients with complete foramen anomaly, it was  $20.89 \pm 6.13$  years. Moreover, no significant relationship was observed between the two age groups. Taitz and Nathan, on the other hand, estimated the prevalence of complete foramen anomaly to be higher in the 30–80 years' age range and the prevalence of incomplete foramen in the age range of 10–30 years.<sup>[47]</sup> It is worth noting that Chitroda *et al.* observed both complete and incomplete anomaly in the age range of 16–45 years.<sup>[42]</sup> Paraskevas *et al.* found that the prevalence of PP was age related and that progressive mineralization of bone bridges from incomplete to complete occurs over time.<sup>[41]</sup>

Some limitations of our study should be noted. Even though lateral cephalometry is one of the main tools for screening PP, CT is more sensitive for assessing the characteristics of arcuate foramen.<sup>[48]</sup> Furthermore, approximately, most of the samples belonged to orthodontic patients that are commonly between the range of 11 and 20 years. Hence, it is recommended that future studies have homogenous distribution in age groups.

## CONCLUSION

The results of the present study showed a relatively high prevalence of PP in the studied population, and a significant relationship was found between anomaly and both types of headaches. Lateral cephalometry and its imaging findings seem to be an excellent tool for screening arcuate foramen because it is the most common diagnostic radiography in orthodontics. It is suggested to research more about PP's

relationship with other symptoms or other craniofacial anomalies for future studies.

## Financial support and sponsorship

Nil.

## Conflicts of interest

There are no conflicts of interest.

## REFERENCES

- Lo Giudice A, Caccianiga G, Crimi S, Cavallini C, Leonardi R. Frequency and type of poniculus posticus in a longitudinal sample of nonorthodontically treated patients: Relationship with gender, age, skeletal maturity, and skeletal malocclusion. *Oral Surg Oral Med Oral Pathol Oral Radiol* 2018;126:291-7.
- Bayrakdar IŞ, Miloğlu Ö, Yeşiltepe S, Yılmaz AB. Poniculus posticus in a cohort of orthodontic children and adolescent patients with different sagittal skeletal anomalies: A comparative cone beam computed tomography investigation. *Folia Morphol (Warsz)* 2018;77:65-71.
- Tambawala SS, Karjodkar FR, Sansare K, Motghare D, Mishra I, Gaikwad S, *et al.* Prevalence of poniculus posticus on lateral cephalometric radiographs, its association with cervicogenic headache and a review of literature. *World Neurosurg* 2017;103:566-75.
- Tasökers M, Özcan S. Poniculus posticus: Is it important for a dentist as an radiological finding? *Yeditepe Dent J* 2017;13:35-41.
- Song MS, Lee HJ, Kim JT, Kim JH, Hong JT. Poniculus posticus: Morphometric analysis and its anatomical implications for occipito-cervical fusion. *Clin Neurol Neurosurg* 2017;157:76-81.
- Ziabari SM, Asadi P, Ansari MM, Razzaghi A, Kasmaei VM. Prevalence of arcuate foramen among emergency department visitors; an epidemiologic study. *Iran J Emerg Med* 2017;4:46-51.
- Adisen MZ, Misirlioglu M. Prevalence of poniculus posticus among patients with different dental malocclusions by digital lateral cephalogram: A comparative study. *Surg Radiol Anat* 2017;39:293-7.
- Amelinda VP, Ismaniati NA, Purbiati M. Association of sella turcica bridge and poniculus posticus with palatally impacted canine and hypodontia. *J Int Dent Med Res* 2019;12:1090-4.
- Haji Ghadimi M, Amini F, Hamed S, Rakhshan V. Associations among sella turcica bridging, atlas arcuate foramen (poniculus posticus) development, atlas posterior arch deficiency, and the occurrence of palatally displaced canine impaction. *Am J Orthod Dentofacial Orthop* 2017;151:513-20.
- Tassoker M, Kok H, Ozcan S. Investigation of the relationship between "sella turcica bridge" and "poniculus posticus": A lateral cephalometric study. *Int J Morphol* 2017;35:337-44.
- Sekerci AE, Soyulu E, Arikani MP, Aglarci OS. Is there a relationship between the presence of poniculus posticus and elongated styloid process? *Clin Imaging* 2015;39:220-4.
- Dadgar S, Alimohamadi M, Rajabi N, Rakhshan V, Sobouti F. Associations among palatal impaction of canine, sella turcica bridging, and poniculus posticus (atlas arcuate foramen). *Surg Radiol Anat* 2021;43:93-9.
- Pasini M, Giuca MR, Ligori S, Mummolo S, Fiasca F, Marzo G, *et al.* Association between anatomical variations and maxillary canine impaction: A retrospective study in orthodontics. *Appl Sci* 2020;10:5638.
- Shahidi S, Hasani M, Khozaei M. Evaluating the relation between the elongated styloid process and the poniculus posticus using

- cone-beam computed tomography. *Folia Morphol (Warsz)* 2022;81:196-202.
15. Giri J, Pokharel PR, Gyawali R. How common is ponticulus posticus on lateral cephalograms? *BMC Res Notes* 2017;10:172.
  16. Cohen J. *Statistical Power Analysis for the Behavioral Sciences*. Academic Press; New York 1969. p. 101-105.
  17. Sjaastad O, Fredriksen TA, Pfaffenrath V. Cervicogenic headache: Diagnostic criteria. *The Cervicogenic Headache International Study Group. Headache* 1998;38:442-5.
  18. Vincent MB. Cervicogenic headache: A review comparison with migraine, tension-type headache, and whiplash. *Curr Pain Headache Rep* 2010;14:238-43.
  19. Hasani M, Shahidi S, Rashedi V, Hasani M, Hajiyani K. Cone Beam CT study of ponticulus posticus: Prevalence, characteristics. *Biomed Pharmacol J* 2016;9:1067-72.
  20. Hoening JF, Schoener WF. Radiological survey of the cervical spine in cleft lip and palate. *Dentomaxillofac Radiol* 1992;21:36-9.
  21. Kavakli A, Aydinlioglu A, Yesilyurt H, Kus I, Diyarbakirli S, Erdem S, *et al.* Variants and deformities of atlas vertebrae in Eastern Anatolian people. *Saudi Med J* 2004;25:322-5.
  22. Elliott RE, Tanweer O. The prevalence of the ponticulus posticus (arcuate foramen) and its importance in the Goel-Harms procedure: Meta-analysis and review of the literature. *World Neurosurg* 2014;82:e335-43.
  23. Joshi V, Matsuda Y, Kimura Y, Araki K, Ishida H. Evaluation of prevalence and characteristics of ponticulus posticus among Japanese adults: A comparative study between CBCT imaging and lateral cephalogram. *Orthod Waves* 2018;77:134-41.
  24. Cho YJ. Radiological analysis of ponticulus posticus in Koreans. *Yonsei Med J* 2009;50:45-9.
  25. Sharma V, Chaudhary D, Mitra R. Prevalence of ponticulus posticus in Indian orthodontic patients. *Dentomaxillofac Radiol* 2010;39:277-83.
  26. Mudit G, Srinivas K, Satheesha R. Retrospective analysis of ponticulus posticus in Indian orthodontic patients—a lateral cephalometric study. *Ethiop J Health Sci* 2014;24:285-90.
  27. Gibelli D, Cappella A, Cerutti E, Spagnoli L, Dolci C, Sforza C. Prevalence of ponticulus posticus in a Northern Italian orthodontic population: A lateral cephalometric study. *Surg Radiol Anat* 2016;38:309-12.
  28. Pérez IE, Chávez AK, Ponce D. Frequency of ponticulus posticus in lateral cephalometric radiography of Peruvian patients. *Int J Morphol* 2014;32:54-60. <https://www.scielo.cl/pdf/ijmorphol/v32n1/art10.pdf>.
  29. Ain QU, Gilani SB, Choudry MA, Awan BY. Prevalence of Ponticulus Posticus in Orthodontic Patients of the Local Population of Islamabad, Pakistan 2019; 14 (3). <https://journals.riphah.edu.pk/index.php/jiimc/article/view/1185>.
  30. Saleh A, Gruber J, Bakhsh W, Rubery PT, Mesfin A. How common is the ponticulus posticus? A CT-based analysis of 3000 patients. *Spine J* 2016;16:S344.
  31. Martínez F, Del Castillo J, Hermosilla S, Kenny J, Sgarbi N, Emmerich J. Ponticulus posticus prevalence in Uruguayan population: Dry bone and cervical CT imaging. *Eur J Anat* 2021;25:179-85.
  32. Pandey P, Pasricha N, Yadav S, Sthapak E. A computed tomographic study to document anatomical variations of first cervical vertebra: Prevalence, classification and possible clinical implications. *FASEB J* 2021;35. <https://doi.org/10.1096/fasebj.2021.35.S1.01620>.
  33. Govindraj P, Kumar TS. Prevalence of ponticulus posticus of the first cervical vertebra: A digital radiographic study. *J Indian Acad Oral Med Radiol* 2017;29:95.
  34. Pekala PA, Henry BM, Pekala JR, Hsieh WC, Vikse J, Sanna B, *et al.* Prevalence of foramen arcuale and its clinical significance: A meta-analysis of 55,985 subjects. *J Neurosurg Spine* 2017;27:276-90.
  35. Mitchell J. The incidence and dimensions of the retroarticular canal of the atlas vertebra. *Acta Anat (Basel)* 1998;163:113-20.
  36. Unur E, Erdoğan N, Ülger H, Ekinci N, Öztürk Ö. Radiographic incidence of complete arcuate foramen in Turkish population. *Erciyes Med J* 2004;26:50-4.
  37. Wight S, Osborne N, Breen AC. Incidence of ponticulus posterior of the atlas in migraine and cervicogenic headache. *J Manipulative Physiol Ther* 1999;22:15-20.
  38. Cakmak O, Gurdal E, Ekinci G, Yildiz E, Cavdar S. Arcuate foramen and its clinical significance. *Saudi Med J* 2005;26:1409-13.
  39. Ratnaparkhi MM, Pokharkar PM, Mhapuskar A, Hiremutt DR, Jain R, Telrandhe NV. Co-relation between presence of ponticulus posticus on the lateral cephalogram with cervical pain and vertigo. *Eur J Mol Clin Med* 2021;7:4047-53.
  40. Sabir H, Kumbhare S, Rout P. Evaluation of ponticulus posticus on digital lateral cephalograms and cone beam computed tomography in patients with migraine and healthy individuals: A comparative study. *Oral Surg Oral Med Oral Pathol Oral Radiol* 2014;118:348-54.
  41. Paraskevas G, Papaziogas B, Tsonidis C, Kapetanios G. Gross morphology of the bridges over the vertebral artery groove on the atlas. *Surg Radiol Anat* 2005;27:129-36.
  42. Chitroda PK, Katti G, Baba IA, Najmudin M, Ghali SR, Kalmath B, *et al.* Ponticulus posticus on the posterior arch of atlas, prevalence analysis in symptomatic and asymptomatic patients of gulbarga population. *J Clin Diagn Res* 2013;7:3044-7.
  43. Zhang J, Shen J, Li Y, Zheng J, Wang Y, Shao H, *et al.* Frequency and type of ponticulus posticus and lateralis in a Chinese population: A CT-based analysis of 4047 cases. *Turk Neurosurg* 2021.
  44. Bayrakdar IS, Miloglu O, Altun O, Gumussoy I, Durna D, Yilmaz AB. Cone beam computed tomography imaging of ponticulus posticus: Prevalence, characteristics, and a review of the literature. *Oral Surg Oral Med Oral Pathol Oral Radiol* 2014;118:e210-9.
  45. Geist JR, Geist SM, Lin LM. A cone beam CT investigation of ponticulus posticus and lateralis in children and adolescents. *Dentomaxillofac Radiol* 2014;43:20130451.
  46. Chen CH, Chen YK, Wang CK. Prevalence of ponticuli posticus among patients referred for dental examinations by cone-beam CT. *Spine J* 2015;15:1270-6.
  47. Taitz C, Nathan H. Some observations on the posterior and lateral bridge of the atlas. *Acta Anat (Basel)* 1986;127:212-7.
  48. White SC, Pharoah MJ. *White and Pharoah's Oral Radiology e-Book: Principles and Interpretation*. Elsevier Health Sciences; 2018.