

Four-Layer Structural Reconstruction for Recurrent Anterior Shoulder Dislocation



Jinzhong Zhao, M.D., and Jin Tang, B.M.

Abstract: Recurrent anterior shoulder dislocation is always combined with glenoid and capsule-labrum deficiency. To address all these deficiency in a single operation, we developed a 4-layer structural reconstruction technique at the anterior side of the shoulder, which includes capsule-labrum repair, glenoid bone grafting, and transfer of the long head of the biceps brachii (LHB). This procedure is indicated in patients who need both sling and bone fragment augmentation. The critical steps of this technique are LHB transfer and 2-layer glenoid bone grafting. We believe that this technique will enhance the field of anterior shoulder reconstruction for complicated anterior shoulder dislocation.

In recurrent anterior shoulder dislocation, various structural deficiencies exist, such as glenoid defect and capsule ligament insufficiency. To address these deficiencies, the Bristow-Latarjet procedure has been developed with a supposed triple-block mechanism and proved effective.¹⁻³ However, during the Latarjet procedure, the coracoacromial arch is destroyed, which may result in increased instability. To create a triple-block mechanism similar to the Bristow-Latarjet procedure, we developed a 4-layer structural reconstruction technique, which includes LHB transfer to make an augmenting sling, 2-layer glenoid bone grafting mainly to amend glenoid bone defect, and capsule-labrum repair. The main indication of this 4-layer structural reconstruction is the requirement of both soft tissue sling augmentation at the anterior-inferior side of the shoulder and bone fragment

augmentation to amend the glenoid or stimulate labrum-glenoid remodeling (Table 1).

Surgical Technique

Patient Position, Portal Creation, and Arthroscopic Examination

General and brachial plexus anesthesia are administered. The patient is placed in the lateral decubitus position with the arm in 30° abduction and 10 pounds of traction. Routine posterior, inferior posterior, anterior, and anterosuperior portals are created.

Table 1. Indications and contraindications

Indications for 4-layer structural reconstruction
• Requirement of both soft tissue sling augmentation and bone fragment augmentation
Detailed indications for sling augmentation with the long head of the biceps
• Age <45 y
• Participation in competitive sports
• Requirement of forceful external rotation and abduction of the shoulder
• Capsule ligament deficiency
• Combined SLAP lesion
Contraindications for sling augmentation with the long head of the biceps
• Sling augmentation not required
• LHB cannot be used
Detailed indications for the bone fragment augmentation at the anterior glenoid
• Glenoid defect
• Requirement of osseous stimulation for labrum-glenoid remodeling
Contraindications for the bone fragment augmentation at the anterior glenoid
• Glenoid defect not existing and osseous stimulation not required.

From the Department of Sports Medicine (J.Z.) and Operating Theater (J.T.), Shanghai Sixth People's Hospital, Shanghai Jiao Tong University, Shanghai, China.

The authors report that they have no conflicts of interest in the authorship and publication of this article. Full ICMJE author disclosure forms are available for this article online, as [supplementary material](#).

Received May 16, 2020; accepted August 16, 2020.

Address correspondence to Jinzhong Zhao, M.D., Department of Sports Medicine, Shanghai Sixth People's Hospital, Shanghai Jiao Tong University, 600 Yishan Road, Shanghai 200233, China. E-mail: zhaojinzhong@vip.163.com or jz Zhao@sjtu.edu.cn

© 2020 by the Arthroscopy Association of North America. Published by Elsevier. This is an open access article under the CC BY-NC-ND license (<http://creativecommons.org/licenses/by-nc-nd/4.0/>).

2212-6287/20963

<https://doi.org/10.1016/j.eats.2020.08.022>

Table 2. Step-by-step procedure: 4-layer structural reconstruction for recurrent anterior shoulder dislocation

1. Prepare the 2 fragments (glenoid-surface and glenoid-neck grafts) used for glenoid grafting.
2. Ligate the LHB tendon with a suture and detach the LHB tendon from its superior glenoid insertion.
3. Extract the LHB tendon out of the joint, the bicipital groove, and the anterodistal portal sequentially.
4. Braid the LHB tendon and tie the tendon end to an adjustable loop with mini-plate to form an LHB complex.
5. Create a freshened bone strip at the anterior edge of the glenoid and release the capsule-labrum from the glenoid neck.
6. Drill 3 glenoid holes for suture anchors at 7, 8:30, and 10 o'clock positions (left shoulder).
7. Create a transverse transglenoid tunnel 7 mm below the glenoid surface.
8. Pass the LHB guide suture through the glenoid tunnel and the subscapularis.
9. Find the LHB guide suture at the anterior side of the subscapularis and pull it to the anterior superior portal.
10. Reroute the LHB complex and the guide suture through 1 cannula. Pull the LHB complex through the subscapularis into the glenoid tunnel with the guide suture.
11. Place the glenoid-neck graft to the anterior side of the glenoid, inferior to the LHB complex.
12. Place the 2 o'clock and 5 o'clock glenoid anchors.
13. Pull 1 suture limb from each of the 2 suture anchors out as guide sutures, and place the glenoid-surface graft.
14. Fix the graft with the guide sutures from the anchors.
15. Reduce the adjustable loop in the LHB complex and pull the LHB tendon fully into the glenoid tunnel.
16. Repair the capsule-labrum and close the rotator interval with the rest of the sutures from the 2 and 5 o'clock anchors and the 3:30 o'clock anchor.

Preparation of Bone Grafts

Two frozen dry biocortical iliac crest grafts, each 30 mm long, 10 mm wide, and 8 to 9 mm thick, are obtained to be placed at the glenoid surface (glenoid-surface graft) and the glenoid neck (glenoid-neck graft). Two 2-mm-wide holes placed ~15 mm apart are made through each graft along the midline of the surface. In the glenoid-neck graft, 2 absorbable sutures are put through the holes (Table 2).

Detaching, Extracting, and Braiding the LHB

Under observation from the posterior portal, a folded no. 2 PE suture is passed through the intraarticular part of the LHB tendon to ligate it. The LHB tendon is cut close to its glenoid insertion (Fig 1A, B; Video 1).

The arthroscope is placed in the anterior subdeltoid space via the anterosuperior portal. A far anterolateral portal, which is located 7 cm distal to the lateral edge of the acromion and 2 cm anterior to the lateral midline of

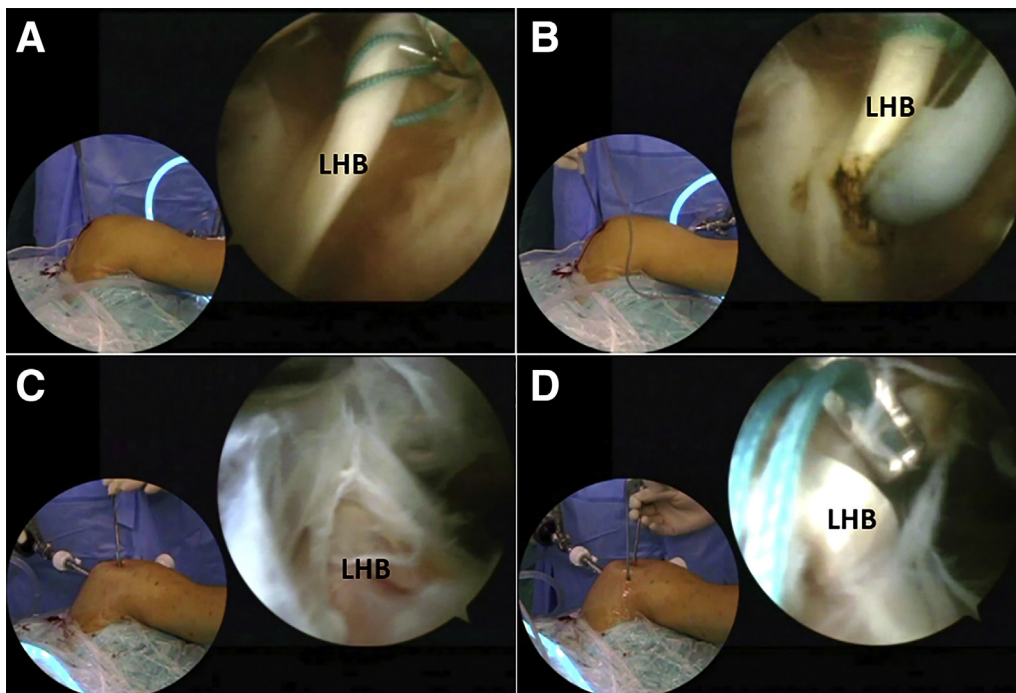
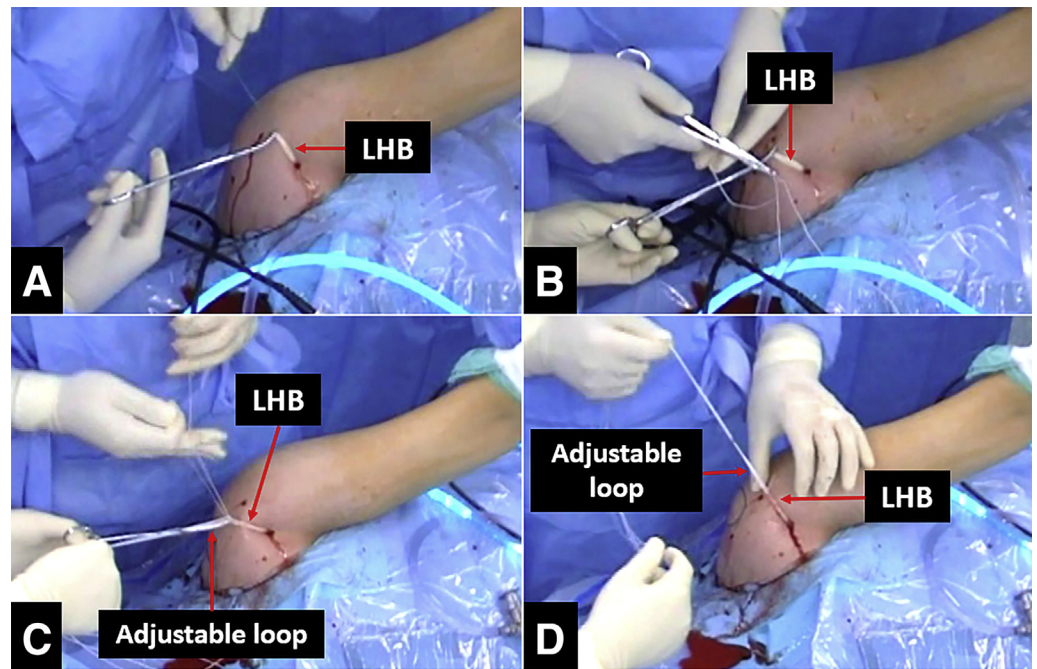


Fig 1. Detachment and extraarticular retrieval of the long head of the biceps (LHB) tendon. Intra-articular view of left shoulder in lateral decubitus position through anterior superior portal. (A) The LHB is ligated with a nonabsorbable suture. (A) The LHB is detached from its glenoid insertion. Anterolateral subdeltoid view of left shoulder in lateral decubitus position through far lateral portal. (C) The LHB is found at the superior edge of the pectoralis major insertion. (D) The LHB is retrieved out of the bicipital groove.

Fig 2. Preparation of the complex of the long head of the biceps (LHB) tendon (left shoulder in lateral decubitus position). (A) The LHB is pulled out through the far anterior portal. (B) The LHB is braided with three no. 2 UHMWPE sutures in a whipstitch style. (C) The braiding sutures are tied to an adjustable loop with mini-plate. (D) An LHB complex is formed by the set of adjustable loop and LHB attached.



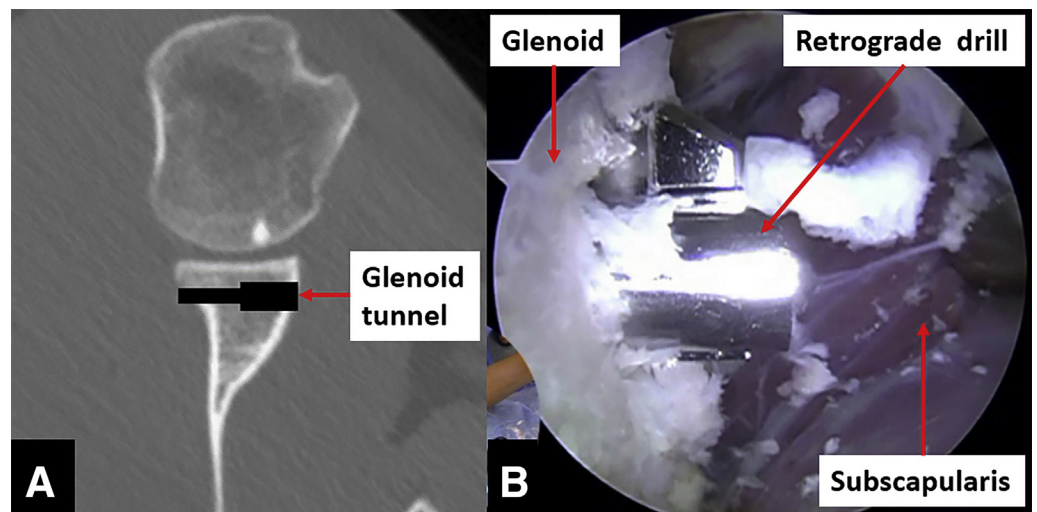
the upper arm, is created. Via the far anterolateral portal, the LHB tendon is detected at the superior edge of the pectoralis major (Fig 1C). A far anterior portal, which is located at the anterior route of the LHB and 2 to 3 cm distal to the proximal edge of the pectoralis major, is created. The LHB tendon is retrieved out of the joint and bicipital groove to the anterior subdeltoid space (Fig 1D), and then out of the far anterior portal. Three no. 2 UHMWPE sutures (Smith & Nephew, Andover, MA) are used to braid the LHB tendon in a

whipstitch style and tie to an adjustable loop with a mini-plate (Arthrex, Naples, FL) to form an LHB complex (Fig 2).

Predrilling in the Glenoid for Suture Anchors

A strip of bone bed with a width of 3 to 5 mm is created at the anterior edge of the glenoid (right shoulder). The capsule-labrum complex is released and elevated to a plane higher than the glenoid surface. Three holes for suture anchors are drilled at the

Fig 3. Creation of the transverse trans-glenoid tunnel. (A) Illustration. (B) Intra-articular view of left shoulder in lateral decubitus position through anterior superior portal.



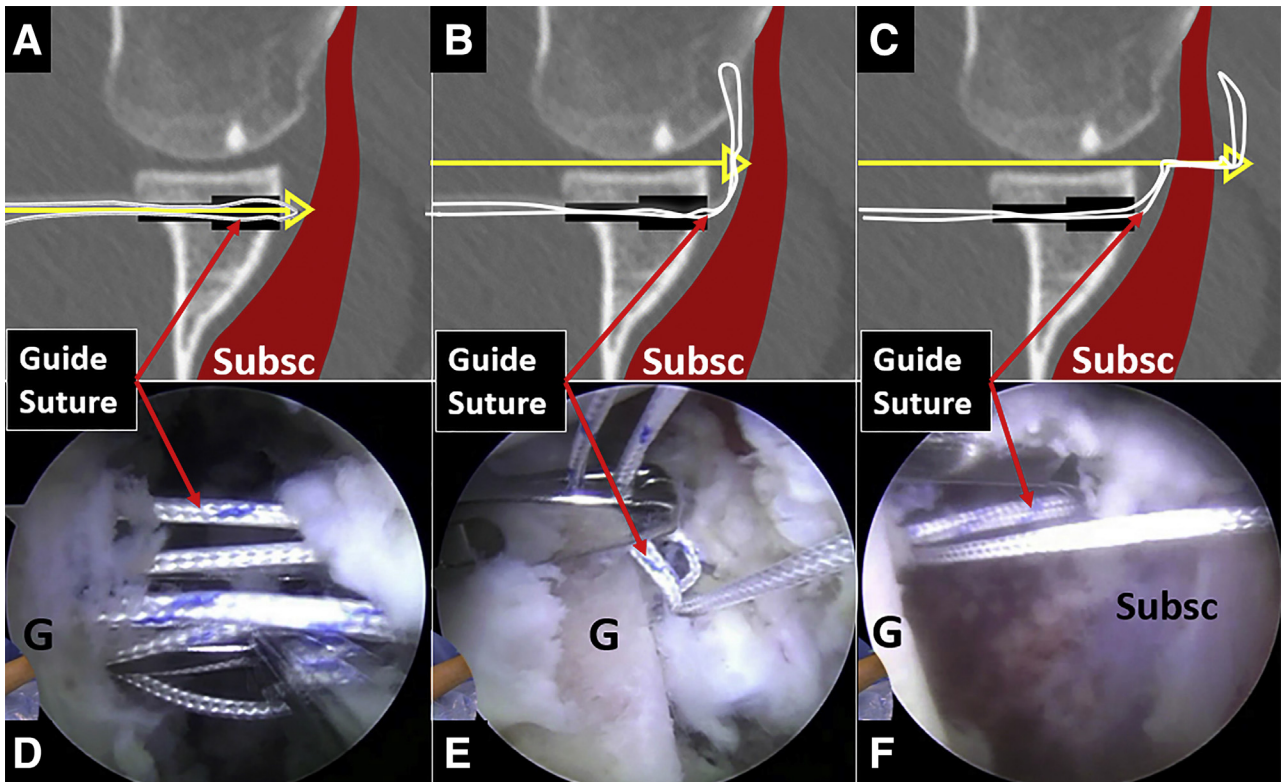


Fig 4. Passing the guide suture through the glenoid tunnel and the subscapularis. Intra-articular view of left shoulder in lateral decubitus position through anterior superior portal. (A and D) Passing the guide suture through the glenoid tunnel to the anterior side of the glenoid. (B and E) Holding the guide suture through the glenohumeral space. (C and F) Passing the guide suture through the subscapularis along the glenoid surface. Abbreviations: G, glenoid; Subsc, subscapularis.

anterior edge of the glenoid at 7, 8:30, and 10 o'clock positions.

Creating a Glenoid Tunnel

Under observation through the anterior superior portal, a customized glenoid-tunnel guide is placed in the joint through the posterior portal. A transverse transglenoid tunnel, which routes from the 2 to 4 o'clock position to the 8 to 9 o'clock position (left shoulder) and centers 7 mm inferior to the glenoid

surface, is created sequentially with a 2.5-mm Kirschner wire, 4.5-mm cannulated drill, and retrograde drill (Arthrex). The length of the enlarged anterior part of the tunnel is 10 mm (Fig 3).

Placement of the Guide Sutures for the LHB Complex Through the Glenoid Tunnel and the Subscapularis

Under observation through the anterior superior portal, one folded No. 2 UHMWPE suture, which will be

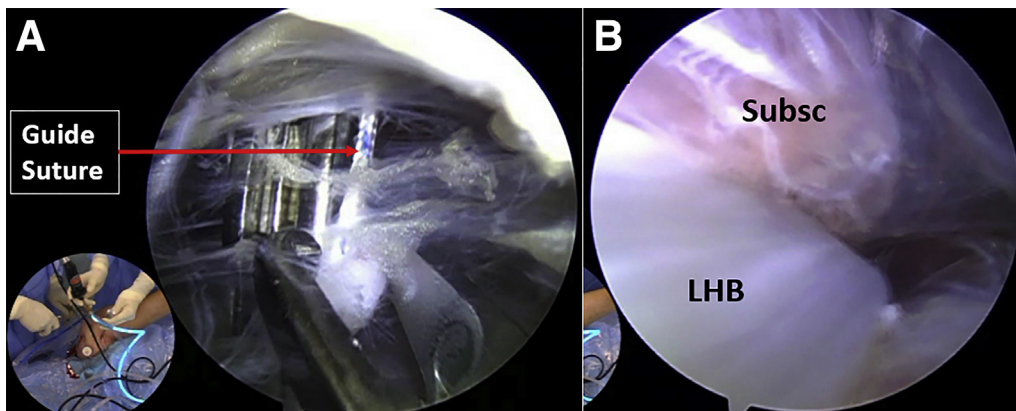
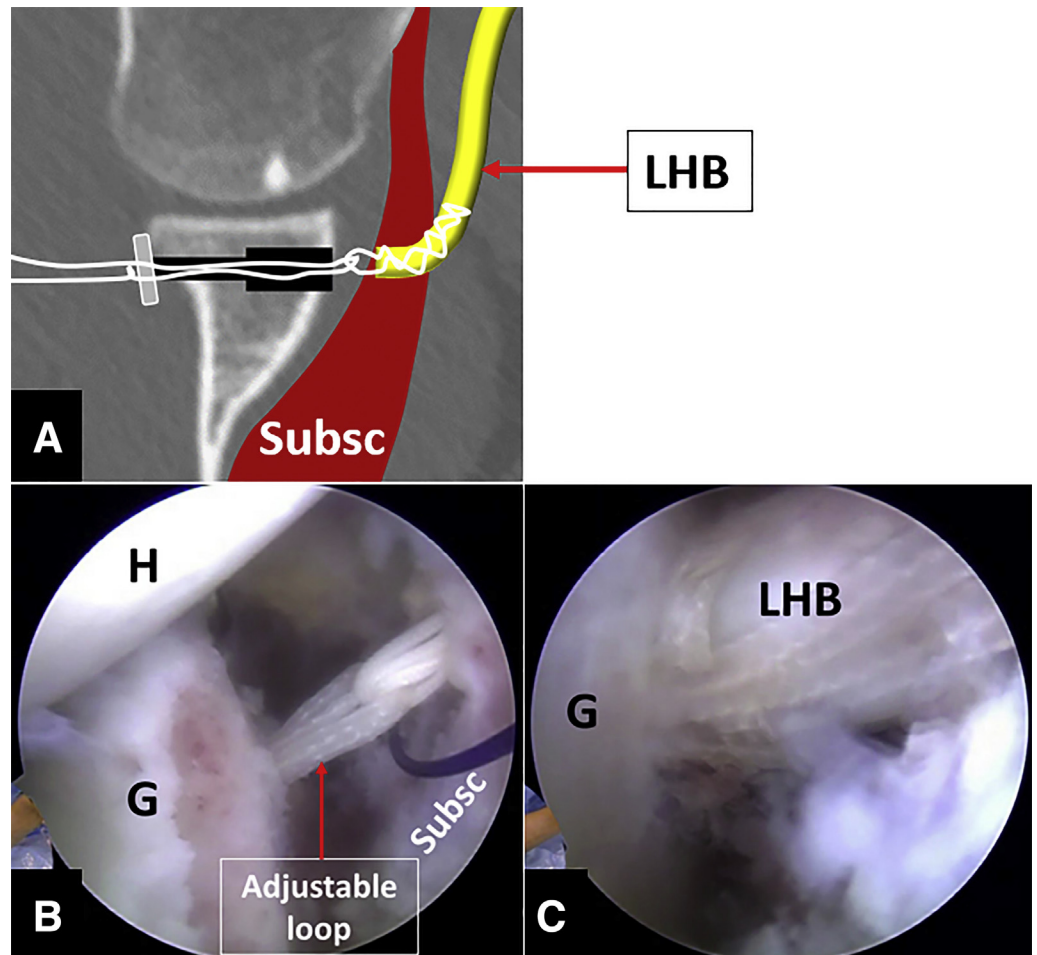


Fig 5. Finding the guide suture at the anterior side of the subscapularis (A) and pulling the long head of the biceps (LHB) tendon through the subscapularis (B). View in lateral decubitus position at the anterior side of the subscapularis through the far lateral portal. Abbreviation: Subsc, subscapularis.

Fig 6. Pulling the complex of the long head of the biceps (LHB) tendon through the glenoid tunnel. (A) The mini-plate in the LHB complex is out of the posterior orifice of the glenoid tunnel and flipped. Intra-articular views of left shoulder in lateral decubitus position through anterior superior portal. (B) Check the adjustable loop at the anterior side of the glenoid. (C) The LHB is checked to ensure it can be pulled into the glenoid tunnel. Abbreviation: Subsc, subscapularis.



used as a guide suture (LHB-complex guide suture), is passed through the glenoid tunnel from posterior to anterior side, held with a suture retriever in the joint,

and passed anteriorly through the subscapularis along the glenoid surface at the 7:30 position (Fig 4).

Finding the Guide Suture at the Anterior Side of the Subscapularis

The arthroscope is placed through the far anterolateral portal to the anterior subdeltoid space. A switching stick is placed through the far anterior portal to elevate the conjoined tendon from the subscapularis. The scope is pushed along the anterior side of the subscapularis in an inferior-medial direction. The LHB-complex guide suture that passed through the subscapularis is found (Fig 5A) and pulled out of the anterior superior portal.

Passing the LHB Complex Through the Subscapularis into the Glenoid Tunnel, Completing the Second-Layer Reconstruction

The sutures from the LHB complex and the LHB-complex guide suture are rerouted through the same cannula. With the guide suture, the LHB complex is pulled through the subscapularis (Fig 5B) into the

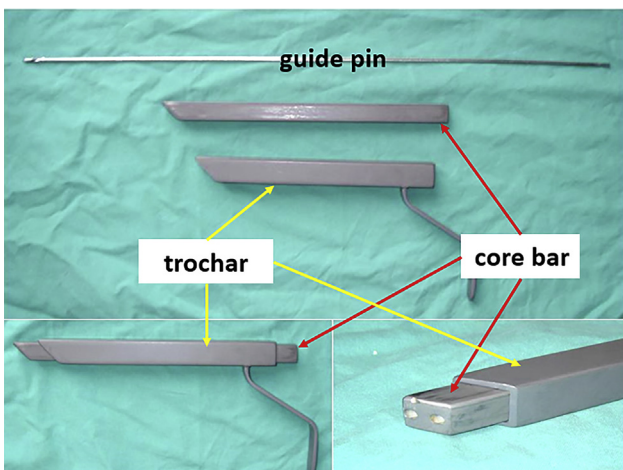


Fig 7. The shoulder bone grafting instrument set.

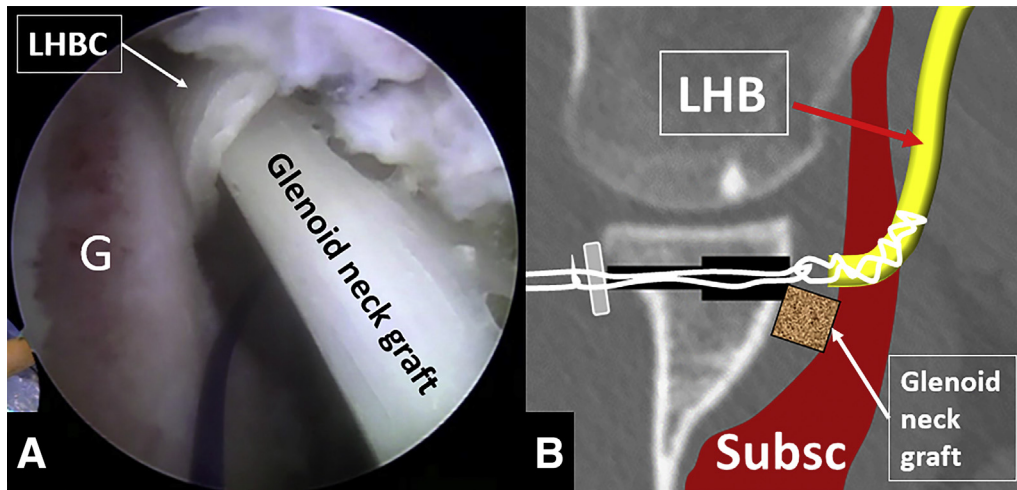


Fig 8. Placing the glenoid-neck graft to the anterior side of the glenoid, inferior to the complex of the long head of the biceps (LHB) tendon. Intra-articular view of left shoulder in lateral decubitus position through anterior superior portal. Abbreviations: G, glenoid; LHBC, LHB complex; Subsc, subscapularis.

glenoid tunnel, until the mini-plate is out of the posterior orifice of the glenoid tunnel and flipped. The LHB complex is checked intra-articularly to make sure the LHB can be pulled into the glenoid tunnel (Fig 6).

Implantation of Glenoid-Neck Graft, Completing the First-Layer Reconstruction

One bone-grafting guide suture is passed through the inferior capsule-labrum at 7 o'clock position and the inferior side of the LHB complex for placement of the

glenoid-neck graft. Another guide suture for later labrum repair is passed through the inferior capsule-labrum at 6 o'clock position.

A set of glenoid bone-grafting instruments is placed through the anterior portal (Fig 7). The bone-grafting guide suture limb is retrieved through the bone-grafting trocar. The glenoid-neck graft is pulled in with the bone-grafting guide suture and placed to the anterior side of the glenoid, inferior to the LHB complex, as parallel as possible to the glenoid surface (Fig 8; Fig 9A).

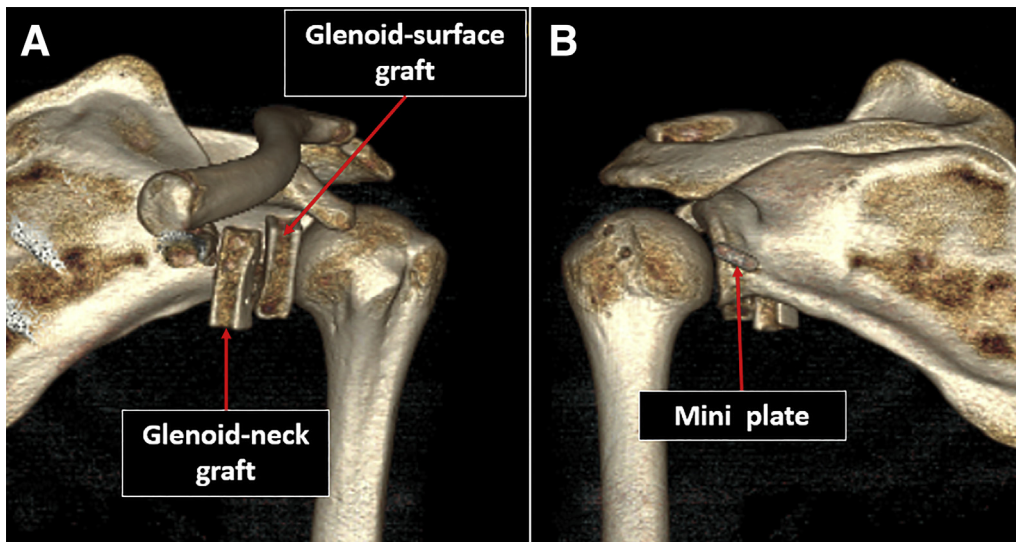


Fig 9. Computerized tomography images after 4-layer structural reconstruction of the anterior shoulder (left shoulder). (A) Anterior view showing the positions of the 2 bone grafts. (B) Posterior view showing the position of the mini-plate.

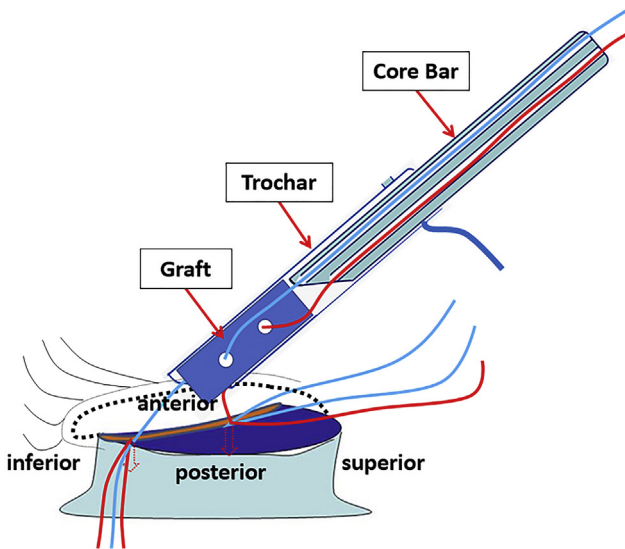


Fig 10. Illustration of glenoid bone grafting with the shoulder bone grafting instrument set.

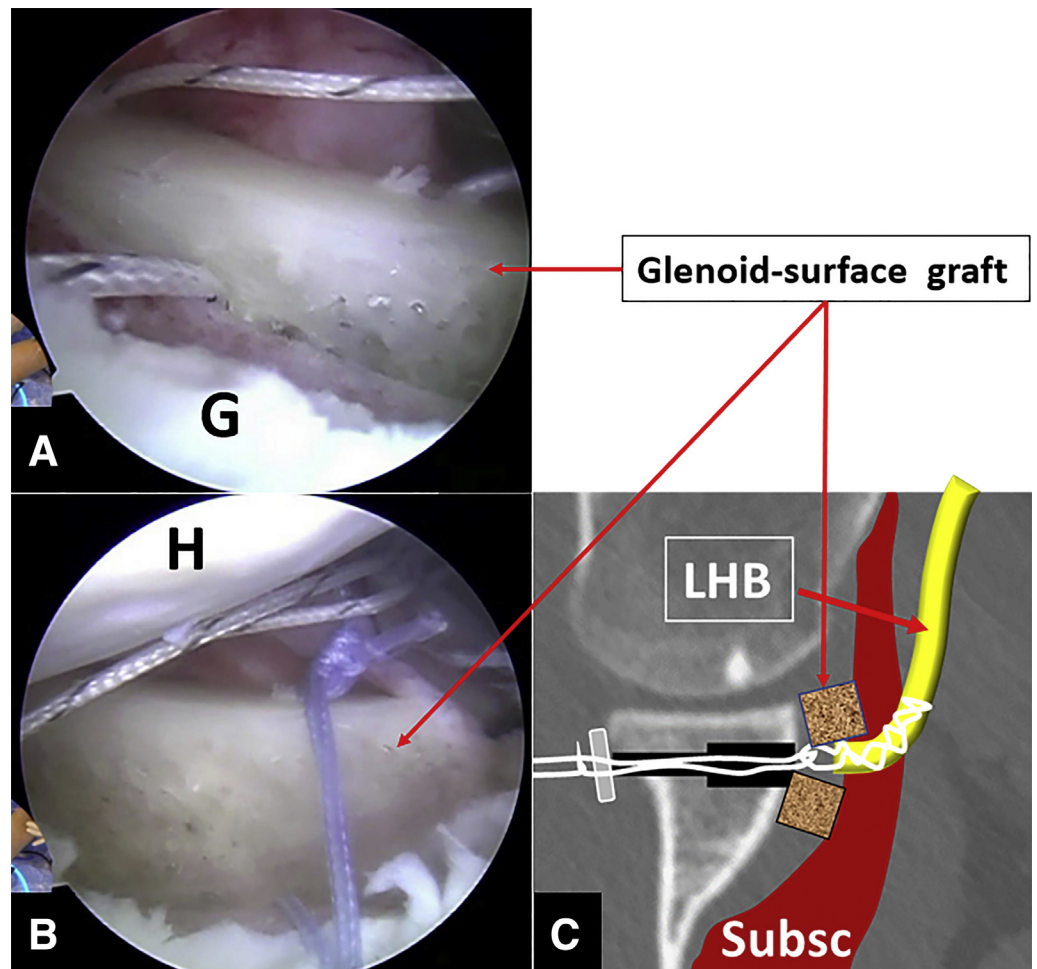
Implantation of Glenoid-Surface Graft, Completing the Third-Layer Reconstruction

The 7 and 10 o'clock anchors are placed. One suture limb from each of the 2 anchors is retrieved out of the joint through the trocar and put through the holes in the graft and the trocar sequentially. With tension kept on the sutures, the graft is pushed with the core bar through the trocar (Fig 10) into the joint to the anterior side of the glenoid, above the LHB complex. The suture limbs passing through the bone fragment are tied to their corresponding suture limbs to hold the bone fragment softly, with the surface of the bone graft parallel and level abreast of the glenoid surface (Fig 9A; Fig 11).

Capsule-Labrum Repair and Rotator Interval Closing, Completing the Fourth-Layer Reconstruction

The capsule-labrum structure is pulled over the bone fragment and attached to the glenoid bone strap, with the help of the prelaidd labrum-repairing

Fig 11. Placing the glenoid-surface graft to the anterior side of the glenoid, superior to the complex of the long head of the biceps (LHB) tendon. Intra-articular views of left shoulder in lateral decubitus position through anterior superior portal. (A) Graft placement. (B) Graft fixation with suture. (C) Positions of both the glenoid-neck graft and the glenoid-surface graft. Abbreviations: G, glenoid; H, humeral head; LHBC, LHB complex; Subsc, subscapularis.



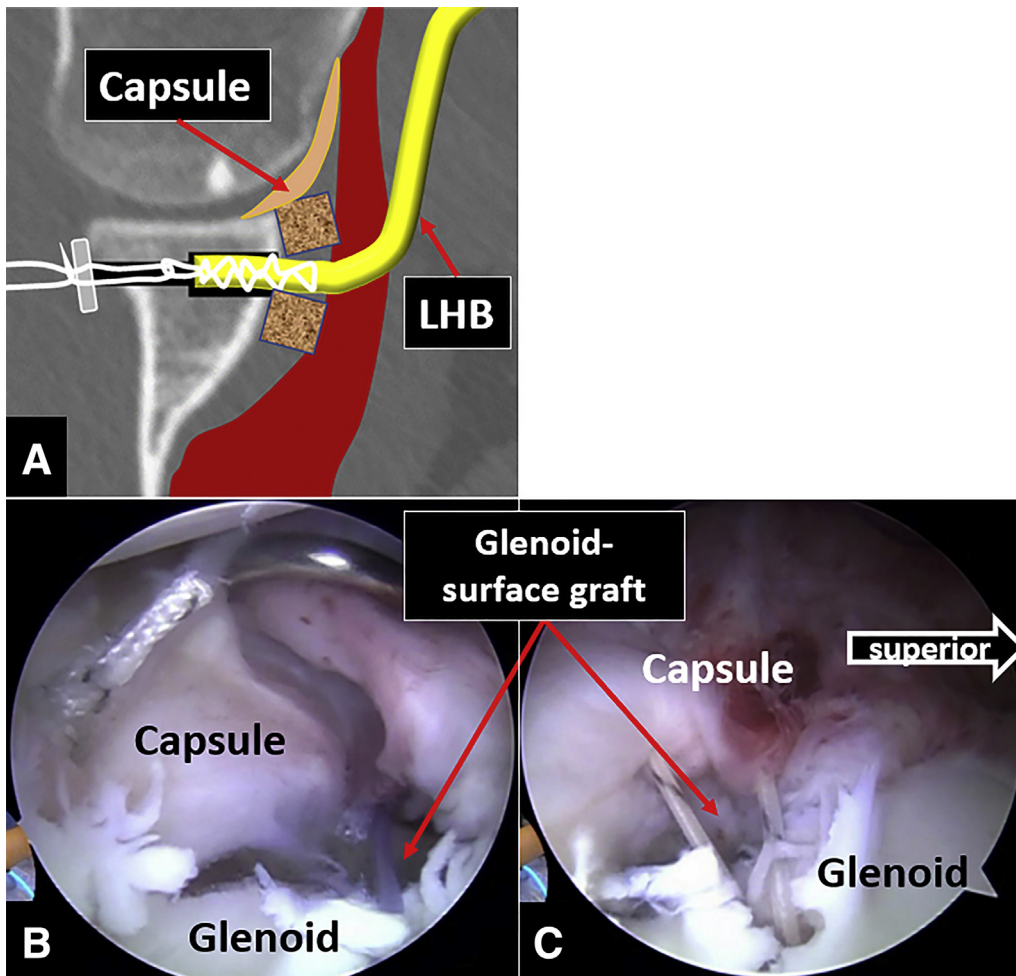


Fig 12. Repairing the capsule labrum to the glenoid and sealing the glenohumeral joint. (A) Pulling the long head of the biceps (LHB) tendon fully into the glenoid tunnel and attaching the capsule labrum to the glenoid. Intra-articular views of left shoulder in lateral decubitus position through anterior superior portal. (B) Repairing the inferior part of the capsule labrum. (C) Repairing the superior part of the capsule labrum and close the rotator interval.

guide suture at the 6 o'clock position and the unused suture from the 7 o'clock position anchor. The adjustable loop is reduced to pull the LHB fully into the glenoid tunnel (Fig 12A). The 3:30 anchor is

placed, and subsequent capsule-labrum repair is performed. Rotator interval is finally closed using the left suture from the 2 o'clock anchor (Fig 12B, C; Fig 13).

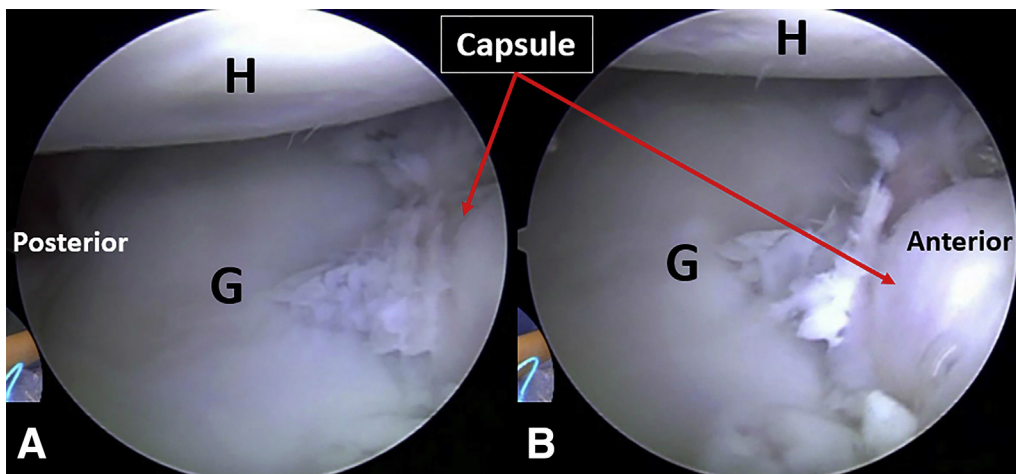
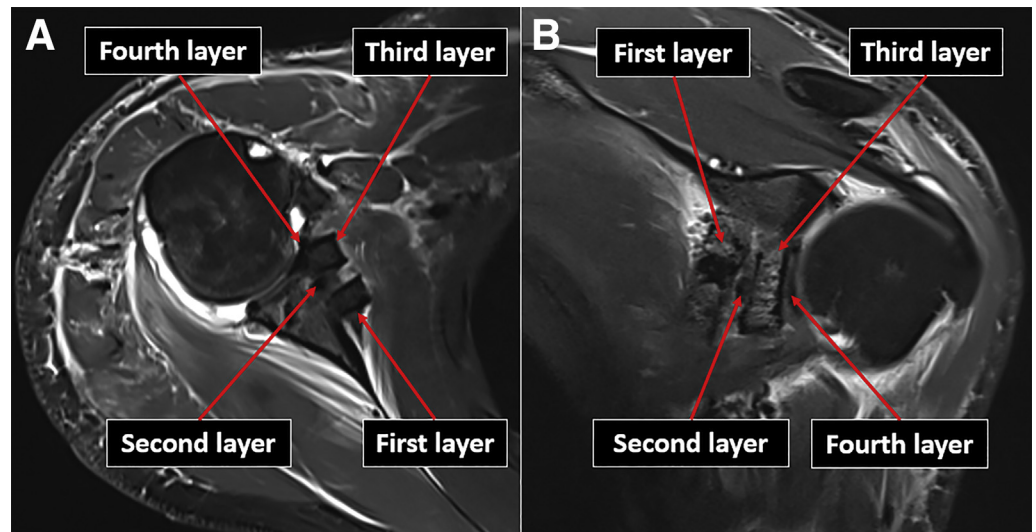


Fig 13. Intra-articular view of left shoulder in lateral decubitus position after capsule labrum repair. (A) The humeral head is centered to the glenoid. (B) The bulk anterior stabilizing structure. Abbreviations: G, glenoid; H, humeral head.

Fig 14. The reconstructed 4-layer structure in magnetic resonance imaging. Left shoulder. (A) Transverse view. B, Oblique sagittal view. First layer, the glenoid-neck bone graft. Second layer, the transferred long head of the biceps tendon. Third layer, the glenoid surface graft. Fourth layer, the repaired capsule labrum.



Rehabilitation

The shoulder is immobilized in a brace in 15° external rotation for 6 weeks. Active range of motion exercises and muscle strengthening begin at 6 weeks. Contact sports are allowed 3 months postoperatively.

Discussion

This 4-layer structural reconstruction (Fig 14) for recurrent anterior shoulder dislocation is a routine technique performed in our clinical practice,

Table 3. Pearls and pitfalls

- This technique is combination of 3 basic procedures, the LHB transfer, double-layer glenoid bone grafting and capsule-labrum repair. One must master these 3 basic procedures first before proceeding to this combined procedure.
- The LHB should be fully detached from the superior glenoid to facilitate later tendon extraction, otherwise forceful extraction in case of proximal connection will result in tendon rupture.
- A freshened bone strip must be created at the anterior edge of the glenoid to facilitate healing of the reattached capsule labrum to the glenoid.
- The capsule labrum must be fully released for later shifting across the bone graft to the glenoid edge.
- In case of an intact labrum-periosteum ring, such as in anterior labrum periosteum sleeve avulsion, the ring is broken at the 11 o'clock position (left shoulder) to facilitate later graft implantation.
- The transglenoid tunnel should not be too close to the glenoid surface, or the glenoid-surface graft will protrude.
- The guide suture should be passed through the subscapularis along the glenoid surface, instead of directly through the glenoid tunnel; otherwise, the anterior exit of the delivering instrument will be medial to and endanger the axillary nerve.
- Before placing the glenoid grafts, check that there is enough space to accommodate the grafts. Enlarge the space if necessary.
 - The LHB complex should be tightened after the graft placement. Early tightening will hinder graft placement.
 - The rotator interval should be closed to seal the joint; otherwise, the bone grafts may be exposed to synovial fluid and healing may be hindered.

considering that most of our young and active patients need sling augmentation,^{4,5} that every patient needs osseous stimulation by glenoid bone grafting for better glenoid remodeling,⁶ and that capsule-labrum repair is critical to ensure capsule-labrum connection to the glenoid and seal the glenohumeral joint.

This 4-layer structural reconstruction technique is somewhat time-consuming: 90 to 120 minutes in our clinical practice. Regarding the learning curve, although it is quite easy to master the glenoid bone grafting procedure, the learning curve of LHB transfer is little bit steeper. Nevertheless, the arthroscopic LHB transfer in this procedure is much simpler than the arthroscopic Latarjet procedure.^{7,8}

The pearls and pitfalls of this 4-layer structural reconstruction technique are illustrated in Table 3. The most important points in performing this procedure include creation of a suitable glenoid tunnel, appropriate penetration of the subscapularis with the

Table 4. Advantages and disadvantages

Advantages

- This technique addresses all structural deficiencies in anterior shoulder.
- Transfer of the long head of the biceps is much easier than transfer of the coracoid process.
- Glenoid bone grafting with soft fixation is easier to perform than hardware or firm fixation.

Disadvantages

- The learning curve of this technique is relatively steep, especially for those who are not familiar with manipulation at the anterior side of the subscapularis.
- This procedure is time-consuming.
- The axillary nerve may be endangered during manipulation at the anterior side of the subscapularis.
- Glenoid bone grafting with allografts may increase the rate of infection.

delivering instrument and the guide suture, reliable fixation of the transferred LHB, and proper placement of the 2 bone grafts. The main disadvantage of this technique is that it is time-consuming compared with isolated capsule labrum repair (Table 4).

Acknowledgments

Funded by the National Natural Science Foundation of China (grants 31972923 and 81772341).

References

1. Cowling PD, Akhtar MA, Liow RY. What is a Bristow-Latarjet procedure? A review of the described operative techniques and outcomes. *Bone Joint J* 2016;98-B:1208-1214.
2. van der Linde JA, van Wijngaarden R, Somford MP, van Deurzen DF, van den Bekerom MP. The Bristow-Latarjet procedure, a historical note on a technique in comeback. *Knee Surg Sports Traumatol Arthrosc* 2016;24:470-478.
3. Willemot L, De Boey S, Van Tongel A, Declercq G, De Wilde L, Verborgt O. Analysis of failures after the Bristow-Latarjet procedure for recurrent shoulder instability. *Int Orthop* 2019;43:1899-1907.
4. Bokshan SL, Gil JA, DeFroda SF, Badida R, Crisco JJ, Owens BD. Biomechanical comparison of the long head of the biceps tendon versus conjoint tendon transfer in a bone loss shoulder instability model. *Orthop J Sports Med* 2019;7. 2325967119883549.
5. Tang J, Zhao J. Arthroscopic transfer of the long head of the biceps brachii for anterior shoulder instability. *Arthrosc Tech* 2017;6:e1911-e1917.
6. Zhao J, Huangfu X, Yang X, Xie G, Xu C. Arthroscopic glenoid bone grafting with nonrigid fixation for anterior shoulder instability: 52 patients with 2- to 5-year follow-up. *Am J Sports Med* 2014;42:831-839.
7. Ekhtiari S, Horner NS, Bedi A, Ayeni OR, Khan M. The learning curve for the Latarjet procedure: A systematic review. *Orthop J Sports Med* 2018;6. 2325967118786930.
8. Domos P, Lunini E, Walch G. Contraindications and complications of the Latarjet procedure. *Shoulder Elbow* 2018;10:15-24.