

Spontaneous internal hemorrhage of a giant hepatic hemangioma

A case report

Fulong Hao, MS^{a,*}, Xiaoli Yang, MS^a, Yinsheng Tian, BS^a, Wenping Wang, MS^b, Minggang Ge, MS^a

Abstract

Rationale: Hepatic hemangioma, a benign liver tumor, can rarely spontaneously rupture and hemorrhage, which is then associated with significant mortality. The diagnosis of internal hemorrhage is challenging and the management is disputed.

Patient concerns: We describe the case of a 52-year-old female patient with chief complaints of fever and anemia, with no history of recent trauma.

Diagnoses: Ultrasound suggested the possibility of a liver abscess and computed tomography (CT) examination revealed a giant space occupying lesion (SOL) (approximately 16 cm) in the right hepatic lobe, indicating a hepatic tumor or abscess. The patient did not respond to antibiotics and blood transfusion. Liver needle biopsy revealed blood clots suggestive of intratumoral hemorrhage, possibly of a hepatic hemangioma.

Interventions: Interventional radiologic approach revealed active bleeding at the phrenic artery that supplied the liver SOL. Thus, embolization was performed and re-angiography showed no active bleeding from the embolized vessel. The patient became afebrile, but fever recurred the next day. Hence, an exploratory open right hemihepatectomy was undertaken and the intraoperative frozen biopsy confirmed hepatic hemangioma with internal hemorrhage, but malignancy could not be excluded for some focal tissues. Postoperative pathology report confirmed the diagnosis of hepatic hemangioma with internal hemorrhage and excluded malignancy.

Outcomes: The fever subsided and the patient was discharged in good health. A follow-up CT performed three months, postoperatively, indicated compensatory growth of the left hepatic lobe.

Lessons: This case demonstrates that the diagnosis of hepatic hemangioma with internal hemorrhage can be confirmed by needle biopsy and surgical resection is the optimal treatment for such a lesion.

Abbreviations: CT = computed tomography, DR = digital radiography, Hb = hemoglobin, SOL = space occupying lesion.

Keywords: hepatic hemangioma, internal hemorrhage, spontaneous rupture

1. Introduction

Hepatic hemangioma is the most common type of benign liver tumor, with the larger tumors being cavernous hemangiomas,^[1,2] and rarely transform into malignancies.^[3] Although the reported incidence of hepatic hemangioma with ruptured bleeding was found to be low (1–4%),^[4] the mortality is rather high (36–39%).^[5] Meanwhile, the incidence of a hepatic hemangioma with internal hemorrhage is even rarer, with only sporadic cases reported to date^[6]; therefore, there are limited experiences that we can refer to for their management. Surgical treatment is the

predominant therapeutic approach for a hepatic hemangioma with ruptured bleeding^[7] but there are certain risks involved.^[8] Recently, it was reported that interventional embolization can improve or even control hepatic hemangioma with ruptured bleeding, which may avoid or prepare for further surgical treatment^[9]; however, the therapeutic efficacy is still unclear.^[10] In the current report, we describe the findings and management approaches in a female patient with a giant liver space occupying lesion (SOL), confirmed as internal hemorrhage of the lesion via liver needle biopsy. She was managed by 2 interventions—initial embolization of the feeder vessel, and surgical resection undertaken later finally resolved her symptoms and cured the patient.

Editor: N/A.

The patient agreed to share her case and provided written informed consent.

The authors have no funding and conflicts of interest to disclose.

^aDepartment of Hepatobiliary Surgery, Suining Central Hospital, ^bDepartment of Infectious Diseases, Suining Central Hospital, Suining, Sichuan, China.

*Correspondence: Fulong Hao, Department of Hepatobiliary Surgery, Suining Central Hospital, Suining, Sichuan 629000, China (e-mail: 583474616@qq.com).

Copyright © 2017 the Author(s). Published by Wolters Kluwer Health, Inc. This is an open access article distributed under the terms of the Creative Commons Attribution-Non Commercial-No Derivatives License 4.0 (CCBY-NC-ND), where it is permissible to download and share the work provided it is properly cited. The work cannot be changed in any way or used commercially without permission from the journal.

Medicine (2017) 96:47(e8702)

Received: 14 September 2017 / Received in final form: 26 October 2017 /

Accepted: 27 October 2017

<http://dx.doi.org/10.1097/MD.00000000000008702>

2. Case report

A 52-year-old female was admitted on October 24, 2016 with a chief complaint of “fever for over 20 days.” She provided a negative history for any medical condition (including hepatitis), recent trauma, or oral contraceptive use. Twenty days prior to the admission, the patient suffered from chills and fever with no obvious cause, with a body temperature between 38.5 and 39.0°C. The fever usually began from the afternoon, every day, with all the other vital signs remaining stable. Physical examination indicated no abdominal pain, distension, or tenderness, and no percussion pain in the hepatic area. Color Doppler ultrasound had been done elsewhere and showed a 15 × 13 cm area of nonhomogeneous echo in the right hepatic lobe; the area was unclearly demarcated from the nearby tissues, showed

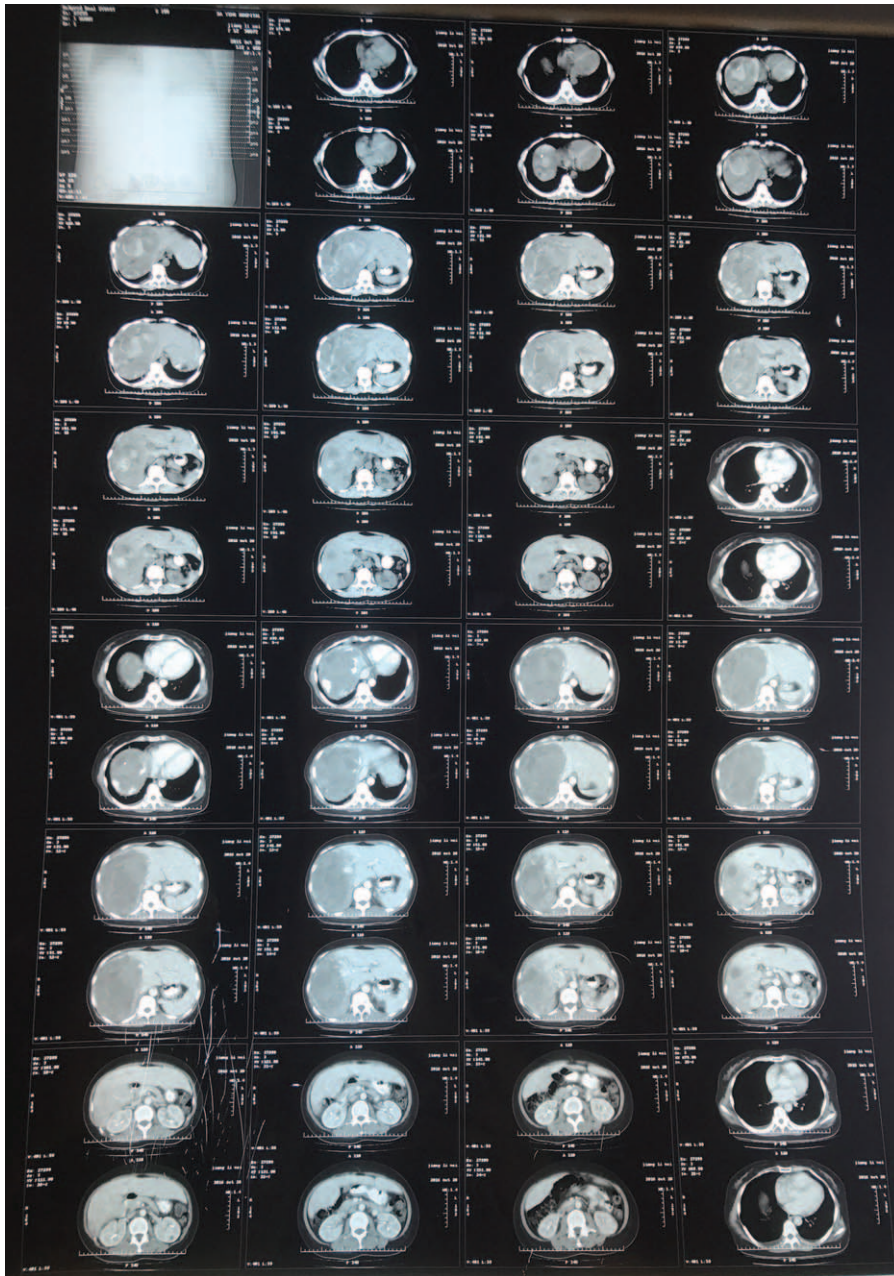

Figure 1. Preoperative computed tomography.

no clear capsule, and contained a few liquefied spots; thus, the possibility of a liver abscess was considered. Computed tomography (CT) examination revealed a 16×12 cm mass with mixed densities in the right hepatic lobe (Fig. 1), irregular enhancement during the arterial phase (Fig. 2), and no significant changes during the balance and delayed phase (Fig. 3). Laboratory testing results showed a hemoglobin (Hb) level of 6.3 g/L, a neutrophil percentage of 86.8, a normal total white blood cell count, normal hepatic function, no history of hepatitis B, and a normal alpha fetoprotein level. We believed that anemia was a result of the fever in a patient with liver abscess. However, after the administration of antibiotic treatment, there was no improvement of fever (Fig. 4). Although blood transfusion was

provided, the anemia was not resolved. Ultrasound-guided liver needle biopsy tissue specimens were blood clots. Based on the biopsy results, we considered a diagnosis of intratumoral hemorrhage. Since the lesion was huge (involving the secondary porta hepatis) and the duration of fever and anemia was long, we presumed direct surgery might pose a great risk and we decided to adopt a relatively less invasive interventional therapy first after deliberations with colleagues.

2.1. Interventional therapy

Five days after hospital admission, we performed the intervention therapy. The hepatic arteriography indicated a

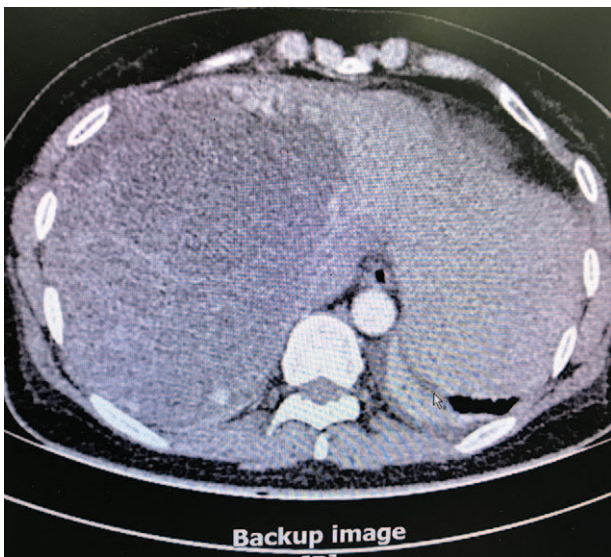


Figure 2. Preoperative computed tomography arterial phase.

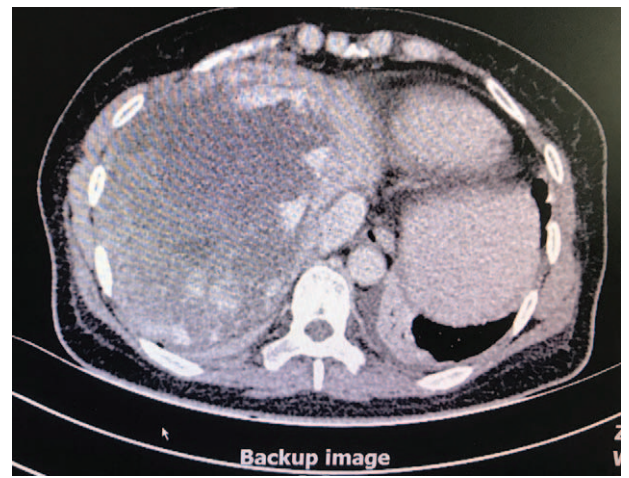


Figure 3. Preoperative computed tomography venous phase.

giant SOL in the right hepatic lobe supplied by the right phrenic artery. Obvious contrast agent overflow was observed around the phrenic artery after angiography (Fig. 5); thus, a possibility of ruptured bleeding of the phrenic artery was considered and coil embolization was performed. Reangiography indicated no obvious contrast agent outflow (Fig. 6). Patients were administered with routine postoperative treatments and no

fever occurred on the day of the surgery. On day 1, postoperatively, the peak body temperature was 37.5°C and the Hb level rose to 8.1g/L; however, on day 3, her body temperature increased to 39.0°C. Following a 2-day period of steady body temperature, her body temperature again rose to around 39.0°C (Fig. 7) and Hb level also gradually decreased and was maintained at about 7.4g/L. After consultation with colleagues, we concluded that the interventional embolization was incomplete and a vascular recanalization was likely to occur; therefore, we had to consider surgical treatment.

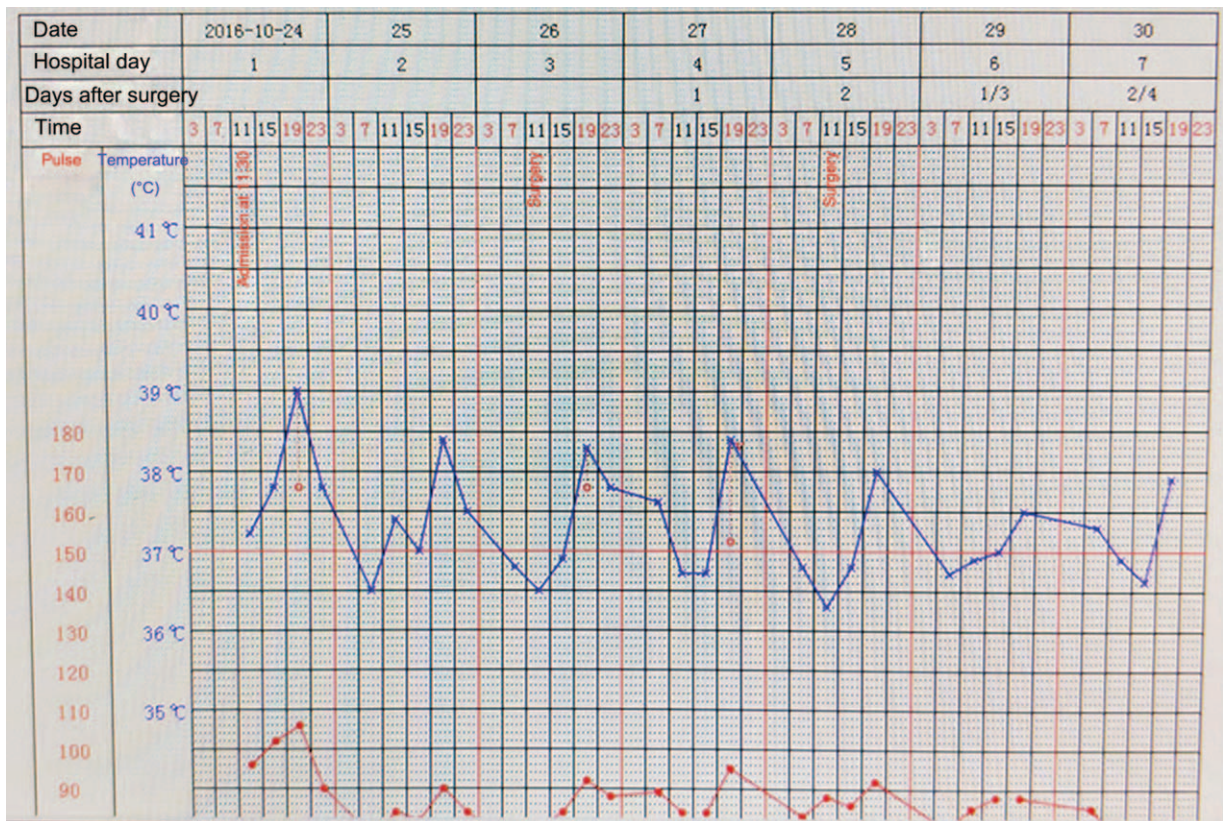


Figure 4. Body temperature before surgery.

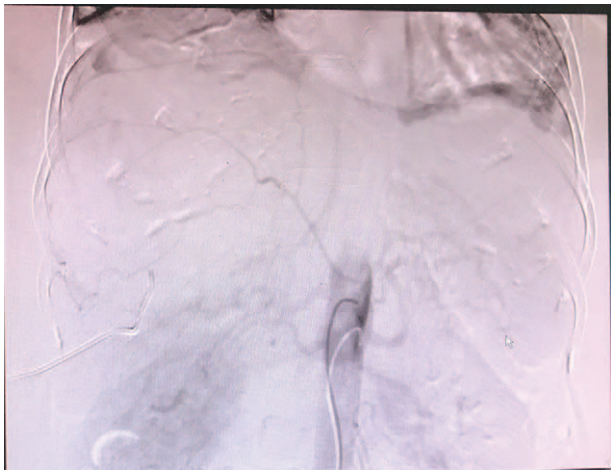


Figure 5. DR before embolism.

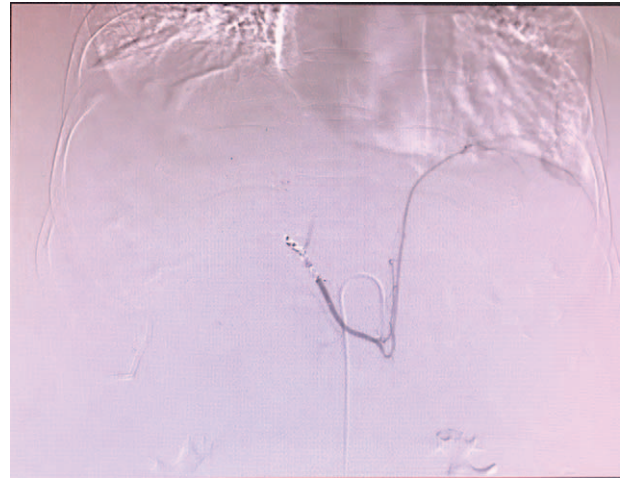


Figure 6. DR after embolism.

2.2. Surgical treatment

On November 21, 2016, we performed the surgical exploration. An experienced surgeon conducted the procedure under general anesthesia with tracheal intubation. A 15-cm oblique subcostal incision was made along the right rib and the abdominal cavity was opened in a layer-by-layer manner. The abdominal findings

indicated no effusion or hemorrhage in the abdominal cavity and a giant mass in the right hepatic lobe (approximately 16 × 10 cm), mainly located at segments VII and VIII and involved the majority of segments V and VI (Couinaud classification) was observed. Local texture of the mass that occupied nearly the entire right hepatic lobe was rather hard and the surface was grey in color. No obvious exudation or adhesion was seen at the

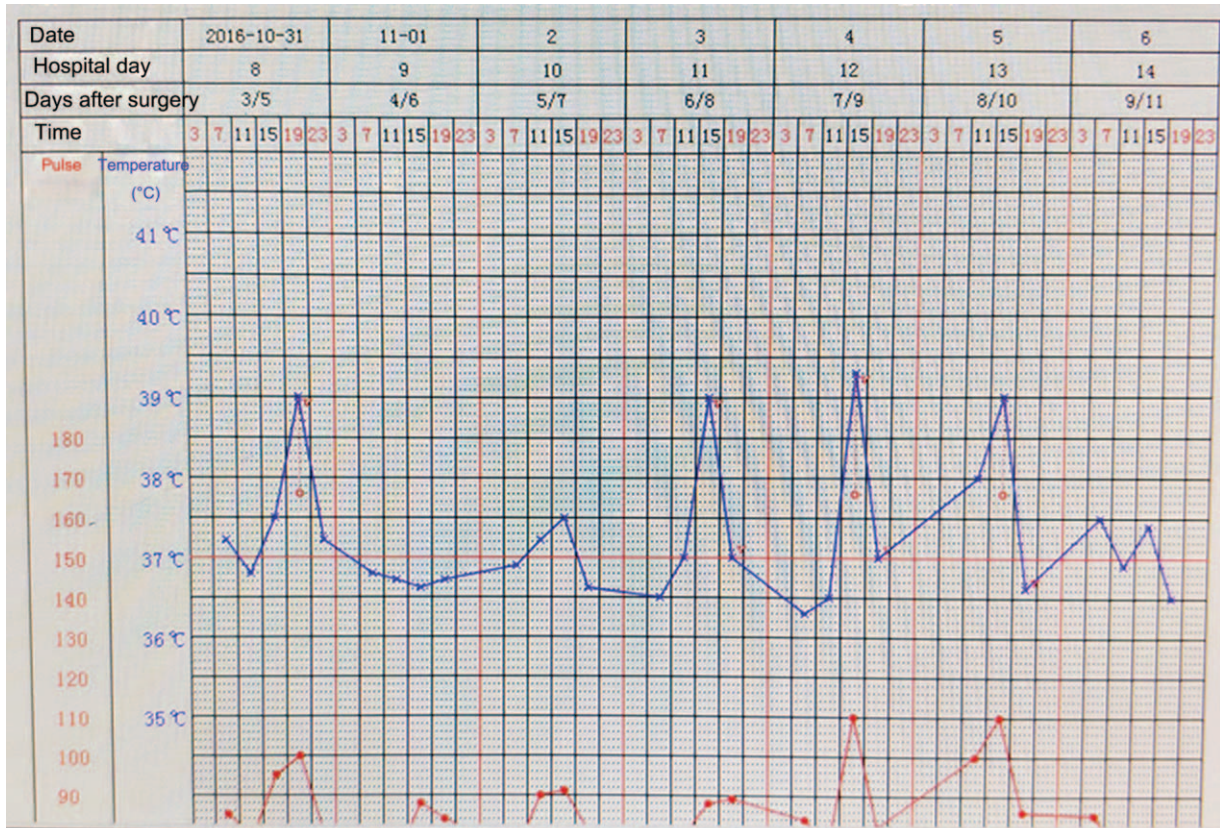


Figure 7. Body temperature report after intervention.

Intraoperative frozen slice report

Name: JLM
Gender: female
Age: 52Y
Department: Digestive Center 2nd Region
Bed number: 10
Hospital number: 16078288
Acquisition time: November 12, 2016 12:10
Lesions: Right Liver, Gallbladder

Pathological diagnosis results:

1. Huge cavernous hemangioma found in the right liver. As the tumor is huge, it need to be widely drawn through paraffin sections, in order to confirm whether there are malignant lesions.
2. Benign lesions of the gallbladder.

Diagnostic physician: LQC
Report time: November 12, 2016 12:25
Surgery room: 6
Surgery serial number: 1
Duty nurse: ZY

Figure 8. Intraoperative freezing report.

tissues surrounding the mass and the right hepatic lobe was significantly enlarged. Thus, we decided to perform a right hemihepatectomy. The operating time was 3h and the intraoperative hemorrhage amount was 200 mL. After resection, we dissected the occupying mass and found solid tissues and blood clots inside. Intraoperative frozen biopsy confirmed the diagnosis of hepatic hemangioma but could not rule out the possibility of malignancy transformation of the consolidated tissues (intraoperative frozen biopsy was performed by an experienced pathologist) (Fig. 8). The postoperative secondary pathology report confirmed the diagnosis of hepatic hemangioma with internal hemorrhage and excluded malignant transformation (Fig. 9). Routine treatments were administered postoperatively and the patient's body temperature returned to normal on the day of the surgery (Fig. 10). The fever did not recur and her anemia gradually improved. No hemorrhage, bile leakage, or other complications were seen. Nine days after the operation, the patient recovered enough to be discharged. One month postoperatively, significant enlargement and growth of the resected liver were observed (Fig. 11) and indices of the blood routine test were restored to their normal levels.

3. Discussion

Hepatic hemangioma is the most common benign liver tumor, with the majority being cavernous hemangiomas,^[1,2] with little chance of malignant transformation.^[3] In general, a hepatic hemangioma with a diameter <4cm is asymptomatic and prone to be neglected, being discovered only as an incidental imaging finding. The diagnosis of a hepatic hemangioma is dependent

on ultrasound, CT, and magnetic resonance imaging, all of which provide a diagnostic accuracy of >90%.^[11] Hepatic hemangiomas with a diameter >4cm are regarded as giant hemangiomas^[12] and can cause symptoms such as abdominal discomfort^[13-15] and other catastrophic complications including rupture, internal hemorrhage, coagulation disorder, etc. If not promptly and appropriately managed, all the above complications are associated with increased risk of mortality.^[8,16,17] Reports on hepatic hemangioma with internal hemorrhage are rather rare; only a few are available worldwide.^[18-20] In general, the ultrasound manifestations of hemangiomas are slightly enhanced echoes and have relatively clear demarcation unless complicated with hemorrhage, fibrosis, or calcification when hypoechoic changes are observed.^[21] In nonhemorrhagic hemangiomas, the typical features of enhanced CT are swift enhancement and slow expurgation and when complicated with hemorrhage, the images may be manifested as medium hyperintensity. However, since this disease is rare and little experience is available regarding its clinical diagnosis, it is difficult for us to differentiate it from liver abscess, hepatic malignancies, or other diseases. Through liver needle biopsy, we confirmed the diagnosis of internal hemorrhage in this patient, which shows that liver needle biopsy is not contradicted for hepatic internal hemorrhage.

Surgical treatment is the most definitive and effective therapeutic approach for hepatic hemangioma, but is associated with a high risk for morbidity and mortality.^[22] It is reported that the operative mortality rate of a ruptured hemangioma is about 36.5%.^[8] For hemangiomas with spontaneously ruptured bleeding, interventional therapies are

Clinicopathological diagnosis report

Pathological number: XF1600387

Hospital number ID:16078288

Source: Department of Hepatobiliary Surgery, Suining Central Hospital

Patient type: Hospitalized patient

Name:JLM

Gender:female

Age:52Y

Department: Digestive Center 2nd Region

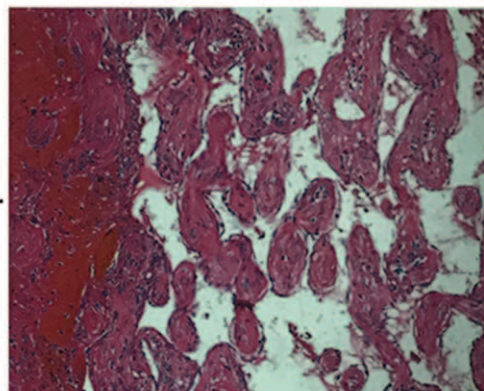
Bed number: 10

Acquisition time:November 12, 2016

Visual observation results:

1. Liver tissue (22*15*8cm). Smooth surface. Huge mass found in the cut section (15*12*cm). Clear boundaries, Colorful. Part of the region appears as sponge, full of blood. Part of the area isan entity, fragile crisp. Hemorrhagic necrosis occurs in some areas. No lesion was found in the remaining liver tissue.
2. Gallbladder tissue (8*5*3cm). Smooth surface. Cross section shows gallbladder filled with bile. Diameter of 0.2m polyps found in the gallbladder wall, Grayish yellow. The thickness of the inner wall of the gallbladder was 0.2 cm.

Micrograph image



(Get the material: QHL; Recording: XYR)

Diagnostic results:

1. Huge cavernous hemangioma found in the right liver.
2. Chronic cholecystitis associated with cholesterol polyps.

Diagnostic physician: QHL

Review physician: LQC

Report time: November 12, 2016

Figure 9. Postoperative pathology report.

reported to achieve auxiliary or ideal therapeutic effects^[10,23]; therefore, we first adopted interventional approaches and found that the right phrenic artery was the blood supply vessel of the hemangioma. This condition, never seen in any previous literature, might share the same underlying pathogenesis of the hepatic carcinoma in which the huge and fast-growing tumor opens and dilates the collaterals between the phrenic and hepatic arteries.^[24] After embolization of the phrenic artery, repeated observations all indicated no active internal hemorrhage while the patient experienced no fever and her symptoms of anemia was also slightly improved within a short period of

time. However, these favorable changes did not last long, necessitating the option of surgical resection for the tumor. After tumor resection, we could neither visually confirm the characteristics of the tumor nor by the intraoperative frozen specimen. Finally, the hepatic hemangioma was confirmed pathologically, postoperatively.

Based on the above information, we have reached the following conclusions: hepatic hemangioma with internal hemorrhage is extremely rare; abnormal blood supply may arise when the tumor grows rapidly; liver needle biopsy facilitates the diagnosis when there is a dilemma; and the efficacy of interventional approach is not

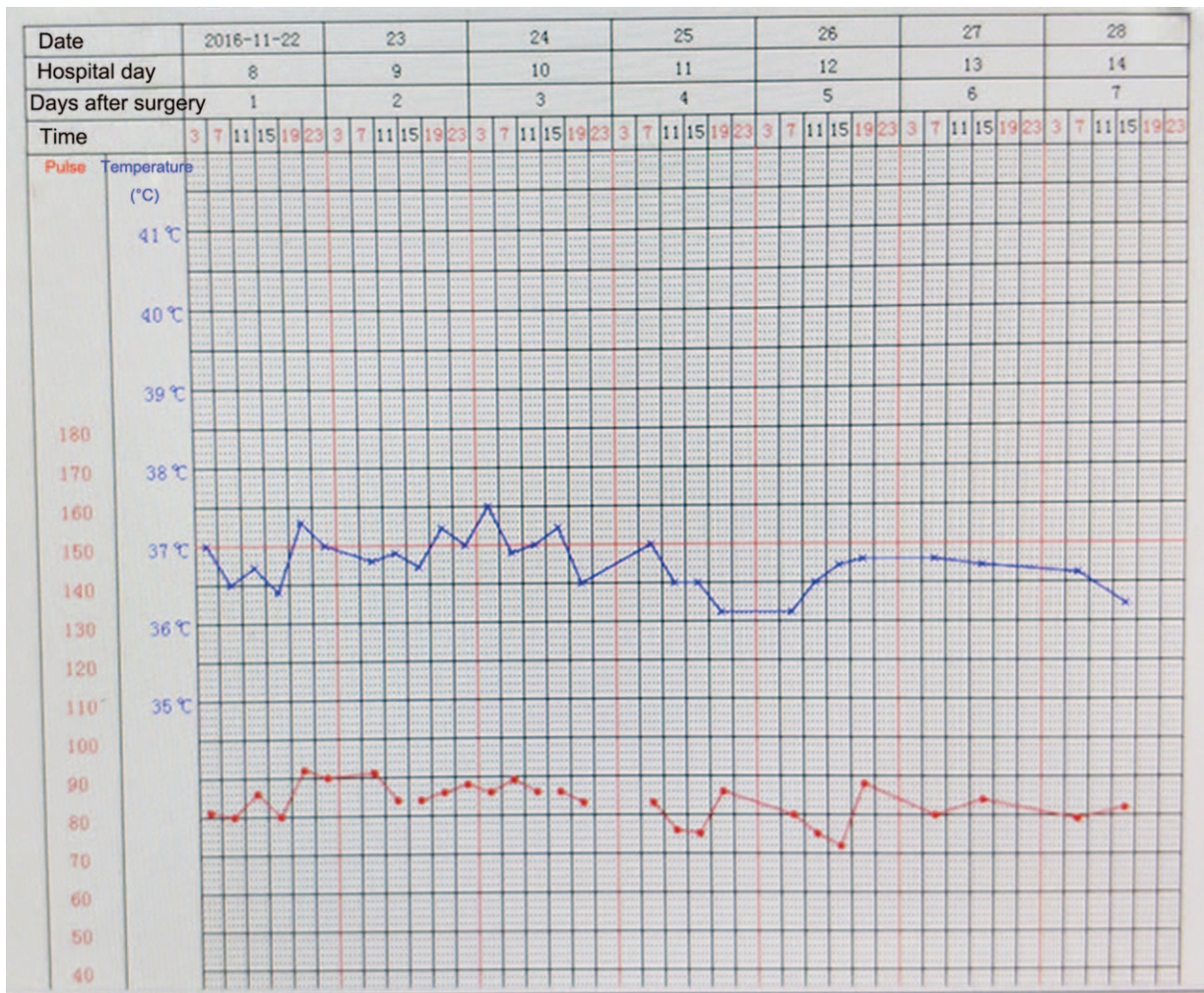


Figure 10. Postoperative temperature report.

adequate for hepatic hemangioma with internal hemorrhage, while surgical resection is still the most reliable therapeutic approach.

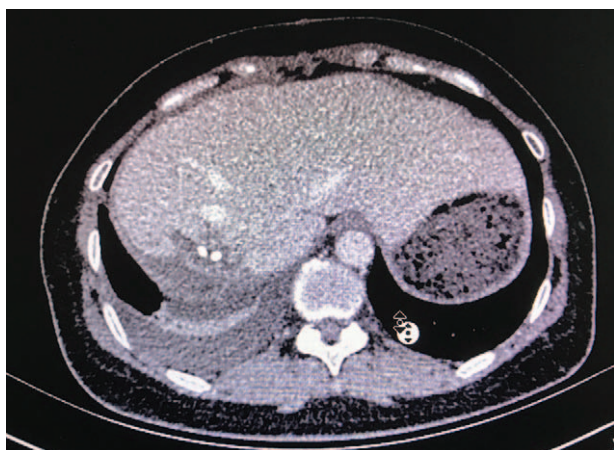


Figure 11. Postoperative computed tomography.

References

- [1] Ishak KG, Rabin L. Benign tumors of the liver. *Med Clin North Am* 1975;59:995–1013.
- [2] Sherlock S. *Disease of the Liver and Biliary System*. Boston, MA: Blackwell Scientific Publications; 1985.
- [3] Nichols FCIII, van Heerden JA, Weiland LH. Benign liver tumors. *Surg Clin North Am* 1989;69:297–314.
- [4] Gupta S, Agarwal V, Acharya AN. Spontaneous rupture of a giant hepatic hemangioma—report of a case. *Indian J Surg* 2012;74:434–6.
- [5] Hoekstra LT, Bieze M, Erdogan D, et al. Management of giant liver hemangiomas: an update. *Expert Rev Gastroenterol Hepatol* 2013;7:263–8.
- [6] Kim JM, Chung WJ, Jang BK, et al. Hemorrhagic hemangioma in the liver: a case report. *World J Gastroenterol* 2015;21:7326–30.
- [7] Pulvirenti E, Toro A, Di Carlo I. An update on indications for treatment of solid hepatic neoplasms in noncirrhotic liver. *Future Oncol* 2010;6:1243–50.
- [8] Jain V, Ramachandran V, Garg R, et al. Spontaneous rupture of a giant hepatic hemangioma—sequential management with transcatheter arterial embolization and resection. *Saudi J Gastroenterol* 2010;16:116–9.
- [9] Spitzer D, Krainz R, Graf AH, et al. Pregnancy after ovarian stimulation and intrauterine insemination in a woman with cavernous macro-hemangioma of the liver. A case report. *J Reprod Med* 1997;42:809–12.
- [10] Vokaer B, Kothonidis K, Delatte P, et al. Should ruptured liver haemangioma be treated by surgery or by conservative means? A case report. *Acta Chir Belg* 2008;108:761–4.

- [11] Toro A, Mahfouz AE, Ardiri A, et al. What is changing in indications and treatment of hepatic hemangiomas: a review. *Ann Hepatol* 2014;13:327–39.
- [12] Nelson RC, Chezmar JL. Diagnostic approach to hepatic hemangiomas. *Radiology* 1990;176:11–3.
- [13] Althaus S, Ashdown B, Coldwell D, et al. Transcatheter arterial embolization of two symptomatic giant cavernous hemangiomas of the liver. *Cardiovasc Intervent Radiol* 1996;19:364–7.
- [14] Giavroglou C, Economou H, Ioannidis I. Arterial embolization of giant hepatic hemangiomas. *Cardiovasc Intervent Radiol* 2003;26:92–6.
- [15] Srivastava DN, Gandhi D, Seith A, et al. Transcatheter arterial embolization in the treatment of symptomatic cavernous hemangiomas of the liver: a prospective study. *Abdom Imaging* 2001;26:510–4.
- [16] Wolf DC. Raghuraman UV Hepatic Hemangiomas [Internet]. New York, NY: Division of Gastroenterology and Hepatobiliary Diseases, Department of Medicine, New York Medical College (Updated December 8, 2009).
- [17] Chen ZY, Qi QH, Dong ZL. Etiology and management of hemorrhage in spontaneous liver rupture: a report of 70 cases. *World J Gastroenterol* 2002;8:1063–6.
- [18] Feldman PA, Regev A. Atypical giant hepatic hemangiomas with intratumoral hemorrhage. *Clin Gastroenterol Hepatol* 2007;5:A24.
- [19] Graham E, Cohen AW, Soulen M, et al. Symptomatic liver hemangioma with intra-tumor hemorrhage treated by angiography and embolization during pregnancy. *Obstet Gynecol* 1993;81:813–6.
- [20] Shimoji K, Shiraishi R, Kuwatsuru A, et al. Spontaneous subacute intratumoral hemorrhage of hepatic cavernous hemangioma. *Abdom Imaging* 2004;29:443–5.
- [21] Ho HY, Wu TH, Yu MC, et al. Surgical management of giant hepatic hemangiomas: complications and review of the literature. *Chang Gung Med J* 2012;35:70–8.
- [22] Herman P, Costa ML, Machado MA, et al. Management of hepatic hemangiomas: a 14-year experience. *J Gastrointest Surg* 2005;9:853–9.
- [23] Lupinacci RM, Szejnfeld D, Farah JF. Spontaneous rupture of a giant hepatic hemangioma. Sequential treatment with preoperative transcatheter arterial embolization and conservative hepatectomy. *G Chir* 2011;32:469–72.
- [24] Charnsangavej C, Chuang VP, Wallace S, et al. Angiographic classification of hepatic arterial collaterals. *Radiology* 1982;144:485–94.