

Chorea-Acanthocytosis Presenting with Parkinsonism-Dystonia without Chorea

Edoardo Monfrini, MD, PhD,^{1,2} Alessio Di Fonzo, MD, PhD,^{2,*} and Francesca Morgante, MD, PhD^{3,4}

Chorea-acanthocytosis (ChAc) is a rare genetic neurodegenerative disorder caused by biallelic VPS13A pathogenic variants. The phenotype is characterized by progressive chorea, neuropsychiatric features, seizures, and hyperCKemia due to myopathy, that may often be subclinical, and neuropathy. The phenotype is characterized by progressive chorea, neuropsychiatric features, seizures, and subclinical myopathy associated with hyperCKemia.¹ The term “acanthocytosis” is due to the observation of abnormal erythrocytes with spiked cell membrane (acanthocytes) in the blood smear of affected individuals.^{1,2} ChAc is part of the “Neuroacanthocytosis syndromes,” which is a group of rare progressive disorders displaying acanthocytes and neurological abnormalities also including McLeod syndrome.¹ Here, we present a case of ChAc without chorea, but with prominent parkinsonism combined with dystonia.

Case Report

The proband was an Italian male with normal psychomotor development. His parents were first cousins. One maternal cousin had epilepsy. At the age of 34 he developed generalized epileptic seizures which were controlled with oxcarbazepine, levetiracetam, and clonazepam. Over the following years, cognitive disturbances, behavioral disinhibition, prominent gait disturbances, and generalized slowness were also noted. These symptoms gradually progressed and within 10 years from onset, he needed assistance in all activities of daily living.

Neurological examination performed at age 48 showed action-induced dystonia in the lower limbs combined with signs of symmetrical parkinsonism (moderate bradykinesia and rigidity). He had knee bending when walking forward, which resolved when walking backwards. He also had freezing of gait and festination. Other findings included: slow

horizontal saccades, nystagmus on lateral gaze; facial hypomimia, hypophonia, and stuttering dysarthria; stimulus-sensitive myoclonus was evident in the upper and lower limbs; motor perseverations, hyperreflexia except for absent ankle reflexes, extensor plantar responses. No motor impersistence or chorea were observed (Video 1).

Laboratory investigations including full blood count, ceruloplasmin, copper studies, liver enzymes, protein electrophoresis, and alpha-fetoprotein were all normal, but for CK which was mildly elevated (258 U/L). Blood films were not performed. Skeletal muscle biopsy showed a moderate reduction in size of some fibers. A liver ultrasound showed hepatomegaly and steatosis. Echocardiography, nerve conduction studies, and electromyography were normal. Brain Magnetic Resonance Imaging showed T₂-weighted symmetrical hyperintensity surrounding the putamen, caudate atrophy, moderate atrophy of the cerebellar vermis, and mild generalized atrophy (Fig. 1A–C). Whole-exome sequencing (WES) was performed upon obtaining written informed consent from the patient. Variant prioritization looking for rare (AF ≤ 0.001) nonsynonymous variants in genes associated with movement disorders revealed a novel homozygous frameshift truncating variant affecting the VPS13A gene (NM_033305.3): c.4351delT, p.(Phe1451Serfs*3), which was confirmed by Sanger sequencing (Fig. 1D, E). Vps13a loss-of-function is the recognized disease mechanism of ChAc. The variant reported here is predicted to lead to nonsense-mediated decay, and consequently to a complete loss of the Vps13a protein.

On long-term follow-up, the patient’s condition deteriorated with worsening of parkinsonian symptoms and dementia. Higher doses of levodopa determined excessive daytime sleepiness and behavioral abnormalities. He died of pneumonia at age 51.

¹Dino Ferrari Center, Neuroscience Section, Department of Pathophysiology and Transplantation, University of Milan, Milan, Italy; ²Foundation IRCCS Ca’Granda Ospedale Maggiore Policlinico, Neurology Unit, Milan, Italy; ³Neurosciences Research Centre, Molecular and Clinical Sciences Research Institute, St George’s, University of London, London, UK; ⁴Department of Experimental and Clinical Medicine, University of Messina, Messina, Italy


*Correspondence to: Dr. Alessio Di Fonzo, Neurology Unit, IRCCS Foundation Ca’ Granda Ospedale Maggiore Policlinico, Via Francesco Sforza 35, 20122 Milan, Italy; E-mail: alessio.difonzo@policlinico.mi.it

Keywords: VPS13A, chorea-acanthocytosis, parkinsonism, dystonia, chorea.

This is an open access article under the terms of the [Creative Commons Attribution-NonCommercial-NoDeriv](https://creativecommons.org/licenses/by-nc-nd/4.0/) License, which permits use and distribution in any medium, provided the original work is properly cited, the use is non-commercial and no modifications or adaptations are made.

Received 24 October 2022; revised 22 December 2022; accepted 18 January 2023.

Published online 00 Month 2023 in Wiley Online Library (wileyonlinelibrary.com). DOI: 10.1002/mdc3.13771



Video 1. The video shows dystonic knee bending only when walking forward combined with freezing of gait and festination. Other features shown in video: facial hypomimia, moderate bradykinesia; dystonic overflow in the lower limbs upon performance of alternate repetitive movements of the upper limbs; stimulus-sensitive myoclonus was evident in the upper and lower limbs; hyperreflexia except for absent ankle reflexes, extensor plantar responses.

Video content can be viewed at <https://onlinelibrary.wiley.com/doi/10.1002/mdc3.13771>

Discussion

We reported a novel highly deleterious homozygous variant of *VPS13A* gene which clinically manifested with early onset

parkinsonism, dystonia, pyramidal signs and myoclonus. Interestingly, he did not display chorea, the most common movement disorder associated with ChAc. He also had epilepsy, sub-clinical myopathic changes, and hepatomegaly, which are known clinical

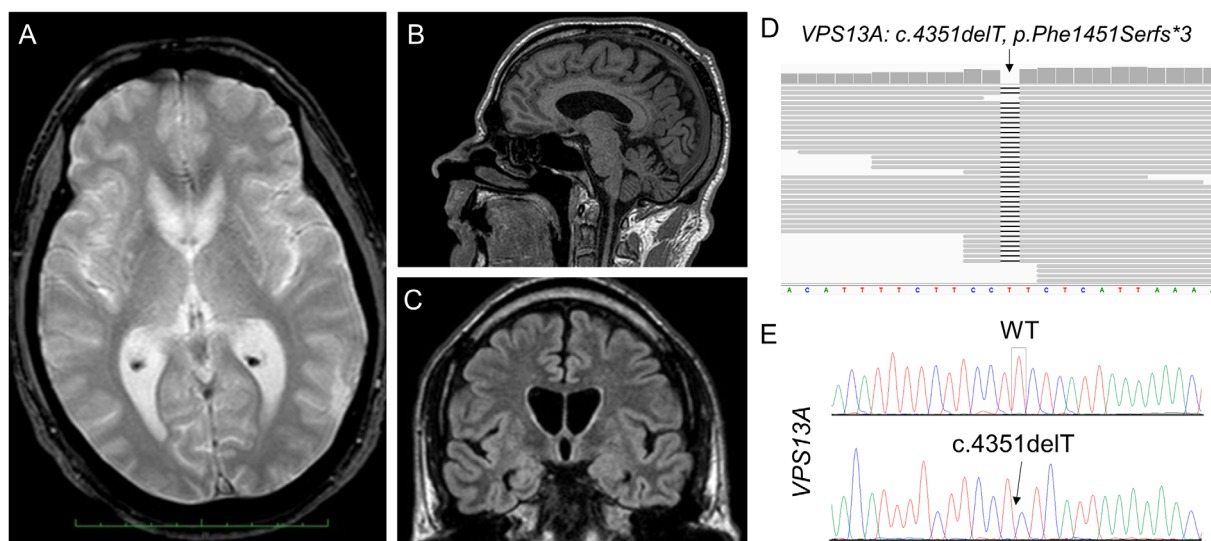


Figure 1. (A–C) Brain MRI of the patient performed at age 48: axial T₂-weighted sequence showing symmetrical hyperintensity surrounding the putamen and mild generalized atrophy (A), sagittal T₁-weighted sequence showing moderate atrophy of the cerebellar vermis (B), coronal FLAIR sequence revealing symmetrical atrophy of the caudate nucleus (C, D) IGV viewer snapshot of genomic .bam file demonstrating the homozygous deletion of a single thymidine (T) in position c.4351 of the *VPS13A* gene; (E) Sanger validation of the identified homozygous *VPS13A* single base deletion: wild-type (WT) in the upper panel and proband's variant in the lower panel.

features of ChAc.¹ Dystonia-parkinsonism without choreic features has been already reported in at least five patients^{3–5} with “Neuroacanthocytosis.” However, none of them received a genetic diagnosis. Indeed, three cases were reported several years before *VPS13A* has been identified as a disease causative gene.^{3,4} In the other two subjects, the diagnosis was supported by western blot of chorein, the protein encoded by *VPS13A*, but their genotypes were not reported.⁵ The identified *VPS13A* variant (c.4351delT, p.(Phe1451Serfs*3)) is novel and expands the mutational spectrum of ChAc. Description of other cases of ChAc carrying this specific variant is warranted to make genotype–phenotype correlations.

In conclusion, *VPS13A* mutation should be suspected also in patients without chorea presenting with early onset parkinsonism in combination with dystonia and other typical neurological and systemic manifestations of ChAc.

Author Roles

(1) Research project: A. Conception, B. Organization, C. Execution. (2) Statistical Analysis: A. Design, B. Execution, C. Review and Critique. (3) Manuscript: A. Writing of the first draft, B. Review and Critique.

E.M.: 1C, 3A, 3B.

A.D.: 1B, 1C, 3B.

F.M.: 1A, 1B, 1C, 3B.

Disclosures

Ethical Compliance Statement: We confirm that we have read the Journal’s position on issues involved in ethical publication and affirm that this work is consistent with those guidelines. We also guarantee that the patient has given his consent to anonymously report her clinical reports and videos in accordance with

current ethical standards. Whole-Exome Sequencing has been performed upon approval of the Ethics Committee of the IRCCS Foundation Ca’ Granda Ospedale Maggiore Policlinico (Milan, Italy).

Funding Sources and Conflicts of Interest: This study was funded by Italian Ministry of Health—Current research IRCCS to ADF.

Financial Disclosures for the Previous 12 Months: E.M.: No disclosures. A.D.: Advisory board fees from Sanofi. Speaking honoraria from Sanofi and Zambon. F.M.: Speaking honoraria from Abbvie, Medtronic, Boston Scientific, Bial, Merz; Travel grants from the International Parkinson’s disease and Movement Disorder Society; Advisory board fees from Abbvie, Merz and Boston Scientific; Consultancies fees from Boston Scientific, Merz and Bial; Research support from NIHR, UKRI, Boston Scientific, Merz and Global Kynetic; Royalties for the book “Disorders of Movement” from Springer; member of the editorial board of Movement Disorders, Movement Disorders Clinical Practice, European Journal of Neurology. ■

References

1. Velayos Baeza A, Dobson-Stone C, Rampoldi L, et al. GeneReviews®. Chorea-Acanthocytosis; Seattle 1993.
2. Rampoldi L, Dobson-Stone C, Rubio JP, et al. A conserved sorting-associated protein is mutant in chorea-acanthocytosis. *Nat Genet* 2001; 28(2):119–120. <https://doi.org/10.1038/88821>.
3. Bostantjopoulou S, Katsarou Z, Kazis A, Vadikolia C. Neuroacanthocytosis presenting as parkinsonism. *Mov Disord* 2000;15(6):1271–1273. [https://doi.org/10.1002/1531-8257\(200011\)15:6<1271::AID-MDS1037>3.0.CO;2-T](https://doi.org/10.1002/1531-8257(200011)15:6<1271::AID-MDS1037>3.0.CO;2-T).
4. Peppard RF, Lu CS, Chu NS, Teal P, Martin WR, Calne DB. Parkinsonism with neuroacanthocytosis. *Can J Neurol Sci* 1990;17(3):298–301. <https://doi.org/10.1017/s0317167100030602>.
5. Peluso S, Bilo L, Esposito M, Antenora A, de Rosa A, Pappatà S, de Michele G. Chorea-acanthocytosis without chorea: expanding the clinical phenotype. *Parkinsonism Relat Disord* 2017;41:124–126. <https://doi.org/10.1016/j.parkreldis.2017.05.013>.