



BRIEF REPORT

Snare-tip-assisted peroral endoscopic myotomy for achalasia (with video)

Zhen-Zi Huang[†], Ren Mao[†], Yi Cui, Yuan-Qi Li, Ying-Lian Xiao, Jin-Hui Wang, Min-Hu Chen and Xiang-Bin Xing*

Department of Gastroenterology, The First Affiliated Hospital of Sun Yat-sen University, Guangzhou, Guangdong, P. R. China

*Corresponding author. Department of Gastroenterology, The First Affiliated Hospital of Sun Yat-sen University, 58 Zhongshan II Road, Guangzhou, Guangdong 510080, China. Tel: +86-20-87755766; Email: xingxbn@mail.sysu.edu.cn

[†]These authors contributed equally to this work.

Introduction

Since peroral endoscopic myotomy (POEM) for the treatment of achalasia was first introduced by Inoue *et al.* [1] in 2010, various endoscopic knives including the Triangular-tip knife have been used during the procedure [2]. To date, the investigation on endoscopic knives with good performance and low expense is still underway for patients with achalasia. In this case, we successfully carried out POEM assisted by a snare tip in a patient with achalasia.

Case presentation

A 58-year-old man presented to our hospital with a 30-year history of dysphagia. Esophageal manometry, upper endoscopy, and barium esophagography confirmed the diagnosis of sigmoid-type achalasia (type II) with an Eckardt score of 6. POEM treatment assisted by a snare tip was performed in this patient. This method was approved by the Ethics Committee of the First Affiliated Hospital of Sun Yat-sen University.

The POEM procedure was conducted as previously described [1]. The snare (SD-221U-25; Olympus) was retracted into the sheath to expose the tip, leaving a 1- to 2-mm length for the operation. The snare tip can be adequate for the major steps: mucosal incision, submucosal tunnelling, and myotomy (Figure 1 and Supplementary Video 1). The entire procedure was completed within 35 min. The patient was discharged from hospital 2 days after POEM without experiencing complications, including perforation and bleeding. His symptoms resolved 3 months after treatment, with the Eckardt score decreasing to 1.

Discussion

While snares are widely used in colon polypectomy and endoscopic mucosal resection (EMR), and even in endoscopic submucosal dissection (ESD) [3, 4]. However, to our knowledge, no study has been reported to use a snare tip in assisting the POEM procedure. The current case demonstrated for the first time that the snare tip could be a safe and efficient instrument for POEM. The procedure time of POEM using a snare tip was comparable to that of Hybrid-knife-assisted POEM as reported (39 min) [5], whereas it is shorter than the conventional dissection knives (ex, Triangular-tip knife; 103.7 min) [6]. Another advantage of a snare-tip-assisted POEM procedure that should be noted is the low cost of using a single snare during the procedure. In our center, the cost of a Triangular-tip knife (KD 640L, Olympus; US \$584) is nine times higher than that of a snare (US \$64). Last but not least, using the snare tip is effective for the coagulation of small to medium-sized vessels, frequently sparing the need for hemostatic forceps. Nonetheless, randomized clinical trials are needed to confirm the clinical efficacy, safety, and cost-effectiveness of POEM assisted by a snare tip for the treatment of achalasia.

Supplementary data

Supplementary data is available at *Gastroenterology Report* online.

Submitted: 9 June 2019; Revised: 27 August 2019; Accepted: 4 October 2019

© The Author(s) 2020. Published by Oxford University Press and Sixth Affiliated Hospital of Sun Yat-sen University

This is an Open Access article distributed under the terms of the Creative Commons Attribution Non-Commercial License (<http://creativecommons.org/licenses/by-nc/4.0/>), which permits non-commercial re-use, distribution, and reproduction in any medium, provided the original work is properly cited. For commercial re-use, please contact journals.permissions@oup.com

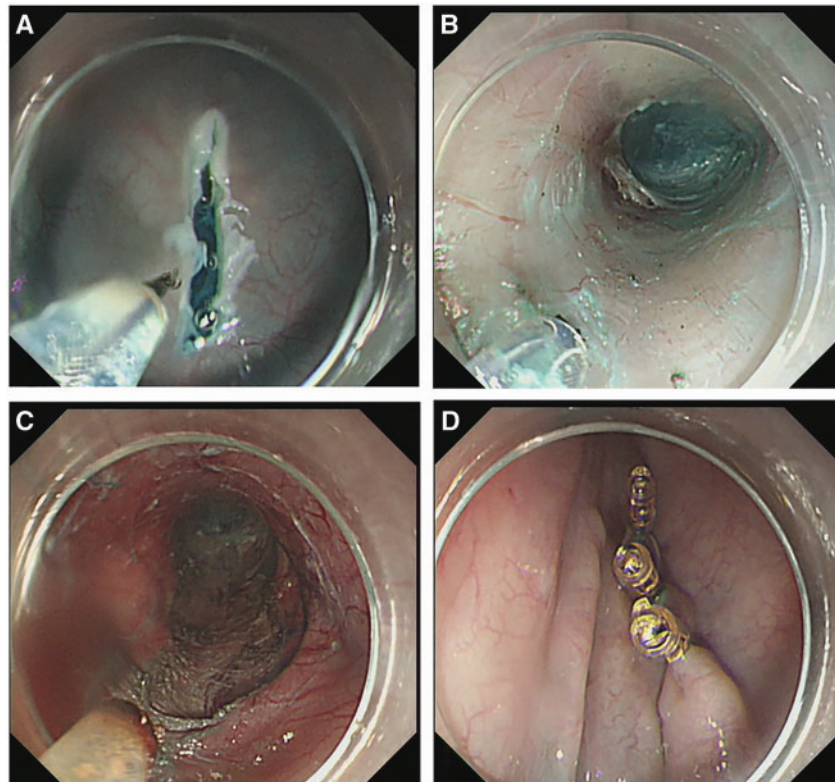


Figure 1. Snare-tip-assisted peroral endoscopic myotomy procedure. (A) Mucosal incision after submucosal saline and methylene blue injection. (B) Submucosal tunnelling from the mid-oesophagus to the gastric cardia. (C) Transecting the inner circular muscle. (D) Closure of the mucosal entrance with endoclips.

Funding

This work was supported by the Natural Science Foundation of Guangdong Province [2015A030313116], Science and Technology Planning Project of Guangdong Province [2016A020215041], and the Junior Teacher Cultivation Project of Sun Yat-sen University [15ykpy18].

Conflicts of interest

None declared.

References

1. Inoue H, Minami H, Kobayashi Y et al. Peroral endoscopic myotomy (POEM) for esophageal achalasia. *Endoscopy* 2010;**42**: 265–7.
2. Bechara R, Onimaru M, Ikeda H et al. Per-oral endoscopic myotomy, 1000 cases later: pearls, pitfalls, and practical considerations. *Gastrointest Endosc* 2016;**84**:330–8.
3. Yang CW, Yen HH, Chen YY et al. Novel use of the tip of a standard diathermic snare for endoscopic submucosal dissection of a large gastric adenomatous polyp. *J Laparoendosc Adv Surg Tech A* 2012;**22**:910–2.
4. Bharadwaj S, Narula N, Tandon P et al. Role of endoscopy in inflammatory bowel disease. *Gastroenterol Rep (Oxf)* 2018;**6**: 75–82.
5. Zhou PH, Cai MY, Yao LQ et al. Peroral endoscopic myotomy for esophageal achalasia by hybridknife: a case report. *Case Rep Gastrointest Med* 2012;**2012**:325479.
6. Chen YI, Inoue H, Ujiki M et al. An international multicenter study evaluating the clinical efficacy and safety of per-oral endoscopic myotomy in octogenarians. *Gastrointest Endosc* 2018;**87**:956–61.