



Usefulness of lateral cephalometric radiography for successful blind nasal intubation: a prospective study

Kana Ito^{1,2}, Ayaka Kamura³, Kyotaro Koshika¹, Toshiyuki Handa¹, Nobuyuki Matsuura², Tatsuya Ichinohe¹

¹Department of Dental Anesthesiology, Tokyo Dental College, Tokyo, Japan

²Department of Oral Medicine and Hospital Dentistry, Ichikawa General Hospital, Tokyo Dental College, Tokyo, Japan

³Department of Dental and Oral Surgery, Tokyo Metropolitan Tama Medical Center, Tokyo, Japan

Background: This study aimed to investigate the relationship between pharyngeal morphology and the success or failure of blind nasotracheal intubation using standard lateral cephalometric radiography and to analyze the measurement items affecting the difficulty of blind nasotracheal intubation.

Methods: Assuming a line perpendicular to the Frankfort horizontal (FH) plane, the reference point (O) was selected 1 cm above the posterior-most end of the hard palate. A line passing through the reference point and parallel to the FH plane is defined as the X-axis, and a line passing through the reference point and perpendicular to the X-axis is defined as the Y-axis. The shortest length between the tip of the uvula and posterior pharyngeal wall (AW), shortest length between the base of the tongue and posterior pharyngeal wall (BW), and width of the glottis (CW) were measured. The midpoints of the lines representing each width are defined as points A, B, and C, and the X and Y coordinates of each point are obtained (AX, BX, CX, AY, BY, and CY). For each measurement, a t-test was performed to compare the tracheal intubation success and failure groups. A binomial logistic regression analysis was performed using clinically relevant items.

Results: The items significantly affecting the success rate of blind nasotracheal intubation included the difference in X coordinates at points A and C (Odds ratio, 0.714; P-value, 0.024) and the $\angle ABC$ (Odds ratio, 1.178; P-value, 0.016).

Conclusion: Using binomial logistic regression analysis, we observed statistically significant differences in AX-CX and $\angle ABC$ between the success group and the failure group.

Keywords: Airway Management; Cephalometry; Intubation.



This is an Open Access article distributed under the terms of the Creative Commons Attribution Non-Commercial License (<http://creativecommons.org/licenses/by-nc/4.0/>) which permits unrestricted non-commercial use, distribution, and reproduction in any medium, provided the original work is properly cited.



INTRODUCTION

Difficulty in intubation is often encountered in the field of dental and oral surgery, especially in cases with retrognathia and phlegmon of the oral floor [1]. To perform tracheal intubation safely and reliably in such cases, it is important to predict the difficulty of tracheal intubation. Commonly used evaluation methods to predict

intubation difficulty include using indicators on the surface of the body. Although various indicators [2-8] have been considered, all have low specificity, and there is no clear indicator for the difficulty of tracheal intubation [9]. Moreover, because these methods use indicators on the surface of the body, it is not possible to evaluate the morphology of the pharynx through which the tracheal tube passes.

In dentistry, cephalometric analysis using standard

Received: August 29, 2022 • Revised: October 11, 2022 • Accepted: October 17, 2022

Corresponding Author: Kana Ito, Anesthesiology Tokyo Dental College Ichikawa General Hospital, 5-11-13, Sugano, Ichikawa, Tokyo 272-8513, Japan
Phone: +81-47-322-0151 E-mail: itoukana@tdc.ac.jp

Copyright© 2022 Journal of Dental Anesthesia and Pain Medicine

lateral cephalometric radiography is widely used for the examination and diagnosis of patients with malocclusion and jaw deformities [10,11]. In this method, the natural head position is determined, a standard radiograph is obtained, and reference points and angles are measured and analyzed. On a standard lateral cephalogram, both hard and soft tissues, including the mandible, tongue, and pharynx can be visualized. Thus, this technique is also used to evaluate skeletal abnormalities and upper airway patency in patients with obstructive sleep apnea syndrome [8,12,13].

Nasotracheal intubation is often used in oral and maxillofacial surgery. During this procedure, the morphology of the area from the nasal cavity to the larynx, centered on the pharynx, may affect the intubation procedure [14,15]. Hence, standard lateral cephalometric radiography can be used to predict the difficulty of tracheal intubation. Both hard and soft tissues, including the morphology of the pharynx, can be examined, which may be useful for evaluating the difficulty of blind nasotracheal intubation.

Therefore, in this study, we used blind nasotracheal intubation, which does not require a laryngoscope, to observe the relationship between pharyngeal morphology and tracheal tube passage. Despite not being the first choice, blind nasal intubation can be a useful alternative when intubation is needed in emergency situations or in cases of difficult mouth opening. To the best of our knowledge, no studies have predicted the degree of difficulty of blind nasotracheal intubation using standard cephalometric radiography. We hypothesized that standard cephalometric radiographic analysis could be used for successful blind nasal intubation. We investigated the relationship between pharyngeal morphology and success or failure of blind nasotracheal intubation using standard lateral cephalometric radiography. The measurement items affecting the difficulty of blind nasotracheal intubation were examined using binomial logistic regression analysis.

METHODS

1. Subjects

Patients scheduled to undergo orthognathic surgery under general anesthesia at the Tokyo Dental College Suidobashi Hospital were included in the study. The purpose and outline of this study were explained to them, and written informed consent was obtained. Patients with cervical spine disorders, limited cervical spine range of motion, and inflammatory diseases or neoplastic lesions in the maxillofacial region or neck were excluded. This study was approved by the ethics committee of the Tokyo Dental College (approval number 913). The standard lateral cephalograms used in this study were obtained within three months preoperatively for orthognathic surgery. Radiographs were not obtained solely for this study. To obtain a standard lateral cephalogram, patients were instructed to lightly contact their upper and lower teeth. This study was approved by the Tokyo Dental College Suidobashi Hospital IRB, and all participants signed an informed consent form.

2. Measurement items

The primary endpoint of this study was to identify factors involved in the success of blind nasal intubation. The measurement items in the standard lateral cephalograms were as follows. Assuming a line perpendicular to the Frankfort horizontal (FH) plane, the reference point (O) was 1 cm above the posteriormost end of the hard palate. This point was selected because the nasotracheal tube was supposed to pass through this point and enter the pharynx. A line passing through the reference point and parallel to the FH plane was defined as the X-axis, and a line passing through the reference point and perpendicular to the X-axis was defined as the Y-axis. The shortest length between the tip of the uvula and posterior pharyngeal wall (AW), shortest length between the base of the tongue and posterior pharyngeal wall (BW), and width of the glottis (CW) were measured. Subsequently, the midpoints of the lines representing each

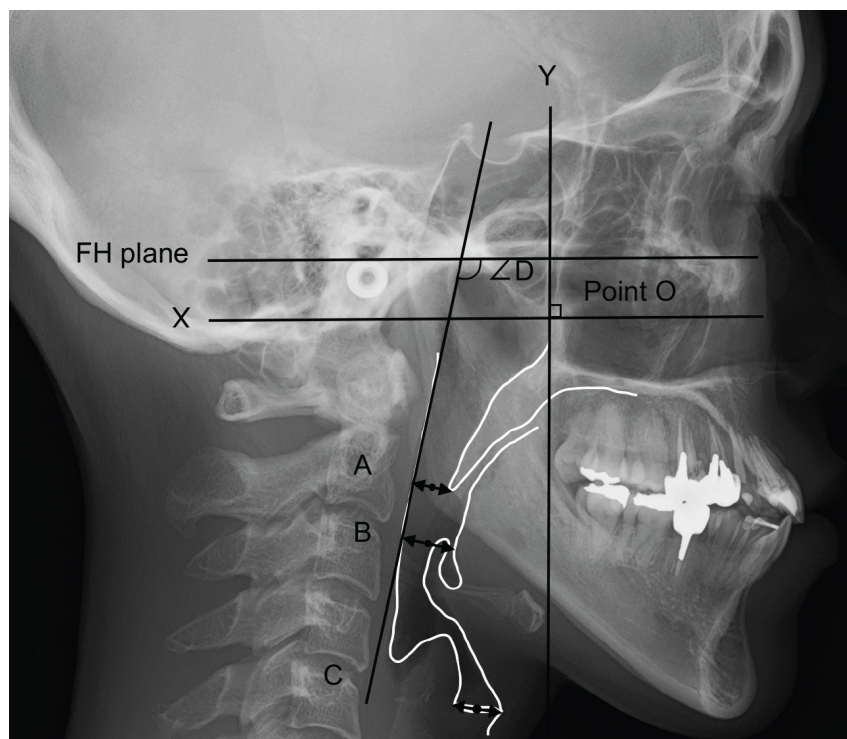


Fig. 1. Measurement items in a standard lateral cephalometric radiogram. Assuming a line perpendicular to the Frankfort horizontal plane (FH plane), the reference point (O) is selected 1 cm above the posteriormost end of the hard palate. A line passing through the reference point and parallel to the FH plane is defined as the X-axis, and a line passing through the reference point and perpendicular to the X-axis is defined as the Y-axis. The shortest length between the tip of the uvula and the posterior pharyngeal wall (AW), the shortest length between the base of the tongue and the posterior pharyngeal wall (BW), and the width of the glottis (CW) were measured. The midpoints of the lines representing each width are defined as points A, B, and C, and the X and Y coordinates of each point were obtained (AX, BX, CX, AY, BY, and CY).

width were defined as points A, B, and C, and the X- and Y-coordinates of each point were obtained (AX, BX, CX, AY, BY, and CY). In addition, the difference between the X coordinates of points A and B (AX-BX), points B and C (BX-CX), points A and C (AX-CX), the difference between the Y coordinates of points A and B (AY-BY), points B and C (BY-CY), points A and C (AY-CY), the angle connecting points A, B, and C (\angle ABC), and the angle between the lines representing the FH plane and the posterior pharyngeal wall (\angle D) were measured. The radius of the circle passing through points A, B, and C was also calculated. The measurement parameters are shown in Fig. 1.

3. Tracheal intubation

After entering the operating room, each patient was placed in the horizontal supine position. The patient's head position was established by stacking one to four

pillows of 1 cm thickness to ensure that the FH plane was perpendicular to the operating table. Anesthesia was induced using propofol, remifentanyl hydrochloride, and rocuronium bromide. After confirming that the train-of-four (TOF) count was 0 using a TOF-watch (Organon Ireland Limited, Dublin, Ireland), blind nasotracheal intubation was performed. Tracheal intubation was performed by the same dental anesthesiologist in every case, ensuring that there were no differences in the technique in each patient. In every case, a Portex® cuffed ivory nasal tube with an inner diameter of 6.5 mm for women or 7.0 mm for men was used. No more than three attempts to perform successful blind nasotracheal intubation were permitted, because three three attempts at intubation would result in a minute-long period of apnea. Devices, such as laryngoscopes, that could affect pharyngeal morphology were not used. If intubation was not possible, tracheal

Table 1. Patient background

	Prognathism (n = 72) Mean ± SD	Retrognathia (n = 34) Mean ± SD	P-value
Gender, Male/Female	27 / 45	4 / 30	0.013*
Age, y	27.3 ± 9.1	29.2 ± 7.4	0.279
Height, cm	164.0 ± 7.9	161.6 ± 5.4	0.116
Weight, kg	59.1 ± 10.6	54.5 ± 10.2	0.040*
BMI, kg/m ²	21.9 ± 3.2	20.8 ± 3.2	0.106
Success rate, %	55.5	76.4	0.063

*P < 0.05 Considered statistically significant.

BMI, body mass index; n, number; SD, standard deviation; y, years.

Table 2. Comparison between the success group and the failure group

	Success Mean ± SD	Failure Mean ± SD	P-value
A-X, mm	-27.5 ± 4.3	-26.0 ± 5.0	0.109
A-Y, mm	-29.2 ± 3.9	-31.0 ± 4.1	0.03*
B-X, mm	-32.0 ± 6.0	-29.4 ± 6.6	0.038*
B-Y, mm	-46.9 ± 6.1	-48.4 ± 5.7	0.204
C-X, mm	-26.6 ± 9.8	-19.7 ± 10.5	< 0.001*
C-Y, mm	-88.5 ± 8.4	-89.4 ± 7.4	0.565
AW, mm	11.1 ± 3.7	12.4 ± 3.4	0.075
BW, mm	11.0 ± 3.7	11.8 ± 3.6	0.246
CW, mm	10.0 ± 2.2	10.4 ± 2.2	0.464
∠ABC, deg	145.2 ± 8.2	141.7 ± 5.5	0.018*
∠D, deg	94.4 ± 6.7	91.0 ± 7.0	0.016*
AX-BX, mm	-4.5 ± 3.1	-3.4 ± 2.8	0.061
BX-CX, mm	5.4 ± 5.9	9.7 ± 5.0	< 0.001*
AX-CX, mm	-0.9 ± 7.1	-6.3 ± 6.9	< 0.001*
AY-BY, mm	-17.6 ± 5.9	-17.4 ± 5.4	0.844
BY-CY, mm	-41.6 ± 6.8	-41.0 ± 6.3	0.653
AY-CY, mm	-59.3 ± 7.7	-58.4 ± 7.2	0.583
Radius, mm	111.3 ± 100	74.5 ± 19.3	0.024*

*P < 0.05 Considered statistically significant.

AX, X coordinate of the midpoint of the shortest length between the tip of the uvula and the posterior pharyngeal wall; AY, Y coordinate of the midpoint of the shortest length between the tip of the uvula and the posterior pharyngeal wall; BX, X coordinate of the midpoint of the shortest length between the base of the tongue and the posterior pharyngeal wall; BY, Y coordinate of the midpoint of the shortest length between the base of the tongue and the posterior pharyngeal wall; CX, X coordinate of the midpoint of the shortest length between the width of the glottis; CY, Y coordinate of the midpoint of the shortest length between the width of the glottis; AW, The shortest length between the tip of the uvula and the posterior pharyngeal wall; BW, The shortest length between the base of the tongue and the posterior pharyngeal wall; CW, The shortest length between the width of the glottis; ∠ABC, The angle connecting points A, B, and C; ∠D, The angle between the lines representing the FH plane and the posterior pharyngeal wall; AX-BX, The difference between the X coordinates of points A and B; BX-CX, The difference between the X coordinates of points B and C; AX-CX, The difference between the X coordinates of points A and C; AY-BY, The difference between the Y coordinates of points A and B; BY-CY, The difference between the Y coordinates of points B and C; AY-CY, The difference between the Y coordinates of points A and C.

intubation was performed using a Macintosh or video laryngoscope. A capnometer (Emma, Masimo Japan, Denmark, Sweden) was used to confirm successful tracheal intubation.

4. Statistical analysis

For each measurement item on a standard lateral cephalometric radiograph, a t-test was performed to

compare the tracheal intubation success and failure groups. Among the measurement items with statistically significant differences, binomial logistic regression analysis was performed using items that were clinically significant. IBM SPSS Statistics version 27 (IBM Corp, Armonk, NY, USA) was used for statistical analyses. Post hoc power analyses were performed using G * Power version 3.1.9.2. The error was set at 0.05.

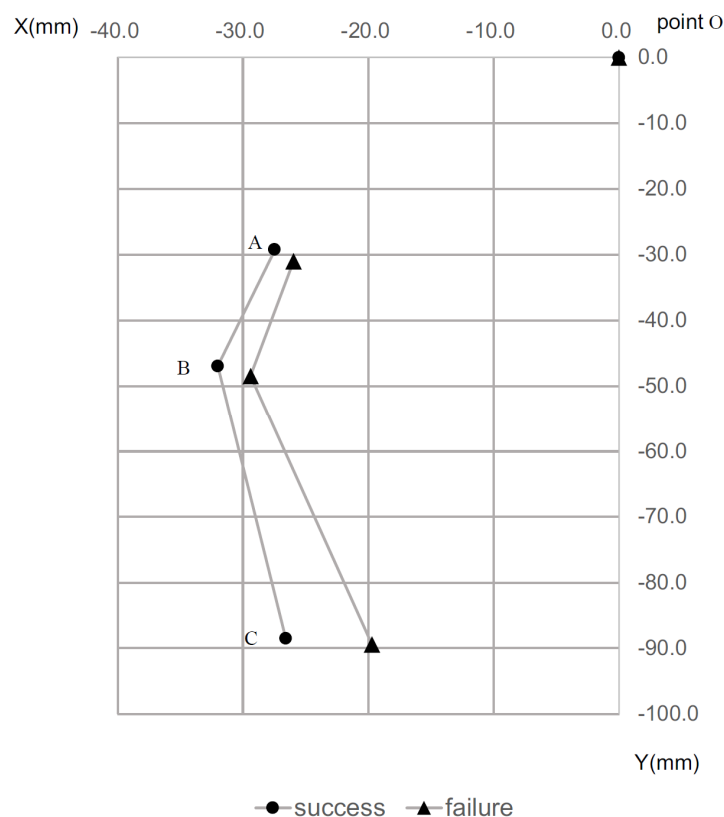


Fig. 2. Relationship of points A, B and C in the success group and failure group. In the success group, points A, B and C were located more posterior to the point O and $\angle ABC$ was larger.

RESULTS

A total of 106 patients with ASA physical status 1 and 2 and aged 18 – 54 years participated in this study. None of the patients met the exclusion criteria during the study period. Intubation was successful in 66 of the 106 patients (success rate: 62.2%). There were 72 cases of mandibular prognathism and 34 of retrognathia (Table 1). Intubation was successful in 40 of 72 cases of mandibular prognathism (success rate: 55.5%) and in 26 of 34 cases of retrognathia (success rate: 76.4%). There was a statistically significant difference in the male-to-female ratio between the patients with mandibular prognathism and those with retrognathia. However, there was no difference in the success rate of blind nasotracheal intubation between males and females in either case. The body weight of patients with mandibular prognathism was greater than that of patients with retrognathia, while BMIs

in both cases were similar. As a result, since there was no statistically significant difference in the success rate of blind nasotracheal intubation between patients with mandibular prognathism and those with retrognathia (chi-squared test, $P = 0.063$), the analysis was performed for all cases.

Comparison between the success group and the failure group revealed statistically significant differences in AY ($P = 0.030$), BX ($P = 0.038$), CX ($P < 0.001$), AX-CX ($P < 0.001$), BX-CX ($P < 0.001$), $\angle ABC$ ($P = 0.018$), $\angle D$ ($P = 0.016$), and the radius ($P = 0.023$) of the circle formed by connecting points A, B, and C (Table 2, Fig. 2). After considering multicollinearity, we performed binomial logistic regression analysis with AX-CX, BX-CX, $\angle ABC$, and the diagnosis (mandibular prognathism or retrognathia) as independent variables. All these factors were considered to have a large effect on the clinical success or failure of blind nasotracheal intubation. As dummy variables, we set the diagnosis of

Table 3. Results of binomial logistic regression analysis

	Odds ratio	95%CI	P-value
Diagnosis	2.253	0.742-6.842	0.152
AX-CX, mm	0.714	0.534-0.956	0.024*
BX-CX, mm	1.438	0.948-2.182	0.088
∠ABC, deg	1.178	1.031-1.346	0.016*

*P < 0.05 Considered statistically significant.

AX-CX, The difference between the X coordinates of points A and C, BX-CX, The difference between the X coordinates of points B and C; ∠ABC, The angle connecting points A, B, and C.

mandibular prognathism to “0” and the diagnosis of retrognathia to “1.” The success or failure of tracheal intubation was the dependent variable, with the dummy variable for success set as “1” and the dummy variable for failure set as “0.” Statistically significant differences were observed in AX-CX (odds ratio [OR]: 0.714, 95% confidence interval [CI]: 0.534 – 0.956) and ∠ABC (OR: 1.178, 95% CI: 1.031 – 1.346) between the groups (Table 3).

The results of the model chi-squared test were significant at $P < 0.05$, and the results of the Hosmer-Lemeshow test revealed a good fit at $P = 0.370$ with 68.9% correct classifications. Post-hoc power analyses showed the achieved power and effect size for AX-CX between the success and failure groups were 0.968 and 0.77, and those for ∠ABC were 0.698 and 0.50, respectively.

DISCUSSION

The results of this study revealed that the items significantly affecting the success rate of blind nasotracheal intubation included the difference in AX-CX and ∠ABC. However, there was no statistically significant difference in the success rate between the patients with mandibular prognathism and those with retrognathia. A comparison between the success and failure groups revealed that there were many cases in the success group wherein points B and C were located more posterior to the reference point and ∠ABC was larger. In cases where the pharynx and larynx were located posterior to the reference point, the radius of the circle

passing through points A, B, and C increased. Hence, it was suggested that blind nasotracheal intubation might have a high success rate because a nasally inserted tube is believed to move toward the larynx without following a sharp curve. In addition, the Japanese Industrial Standards state that if the tracheal tube is described as Magill-shaped, the radius of curvature of tubes sized ≥ 6.5 must be 140 ± 20 mm [16]. In the success group, the radius of the circle passing through points A, B, and C was close to this value.

In this study, the body weights of patients with mandibular prognathism were higher than those of patients with retrognathia. However, as there was no difference in BMI between the two cases, it is suggested that the difference in body weight had little effect on the difficulty of tracheal intubation.

Generally, tracheal intubation is more difficult in patients with retrognathia than in those with mandibular prognathism [17]. However, the results of this study showed that the success rate of blind nasotracheal intubation was slightly higher in retrognathia cases than in mandibular prognathism cases, although the difference was not statistically significant ($P = 0.063$). This may indicate that blind nasotracheal intubation may be easier in patients with retrognathia than in those with mandibular prognathism. Further investigation is required to explain this possibility.

Several studies have evaluated benchmarks on the body surface to predict the difficulty of tracheal intubation. Posterior deviation of the tongue and anterior deviation of the larynx have been reported as the primary factors affecting the difficulty of laryngoscopy [18]. Another study reported that the presence or absence of posterior

deviation of the tongue and the size of the tongue affected the difficulty of laryngeal intubation [19]. Other indicators that evaluate the difficulty of tracheal intubation, such as the upper lip bite test and maximum laryngeal height, have been discussed in many other studies [2]; however, both methods are semiquantitative examination methods.

Extensive literature is present regarding the usefulness of ultrasonography in predicting the difficulty of tracheal intubation [3,6,20]. Ultrasonography is an excellent examination method because it can be performed easily and does not involve exposure to radiation. Most ultrasonography procedures are based on soft tissues such as the tongue and anterior neck. Although the size of the tongue and the morphology of the base of the tongue can be easily observed, the width of the pharynx cannot be evaluated. As points A, B, and C in this study can only be determined by adding the pharyngeal width to the morphology of the base of the tongue examined using ultrasound, it is difficult to obtain the results observed in this study using ultrasonography alone. In other words, we believe that the difficulty of blind nasotracheal intubation can be evaluated objectively and accurately by examining both the hard and soft tissues using standard lateral cephalometric radiography.

Airway management in patients at risk of relatively difficult intubation is important for anesthesiologists, and they should always be prepared for emergencies. According to the American Society of Anesthesiologists, the incidence of difficult intubation in the operating room is 1.2 – 3.8% and the incidence of failed intubation is 0.13 – 0.3% [2]. Currently, blind tracheal intubation is not the first choice in cases in which tracheal intubation may be difficult. However, it can be a useful alternative and an emergency life-saving technique in cases where general airway management is difficult [21]. If the success or failure of blind nasotracheal intubation can be evaluated objectively, it can be considered a useful intubation method not only for cases of jaw deformities but also for cases requiring emergent operation, such as phlegmon of the oral floor and inability to open the

mouth.

Generally, standard lateral cephalometric radiography is performed in the sitting position. In contrast, tracheal intubation was performed with the patient in the supine position. Since the body muscles are relaxed during tracheal intubation, the BW during tracheal intubation may be smaller than that during the preoperative period, and point B may move posteriorly. Therefore, it is considered that $\angle ABC$ is decreased. However, the relationship between the positions at points A, B, and C was similar in both the groups. In other words, points A, B, and C in the success group were located behind those in the failure group. Therefore, the usefulness of preoperative standard lateral cephalometric radiography for predicting the difficulty of tracheal intubation cannot be ruled out. In addition, the positions of points A and C were considered minimally affected by body position and muscle relaxation. Thus, AX-CX, which showed a significant difference between the success and failure groups in binomial logistic regression analysis, can be a simple and reliable index for predicting the difficulty of tracheal intubation.

The measurements were performed using standard lateral cephalometric radiography alone. The pharynx morphology might be evaluated by obtaining the posteroanterior image and combining it into a three-dimensional view. However, soft tissues, including the pharynx, should not be precisely evaluated because of the presence of the mandible in the posteroanterior cephalogram.

In conclusion, we investigated the relationship between the morphology of the area from the nasal cavity to the larynx, centered on the pharynx, and the success or failure of blind tracheal intubation, using standard lateral cephalometric radiography. Binomial logistic regression analysis revealed statistically significant differences in AX-CX and $\angle ABC$ between the success and failure groups.

AUTHOR ORCID*s*

Kana Ito: <https://orcid.org/0000-0001-6712-222X>
Ayaka Kamura: <https://orcid.org/0000-0002-1222-7435>
Kyotaro Koshika: <https://orcid.org/0000-0002-2656-9698>
Toshiyuki Handa: <https://orcid.org/0000-0002-9290-9865>
Nobuyuki Matsuura: <https://orcid.org/0000-0002-9527-4981>
Tatsuya Ichinohe: <https://orcid.org/0000-0001-5793-3379>

AUTHOR CONTRIBUTIONS

Kana Ito: Conceptualization, Data curation, Formal analysis, Methodology, Writing - original draft
Ayaka Kamura: Data curation
Kyotaro Koshika: Formal analysis
Toshiyuki Handa: Data curation, Formal analysis
Nobuyuki Matsuura: Data curation, Formal analysis, Methodology
Tatsuya Ichinohe: Supervision

ACKNOWLEDGMENTS: The author acknowledges Prof. Tatsuya Ichinohe for his assistance in editing the manuscript, and appreciates Dr. Ayaka Kamura, Senior Assist. Prof. Kyotaro Koshika Senior Assist, Prof. Toshiyuki Handa and Prof. Nobuyuki Matsuura for their continuous support with this study.

CONFLICT OF INTEREST: The authors declare no conflict of interest.

REFERENCES

1. Miller RD, Eriksson LI, Fleisher LA, Wiener-Kronish JP, Cohen NH, Young WL. Miller'S Anesthesia. 8th ed. Amsterdam, Elsevier. 2015, pp 1651-3.
2. Badheka JP, Doshi PM, Vyas AM, Kacha NJ, Parmar VS. Comparison of upper lip bite test and ratio of height to thyromental distance with other airway assessment tests for predicting difficult endotracheal intubation. *Indian J Crit Care Med* 2016; 20: 3-8.
3. Reddy PB, Punetha P, Chalam KS. Ultrasonography - A viable tool for airway assessment. *Indian J Anaesth* 2016; 11: 807-13.
4. Connor CW, Segal S. The importance of subjective facial appearance on the ability of anesthesiologists to predict difficult intubation. *Anesth Analg* 2014; 118: 419-27.
5. Mahmoodpoor A, Soleimanpour H, Golzari SE, Nejabatian A, Poulak T, Amani M, et al. Determination of the diagnostic value of the modified mallampati score, upper lip bite test and facial angle in predicting difficult intubation: a prospective descriptive study. *J Clin Anesth* 2017; 37: 99-102.
6. Guay J, Kopp S. Ultrasonography of the airway to identify patients at risk for difficult tracheal intubation : are we there yet? *J Clin Anesth* 2018; 46: 112-5.
7. Luba K, Apfelbaum JL, Cutter TW. Airway management in the outpatient setting. *Clin Plast Surg* 2013; 40: 405-17.
8. Kohjitani A, Miyawaki T, Miyawaki S, Nakamura N, Iwase Y, Nishihara K, et al. Features of lateral cephalograms associated with difficult laryngoscopy in Japanese children undergoing oral and maxillofacial surgery. *Paediatr Anaesth* 2013; 23: 994-1001.
9. Chhina AK, Jain R, Gautam PL, Garg J, Singh N, Grewal A. Formulation of a multivariate predictive model for difficult intubation : a double blinded prospective study. *J Anaesthesiol Clin Pharmacol* 2018; 34: 62-7.
10. Chaconas SJ, Fragiscos FD. Orthognathic diagnosis and treatment planning: a cephalometric approach. *J Oral Rehabil* 1991; 18: 531-45.
11. Graber LW, Vanarsdall RL, Vig KW, Huang G. Orthodontics: current principles and techniques. 6th ed. Amsterdam: Elsevier; 2015.
12. Dahy KG, Takahashi K, Saito K, Kakeno A, Kiso H, Isobe Y, et al. The relationship between cephalogram analysis and oxygen desaturation index during sleep in patients submitted for mandibular setback surgery. *J Craniofac Surg* 2018; 29: e375-80.
13. Narayanan A, Faizal B. Correlation of lateral cephalogram flexible laryngoscopy with sleep study in obstructive sleep apnea. *Int J Otolaryngol* 2015; 3: 1-7.
14. Kim D, Kim K, Sun J, Lim H. Conversion of an oral to nasal intubation in difficult nasal anatomy patients: two case reports. *BMC Anesthesiol* 2021; 21: 72.
15. Takasugi Y, Futagawa K, Konishi T, Morimoto D, Okuda T. Possible association between successful intubation via the right nostril and anatomical variations of the

- nasopharynx during nasotracheal intubation: a multiplanar imaging study. *J Anesth* 2016; 30: 987-93
16. Japanese Standards Association (JSA): JIS T 7221:2020 Anaesthetic and respiratory equipment tracheal tubes and connectors.
 17. Taharabaru S, Sato T, Nishiwaki K. Difficult airway management in a patient with Nicolaidis-baraitser syndrome who had a small jaw and limited mouth opening. *Anesth Prog* 2021; 68: 47-9.
 18. Cormack RS, Lehane J. Difficult tracheal intubation in obstetrics. *Anaesthesia* 1984; 39: 1105-11.
 19. Hyun K, Sumitomo S. Preoperative evaluation of the difficulty of laryngeal deployment. *J Jpn Dent Soc Anesthesiol* 1993; 21: 784-92.
 20. Ji C, Ni Q, Chen W. Diagnostic accuracy (CT, X-ray, US) for predicting difficult intubation in adults : a meta-analysis. *J Clin Anesth* 2018; 45: 79-87.
 21. Yoo H, Choi JM, Jo JY, Lee S, Jeong SM. Blind nasal intubation as an alternative to difficult intubation approaches. *J Dent Anesth Pain Med* 2015; 15: 181-4.