

# A Case of Homocystinuria Misdiagnosed as Moyamoya Disease: A Case Report

Meltem Erol,<sup>1\*</sup> Ozlem Bostan Gayret,<sup>1</sup> Ozgul Yigit,<sup>1</sup> Kubra Serefoglu Cabuk,<sup>2</sup> Mehmet Toksoz,<sup>3</sup> and Mahir Tiras<sup>1</sup>

<sup>1</sup>Department of Pediatrics, Bagcilar Training and Research Hospital, Istanbul, Turkey

<sup>2</sup>Department of Ophthalmology, Bagcilar Training and Research Hospital, Istanbul, Turkey

<sup>3</sup>Department of Radiology, Bagcilar Training and Research Hospital, Istanbul, Turkey

\*Corresponding author: Meltem Erol, Department of Pediatrics, Bagcilar Training and Research Hospital, Istanbul, Turkey. Tel: +90-5324578397, Fax: +90-2124404242, E-mail: meltembagcilar@gmail.com

Received 2015 May 29; Revised 2015 August 07; Accepted 2015 August 30.

## Abstract

**Introduction:** Homocystinuria is a hereditary disease caused by a defect in the enzymes involved in metabolizing methionine. Homocystinuria can influence many systems and may be mistaken for other diseases, including Moyamoya disease. Here, we report the case of a 10-year-old male patient with a diagnosis of Moyamoya disease who had been monitored for that for an extended period. The patient's diagnosis was changed to homocystinuria as a result of lens subluxation and cataract findings.

**Case Presentation:** A 10-year-old male patient presented with vomiting, headache, lethargy, muscular weakness, and eye redness. The patient was mentally retarded, his right pupil was hyperemic, and he had muscle weakness on his left side. In addition, his blood pressure was high. The patient's history included a diagnosis of Moyamoya. A neck and cranial computed tomography (CT) angiography showed no flow bilaterally past the bifurcation of the carotid artery. The patient's bilateral internal carotid arteries were determined to be occluded. It was considered that his eye findings could be compatible with a metabolic disease. On metabolic screening, the patient's homocysteine level was very high. In addition, a heterozygous A1298C mutation was identified in *MTHFR*. Therefore, the patient was started on a diet free from homocysteine and methionine. In addition, his treatment regimen included vitamins B12 and B6. With these treatments, the patient's complications regressed.

**Conclusions:** In cases of unusual vascular lesions, metabolic diseases must be considered. In homocystinuria, early diagnosis and treatment are important. Blood homocysteine levels can be returned to normal, and some complications can be prevented.

**Keywords:** Metabolic Disease, Lens Subluxation, Moyamoya Disease

## 1. Introduction

Homocystinuria is a hereditary disease involving a failure to metabolize methionine. It is characterized by mental retardation, an atypical facial appearance, lens dislocation, skeletal anomalies, osteoporosis, and thrombosis (1). Homocysteine metabolism occurs via two major pathways. The first is remethylation back to methionine, using vitamin B12 as a cofactor. The second is trans-sulfuration to cysteine, using vitamin B6 as a cofactor. These reactions reduce the total homocysteine concentrations in the cells and blood (2). Hyperhomocysteinuria is caused by deficiencies in methylene tetrahydrofolate reductase (*MTHFR*), cystathionine beta synthase, or enzymes involved in homocysteine methylation and methyl-B12 synthesis (1). Arterial and venous thrombosis and arteriosclerosis may be seen in patients with homocysteinemia (2). Although the mechanism of damage due to homocysteine is not entirely clear, it is believed that disturbances in methylation reactions ultimately lead to vascular obstruction (3). Cerebral infarcts

or strokes among children are rare, but they can cause significant morbidity and mortality (4).

Moyamoya disease can also present with progressive stenosis or occlusion of the intracranial internal carotid artery. The clinical presentation and imaging findings may be similar to those of homocystinuria (5).

In homocystinuria, early diagnosis is important. It has been suggested that early detection and treatment are helpful and that homocysteine levels can be controlled with vitamins B6 and B12, which are cofactors needed for homocysteine metabolism, and with folic acid supplements (2).

This article presents the case of a patient who had been diagnosed with Moyamoya disease and followed for an extended period. The patient's ocular findings were compatible with homocystinuria; thus, he was evaluated for metabolic disease and ultimately diagnosed as having homocystinuria. After beginning an appropriate diet and treatment regimen consisting of folate and vitamin B12, the patient's clinical findings regressed moderately.

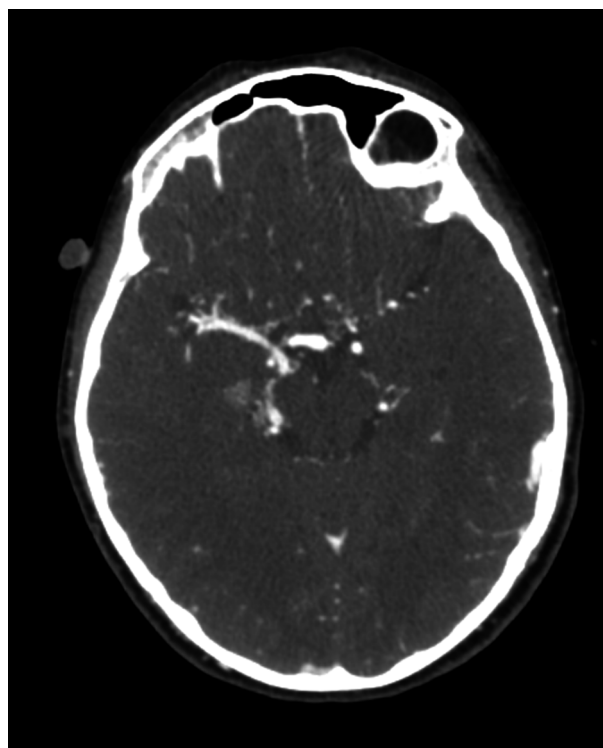
## 2. Case Presentation

The hospital ethics committee approved the protocol for this study (No. 2015-378).

In June 2014, a 10-year-old male patient presented to the pediatric outpatient clinic of Bagcilar training and research hospital (Istanbul, Turkey) with vomiting, headache, lethargy, eye redness, and a speech disorder. On physical examination, the patient's body temperature was 37.3°C and his blood pressure was 189/110 mmHg (95th percentile, 125/80 mmHg). He also showed a mildly Marfan-like phenotype. He had muscular weakness on the left side and a dilated, hyperemic right pupil. An examination of mental state at admission showed poor socialization, isolation, learning difficulties, and mild mental retardation. Given these findings, the patient was hospitalized. The patient and his family had moved to Istanbul from another city. We learned that he had been hospitalized due to an intracranial pathology and had had surgery on his left eye when he was 5 years old, but no medical records of this could be obtained. His parents had no consanguineous relationship. The patient had long suffered from learning difficulties, and he had been followed at another hospital as a case of Moyamoya disease.

Following his admission to the pediatric clinic, antihypertensive treatment was initiated. Cranial computed tomography (CT) was normal. However, on cranial CT angiography, no flow was seen bilaterally in the anterior cerebral artery (ACA). The bilateral middle cerebral artery (MCA) and ACA territories were vascularized by a thick, right-posterior communicating artery (Figure 1). No flow was seen bilaterally past the carotid artery bifurcation level. The bilateral internal carotid arteries were occluded (Figure 2). Doppler ultrasound tests of the renal artery were normal, and no renal artery stenosis was found. The patient's complete blood cell count, biochemical test results, thyroid function, and serum levels of renin, aldosterone, cortisol, and cholesterol were normal. In addition, the patient's protein C, protein S, antithrombin III, and factor 5 Leiden levels were normal. Echocardiography showed increased wall thickness in the left ventricle.

Ocular examination was not compatible with hypertensive retinopathy. Lens luxation into the anterior camera and glaucoma were detected. An ophthalmologist reported that these specific ocular findings were compatible with a metabolic disease, especially homocystinuria. The patient's homocysteine level was 282  $\mu\text{mol/L}$  (normal level, 4.7 - 10.3  $\mu\text{mol/L}$ ), his vitamin B12 level was 108 pg/mL, and his folic acid level was 6.26 ng/mL. A treatment regimen with vitamins B12 and B6 was initiated. After 5 days of vitamin B12 treatment, the patient's vitamin B12 level was > 2000 pg/mL and his serum homocysteine level continued

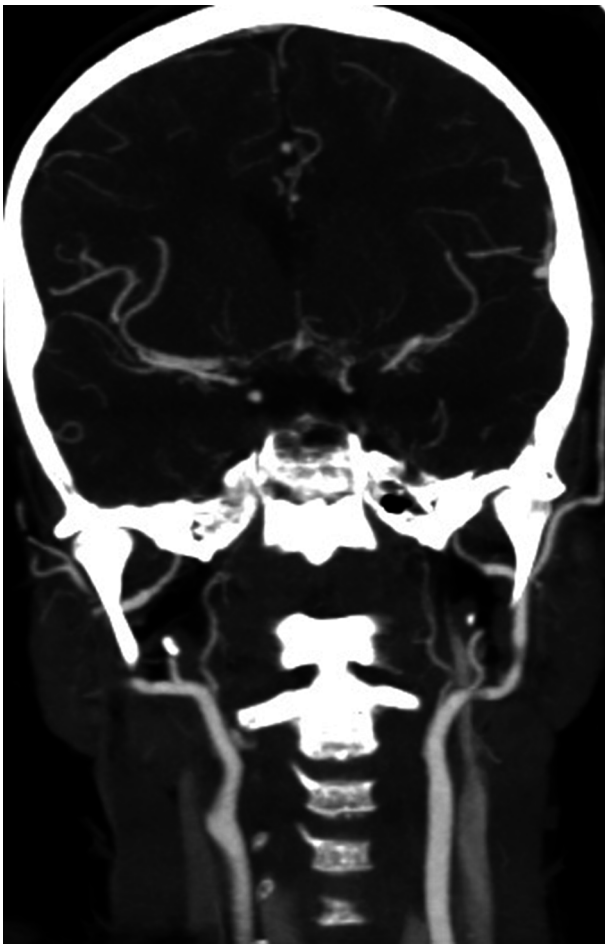


**Figure 1.** Bilaterally, no flow was seen in the ACA. Bilaterally, the MCA and ACA territories were vascularized by a thick, right-posterior communicating artery.

to be as high as 398  $\mu\text{mol/L}$ .

An analysis of the *MTHFR* gene revealed a heterozygous A1298C mutation. Therefore, the patient was referred to a specialist in pediatric endocrinology and metabolic diseases.

Table 1 summarizes the patient's descriptive and demographic findings. The patient was prescribed a diet free from homocysteine and methionine and a treatment regimen consisting of betaine and vitamins B12 and B6. Each day, he was administered 400 mg of vitamin B6 and 15 mg of folic acid. During this period, the patient's blood pressure values were high and antihypertensive treatment continued. After 15 days, the patient's homocysteine level regressed to 23.4  $\mu\text{mol/L}$  and his blood pressure was under control. Acetyl salicylic acid was used to protect against possible thromboembolic complications. Then, the patient underwent surgery at the eye clinic for lens subluxation and glaucoma. After the surgery, the acetyl salicylic acid treatment was terminated. At the one-year follow-up examination, the patient's mental status and cognitive functions were found to have improved. However, treatment with vitamin B6 and folic acid continues.



**Figure 2.** Carotid artery occlusion at the bifurcation level was observed by cranial CT angiography.

### 3. Discussion

Homocystinuria is a congenital metabolic disease identified in 1962 by Field et al. (5, 6). The most characteristic and earliest symptoms of homocystinuria are subluxation of the lens and progressive myopia. Mental retardation, cognitive impairment, a Marfan-like phenotype, osteoporosis, and cerebrovascular and cardiac thrombosis are other presenting symptoms (7). The wide range of both symptoms and severity can make diagnosis a challenge for even the most experienced clinician. As each particular manifestation of the disease should be evaluated in a different specialized clinical setting, it can be difficult to gather all of the relevant information to make an informed diagnosis (8). Because of the potential for serious complications, including increased tendency toward stroke, ocular complications, and mental impairment, early diagnosis and regular medical follow-ups are essential (9).

**Table 1.** Patient's Descriptive and Demographic Data

Demographic Data	Descriptive Data
Gender	Male
Age, y	10
Medical history	He had been followed for Moyamoya disease from the age of 5 years. He had had surgery on his left eye (we could not obtain the medical records).
Presenting symptoms	Vomiting, headache, lethargy, eye redness, and a speech disorder
Examination findings	Muscular weakness on the left side, lethargy, mental retardation, a dilated, hyperemic right pupil, and a Marfan-like phenotype
Blood pressure	Before treatment: 189/110 mmHg. After 15 days of treatment: 120/75 mmHg
Ocular findings	Lens subluxation and a secondary cataract
CT angiography	Bilaterally, no flow was seen after the level of the carotid artery bifurcation. Bilaterally, internal carotid arteries were occluded.
Homocysteine level	Initial level: 282 $\mu\text{mol/L}$ . After 15 days of treatment: 23.4 $\mu\text{mol/L}$
MTHFR genetic analysis	Heterozygous A1298C
Vitamin B12 level, pg/mL	108
Folic acid level, ng/mL	6.26
Ongoing clinical situation	Normal blood pressure. Normal homocysteine levels. Moderate improvement of cognitive functions

The patient had undergone surgery on his left eye when he was 5 years old, probably because of lens subluxation and glaucoma. However, no medical records could be obtained. These ocular findings were likely his first presenting symptoms. Since the patient's ocular findings were not evaluated properly, his diagnosis was delayed.

During the same period, the patient had had a history of hospitalization due to intracranial hemorrhagic pathology. This might have developed due to a thrombosis related to homocystinuria. His previous medical records mention bilateral carotid occlusion as an MRI finding.

Bilateral carotid occlusion is rare in children (10). Moyamoya disease is a rare disorder of the connective tissue of unknown origin that causes cerebrovascular occlusive disease. The main symptoms of Moyamoya disease are bilateral steno-occlusive changes at and around the internal carotid artery bifurcation, along with abnormal net-like vessels, called moyamoya, in the basal ganglia (11).

Neurological deficits in children with Moyamoya disease can present as dysarthria, aphasia, hemiparesis, paraparesis, or visual symptoms. Mental retardation has been observed in pediatric cases (11, 12). This patient had hemiparesis and mental retardation. He was first hospitalized

for hypertension and the presumptive diagnosis of Moyamoya disease.

The clinical symptoms of homocystinuria include subluxation of the lens, which is also a characteristic feature of connective-tissue disorders (2). However, the eye findings, including lens subluxation, a secondary cataract, and poor vision, discovered during this patient's eye examination pointed to a metabolic disease. In addition, in agreement with previously published cases of homocystinuria, the patient had a Marfan-like phenotype, mental retardation, and cerebrovascular thrombosis with carotid-artery occlusion at the bifurcation level on CT angiography.

The normal plasma homocysteine level is 5 - 15  $\mu\text{mol/L}$ ; 16 - 30  $\mu\text{mol/L}$  is moderate, 31 - 100  $\mu\text{mol/L}$  is intermediate, and a level above 100  $\mu\text{mol/L}$  indicates severe homocystinemia (7, 12, 13). Thus, the patient's homocysteine level, 282  $\mu\text{mol/L}$ , was considered extremely high. In addition, he had severe hypertension at admission. Hyperhomocystinemia can lead to various complications. Severe hyperhomocystinemia causes thrombosis of systemic arteries and arterial endothelial dysfunction (14, 15). The literature contains no cases of systemic hypertension associated with hyperhomocystinemia. However, one case had pulmonary hypertension that complicated homocystinuria (15).

*MTHFR* plays an important role in the folate cycle and contributes to the metabolism of homocysteine (1, 3). There is an association between *MTHFR* mutations and elevated levels of homocysteine. The *MTHFR* gene has at least two functional polymorphisms, 677 C > T and 1298 A > C. The *MTHFR* 677 T allele is associated with reduced enzymatic activity, decreased levels of folate in serum, and increased plasma homocysteine levels (1). In addition, *MTHFR* 1298 A > C has decreased enzymatic activity, but it has been reported that this does not elevate plasma homocysteine concentrations (16). Although the patient's genetic analysis showed a heterozygous A1298C mutation, his homocysteine level was extremely high. The presence of these mutations also increases the risk of thrombosis (14).

Homocystinuria cases may present with various clinical symptoms. The literature reports two cases with behavioral disorders and psychotic symptoms (2, 7, 8).

Evidence indicates that appropriate treatment of homocystinuria markedly reduces the risk of vascular complications, even if biochemical control is suboptimal (17). In most cases, vitamin supplementation results in near-normalization of plasma homocysteine. Homocysteine metabolism requires the participation of folate as well as vitamins B12 (cobalamin) and B6 (pyridoxal phosphate) as coenzymes; In addition, a diet low in methionine is important. Betaine is a methyl donor; it has the effect of converting homocysteine to methionine, and it can be used as

a supplementary treatment. Antiplatelet treatment must be applied to all patients with homocystinuria who have a history of cerebral infarction (3). An appropriate diet and treatment with folate and vitamins B12 and B6 can prevent serious complications.

### 3.1. Conclusions

In cases of unusual vascular lesions, metabolic diseases must be kept in mind. In addition, homocystinuria must be considered in addition to Moyamoya disease in cases with bilateral carotid occlusion, which may be observed in childhood. Slow stroke phases, with continued progressive stenosis and eventual occlusion, are important in homocystinuria, and it must be remembered that it may affect many systems. As each particular manifestation of the disease should be evaluated in a different specialized setting, it can be difficult to gather all the relevant information to make an informed diagnosis. Therefore, patients should be evaluated as a whole. Early diagnosis is important, and many complications can be prevented or reduced with an appropriate diet and treatment regimen.

### Acknowledgments

We thank the department of radiology for its technical support.

### Footnote

**Authors' Contribution:** Study concept and design: Meltem Erol; acquisition of data: Meltem Erol and Mahir Tiras; analysis and interpretation of data: Meltem Erol and Ozlem Bostan Gayret; drafting of the manuscript: Meltem Erol and Kubra Cabuk Serefoglu; critical revision of the manuscript for important intellectual content: Ozgul Yigit; administrative, technical, and material support: Ozlem Bostan Gayret and Mahir Tiras; study supervision: Ozgul Yigit.

### References

- Selhub J. Homocysteine metabolism. *Annu Rev Nutr.* 1999;**19**:217-46. doi:10.1146/annurev.nutr.19.1.217. [PubMed: 10448523].
- Karimzadeh P, Jafari N, Alai M, Jabbehdari S, Nejad Biglari H. Homocystinuria: Diagnosis and Neuroimaging Findings of Iranian Pediatric patients. *Iran J Child Neurol.* 2015;**9**(1):94-8. [PubMed: 25767545].
- Matte C, Mackedanz V, Stefanello FM, Scherer EB, Andrezza AC, Zanutto C, et al. Chronic hyperhomocystinemia alters antioxidant defenses and increases DNA damage in brain and blood of rats: protective effect of folic acid. *Neurochem Int.* 2009;**54**(1):7-13. doi: 10.1016/j.neuint.2008.08.011. [PubMed: 18983880].

4. Per H, Unal E, Poyrazoglu HG, Ozdemir MA, Donmez H, Gumus H, et al. Childhood stroke: results of 130 children from a reference center in Central Anatolia, Turkey. *Pediatr Neurol*. 2014;**50**(6):595-600. doi: [10.1016/j.pediatrneurol.2013.12.023](https://doi.org/10.1016/j.pediatrneurol.2013.12.023). [PubMed: [24842257](https://pubmed.ncbi.nlm.nih.gov/24842257/)].
5. Guey S, Tournier-Lasserre E, Herve D, Kossorotoff M. Moyamoya disease and syndromes: from genetics to clinical management. *Appl Clin Genet*. 2015;**8**:49-68. doi: [10.2147/TACG.S42772](https://doi.org/10.2147/TACG.S42772). [PubMed: [25733922](https://pubmed.ncbi.nlm.nih.gov/25733922/)].
6. Carson NA, Neill DW. Metabolic abnormalities detected in a survey of mentally backward individuals in Northern Ireland. *Arch Dis Child*. 1962;**37**:505-13. [PubMed: [14018926](https://pubmed.ncbi.nlm.nih.gov/14018926/)].
7. Colafrancesco G, Di Marzio GM, Abbracciavento G, Stoppioni V, Leuzzi V, Ferrara M. Acute psychosis in an adolescent with undiagnosed homocystinuria. *Eur J Pediatr*. 2015;**174**(9):1263-6. doi: [10.1007/s00431-015-2552-2](https://doi.org/10.1007/s00431-015-2552-2). [PubMed: [25939413](https://pubmed.ncbi.nlm.nih.gov/25939413/)].
8. Hidalgo Mazzei D, Martin Rodriguez S, Perez Molto H, Ruiz Izquierdo J, Baeza I. A forgotten lethal psychosis: a case report. *Eur Child Adolesc Psychiatry*. 2014;**23**(4):235-8. doi: [10.1007/s00787-013-0449-z](https://doi.org/10.1007/s00787-013-0449-z). [PubMed: [23812867](https://pubmed.ncbi.nlm.nih.gov/23812867/)].
9. Garland J, Prasad A, Vardy C, Prasad C. Homocystinuria: Challenges in diagnosis and management. *Paediatr Child Health*. 1999;**4**(8):557-62. [PubMed: [20213008](https://pubmed.ncbi.nlm.nih.gov/20213008/)].
10. Han DH, Kwon OK, Byun BJ, Choi BY, Choi CW, Choi JU, et al. A cooperative study: clinical characteristics of 334 Korean patients with moyamoya disease treated at neurosurgical institutes (1976-1994). The Korean Society for Cerebrovascular Disease. *Acta Neurochir (Wien)*. 2000;**142**(11):1263-73. [PubMed: [11201642](https://pubmed.ncbi.nlm.nih.gov/11201642/)] discussion 1273-4.
11. Mugikura S, Takahashi S, Higano S, Shirane R, Kurihara N, Furuta S, et al. The relationship between cerebral infarction and angiographic characteristics in childhood moyamoya disease. *AJNR Am J Neuroradiol*. 1999;**20**(2):336-43. [PubMed: [10094366](https://pubmed.ncbi.nlm.nih.gov/10094366/)].
12. Kang SS, Wong PW, Malinow MR. Hyperhomocyst(e)inemia as a risk factor for occlusive vascular disease. *Annu Rev Nutr*. 1992;**12**:279-98. doi: [10.1146/annurev.nu.12.070192.001431](https://doi.org/10.1146/annurev.nu.12.070192.001431). [PubMed: [1503807](https://pubmed.ncbi.nlm.nih.gov/1503807/)].
13. Weiss N, Keller C, Hoffmann U, Loscalzo J. Endothelial dysfunction and atherothrombosis in mild hyperhomocysteinemia. *Vasc Med*. 2002;**7**(3):227-39. [PubMed: [12553746](https://pubmed.ncbi.nlm.nih.gov/12553746/)].
14. Brustolin S, Giugliani R, Felix TM. Genetics of homocysteine metabolism and associated disorders. *Braz J Med Biol Res*. 2010;**43**(1):1-7. [PubMed: [19967264](https://pubmed.ncbi.nlm.nih.gov/19967264/)].
15. Ogawa S, Katayama T, Kaikita K, Tsukamoto M, Yamamoto E, Yamamoto M, et al. Chronic thromboembolic pulmonary hypertension complicated with homocystinuria. *Intern Med*. 2014;**53**(22):2605-8. [PubMed: [25400183](https://pubmed.ncbi.nlm.nih.gov/25400183/)].
16. Lievers KJ, Boers GH, Verhoef P, den Heijer M, Kluijtmans LA, van der Put NM, et al. A second common variant in the methylenetetrahydrofolate reductase (MTHFR) gene and its relationship to MTHFR enzyme activity, homocysteine, and cardiovascular disease risk. *J Mol Med (Berl)*. 2001;**79**(9):522-8. doi: [10.1007/s001090100253](https://doi.org/10.1007/s001090100253). [PubMed: [11692165](https://pubmed.ncbi.nlm.nih.gov/11692165/)].
17. Wilcken DE. Overview of inherited metabolic disorders causing cardiovascular disease. *J Inherit Metab Dis*. 2003;**26**(2-3):245-57. [PubMed: [12889664](https://pubmed.ncbi.nlm.nih.gov/12889664/)].