

Case Report

Coexistence of Vulvar Dowling-Degos Disease and Seborrheic Keratosis

R. Guedes¹ and Luiz Leite²

¹ Serviço de Dermatologia, Centro Hospitalar de Vila Nova de Gaia, Rua Conceição Fernandes, 4434-502 Vila Nova de Gaia, Portugal

² Departamento de Dermatologia, Clínica Laser Belém, Calçada da Ajuda 72, 1300 012 Lisboa, Portugal

Correspondence should be addressed to R. Guedes, ritapereiraguedes@gmail.com

Received 28 March 2011; Revised 20 June 2011; Accepted 27 June 2011

Academic Editor: Robert S. Dawe

Copyright © 2011 R. Guedes and L. Leite. This is an open access article distributed under the Creative Commons Attribution License, which permits unrestricted use, distribution, and reproduction in any medium, provided the original work is properly cited.

Dowling-Degos disease is a rare autosomal dominant inherited pigmentary disorder, mostly confined to the flexures. Diagnosis is established based on the clinical and histopathological correlation. The authors describe the clinical case of a female patient with vulvar involvement and multiple seborrheic keratoses on her face, neck, and upper trunk. Major and minor clinical manifestations of Dowling-Degos disease are discussed, with particular emphasis on the genital location of the lesions, which is a rare finding. Also the presence of seborrheic keratosis is discussed as a coincidence or a true-associated phenomenon.

1. Introduction

Dowling-Degos disease (DDD) or reticulate pigmented anomaly of the flexures is a rare autosomal dominant inherited disease [1]. The disorder usually appears after puberty and is more frequent in the female gender. Diagnosis is established based on the clinical and histopathological correlation. Until now there are approximately 50 cases described in the literature [2].

2. Case Report

We describe the clinical case of a 38-year-old female patient who presented to the outpatient clinic with numerous unaesthetic, pruritic lesions on her face, neck, and upper trunk. She reported to have these lesions for more than 10 years. A few years ago she had also noticed similar lesions on her genitals. Clinically we observed multiple seborrheic keratosis over her face, neck, and upper trunk (Figure 1). Moreover, on the complete dermatological examination, we additionally observed multiple genital small, round, dark-brown macules with 1 mm to 0,5 cm of diameter, smooth surface, and dark-brown colour (Figure 2). The lesions had symmetrical distribution in the labia major and were asymptomatic. None of the other family members had similar findings, and she was otherwise healthy.

We performed two biopsies, namely, of one neck and one genital lesion.

Histology of a neck lesion revealed acanthosis, hyperkeratosis, and papillomatosis consistent with the clinical diagnosis of seborrheic keratosis. Histological examination of one genital macule showed elongation of rete ridges in a branching form with basal hyperpigmentation. There were no atypical keratinocytes or melanocytes (Figure 3).

These clinical and histopathological findings were consistent with the diagnosis of DDD. The patient was submitted to several carbon dioxide laser (CO₂) sessions in order to treat the seborrheic keratosis. Because the genital lesions were asymptomatic, we did not perform any treatment.

3. Discussion

Dowling-Degos disease was described by Wilson-Jones and Grice in 1978 [3] as a reticulate pigmented anomaly of the flexures. Although some authors have proposed a loss-of-function mutation on chromosome 12 (in the KRT5 gene encoding for keratin 5), leading to melanosome uptake deficiencies [1], the exact pathophysiology is still unknown.

Clinically it is characterized by acquired hyperpigmentation affecting the flexures, pitted perioral acneiform scars, and hyperkeratotic comedo-like lesions on the neck [4]. In addition to these major features, minor features have also

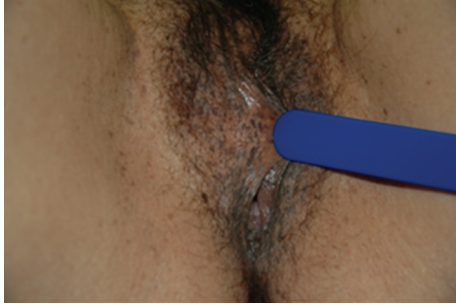

FIGURE 1: Dark-brown macules in the labia major.

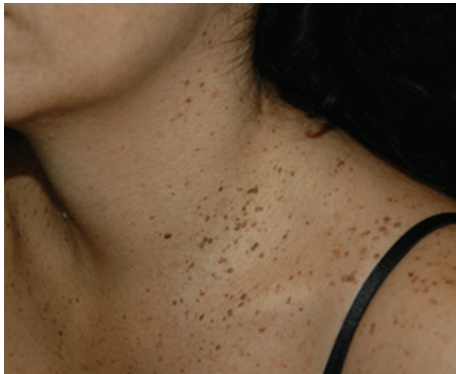

FIGURE 2: Multiple seborrheic keratosis over the patients' neck and upper trunk.

been described, including dystrophic fingernails, multiple keratoacanthomas, pilonidal sinus, seborrheic keratosis, and hidradenitis suppurativa [4].

As differential diagnosis one has to exclude acanthosis *nigricans*, Galli-Galli disease, Kitamura reticulate acropigmentation, and Haber's syndrome. Acanthosis *nigricans* is characterized by velvetlike plaques with no other minor criteria of DDD. Histopathologically, unlike DDD, papillomatosis can be observed together with the elongation of the rete ridges. Galli-Galli disease is a rare variant of DDD with acantholysis on the histology [5], and Kitamura reticulate acropigmentation affects the extensor surfaces of the hands and feet, both characteristics not observed in the described patient. Finally, Haber's syndrome was excluded due to the lack of persistent rosacea-like lesions, characteristic of this syndrome.

The association of DDD and seborrheic keratosis has been previously reported, and their simultaneous occurrence is based on the theory of a single underlying defect in follicular keratinization as main pathological mechanism [4]. Their occurrence, especially in young patients [6, 7], helped to establish them as a minor criterion of DDD. Likewise, genital involvement is rare, and, until today, only six case reports of DDD affecting the vulva are described in the literature [8–11], with skin lesions usually confined to the external genital areas.

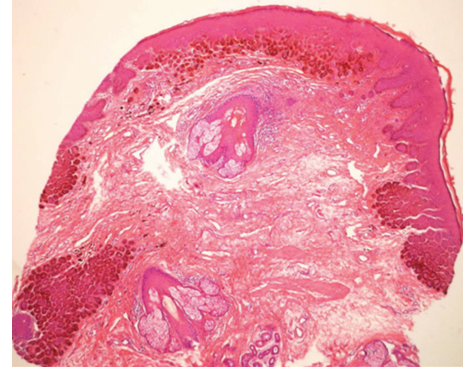


FIGURE 3: Histology findings of one vulvar lesion showing the typical elongation of the rete ridges with basal hyperpigmentation; H&E 40*.

Our case is unusual in that there was reticulate hyperpigmentation affecting the vulva but without other characteristic findings (perioral scars and comedo-like lesions). Instead, multiple seborrheic keratoses were observed. Both are rare findings in this disorder.

4. Conclusion

The aim of this paper is to report the rarity of vulvar involvement in this disease and the association between seborrheic keratosis and DDD. In fact, seborrheic keratoses are not major features in this disease, but in our case they were the triggering factor for the clinical suspicion. Indeed, it is uncommon to observe patients in the 3rd decade of life with a high number of these lesions. We hope that in the future there will be more awareness of this association, in order to perform the correct diagnosis.

To our knowledge this is the first report of vulvar DDD associated with seborrheic keratosis.

Conflict of Interests

The authors declare that there is no conflict of interests.

References

- [1] R. C. Betz, L. Planko, S. Eigelshoven et al., "Loss-of-function mutations in the keratin 5 gene lead to Dowling-Degos disease," *American Journal of Human Genetics*, vol. 78, no. 3, pp. 510–519, 2006.
- [2] Y. C. Kim, M. D. P. Davis, C. F. Schanbacher, and W. P. D. Su, "Dowling-Degos disease (reticulate pigmented anomaly of the flexures): a clinical and histopathologic study of 6 cases," *Journal of the American Academy of Dermatology*, vol. 40, no. 3, pp. 462–467, 1999.
- [3] E. Wilson-Jones and K. Grice, "Reticulate pigmented anomaly of the flexures," *Archives of Dermatology*, vol. 114, no. 8, pp. 1150–1157, 1978.
- [4] C. R. Rubio, M. Mayor, M. A. Martín, M. J. González-Beato, F. Contreras, and M. Casado, "Atypical presentation of Dowling-Degos disease," *Journal of the European Academy of*

- Dermatology and Venereology*, vol. 20, no. 9, pp. 1162–1164, 2006.
- [5] H. Gilchrist, S. Jackson, L. Morse, and L. T. Nesbitt, “Galli-Galli disease: a case report with review of the literature,” *Journal of the American Academy of Dermatology*, vol. 58, no. 2, pp. 299–302, 2008.
- [6] S. Cliff, M. Otter, M. G. Cook, and R. A. Marsden, “Dowling Degos disease in association with multiple seborrhoeic warts,” *Clinical and Experimental Dermatology*, vol. 22, no. 1, pp. 34–36, 1997.
- [7] H. J. Cramer, “Verrucosis seborrhoica,” *Hautarzt*, vol. 20, no. 1, pp. 31–34, 1969.
- [8] C. Massone and R. Hofmann-Wellenhof, “Dermoscopy of Dowling-Degos disease of the vulva,” *Archives of Dermatology*, vol. 144, no. 3, pp. 417–418, 2008.
- [9] K. I. O’Goshi, T. Terui, and H. Tagami, “Dowling-Degos disease affecting the vulva,” *Acta Dermato-Venereologica*, vol. 81, no. 2, p. 148, 2001.
- [10] P. Milde, G. Goerz, and G. Plewig, “Dowling-Degos disease with exclusively genital manifestation,” *Hautarzt*, vol. 43, no. 6, pp. 369–372, 1992.
- [11] V. Fernández-Redondo, A. Losada, A. Zulaica, C. Cebreiro, R. Cervantes, and J. Toribio, “Dowling-Degos disease,” *Medicina cutanea ibero-latino-americana*, vol. 18, no. 2, pp. 96–100, 1990.