

Case Report

A case of ovarian yolk sac tumor associated with endometrioid adenocarcinoma

Chiho Koi^{a,1}, Tomoko Kurita^{a,*}, Seiji Kagami^{a,1}, Atsuji Matsuyaya^{b,1}, Toru Hachisuga^{a,1}^a Department of Obstetrics and Gynecology, University of Occupational and Environmental Health School of Medicine, 1-1 Iseigaoka, Yahatanishi-ku, Kitakyusyu 807-8555, Japan^b Department of Pathology-1, University of Occupational and Environmental Health School of Medicine, 1-1 Iseigaoka, Yahatanishi-ku, Kitakyusyu 807-8555, Japan

ARTICLE INFO

Article history:

Received 24 February 2014

Accepted 21 April 2014

Available online 29 April 2014

Keyword:

Ovarian yolk sac tumor

Endometrioid adenocarcinoma

Endometriosis

Alpha-fetoprotein

Introduction

Ovarian yolk sac tumor (YST) is characterized by endodermal differentiation, and represents approximately 20% of malignant germ cell neoplasms. The age distribution of patients reported with YST ranges from 16 months to 46 years, but most patients are under 30 years of age (Talerman and Vang, 2011). YST is often found admixed with other types of germ cell neoplasm, but YST associated with epithelial ovarian carcinoma is extremely rare (Talerman and Vang, 2011). Unlike pure YST, YST associated with epithelial ovarian carcinoma is reported in elderly patients, and has a poor response to chemotherapy. Here we describe a case of YST associated with endometrioid adenocarcinoma in a postmenopausal woman. Our patient responded favorably to treatment with Docetaxel and Carboplatin combination chemotherapy, and has survived without evidence of relapse for 48 months postoperatively including a long term follow-up program. To the best of our knowledge, this is the first report of YST associated with endometrioid adenocarcinoma with longterm (>48 months) successful therapy treatment, according to a Medline search of English publications.

Case report

A 56-year-old postmenopausal woman presented with abdominal fullness and a rapid weight gain of 5 kg in a week. She had an approximately 10 cm pelvic mass upon physical examination, and a left adnexal mass was

palpable with tenderness upon pelvic examination. Magnetic resonance imaging (MRI) demonstrated a 12 × 10 cm multilocular cystic mass containing several solid portions with multiple disseminations and ascites in her pelvis. Computed tomography (CT) did not detect any sign of distant metastasis or lymphadenopathy. Preoperative CA125 was 88.6 U/ml (normal <35 U/ml), and alpha-fetoprotein (AFP) was not evaluated at this point. She underwent total abdominal hysterectomy with bilateral salpingo-oophorectomy, pelvic lymphadenectomy, partial omentectomy, appendectomy, and partial peritonectomy. The ascetic fluid (3030 ml) was hemorrhagic and positive by cytologic examination. The right ovary was replaced by a tumor, 12 × 7 cm in diameter with a smooth surface. The cyst contained brown serous fluid and a 3 cm solid tumor with necrotic tissue. The left ovary was normal, but uterine serosa, omentum, and mesentery had multiple nodules with easy bleeding. There were also many peritoneal disseminated tumors within the pelvis and the abdominal cavity, and under the diaphragm. We could not resect completely, and all mesentery nodules and most tumors under the diaphragm were residual. The reduction rate was estimated to be about 60% of the whole tumors. The histopathological examination demonstrated a yolk sac tumor with endometrioid adenocarcinoma (G3) of the ovary. The diagnosis was staged as pT3cN0M0. We measured a preoperative AFP serum level using reserved serum, of 374,700 ng/ml (normal <20 ng/ml). A combination chemotherapy including Bleomycin, Etoposide, and Cisplatin (BEP chemotherapy) to target the YST component was initiated. However there was no response after two courses. CT showed the appearance of liver metastasis and an increase of residual tumors. Docetaxel and Carboplatin combination chemotherapy (DC chemotherapy) was administered. The high AFP serum level declined rapidly after starting the DC chemotherapy, falling within the normal range after four courses (Fig. 1). Furthermore, most of the liver metastasis and multiple residual tumors disappeared after six courses (Fig. 2). Our patient's follow-up consisted of monthly AFP serum level tests and CT images every three months.

Histopathological findings

There were two different types of histological components. The first element was YST, composed of mainly reticular or papillary patterns (Fig. 3A-1). The second one was poorly differentiated endometrioid adenocarcinoma, which showed solid growth and complex glandular patterns with marked nuclear pleomorphism and mitotic activity (Fig. 3B-1). Furthermore, there were some foci of endometriosis composed of an epithelial lining and endometrial stromal cells.

* Corresponding author. Fax: +81 93 691 9337.

E-mail address: t-kurita@med.uoeh-u.ac.jp (T. Kurita).¹ Fax: +81 93 691 9337.

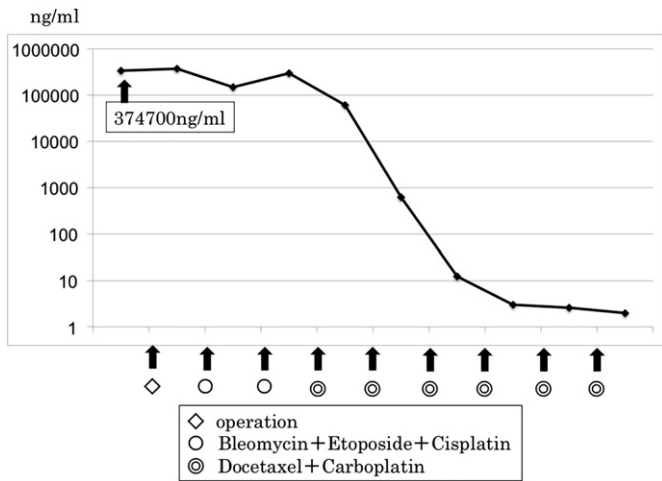


Fig. 1. Serum AFP levels. The high serum AFP level declined rapidly after DC chemotherapy.

Immunohistochemical findings

Immunohistochemical studies demonstrated that the YST component was positive for AFP, but negative for CK7 and EMA (Fig. 3A-2, 3, 4). In contrast, the endometrioid adenocarcinoma component was negative for AFP, but positive for CK7 and EMA (Fig. 3B-2, 3, 4). Immunohistochemical findings confirmed that this tumor had both YST and endometrioid adenocarcinoma elements.

Discussion

In 1987, Rutgers et al. reported the case of “ovarian YST arising from an endometrioid carcinoma” for the first time (Rutgers et al., 1987); since then thirteen cases of YST with endometrioid adenocarcinoma have been reported (Rutgers et al., 1987; Nogales et al., 1996; Kamoi et al., 2002; Hong et al., 2010). Nogales et al. characterized the features of this rare tumor as follows: (1) Most of these tumors occur in perimenopausal woman. (2) Endometriosis often coexists with these tumors as a precursor lesion. (3) Both the YST component and the

endometrioid component show typical histological patterns, respectively. (4) Immunohistochemical studies show that the YST component is positive for AFP, but the endometrioid component is negative for AFP (Nogales et al., 1996). The presented case coincided well with this definition. To summarize the previous thirteen cases, this tumor often had aggressive behavior and poor response to chemotherapy. Nine patients died within an average of 7 months (3–14 months) from the diagnosis, and the other four are disease-free at an average follow-up time of 16 months (12–21 months). Their prognosis had no correlation with the stage or the histologic grade of the endometrioid component.

According to the past literature, more than 38% of epithelial ovarian carcinoma secrete detectable amounts of AFP (Bose and Mukherjee, 1993), and 6.5% show histochemical evidence of AFP secretion in individual cells (Casper et al., 1984). Therefore, it is important not only to determine each different histological type, but also to distinguish immunohistochemically between the YST component and the endometrioid component. Ramalingam et al. reported on the use of CK7 and EMA in differentiating ovarian YST from endometrioid adenocarcinoma (Ramalingam et al., 2004). CK7 and EMA are negative in YST, but positive in endometrioid adenocarcinoma, while AFP is positive in YST, but negative in endometrioid adenocarcinoma. We also could distinguish this tumor from an endometrioid-like variant of YST that was proposed as a distinctive subtype of YST by Clement et al. (1987). They described the diagnostic features of YST that occur in young patients and immunohistochemical stains for AFP showed a positive reaction in the endometrioid-like foci as well as typical YST areas.

Although some theories have been proposed (Rutgers et al., 1987; Nogales et al., 1996; Kamoi et al., 2002; Hong et al., 2010), the biological behavior of this rare tumor is uncertain. This tumor often occurs in perimenopausal women and has poor response to chemotherapy. Therefore, the clinical characteristics are thought to resemble endometrioid adenocarcinoma rather than YST. On the other hand, the prognosis has no correlation with the stage or the histologic grade of the endometrioid component, and the YST component has a tendency to be seen in metastatic tumors and recurrent lesions. There is also a view that the YST component seems to influence the poor prognosis more so than the endometrioid component.

It is difficult to decide the treatment and determine the therapeutic target lesion for this tumor. Cisplatin-based chemotherapy was used as an adjuvant treatment in early reports (Nogales et al., 1996), and BEP

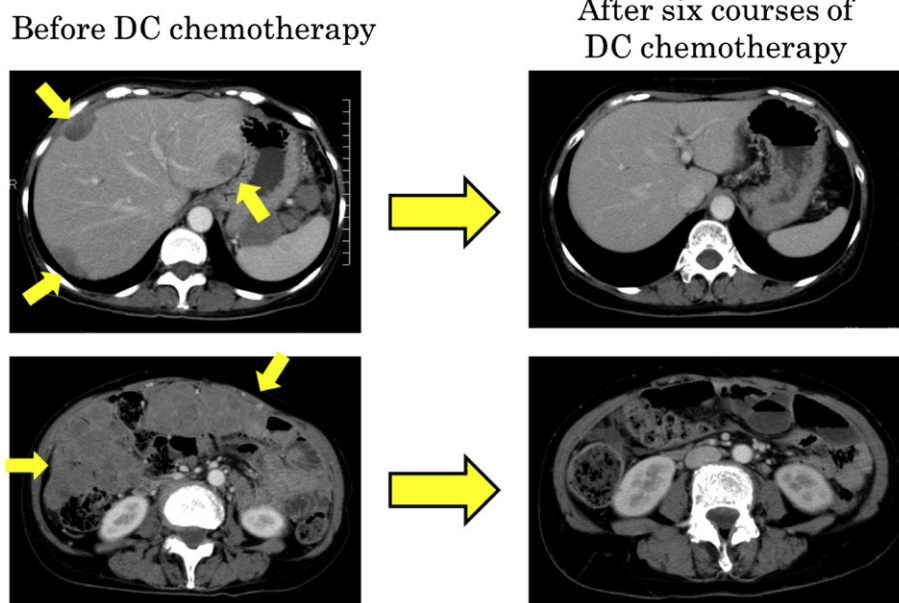


Fig. 2. Change of residual lesions by DC chemotherapy. Most of the liver metastasis and multiple residual tumors disappeared after six courses of DC chemotherapy.

chemotherapy (Kamoi et al., 2002) and intraperitoneal chemotherapy with Carboplatin (Kamoi et al., 2002) were given in the subsequent reports. In a recent report, Taxane and Carboplatin combination therapy after BEP chemotherapy was used (Hong et al., 2010). However, the effects of these treatments were different in each case, and there is no consensus about the effective therapy for this tumor.

Although YST associated with endometrioid adenocarcinoma is an extremely rare tumor, the recognition of this histological subtype is important in differential diagnosis, because this tumor is greatly different from pure YST in terms of the response to chemotherapy or the postoperative clinical course.

Despite our patient having residual lesions after operation, the high serum level of AFP declined to normal and the target lesions

reduced significantly after DC chemotherapy. Compared to previous reports, the response to chemotherapy and the clinical outcome are extremely good in our case. A combination of Taxane and Platinum has been suggested as the standard chemotherapy for not only endometrioid adenocarcinoma but also YST in pregnancy (Amant et al., 2009), and consequently it might be effective for both the YST and the endometrioid components. However, this treatment had a poor response in another past case (Hong et al., 2010). We could not determine the reason for her good prognosis, but plan to follow this patient carefully considering the clinicopathological features of this tumor. Although the number of cases is limited, the immediate establishment of treatment for this rare tumor is desired.

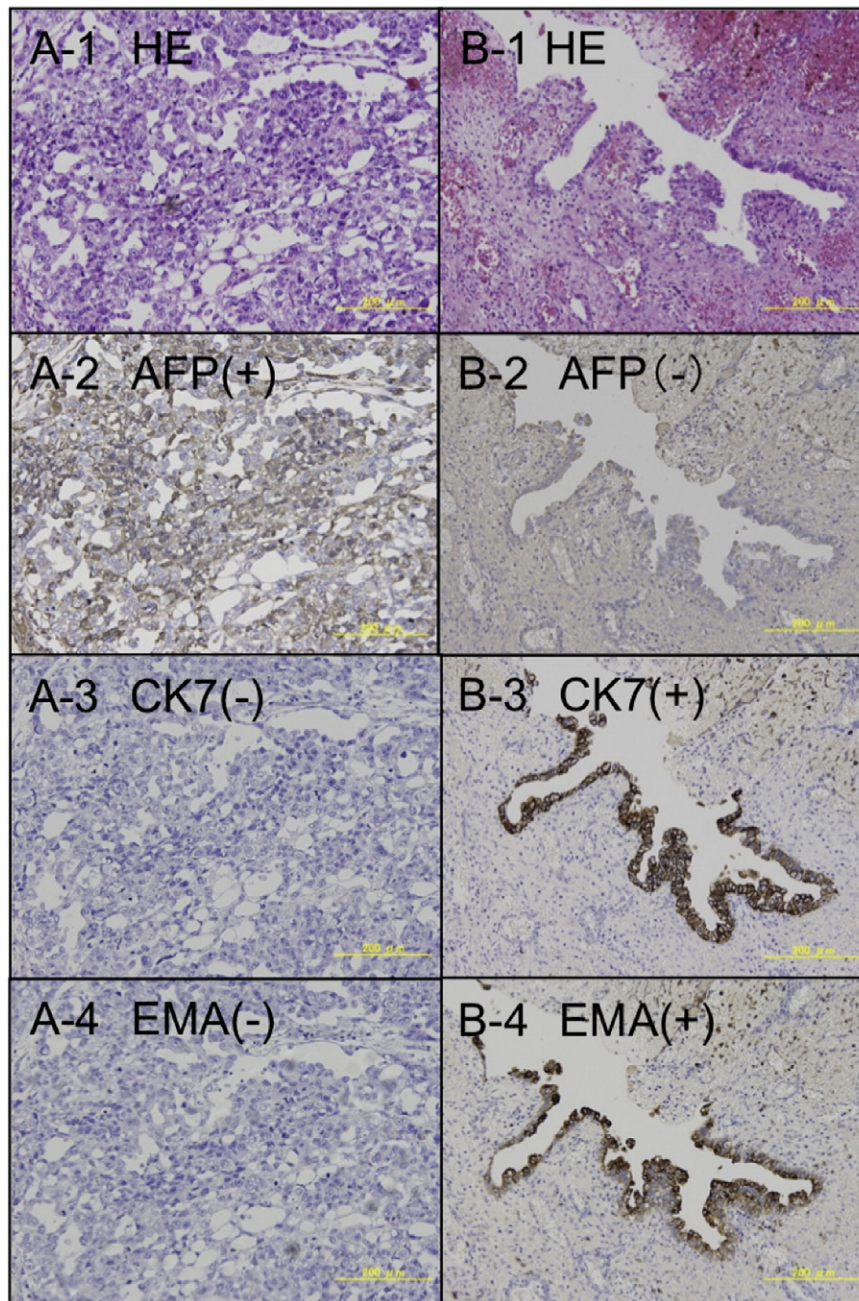


Fig. 3. Histopathological and immunohistochemical findings. The histopathological studies showed two different histological types, YST (A-1) and poorly differentiated endometrioid adenocarcinoma (B-1). The YST component was positive for AFP (A-2), but negative for CK7 (A-3) and EMA (A-4). In contrast, the endometrioid adenocarcinoma component was negative for AFP (B-2), but positive for CK7 (B-3) and EMA (B-4).

Conflict of interest statement

No authors have any conflicts of interest to declare.

Appendix A. Supplementary data

Supplementary data to this article can be found online at <http://dx.doi.org/10.1016/j.gynor.2014.04.002>.

References

- Amant, F., Van Calsteren, K., Halaska, M.J., Beijnen, J., du Bois, A., et al., 2009. Gynecologic cancers in pregnancy: guidelines of an international consensus meeting. *Int. J. Gynecol. Cancer* 19, S1–S12.
- Bose, C.K., Mukherjee, M., 1993. Alpha-fetoprotein in advanced epithelial ovarian cancer. *Br. J. Obstet. Gynaecol.* 100, 1149–1150.
- Casper, S., van Nagell, J.R., Jr, Powell D.F., Dubilier, L.D., Pavlik, E.J., et al., 1984. Immunohistochemical localization of tumor markers in epithelial ovarian cancer. *Am. J. Obstet. Gynecol.* 149, 154–158.
- Clement, P.B., Young, R.H., Scully, R.E., 1987. Endometrioid-like variant of ovarian yolk sac tumor. A clinicopathologic analysis of eight cases. *Am. J. Surg. Pathol.* 11, 767–778.
- Hong, D.G., Chong, G.O., Seong, W.J., Lee, Y.S., Park, I.S., et al., 2010. A case of ovarian endometrioid adenocarcinoma with yolk sac tumor in a 35-year-old woman. *Eur. J. Gynaecol. Oncol.* 31, 471–474.
- Kamoi, S., Ohaki, Y., Mori, O., Osada, S., Araki, T., et al., 2002. A case of ovarian endometrioid adenocarcinoma with yolk sac tumor component in a postmenopausal woman. *APMIS* 110, 508–514.
- Nogales, F.F., Bergeron, C., Carvia, R.E., Alvaro, T., Fulwood, H.R., 1996. Ovarian endometrioid tumors with yolk sac tumor component, an unusual form of ovarian neoplasm. Analysis of six cases. *Am. J. Surg. Pathol.* 20, 1056–1066.
- Ramalingam, P., Malpica, A., Silva, E.G., Gershenson, D.M., Deavers, M.T., et al., 2004. The use of cytokeratin 7 and EMA in differentiating ovarian yolk sac tumors from endometrioid and clear cell carcinomas. *Am. J. Surg. Pathol.* 28, 1499–1505.
- Rutgers, J.L., Young, R.H., Scully, R.E., 1987. Ovarian yolk sac tumor arising from an endometrioid carcinoma. *Hum. Pathol.* 18, 1296–1299.
- Talerman, A., Vang, R., 2011. Germ cell tumors of the ovary, In: Kurman, R.J., Ellenson, L.H., Ronnett, B.M. (Eds.), *Blaustein's Pathology of the Female Genital Tract*, 6th ed. Springer-Verlag, New York, pp. 847–908.